

# Successful Treatment of a Multidrug-Resistant Tuberculosis Patient with a Negative Xpert MTB/RIF Test for Rifampicin-Resistant Tuberculosis in Guizhou Province of China: A Case Report

This article was published in the following Dove Press journal:  
*Infection and Drug Resistance*

Zhao-Liang Zhao<sup>1</sup>

Ling Chen<sup>1</sup>

Hong Zhang<sup>1,2</sup>

<sup>1</sup>Tuberculosis Division of Respiratory and Critical Care Medicine, Affiliated Hospital of Zunyi Medical University, Zunyi, Guizhou 563003, People's Republic of China; <sup>2</sup>Z-BioMed, Inc., Rockville, MD 20855, USA

**Abstract:** The Xpert MTB/RIF (Xpert) assay recommended by the World Health Organization (WHO) can be used to simultaneously detect *Mycobacterium tuberculosis* complex (MTBC) and rifampicin (RIF) resistance associated mutations. However, if Xpert testing results are negative for RIF resistance because mutations outside the RIF resistance-determining region (RRDR) are not detectable by the assay, patients with RIF-resistant/multidrug-resistant tuberculosis (RR/MDR-TB) will be treated inappropriately for several weeks prior to obtaining the drug susceptibility testing (DST) results. Here, we report a rare case of TB in Guizhou Province of China that was identified as RIF-susceptible by the Xpert MTB/RIF assay, but later was confirmed as MDR-TB by DST, and its successful treatment with effective second-line anti-TB drugs. We detected a rare *rpoB* mutation (Ile572Phe) in clinical samples of this patient, highlighting the importance of using other methods such as PCR and sequencing to complement the Xpert MTB/RIF assay for the routine diagnosis of RR/MDR-TB because of the limited scope of the assay. These complementary methods allow for the detection of rare *rpoB* mutations outside the RRDR and can be beneficial when used in geographical locations where such *rpoB* mutations are frequently reported. However, these methods may not be feasible for resource-limited settings.

**Keywords:** commercial tests, MTB/RIF Xpert assays, Ile572Phe, Ile491Phe, rifampicin/multidrug-resistant tuberculosis

## Introduction

Drug-resistant tuberculosis (DR TB) is a major global public health threat. In 2018, about half a million new cases of rifampicin (RIF)-resistant TB (RR-TB) were reported to WHO. Rifampicin resistance was considered as a predictor of multidrug-resistant TB (MDR-TB) because 78% of RR-TB were MDR-TB.<sup>1</sup> To prevent the spread of RR/MDR-TB through quick diagnosis and effective treatment, WHO recommended the use of the Xpert MTB/RIF assay (Xpert, Cepheid, USA) for the rapid diagnosis of *Mycobacterium tuberculosis* complex (MTBC) and uncovering RIF resistance by detecting common mutations in the 81 bp RIF resistance-determining region (RRDR) of the *rpoB* gene.<sup>1</sup> Usually, when Xpert testing results are positive for MTBC and RR, effective second-line regimens are immediately initiated for TB patients weeks before the drug susceptibility testing (DST) results become available. However, *rpoB* mutations outside the RRDR are undetectable by

Correspondence: Ling Chen; Hong Zhang  
Tel +86-851-28609237  
Fax +86-851-28608239  
Email lingjuncd@163.com;  
hzhang@zbiomed.com

commercial molecular assays such as the Xpert MTB/RIF assay.<sup>2</sup> If Xpert MTB/RIF testing results are negative for RR due to the limited scope of the assay, but later confirmed by DST as RR/MDR-TB, patients with RR/MDR-TB would be treated inappropriately for several weeks prior to obtaining the DST results. During that period, RR/MDT-TB patients treated with ineffective regimens could potentially spread the pathogen to many people in public places, causing heavy economic and social burdens. Here, we report a rare case of TB, which was identified as RIF-susceptible by the Xpert MTB/RIF assay, but was confirmed as MDR-TB by DST, and its successful treatment with effective second-line anti-TB drugs.

## Case Report

A 32-year-old Chinese woman with a five-year history of pulmonary TB presented to our hospital in February 2017 with symptoms of cough, sputum, and shortness of breath. Physical examination revealed that her heart and abdomen were normal, and no dry and wet rales were heard in her lungs. Computed tomography (CT) scans of the chest showed bilateral pulmonary TB with cavities, bilateral pleural thickening, and enlarged lymph nodes in the upper mediastinum (Figure 1, A1 and A2). Her sputum smear results revealed the presence of acid-fast bacilli (AFB) graded as 2<sup>+</sup>. No obvious abnormality was found in routine biochemical tests. The patient claimed to have no history of hypertension, diabetes, hepatitis, typhoid and other infectious diseases. While waiting for the DST results, a treatment with four first-line anti-TB drugs was initiated, which included isoniazid (INH, 400 mg daily), RIF (450 mg daily), pyrazinamide (PZA, 1.5 g daily), and ethambutol (EMB, 0.75 mg daily).

Three months later, chest CT scans of the patient showed increased lesions in her left lung (data not shown) and her sputum smear was still graded as 2<sup>+</sup>. Results from the Xpert MTB/RIF assay were positive for MTBC but negative for RIF resistance, suggesting that the *M. tuberculosis* isolate was susceptible to RIF. However, results from the traditional DST showed that the clinical isolate collected from this patient three months after admission were resistant to INH, RIF, EMB, streptomycin (STR), levofloxacin (LFX), ofloxacin (OFX) and gatifloxacin (GFX), but susceptible to moxifloxacin (MFX), amikacin (AM), prothionamide (PTO), capreomycin (CM), kanamycin (KM) and para-aminosalicylic acid (PAS). Based on the DST results and WHO treatment guidelines for drug-resistant TB, a new treatment regimen was

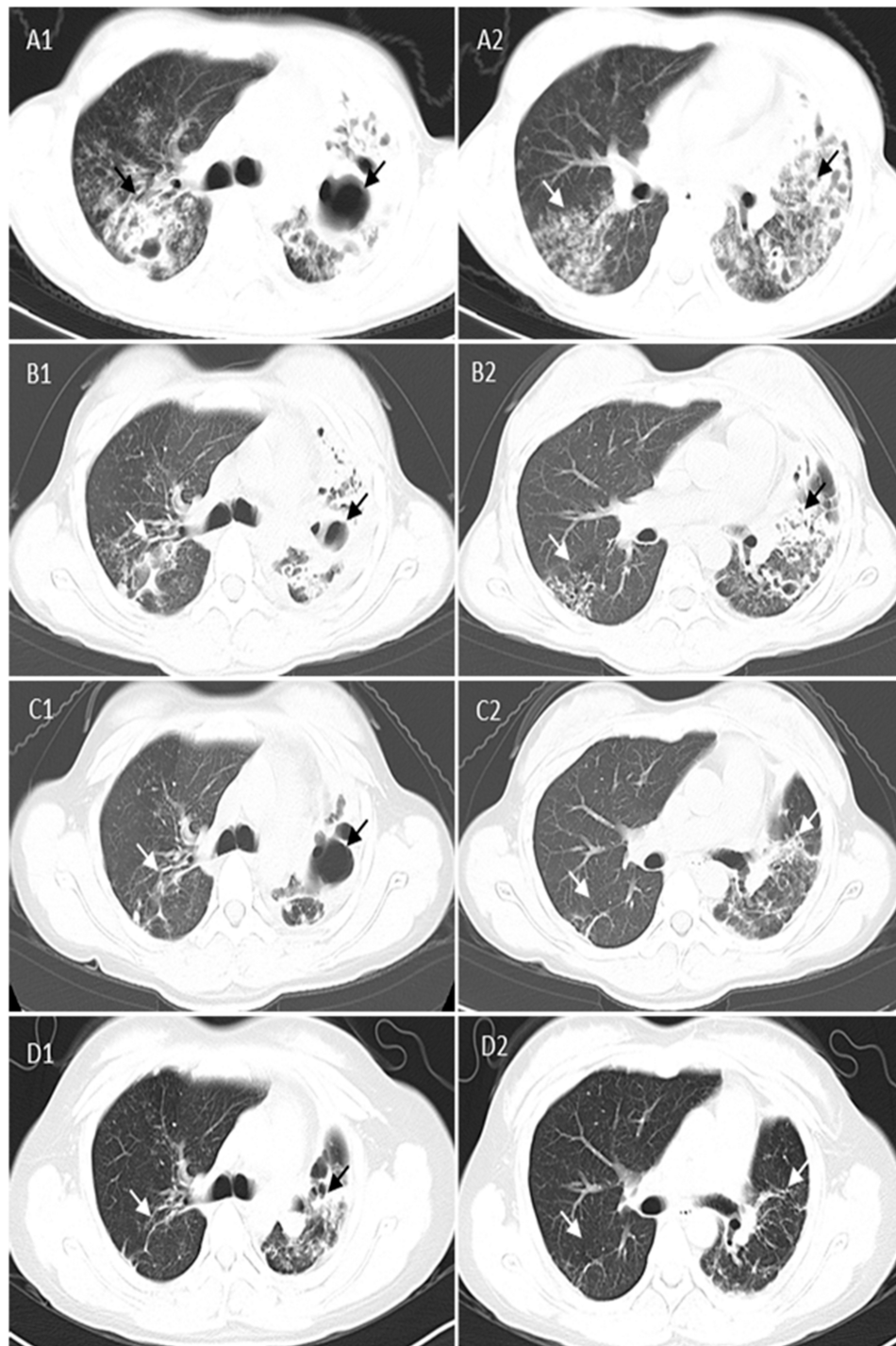
subsequently selected for this confirmed MDR-TB patient. This regimen contained up to five TB medicines from different groups: group A (fluoroquinolones), MFX; group B (second-line injectable agents), AM; group C (other core second-line agents), PTO and cycloserine (CS); and group D1 (add-on agents), pyrazinamide (PZA).<sup>3</sup> The 20-month treatment plan included six months with five medicines (MFX, 400 mg daily; AM, 600 mg a day intramuscularly and five times weekly; CS, 500 mg daily; PTO, 600 mg daily; and PZA, 1.5 g daily), and 14 months with four medicines (MFX, 400 mg daily; CS, 500 mg daily; PTO, 600 mg daily; and PZA, 1.5 g daily).

During the revised treatment period, patient's sputum smears for AFB were negative seven times while sputum cultures were negative four times during testing at two, four and 11 months. Chest CT scans of the patient performed two months after starting the new treatment showed decreased lesions in bilateral lungs (Figure 1, B1 and B2), and those performed at eight months after starting the new treatment showed that lesions and cavities in bilateral lungs disappeared while pulmonary fibrosis remained unchanged, indicating the treatment was successful (Figure 1, C1 and C2). After the lung lesions of the patient stabilized and her symptoms abated, treatments with second-line anti-TB medicines were discontinued after the 20 months. Follow-up chest CT scans performed seven months after the completion of the 20-months of treatment showed that patient's lung lesions and fibrosis remained unchanged (Figure 1, D1 and D2), and sputum cultures were negative for *M. tuberculosis*.

To understand why the Xpert MTB/RIF results were inconsistent with the DST results, we extracted genomic DNA from the clinical isolate (No. s20170731y)<sup>4</sup> collected from the first sputum sample of this patient when she was admitted to the hospital, and sequenced the entire RNA polymerase  $\beta$ -subunit (*rpoB*) gene. We detected an A→T nucleotide substitution at the *Escherichia coli* codon position 572 of the *rpoB* gene (ATC572TTC) leading to a missense mutation (Ile572Phe), which was the same as the *M. tuberculosis* codon position 491 (Ile491Phe).<sup>5</sup> In addition, sequencing results showed no other mutations in the *rpoB* coding region including the 81 bp RRDR.

## Discussion

Resistance of *M. tuberculosis* to RIF is mainly caused by mutations in the *rpoB* gene, and the majority of mutations are located in the RRDR.<sup>6</sup> Mutations outside the RRDR, such as Val146Phe and Ile572Phe, were also found to be



**Figure 1** Comparison of cross-sectional chest CT scan images of the patient with MDR-TB at different time points before and after taking effective treatment regimens. **(A)** Three months before effective treatment regimens showing multiple lesions and cavities in bilateral lungs (black and white arrowheads) at two cross-sections **(A1 and A2)**; **(B)** Two months after effective treatment regimens showing absorption of multiple lesions and cavities in bilateral lungs (black and white arrowheads) at two cross-sections **(B1 and B2)**; **(C)** Eight months after effective treatment regimens showing multiple lesions and cavities in bilateral lungs disappeared (more obvious in the right lung), and fibrosis remained unchanged (black and white arrowheads) at two cross-sections **(C1 and C2)**; and **(D)** Seven months after the 20-month treatment using effective regimens showing multiple lesions and cavities in bilateral lungs disappeared (more obvious in the right lung) and pulmonary fibrosis remained unchanged (black and white arrowheads) at two cross-sections **(D1 and D2)**. CT, computed tomography; MDR-TB, multidrug-resistant tuberculosis.

associated with RIF resistance in *M. tuberculosis* isolates.<sup>7,8</sup> Currently, commercial molecular assays such as the Xpert MTB/RIF and Genotype MTBDR<sub>plus</sub> VER 2.0 are unable

to detect *rpoB* gene mutations outside the RRDR.<sup>2</sup> Therefore, a novel rapid PCR method was developed to detect the Ile491Phe mutation and proposed to complement

commercial assays for the diagnosis of RR-TB, particularly in countries where this specific mutation is frequent.<sup>9,10</sup>

In this case report, results from the Xpert MTB/RIF assay indicated that the *M. tuberculosis* was susceptible to RIF, but results from the traditional DST showed that the clinical isolate collected from this patient was MDR-TB. Our sequencing results demonstrated that the inconsistency was caused by a point mutation at the codon 572 of the *rpoB* gene (Ile572Phe), which was detected previously in RIF-resistant clinical *M. tuberculosis* isolates.<sup>8,11</sup> It has been reported that *rpoB* mutation profiles of RR-TB isolates are variable depending on the geographical locations,<sup>8</sup> and the same is true for the Ile572Phe mutation. For example, the Ile572Phe mutation was identified in one out of 33 RR-TB isolates (3.0%) in Australia,<sup>11</sup> in one out of 32 RR-TB isolates (3.1%) in Guizhou Province of China,<sup>8</sup> in one out of 50 RR-TB isolates (2.0%) in Hong Kong,<sup>7</sup> and in one out of 53 RR-TB isolates (1.9%) in Pakistan.<sup>12</sup>

Even though the Ile572Phe (Ile491Phe in the *M. tuberculosis* numbering system) mutation is relatively uncommon, assuming 2% to 3% prevalence in the 500,000 new cases of RR-TB reported globally in 2018, thousands of RR-TB patients may have been misidentified as RIF-susceptible using current commercial molecular assays. Delayed appropriate treatment of RR/MDR-TB patients could lead to extended treatment periods, increases in unsuccessful treatment outcomes, and outbreaks of *M. tuberculosis* strains with rare mutations such as the Ile572Phe mutation. In this case report, the patient required effective drug regimens consisting of up to five TB medicines from different groups over 20 months in order to be successfully treated, highlighting the importance of rapid and appropriate diagnosis and treatment of RR/MDR-TB.

In conclusion, as the Xpert MTB/RIF assay is increasingly used for simultaneous detection of MTBC and RR, other methods such as PCR and sequencing should be used to complement commercial assays such as the Xpert MTB/RIF for the routine diagnosis of RR/MDR-TB because of the limited scope of the assay. These complementary methods allow for detection of rare *rpoB* mutations outside the RRDR and can be beneficial when used in geographical locations where such mutations (Val146Phe and Ile572Phe) are frequently reported. However, these methods may not be feasible for some resource-limited settings.

## Consent

Written informed consent was obtained from the patient for publication of this report. The collection of *M. tuberculosis* isolates was a part of the routine hospital laboratory procedures and therefore the institutional approval was not required to publish the case details.

## Acknowledgments

This study was supported by the National Natural Science Foundation of China (NSFC no. 81760003), the 2nd 2011 Collaborative Innovation Center for TB Prevention and Cure in Guizhou Province (Incubation Project), and the 4th Talented Individual Base for Infectious Disease Prevention and Control in Guizhou Province (Qian 2013–15). The sponsors played no role in the collection, analysis, and interpretation of data; in writing the manuscript; and in the decision to submit the report for publication. We thank Derek T. Zhang for reading, editing and revising the manuscript prior to submission.

## Disclosure

HZ is employed by and has shares in Z-BioMed, Inc., which is involved in infectious disease research. The authors report no other conflicts of interest in this work.

## References

1. World Health Organization. *Global Tuberculosis Report 2019*. Geneva: World Health Organization; 2019. Licence: CCBY-NC-SA3.0/IGO.
2. Torrea G, Ng KCS, Van Deun A, et al. Variable ability of rapid tests to detect *Mycobacterium tuberculosis* *rpoB* mutations conferring phenotypically occult rifampicin resistance. *Sci Rep*. 2019;9(1):11826. doi:10.1038/s41598-019-48401-z
3. World Health Organization. WHO treatment guidelines for drug-resistant tuberculosis. Geneva, Switzerland; 2016. Available from: <http://apps.who.int/medicinedocs/en/d/Js23097en/>. Accessed January 5, 2020.
4. van Soolingen D, Hermans PW, de Haas PE, Soll DR, van Embden JD. Occurrence and stability of insertion sequences in *Mycobacterium tuberculosis* complex strains: evaluation of an insertion sequence-dependent DNA polymorphism as a tool in the epidemiology of tuberculosis. *J Clin Microbiol*. 1991;29(11):2578–2586.
5. Andre E, Goeminne L, Cabibbe A, et al. Consensus numbering system for the rifampicin resistance-associated *rpoB* gene mutations in pathogenic mycobacteria. *Clin Microbiol Infect*. 2017;23(3):167–172. doi:10.1016/j.cmi.2016.09.006
6. Zaw MT, Emran NA, Lin Z. Mutations inside rifampicin-resistance determining region of *rpoB* gene associated with rifampicin-resistance in *Mycobacterium tuberculosis*. *J Infect Public Health*. 2018;11(5):605–610. doi:10.1016/j.jiph.2018.04.005
7. Siu GK, Zhang Y, Lau TC, et al. Mutations outside the rifampicin resistance-determining region associated with rifampicin resistance in *Mycobacterium tuberculosis*. *J Antimicrob Chemother*. 2011;66(4):730–733. doi:10.1093/jac/dkq519

8. Chen L, Gan X, Li NN, et al. rpoB gene mutation profile in rifampicin-resistant *Mycobacterium tuberculosis* clinical isolates from Guizhou, one of the highest incidence rate regions in China. *J Antimicrob Chemother.* 2010;65(6):1299–1301. doi:10.1093/jac/dkq102
9. André E, Goeminne L, Colmant A, Beckert P, Niemann S, Delmee M. Novel rapid PCR for the detection of Ile491Phe rpoB mutation of *Mycobacterium tuberculosis*, a rifampicin-resistance-conferring mutation undetected by commercial assays. *Clin Microbiol Infect.* 2017;23(4):267.e5–267.e7. doi:10.1016/j.cmi.2016.12.009
10. Al-Mutairi NM, Ahmad S, Mokaddas E, Eldeen HS, Joseph S. Occurrence of disputed rpoB mutations among *Mycobacterium tuberculosis* isolates phenotypically susceptible to rifampicin in a country with a low incidence of multidrug-resistant tuberculosis. *BMC Infect Dis.* 2019;19(1):3. doi:10.1186/s12879-018-3638-z
11. Yuen LK, Leslie D, Coloe PJ. Bacteriological and molecular analysis of rifampin-resistant *Mycobacterium tuberculosis* strains isolated in Australia. *J Clin Microbiol.* 1999;37(12):3844–3850. doi:10.1128/JCM.37.12.3844-3850.1999
12. Javed H, Bakula Z, Pleń M, et al. Evaluation of genotype MTBDRplus and MTBDRsl assays for rapid detection of drug resistance in extensively drug-resistant *Mycobacterium tuberculosis* isolates in Pakistan. *Front Microbiol.* 2018;9:2265. doi:10.3389/fmicb.2018.02265

## Infection and Drug Resistance

Dovepress

### Publish your work in this journal

Infection and Drug Resistance is an international, peer-reviewed open-access journal that focuses on the optimal treatment of infection (bacterial, fungal and viral) and the development and institution of preventive strategies to minimize the development and spread of resistance. The journal is specifically concerned with the epidemiology of

antibiotic resistance and the mechanisms of resistance development and diffusion in both hospitals and the community. The manuscript management system is completely online and includes a very quick and fair peer-review system, which is all easy to use. Visit <http://www.dovepress.com/testimonials.php> to read real quotes from published authors.

Submit your manuscript here: <https://www.dovepress.com/infection-and-drug-resistance-journal>