

Sphenoethmoidal mucocele presenting with unilateral visual loss

Harsha Bhattacharjee
Ronel Soibam
Nilutparna Deori

Neuroophthalmology Department,
Sri Sankaradeva Nethralaya, Guwahati,
Assam, India

Background: Sphenoethmoidal sinus mucocele causing unocular progressive vision loss is a rare entity and was first described by Bery in 1985. It is generally diagnosed in its advanced stage when the patients develop subjective ophthalmic symptoms.

Case: A 43-year-old male presented to our institute for further evaluation and treatment of progressive visual deterioration in his left eye. The patient complained of visual impairment in his left eye for the past three months, in the form of a dark area in his left side of the visual field.

Observations: Magnetic resonance imaging (MRI) revealed a large expansile lesion in the left sided posterior ethmoidal air cells, abutting on the left optic nerve and displacing it in the region of the orbital apex. The patient underwent an urgent endoscopic sinus surgery by an Ear-Nose-Throat surgeon which resulted in stable visual acuity in the sixth postoperative month.

Conclusions: Sphenoethmoidal mucocele can cause irreversible blindness. Progressive vision loss with a neurological visual field defect should raise a high index of suspicion and computed tomography and MRI are to be performed to confirm the diagnosis. Collaboration between radiologists, ENT specialists, and ophthalmologists is essential for treating such cases.

Keywords: sphenoethmoidal mucocele, compressive optic neuropathy, visual field defect, endoscopic sinus surgery

Background

Sphenoethmoidal mucocele can cause irreversible blindness. Progressive vision loss with a neurological visual field defect should raise suspicion and computed tomography (CT) and magnetic resonance imaging (MRI) imaging are to be performed to confirm the diagnosis. Collaboration between radiologists, Ear-Nose-Throat (ENT) specialists, and ophthalmologists is essential for treating such cases.

A paranasal sinus mucocele is an encapsulated mass within a sinus containing mucoid secretions with desquamated epithelium and causing distension of the sinus walls. It is mostly found in the frontal and ethmoidal sinus and less commonly in the sphenoid sinus. Sphenoethmoidal sinus mucocele causing unocular progressive vision loss is a rare entity and only a few reports are available in ophthalmic literature since its first description by Bery in 1989.¹⁻⁵ This disease is most commonly diagnosed in its advanced stage because patients tend to seek examination only when they develop subjective ophthalmic symptoms.⁶ Early endoscopic surgical intervention may result in visual improvement.⁶ We herein report a rare case of sphenoethmoidal mucocele causing unilateral, painless progressive visual loss with immediate stabilization of vision following surgery.

Correspondence: Harsha Bhattacharjee
Sri Sankaradeva Nethralaya,
96 Basistha Rd, Beltola,
Guwahati, Assam, India 781028
Tel +91 361 2228879
Fax +91 361 2228878
Email ssnghy1@sify.com

Case

A 43-year-old man was referred to our institution in November 2008 for further evaluation and treatment of progressive visual deterioration out of retrobulbar neuritis in the left eye in spite of diagnosis and treatment with intravenous methylprednisolone at another medical centre. He complained of visual impairment in the left eye for the past three months, in the form of a dark area in his left side of the visual field. His medical and family history was unremarkable.

Observation

On examination, his visual acuity was 20/20 in the right eye and 20/30 in the left eye. Ocular movements were normal but relative afferent pupillary defect was present in the left eye. Fundus examination revealed generalized optic disc pallor, a well demarcated disc margin, and dilated retinal venules in the left eye (Figure 1). Computerized visual field analysis detected gross loss of threshold sensitivity except in the inferonasal quadrant where some sensitivity was retained (Figure 2). Extinguished visual-evoked potential (VEP) response was recorded in the left eye (Figure 3), while the right eye was clinically normal. Urgent MRI disclosed a large expansile T₂ hyperintense lesion in the left sided posterior ethmoid air cells encroaching the adjacent sphenoid sinus (Figure 4). On T₁-weighted images the lesion showed significant hyperintensity (Figure 5). The rest of the sphenoid sinus also contained mixed intensity components expressing hyperintense and hypointense signals. The lesion was abutting on the left optic nerve which was displaced in the region of orbital apex with narrowing of the superior orbital fissure. Depending upon the clinical and investigation findings, left compressive optic neuropathy caused by left sphenothmoidal mucocele was diagnosed and the patient underwent urgent endoscopic sinus surgery. Marsupialization of the mucocele was performed under general anesthesia, in which the anterior and interior walls (septum) of the mucocele were removed. Pathological examination confirmed diagnosis

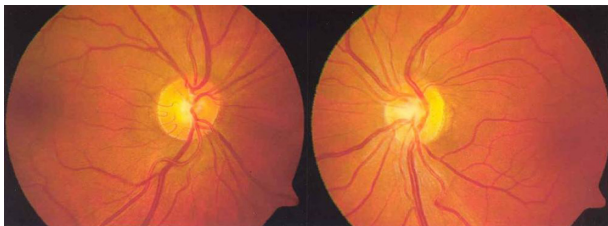


Figure 1 Fundus photo revealing generalized optic disc pallor, well demarcated disc margin and dilated retinal venules in the left eye.

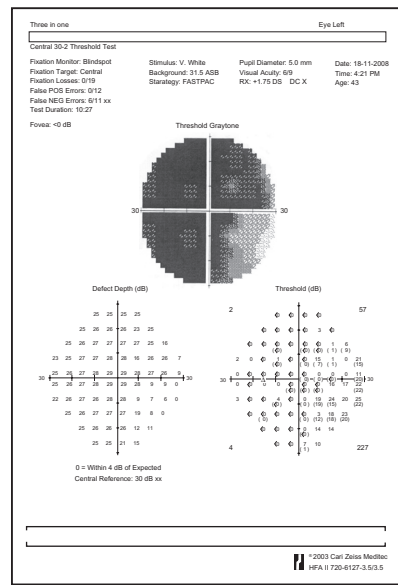


Figure 2 Computerized visual field analysis showing a neurological field defect in the left eye.

of a mucocele. At the sixth month postoperative follow up, vision was stable with persistent disc pallor (Figure 6). Humphrey field analysis detected paracentral scotoma (30-2 tests; Figure 7) in left eye. MRI revealed minimal residual collection of fluid in the mucocele (Figure 8), however there was no compression to the optic nerve.

Discussion

Sphenoethmoidal sinus mucocele is a rare cause of unilateral vision loss and blindness. Both genders are equally affected without any age predominance.¹⁻⁷ Clinical examination and imaging (CT and MRI) are the bases of diagnosis. Clinical

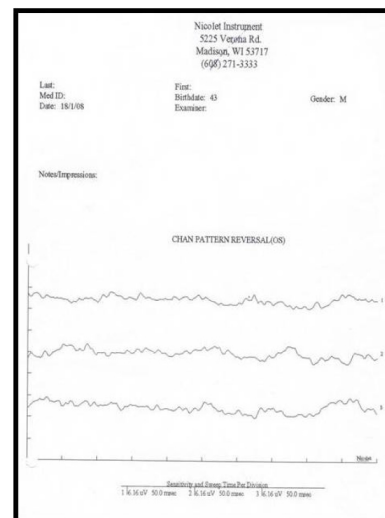


Figure 3 Flat visual-evoked potential response in the left eye.

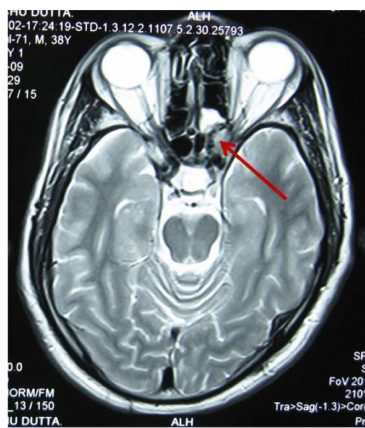


Figure 8 Magnetic resonance imaging showing minimal residual collection of fluid in the mucocoele (arrow).

theory of vision loss by the sphenothmoidal mucocoele. Thus, transnasal endoscopic surgical decompression is the standard surgical management of such cases and was carried out by an ENT surgeon for our patient. In the postoperative period, there was no further loss of vision.

Sphenothmoidal sinus mucocoeles can cause bilateral or even irreversible blindness and overall surgical prognosis may not be good.⁵ Ophthalmologists must be alert to this diagnosis. Progressive vision loss in one eye with a neurological visual field defect should raise a high index of suspicion and CT and MRI imaging need to be performed to confirm the diagnosis. Close collaboration between radiologists, ENT specialist, and ophthalmologists is essential for treating such cases.

Acknowledgments/disclosure

The authors thank Dr T Das and Dr N Medhi. The authors report no conflicts of interest in this work.

References

1. Nugent GR, Sprinle P, Bloor BM. Sphenoid sinus mucocoeles. *J Neurosurg.* 1970;32:443–451.
2. Tseng CC, Ho CY, Kao SC. Ophthalmic manifestations of paranasal sinus mucocoeles. *J Chin Med Assoc.* 2005;68:260–264.
3. Stankiewicz JA. Sphenoid sinus mucocoele. *Arch Otolaryngol Head Neck Surg.* 1989;115:735–740.
4. Lochrl TA, Leopold DA. Spheno-ethmoidal mucocoeles presenting with bilateral visual compromise. *Am Otol Rhinolaryngol.* 2000;109:608–610.
5. Levy J, Monos T, Puterman M. Bilateral consecutive blindness due to sphenoid sinus mucocoele with unilateral partial recovery. *Can J Ophthalmol.* 2005;40:506–508.
6. Moriyama H, Hesaka H, Tachibana T, Honda Y. Mucocoeles of ethmoid and sphenoid sinus with visual disturbance. *Arch Otolaryngol Head Neck Surg.* 1992;118:142–146.
7. Di Girolamo S, Cannizzaro P, Picciotti P, Nardi C. Ophthalmoplegia and ptosis as onset symptoms of an isolated primary mucocoele of the sphenoid sinus. *J Oral Maxillofac Surg.* 2002;60:1500–1502.
8. Chawla HS, Goodwin JA, Ticho BH, Feist RM. Orbital and sinus inflammation with secondary optic neuropathy. *Ann Ophthalmol.* 1991;23:231–233.
9. Shimo-Oku M, Miyazaki S, Shiraki K, Sagimoto T, Sotari H. Optic nerve involvement in posterior paranasal sinus disease. *Neuroophthalmology.* 1989;9:147–155.
10. Hiratsuka Y, Hotta Y, Yui A, Nakayasu K, Kanai A, Yamakawa T. Rhinogenic optic neuropathy cause bilateral loss of light perception. *Br J Ophthalmol.* 1998;82:99–100.

Eye and Brain

Publish your work in this journal

Eye and Brain is an international, peer-reviewed, open access journal focusing on clinical and experimental research in the field of neuro-ophthalmology. All aspects of patient care are addressed within the journal as well as basic research. Papers covering original research, basic science, clinical and epidemiological studies, reviews and

Submit your manuscript here: <http://www.dovepress.com/eye-and-brain-journal>

Dovepress

evaluations, guidelines, expert opinion and commentary, case reports and extended reports are welcome. The manuscript management system is completely online and includes a very quick and fair peer-review system, which is all easy to use. Visit <http://www.dovepress.com/testimonials.php> to read real quotes from published authors.