


# Infectious dermatoses that can manifest as vesicles

This article was published in the following Dove Press journal:  
*Infection and Drug Resistance*

Yongxuan Hu 

Department of Dermatology and Venereology, The 3rd Affiliated Hospital of Southern Medical University, Guangzhou, Guangdong, People's Republic of China

**Abstract:** In dermatology, diseases that manifest as blisters or blister-like lesions are common, and some of these features are caused by infectious diseases. Here, we summarize and describe these diseases to increase their clinical awareness and diagnosis.

**Keywords:** infectious dermatosis, vesicles

## Introduction

In dermatology, diseases that manifest as blisters or blister-like lesions are common, and some of these features are caused by infectious diseases. These conditions not only include bacterial and viral infections, but also fungal infections. Some of these diseases can be accurately diagnosed based on typical clinical manifestations and characteristics. However, some are easily misdiagnosed because of the atypical symptoms. In the diagnosis of these diseases, it is necessary to distinguish not only non-infectious skin diseases but also the infectious diseases themselves. Here, we summarize and describe the common infections associated with these diseases to increase their clinical awareness and diagnosis.

## Clinical manifestations and characteristics

### Erysipelas

Erysipelas is a common soft tissue bacterial infection, and the typical clinical manifestations include redness, swelling, heat, and pain in the local tissue. Some erysipelas infections may exhibit blisters or bullae due to erythema and occasional itching (Figure 1A).<sup>1,2</sup> The diagnosis of erysipelas can be based on typical clinical manifestations and routine blood tests, and biopsy can be performed if necessary.

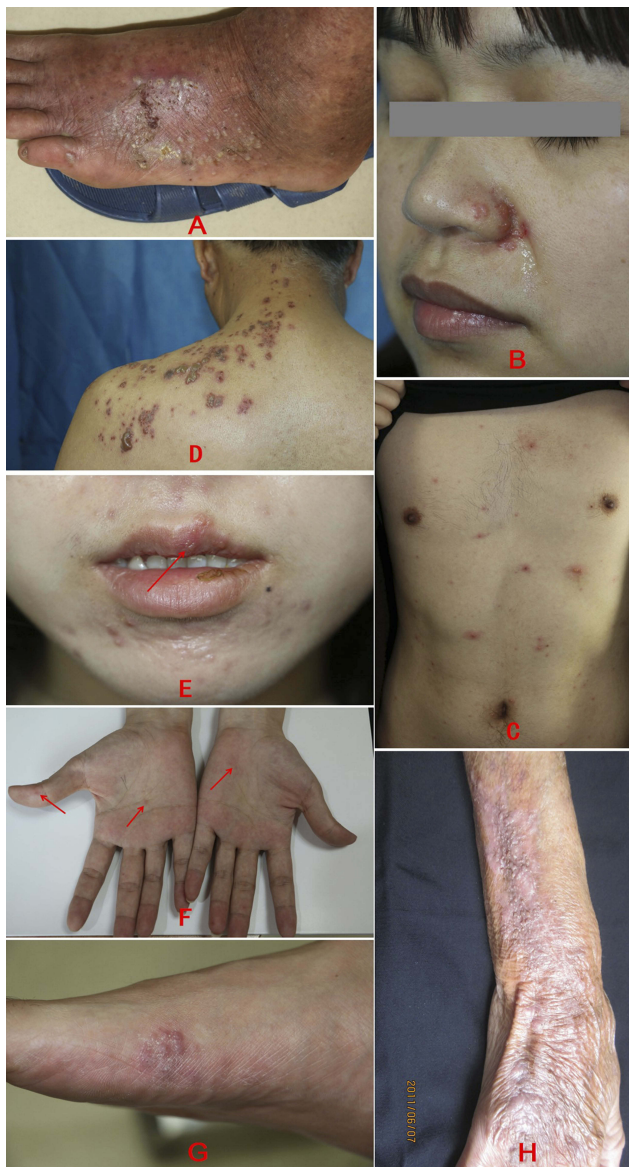### Impetigo

Impetigo is a highly contagious bacterial skin infection and is one of the most common skin infections in children, among which 30% of cases are bullous impetigo.<sup>3,4</sup> Bullous impetigo is caused exclusively by *Staphylococcus aureus*, and the typical clinical manifestation is large, flaccid bullae that are likely to affect intertriginous areas.<sup>5</sup> The diagnosis of impetigo can be based on typical clinical manifestations, routine blood tests, repeated bacterial culture and drug sensitivity tests.

### *Serratia marcescens* infection

Most *Serratia marcescens* infections are iatrogenic infections. Skin infections are uncommon, and the appearance of blister-like skin infections is even rarer. We have diagnosed one case of facial *Serratia marcescens* infection with blisters (Figure 1B). This

Correspondence: Yongxuan Hu  
Department of Dermatology and Venereology, The 3rd Affiliated Hospital of Southern Medical University, Guangzhou, Guangdong, People's Republic of China  
Tel +86 20 6278 4560  
Fax +86 20 6278 4560  
Email huyongxuan2003@163.com



**Figure 1** Infectious dermatoses that can manifest as vesicles. Some infectious dermatoses can manifest as vesicles. (A) There are blisters, redness, swelling in the left foot. (B) There are blisters in the left nose after scratched acne lesions. (C) There are herpes on the head, face, trunk and limbs. (D) Typical clinical manifestations of herpes zoster include localized erythema and blisters. (E) There are localized erythema and blisters in the left upper lip. (F) Typical clinical manifestations include erythema and blisters on the hands, feet and oral cavity. (G) There are blisters in the right feet. (H) There are blisters-like rash in the right forearm.

type of infection involves scratching, “picking” of acne lesions and other traumatic history. The lesions do not involve itching and pain.<sup>6-8</sup> This infection is easily misdiagnosed. Etiological tests include bacterial and fungal cultures, and pathological biopsy is extremely important for the diagnosis of this disease.

## Leprosy

Leprosy is a teratogenic, disabling disease caused by infection with *Mycobacterium leprae*. Blister lesions in

leprosy are a rare phenomenon and occur clinically in certain types of leprosy and leprosy reactions, thus they are very easy to misdiagnose. Repeated bacteriological examinations, pathological biopsy, and neurological tests are extremely important for diagnosis.<sup>9</sup>

## Chicken pox

Chicken pox can occur in children, young adults, and the elderly, but the disease is most common in children. Typical clinical manifestations of chicken pox include fever and other discomfort, and herpes on the basis of erythema can be widespread (Figure 1C). Most skin lesions involve mild itching.<sup>10</sup> The diagnosis of chicken pox is based on typical clinical manifestations, epidemiological history, and routine haematological examinations. The diagnosis is generally not difficult.

## Herpes zoster

Herpes zoster is varicella zoster virus infection that results in reactivation of latent virus. Female sex, age, family history and comorbidities are risk factors for herpes zoster. Classically, a single dermatome is involved, and the lesions usually do not cross the midline. Typical clinical manifestations of herpes zoster include localized erythema and blisters (Figure 1D), and infection is often accompanied by limited pain and itching.<sup>11-13</sup> The diagnosis is simple and based on typical clinical manifestations combined with dermoscopic observations and virus detection when necessary.

## Herpes simplex

Herpes simplex virus, including HSV-1 and HSV-2 infections, is highly prevalent worldwide. HSV-2 often causes genital herpes and is a leading cause of sexually transmitted infections. A typical clinical manifestation of herpes simplex virus infection is localized rash, including erythema and blisters, often accompanied by a burning sensation and partial pain (Figure 1E). Herpes simplex virus often recurs throughout the lifetime of infected hosts.<sup>14,15</sup> The diagnosis is generally simple and based on typical clinical manifestations and virus detection combined with dermoscopic observations.

## Hand-foot-mouth disease

Hand-foot-mouth disease (HFMD) is a common viral illness that usually affects infants and children, although it can sometimes affect adults. The main causes of HFMD are coxsackievirus A type 16 and other strains of coxsackievirus.

The virus generally spreads through the respiratory tract. The infection usually involves the hands, feet, mouth and sometimes the genitals and buttocks. Typical clinical manifestations of the infection include erythema and blisters on the hands and feet and vesicles or ulcers in the oral cavity with or without itching and pain (Figure 1F). Different degrees of fever can occur before or when the rash appears.<sup>16,17</sup> The diagnosis is not difficult and is based on typical clinical manifestations, epidemiological history, and haematological examinations.

## Tinea pedis

Tinea pedis or foot ringworm is a foot infection caused by dermatophyte fungi, such as *Trichophyton rubrum*, *Trichophyton interdigitale* and *Epidermophyton floccosum*.

The major clinical variants of tinea pedis are the interdigital type, plantar moccasin type and vesiculobullous type (Figure 1G).<sup>18</sup> The diagnosis of tinea pedis relies on typical clinical manifestations, direct smear examination with fungal culture, and staining with Periodic Acid-Schiff stain (PAS) or methenamine silver stain for pathological examination.

## Chromoblastomycosis

Chromoblastomycosis is one of the most frequent chronic infections caused by melanized fungi, such as *Cladophialophora carrionii*, *Fonsecaea monophora* and *Fonsecaea pedrosoi*. There are several different clinical manifestations of chromoblastomycosis, including plaque, tumoral, cicatricial, verrucous, pseudo-vacuole, eczematous and mixed types of lesions; the pseudo-vacuole type is very rare (Figure 1H).<sup>19,20</sup> The correct diagnosis depends on adequate mycological tests including direct examination, culture, molecular biology identification, and histopathology of the lesions.

## Syphilis

Syphilis is a sexually transmitted disease caused by *Treponema pallidum*. The incidence of syphilis is increasing in China, and it remains a major public health problem. The clinical manifestations of syphilis are often not specific, except for a few specific indicators. Syphilis can be manifested as a variety of other skin diseases; therefore, it is called a “universal simulator”. This also leads to misdiagnosis or missed diagnosis of syphilis.<sup>21,22</sup> Personal

history and blood antibody tests are crucial for the diagnosis of syphilis.

## Mycoplasma infection

Mycoplasma infection is usually characterized by genitourinary tract inflammation or pneumonia caused by mycoplasma, such as *Ureaplasma urealyticum*, *Mycoplasma genitalium*, *Mycoplasma hominis* and *Mycoplasma pneumoniae*. Mycoplasma-induced skin manifestations, especially blister changes, are relatively rare.<sup>23</sup> The correct diagnosis may depend on mycoplasma culture, drug sensitivity tests, molecular biology identification, and histopathology of the lesions.

## Possible diagnostic steps

Infectious dermatoses that can manifest as vesicles include bacteria, viruses, fungi, syphilis and other infections. In many cases, these infections are easily misdiagnosed.

A detailed medical history request is the first step in making a correct diagnosis. Next, a comprehensive physical examination and detailed local examination should be performed. In some cases, it is necessary to use auxiliary tools such as a magnifying glass or a dermascope. Targeted auxiliary blood examinations should include routine blood tests and syphilis serology. Etiological examinations, such as fungal smear, fungal culture and bacterial culture from skin vesicles and/or skin tissue, are necessary.

However, the biopsy of skin lesions is crucial for the final diagnosis.

## Acknowledgment

This work was supported by a grant from the Natural Science Foundation of Guangdong Province (2017A030313457).

## Disclosure

The author reports no conflicts of interest in this work.

## References

1. Krasagakis K, Samonis G, Valachis A, Maniatakis P, Evangelou G, Tosca A. Local complications of erysipelas: a study of associated risk factors. *Clin Exp Dermatol*. 2011;36(4):351–354. doi:10.1111/j.1365-2230.2010.03978.x
2. Chong FY, Thirumoorthy T. Blistering erysipelas: not a rare entity. *Singapore Med J*. 2008;49(10):809–813.
3. Hartman-Adams H, Banvard C, Juckett G. Impetigo: diagnosis and treatment. *Am Fam Physician*. 2014;90(4):229–235.
4. D’Cunha NM, Peterson GM, Baby KE, Thomas J. Impetigo: a need for new therapies in a world of increasing antimicrobial resistance. *J Clin Pharm Ther*. 2018;43(1):150–153. doi:10.1111/jcpt.12639

5. Pimentel de Araujo F, Tinelli M, Battisti A, et al. An outbreak of skin infections in neonates due to a staphylococcus aureus strain producing the exfoliative toxin A. *Infection*. 2018;46(1):49–54. doi:10.1007/s15010-017-1084-2
6. Rallis E, Karanikola E, Papadakis P. Severe facial infection caused by *serratia marcescens* in an immunocompetent soldier. *J Am Acad Dermatol*. 2008;58(5 Suppl 1):S109–S110. doi:10.1016/j.jaad.2007.04.010
7. Yoshida R, Takae Y, Fujio Y, Tanaka M, Ohyama M. Cutaneous *serratia marcescens* infection on the face of a healthy female. *J Eur Acad Dermatol Venereol*. 2009;23(10):1213–1215. doi:10.1111/j.1468-3083.2009.03119.x
8. Ryu DJ, Oh SH, Choi YJ, Lee JH. A case of *serratia marcescens* infection after augmentation rhinoplasty. *Dermatol Surg*. 2010;36(12):2079–2081. doi:10.1111/j.1524-4725.2010.01788.x
9. Agarwal US, Mehta S, Kumar R, Besarwal RK, Agarwal P. Bullous lesions in leprosy: a rare phenomenon. *Indian J Dermatol Venereol Leprol*. 2013;79(1):107–109. doi:10.4103/0378-6323.104682
10. Navaratnam AMD, Ma N, Farrukh M, Abdulla A. Chickenpox: an ageless disease. *BMJ Case Rep*. 2017. pii: bcr-2017-222027. doi:10.1136/bcr-2017-222027
11. O'Connor KM, Paauw DS. Herpes zoster. *Med Clin North Am*. 2013;97(4):503–522. doi:10.1016/j.mcna.2013.02.002
12. Nair P, Gharote H, Singh P, Jain-Choudhary P. Herpes zoster on the face in the elderly. *BMJ Case Rep*. 2014. pii: bcr2013200101. doi:10.1136/bcr-2013-200101
13. Afonso T, Pires R. Images in clinical medicine. herpes zoster mandibularis. *N Engl J Med*. 2016;375(4):369. doi:10.1056/NEJMicm1513572
14. Jaishankar D, Shukla D. Genital herpes: insights into sexually transmitted infectious disease. *Microb Cell*. 2016;3(9):438–450. doi:10.15698/mic2016.09.528
15. El Hayderi L, Rübben A, Nikkels AF. The alpha-herpesviridae in dermatology: herpes simplex virus types I and II. *Hautarzt*. 2017;68(Suppl 1):1–5. doi:10.1007/s00105-016-3919-7
16. Murase C, Akiyama M. Hand, foot, and mouth disease in an adult. *N Engl J Med*. 2018;378(14):e20. doi:10.1056/NEJMc1711583
17. Esposito S, Principi N. Hand, foot and mouth disease: current knowledge on clinical manifestations, epidemiology, aetiology and prevention. *Eur J Clin Microbiol Infect Dis*. 2018;37(3):391–398. doi:10.1007/s10096-018-3206-x
18. Romano C, Rubegni P, Ghilardi A, Fimiani M. A case of bullous tinea pedis with dermatophytid reaction caused by trichophyton violaceum. *Mycoses*. 2006;49(3):249–250. doi:10.1111/j.1439-0507.2006.01234.x
19. Queiroz-Telles F, de Hoog S, Santos DW, et al. Chromoblastomycosis. *Clin Microbiol Rev*. 2017;30(1):233–276. doi:10.1128/CMR.00032-16
20. Lu S, Lu C, Zhang J, Hu Y, Li X, Xi L. Chromoblastomycosis in Mainland China: a systematic review on clinical characteristics. *Mycopathologia*. 2013;175(5–6):489–495. doi:10.1007/s11046-012-9586-z
21. Kim JK, Choi SR, Lee HJ, Kim DH, Yoon MS, Jo HS. Congenital syphilis presenting with a generalized bullous and pustular eruption in a premature newborn. *Ann Dermatol*. 2011;Suppl 1:S127–S130. doi:10.5021/ad.2011.23.S1.S127
22. Leuci S, Martina S, Adamo D, et al. Oral syphilis: a retrospective analysis of 12 cases and a review of the literature. *Oral Dis*. 2013;19(8):738–746. doi:10.1111/odi.12058
23. Sandhu R, Mareddy C, Itskowitz M, et al. Mycoplasma-induced rash and mucositis in a young patient with red eyes, oral mucositis, and targetoid cutaneous vesicles. *Lancet Infect Dis*. 2017;17(5):562. doi:10.1016/S1473-3099(17)30242-6

## Infection and Drug Resistance

Dovepress

### Publish your work in this journal

Infection and Drug Resistance is an international, peer-reviewed open-access journal that focuses on the optimal treatment of infection (bacterial, fungal and viral) and the development and institution of preventive strategies to minimize the development and spread of resistance. The journal is specifically concerned with the epidemiology of

antibiotic resistance and the mechanisms of resistance development and diffusion in both hospitals and the community. The manuscript management system is completely online and includes a very quick and fair peer-review system, which is all easy to use. Visit <http://www.dovepress.com/testimonials.php> to read real quotes from published authors.

Submit your manuscript here: <https://www.dovepress.com/infection-and-drug-resistance-journal>