

RETRACTED ARTICLE: Long term chemoradiotherapy-related dental and skeletal complications in a young female with nasopharyngeal carcinoma

Ioulia Ioannidou-Marathiotou¹
Kyriaki Pistevou-Gompaki²
Nikolaos Eleftheriadis³
Christos Papaloukas⁴

¹Department of Orthodontics, School of Dentistry, Aristotle University of Thessaloniki, ²Department of Radiation Oncology, AHEPA University Hospital, Aristotle University of Thessaloniki,

³Propaedeutic Department of Internal Medicine, AHEPA University Hospital, Aristotle University of Thessaloniki,

⁴Department of Radiation Oncology, AHEPA University Hospital, Aristotle University of Thessaloniki, Thessaloniki, Greece

Abstract: We describe the long-term complications 20 years after chemoradiotherapy in a 20-year old woman with nasopharyngeal carcinoma. We wanted to know whether the radiation dose was constant throughout the oral cavity, and thus uniformly affecting the corresponding dental and skeletal structures. Clinical and radiologic findings are described 20 years after chemoradiotherapy based on a two-dimensional computerized treatment planning system. This revealed radiation caries limited only to posterior teeth, proximal caries in the anterior teeth, limited but continuous salivary flow, mild periodontal infection, mild xerostomia, and a regenerative capacity of bones and the developmental process. The quantitative assessment of radiation delivered to the mandible revealed a high radiation dose in the posterior area and minimal dose in the anterior area. This explains the differences in caries manifestation between the anterior and posterior teeth. According to the present study, individualized radiation fields, using a two-dimensional treatment planning system, result in restriction of severe damage to dental and skeletal structures, which usually follows chemoradiotherapy. Orthodontic treatment could be initiated according to individual patient needs.

Keywords: nasopharyngeal carcinoma, adolescence, radiotherapy, dental and skeletal complications

Introduction

Nasopharyngeal carcinoma (NPC) is rarely reported in children¹⁻³ and is more often of the differentiated type. Combined chemoradiotherapy is the treatment of choice for this malignancy, and has shown promising results.³⁻⁵ Overall survival rates of 50%–77% are reported.²⁻⁴ However, the high radiation doses needed to provide effective treatment have resulted in long-term toxicity, with hard and soft tissue growth complications, particularly in young children who are still growing.⁴⁻⁵ Maxillofacial and dental abnormalities are well-known long-term chemoradiotherapy-related complications in children with head and neck cancer.⁶⁻¹¹ Severity of the developmental disturbances are related to the patient's age at the time of treatment. The younger the child, the more severe the abnormalities, especially in those under six years.⁷ Another factor influencing the severity of developmental disturbances is the radiation dose, with doses between 10 to 30 Gy leading to significant bone growth disturbance and arrested tooth development.¹² According to Guyuron et al¹³ 30 Gy can be considered to be a harmful dosage for the development of the maxillofacial bones, and 4 Gy harmful to development of the soft tissues. Xerostomia, oral mucositis, and late visual and auditory toxicity have also been reported as frequent and potentially severe complications of radiotherapy.^{14,15} Although treatment-related skeletal and dental complications from a range of malignancies have been often reported in children, there are few published

Correspondence: Ioulia Ioannidou-Marathiotou
Department of Orthodontics, School of Dentistry, Aristotle University of Thessaloniki, GR-54124, Thessaloniki, Greece
Tel +30 231 099 9483
Fax +30 231 099 9549
Email ioannidou@dent.auth.gr

studies concerning those with NPC in children.^{2,16} In addition, oral health after NPC treatment was reported by Schwarz et al¹⁷ but not for children.

We report here on a 20-year-old woman with dental and maxillofacial skeletal complications six years after chemoradiotherapy for NPC. The rarity of NPC in children and the absence of clear data regarding the safety of the radiation dose delivered to the oral area makes this study of interest to all dentists and orthodontists involved in improving quality of life for these young patients.

Materials and methods

A 20-year-old woman was referred by Radiation Oncology to our Orthodontics Department for dental assessment and subsequent orthodontic consultation and treatment. She had a known six-year history of histologically diagnosed NPC, (Type II according to WHO criteria, cT3cN3M0, Grade I. She had been treated with chemoradiotherapy comprising concurrent cisplatin (100 mg/m² on days 1, 22, and 43) chemoradiotherapy, followed by three cycles of adjuvant chemotherapy consisting of cisplatin 80 mg/m² and 5-fluorouracil 500 mg/m² at 28-day intervals.¹⁸ She did not receive any nonchemotherapeutic agents.

The radiotherapy plan was conducted using a two-dimensional computerized treatment planning system (Telemaque Technos, Technologies-Informatique S.A., Trappes). The primary site and bilateral upper neck received 60 Gy in 33 fractions over 6.5 weeks and the lower neck and supraclavicular fossae received 40 Gy in 22 fractions over 4.5 weeks. A two-phase technique was used.

Following conventional simulation and using a Cobalt-60 gamma ray unit, radiotherapy was initially delivered by large parallel-opposed lateral fields to a dose of 36 Gy given over four weeks at 180 cGy per day. The treatment field extended superiorly to the inferior orbital margin, inferiorly to the C6 spinous process, anteriorly to the anterior border of the masseter muscle, and posteriorly to the T2 spinous process, encompassing the macroscopic disease, including that in the spinal cord. To target undetectable microscopic disease, the clinical volume included the base of the skull, posterior half of the nasal cavity, nasopharynx, sphenoid base, parapharyngeal space, and lateral pharyngeal, and posterior and upper deep cervical nodes. The brainstem, optic chiasm, and anterior half of the orbit were shielded. During the second phase of treatment, the parallel-opposed lateral fields were reduced posteriorly to exclude the spinal cord, and a further dose of 24 Gy was given over 2.5 weeks, at 180 cGy per day, achieving a total dose of 60 Gy in 33 fractions.

In order to assess the delivered radiation dose on dental and skeletal structures in the present study, we used the central slice of the magnetic resonance imaging (MRI), including the mandibular teeth (Figure 1). The total radiation dose delivered was evaluated for the large parallel-opposed lateral field (Phase 1, Figure 2A) and for the reduced parallel-opposed lateral field (Phase 2, Figure 2B) in different levels representing mandibular tooth groups. Thus, the internal volume 1 (A) represents the central incisors, internal volume 2 (C) the canines, internal volume 3 (E) the second premolars, internal volume 4 (F) the first molars, internal volume 5 (G) the second molars, and internal volume 6 (H) the third molars. The isodose calculation was conducted by the two-dimensional planning system for a 11 × 15 cm and a 7 × 7 cm 1.25 MV photon beam for Phase 1 and Phase 2 lateral fields, respectively. The isodose curves in Figure 3, which are the lines with the different colors, corresponded to different percentages of the total dose delivered during both phases of radiotherapy.

Results

Radiation dose, as a percentage of the total dose, and total irradiation delivered are shown in Table 1. According to the isodose calculation, it appears that the delivered doses decreased from level 6, the nearest to the radiation field, to level 1, the most deviated. In summary, during Phase 1, the delivered dose at level 1 was 0% and at level 6 was 97%; for Phase 2, at level 1 the dose was 0% and at level 6 was 98%.

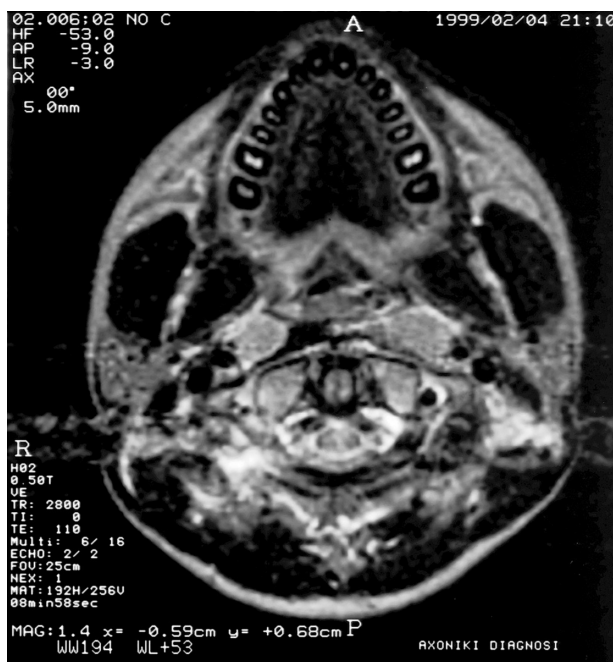

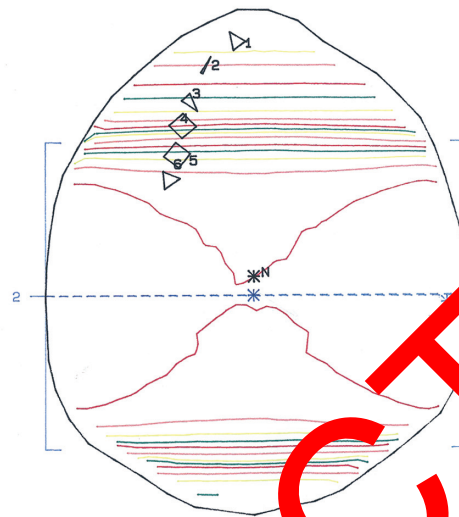
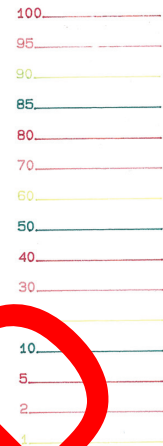
Figure 1 Central slice of magnetic resonance imaging of the mandibular teeth.

A NAME : S.E. FILE # : DATE : 5/16/98 DR PISTEVOU

INTERNAL VOLUME 1 : A
 INTERNAL VOLUME 2 : C
 INTERNAL VOLUME 3 : E
 INTERNAL VOLUME 4 : F
 INTERNAL VOLUME 5 : G
 INTERNAL VOLUME 6 : H

| FIELD | TR. UNIT | WIDTH IN CM | LENGTH IN CM | SAD IN CM | WEIGHT | FILTER |
|-------|----------|-------------|--------------|-----------|--------|--------|
| 1 | ALCYON | 11 | 15 | 80 | 1 | |
| 2 | ALCYON | 11 | 15 | 80 | 1 | |

NORMALISATION AT POINT *N*
 WEIGHING IN DEPTH



PRINCIPAL PLANE
 OUTPUT SCALE : 1

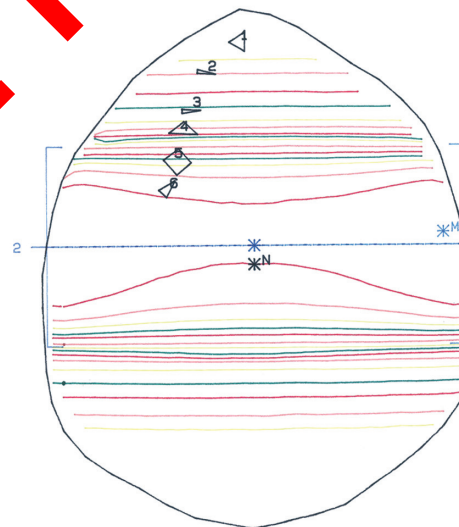
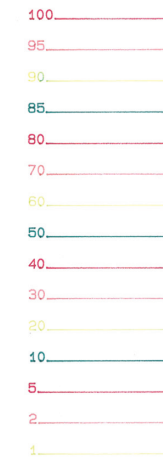
AXEPA GENERAL HOSPITAL

B NAME : S.E. FILE # : DATE : 5/16/98 DR PISTEVOU

INTERNAL VOLUME 1 : A
 INTERNAL VOLUME 2 : C
 INTERNAL VOLUME 3 : E
 INTERNAL VOLUME 4 : F
 INTERNAL VOLUME 5 : G
 INTERNAL VOLUME 6 : H

| FIELD | TR. UNIT | WIDTH IN CM | LENGTH IN CM | SAD IN CM | WEIGHT | FILTER |
|-------|----------|-------------|--------------|-----------|--------|--------|
| 1 | ALCYON | 7 | 15 | 80 | 1 | |
| 2 | ALCYON | 7 | 15 | 80 | 1 | |

NORMALISATION AT POINT *N*
 WEIGHING IN DEPTH



PRINCIPAL PLANE
 OUTPUT SCALE : 1

AXEPA GENERAL HOSPITAL

Figure 2 The two-dimensional planning system for isodose calculation for the large (A) and the reduced (B) parallel-opposed lateral fields and color curves showing the differences in radiation dose between posterior and anterior teeth during the two phases of radiotherapy.

In total, the incisors received 0 Gy and the third molars received 58.44 Gy (Table 1).

The lower deep cervical and supraclavicular fossae lymph nodes were treated with a direct anterior photon field because of the position of the shoulders to a dose of 40 Gy in 22 fractions given over 4.5 weeks. A half-beam blocking technique was used along the superior margin of the anterior field to reduce divergence, central shielding to protect the spinal cord and larynx, and bilateral shielding to protect apical parts of both lungs.

Focusing on the anatomic structures of the jaw and oral cavity, the irradiated area at the midplane included the major salivary glands, mucosal surface, posterior part of the maxilla and of the body of the mandible to the anterior border of the masseter muscle, and the ramus of the mandible along with the coronoid process and the condyle. These structures received 50% of the prescribed dose at the lateral field margins, 95%–104% at the center of the fields, and less than 50% at the anterior part of the jaw.

In order to manage the expected xerostomia, the patient was advised to take frequent sips of water and maintain an adequate daily fluid intake. Sugar-free gums were used to stimulate saliva flow, and scrupulous oral hygiene was recommended. Moreover, amifostine, the most comprehensively tested radioprotective agent, was utilized to prevent primarily radiation-induced xerostomia and mucositis, providing protection for the salivary glands,¹⁹ as well as preventing cisplatin-induced neurotoxicity, ototoxicity, and renal toxicity.

The size of the malignancy before and after treatment was estimated by MRI (Figures 3A, B, and C). A complete response, both of the primary tumor and the regional lymph nodes, was achieved one month after the end of treatment (Figures 3D, E, and F).

Toxicity was evaluated according to WHO criteria during and after treatment. Toxicity from chemotherapy was predominantly Grade 1 nausea/vomiting and Grade 1 hematologic

toxicity. The acute toxicity of radiotherapy consisted of Grade 2 mucositis and a Grade 2 skin reaction. Late complications of radiotherapy were mainly Grade 2 xerostomia and fibrosis in the soft tissues of the neck (Figure 4). Five years after radiotherapy, the complications were edema of the eye lids requiring reconstructive surgery and hypothyroidism treated with thyroxine at a maintenance dose of 0.05 mg/day orally, respectively.

Follow-up was scheduled every three months for the first two years, every six months for the next two years, and annually thereafter. The patient remained disease-free six years post-chemoradiotherapy, and extraoral examination showed no apparent signs of deformity. Facial examination showed no asymmetry in the frontal view (Figure 5A) and the soft tissue profile was acceptable (Figure 5B). Oral examination revealed that the patient had Class II, Division 1 malocclusion in her permanent dentition. Left first molars and left and right canines showed a Class II tooth relationship, while the right first molars showed a Class III tooth relationship. The overjet was 7 mm, and the overbite 5 mm (Figures 6A, B, and C).

The maxilla was narrow anteriorly, maxillary anterior teeth were crowded, and the mandibular dental arch had spaces distal to the canines. Left maxillary and right and first left mandibular molars, as well as lower the right and third left molars, were extracted (Figures 6D and E). Multiple caries lesions were found in almost all teeth, but the lesions of the canines, premolars, and molars were more significant. Maxillary and mandibular posterior teeth showed Class I caries and enamel decalcification, while the anterior teeth showed proximal, distal, and mesial caries. No cervical caries on the anterior or posterior teeth was evident. The patient's oral hygiene was poor, with plaque accumulation, severe localized inflammatory gingivitis, and gingival hyperplasia (Figure 6).

Comparison of two panoramic radiographs at the end of chemoradiotherapy (Figure 7A) and six years later (Figure 7B) revealed that the third mandibular molars

Table 1 Isodose distribution for the large (A), and the reduced (B) parallel-opposed lateral fields with the different percentages of the total dose delivered to the mandibular teeth

| Teeth large parallel-opposed I | Lateral field (Phase 1) (total dose 36 Gy,%) | Reduced parallel-opposed lateral field (Phase 2) (total dose 24 Gy,%) | Total (Gy) |
|--------------------------------|----------------------------------------------|-----------------------------------------------------------------------|------------|
| Central incisor (A) | 0 | 0 | 0.0 |
| Lateral incisor | 1 | 1 | 0.6 |
| Canine (C) | 2 | 2 | 1.2 |
| First premolar | 5 | 5 | 3.0 |
| Second premolar (E) | 15 | 15 | 9.0 |
| First molar (F) | 45 | 30 | 23.4 |
| Second molar (G) | 85 | 85 | 51.0 |
| Third molar (H) | 97 | 98 | 58.4 |

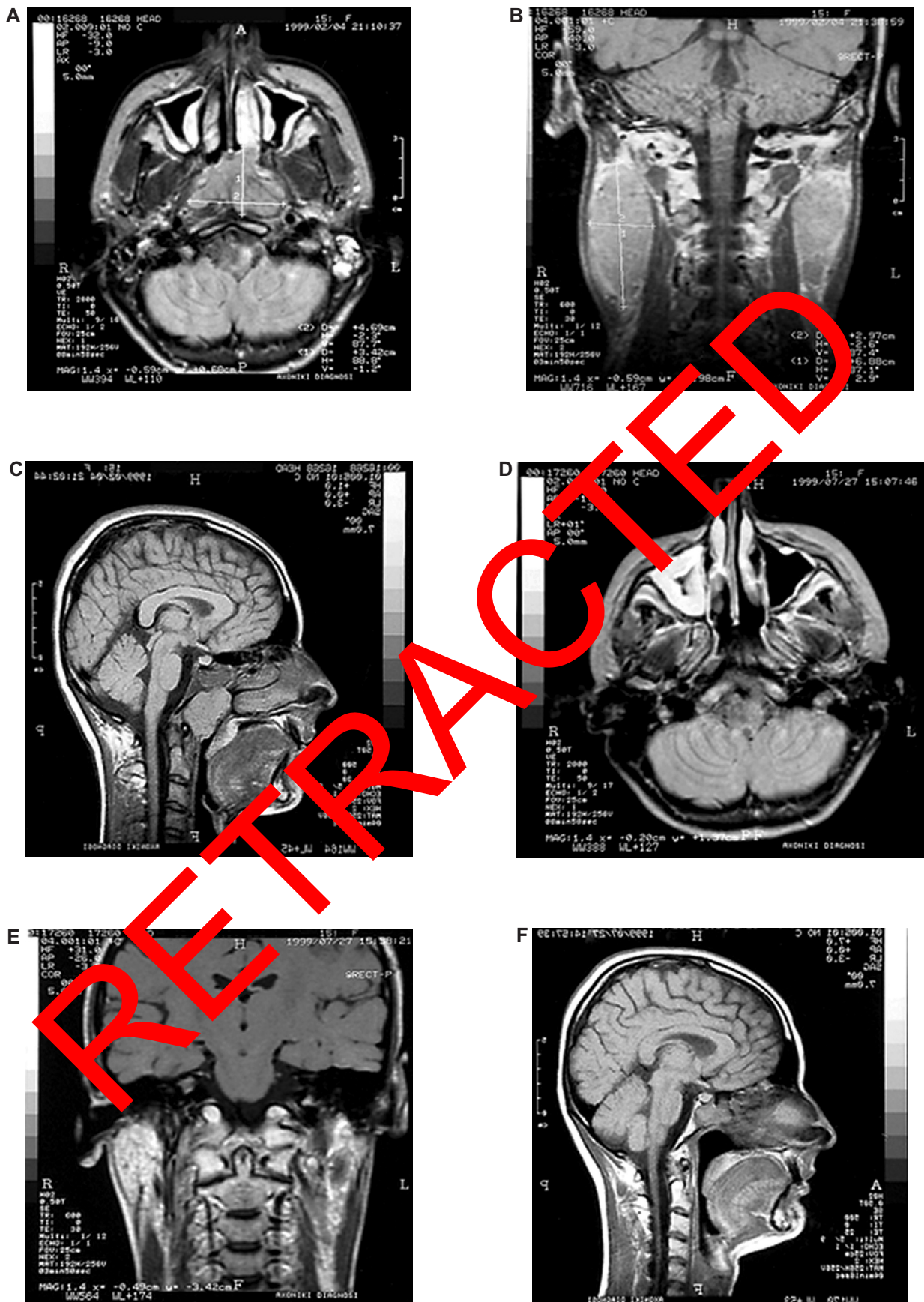

Figure 3 Magnetic resonance imaging showing the size of the malignancy before treatment with chemoradiotherapy (A, B, C), and the response after treatment (D, E, F).

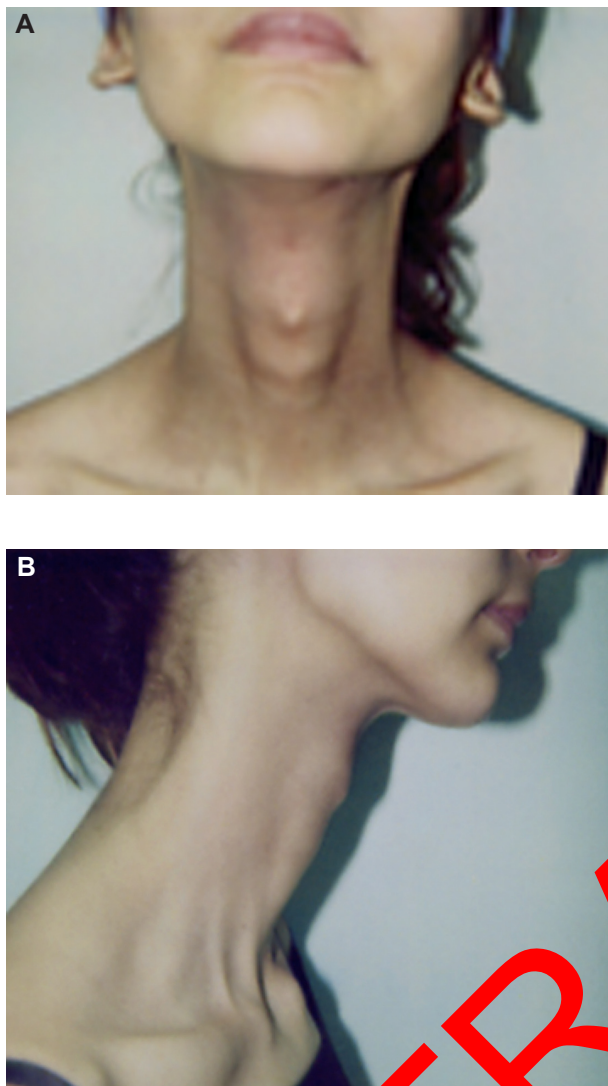


Figure 4 Soft tissue fibrosis of the neck (frontal (A) and lateral (B) views immediately after treatment with chemoradiotherapy.

were presented initially. They were, however, extracted after chemoradiotherapy prior to the start of six-year follow-up. The extraction spaces of the left maxillary and right and left mandibular first molars were not totally closed initially (Figure 7A). During the six years of follow-up, the corresponding first molars were moved forward to close the remaining spaces, but with significant mesial inclination (left maxillary and right mandibular first molar) accompanied by periodontal pockets located at the mesial aspect of their mesial roots (Figure 7B). Six years after chemoradiotherapy, the right and left third maxillary molars showed good positioning in the dental arch, the pulp chamber was formed and the apex was fully closed, although the later was not evident immediately after chemoradiotherapy.



Figure 5 Extraoral photographs (A, frontal view; B, lateral view) of the patient six years after chemoradiotherapy, showing no alterations of facial proportions and symmetry.

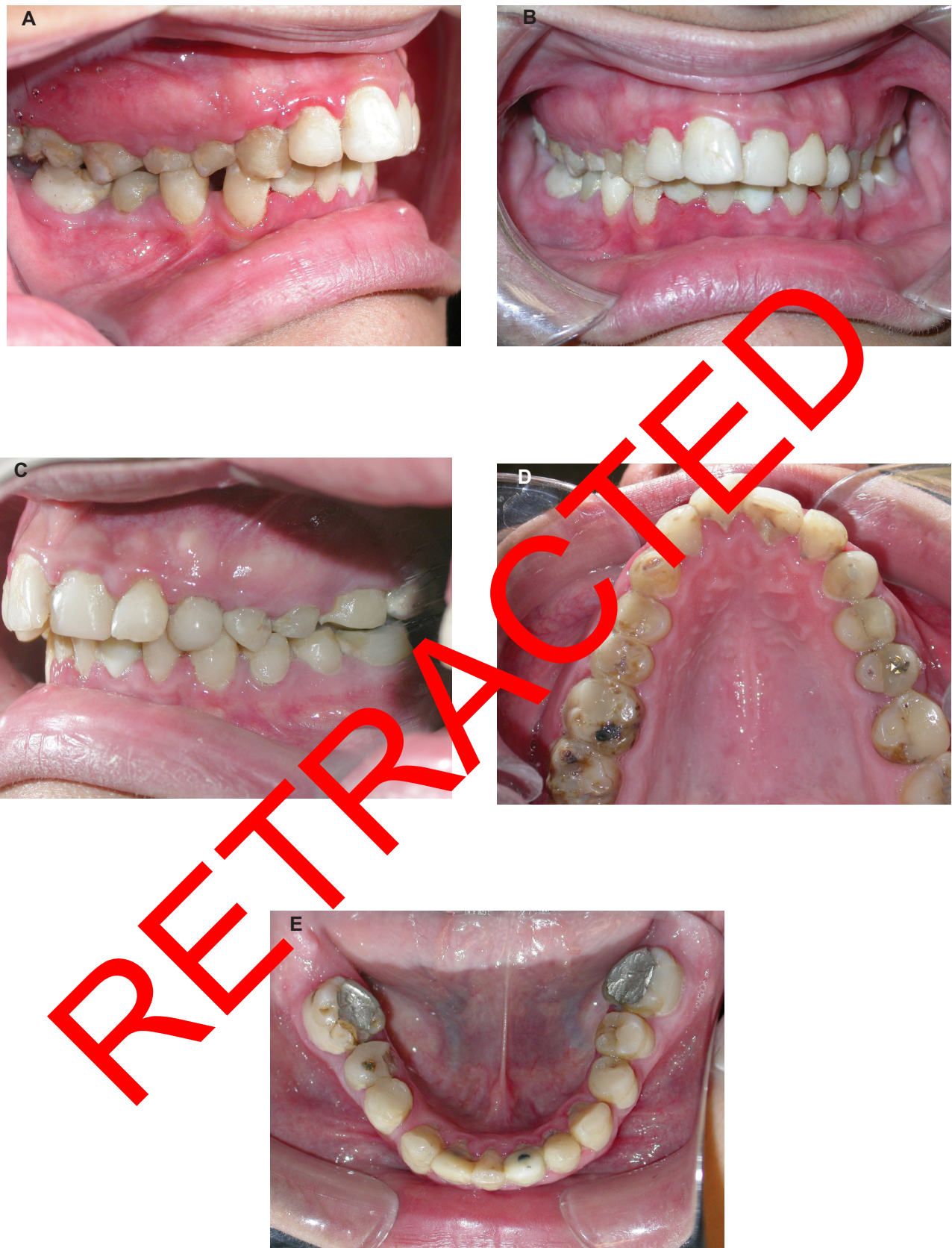

Figure 6 Intraoral photographs of the patient six years after chemoradiotherapy showing occlusal relationships, radiation caries in posterior teeth, proximal caries in anterior teeth, inflammatory gingivitis, and gingival hyperplasia (A, right view; B, frontal view; C, left view; D, maxillary dental arch; E, mandibular dental arch).

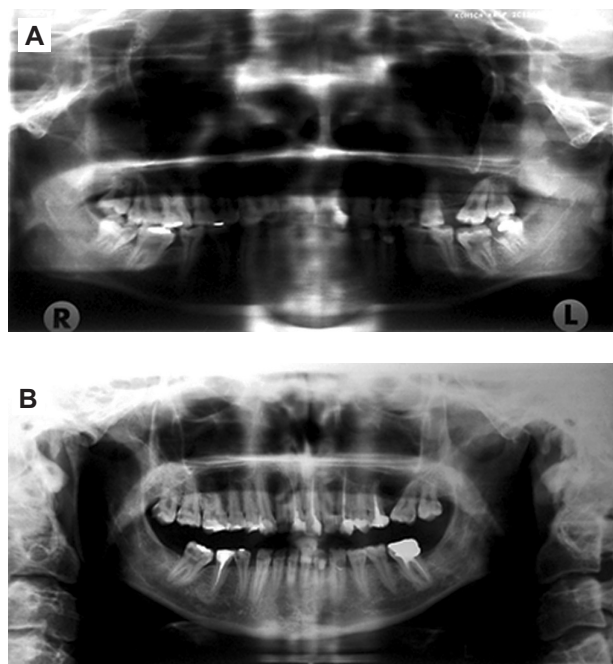


Figure 7 Panoramic radiographs immediately after chemoradiotherapy (A), and six years later (B).

It was also observed that, during the same follow-up period, six endodontic treatments were performed in a total of 27 preserved teeth. Bone density and mandible body volume did not seem to differ from the non-irradiated bones. In addition, no apparent signs of radionecrosis were evident. Furthermore, following extraction of the third molar after chemoradiotherapy, normal bone healing was observed at the corresponding extraction sites (Figure 7B).

Cephalometric analysis revealed maxillary protrusion in relation to the anterior skull base, mandibular retrusion, a dolichofacial growth pattern, normal lower facial height, normal mandibular length and anterior rotation of the mandible. Lower incisors were positioned at a normal distance to the A-Point plane, but with lingual inclination. The lower lip was found in a posterior position in relation to the esthetic line, and the nose seemed pronounced (Figure 8, Table 2).

Discussion

Chemoradiotherapy has improved the cure rates for childhood head and neck malignancies. Concomitant chemotherapy enhances the effects of radiotherapy, resulting in improved outcome in NPC, but with a significant increase in acute toxicity, especially mucositis, due to the use of cisplatin as a radiosensitizer.²⁰

Direct and indirect long-term radiation effects on developing organs have been reported in long-term survivors.^{11,17,21} The

effects of chemotherapy appear to be similar to those reported for irradiation, although generally milder.²⁰

In our patient, long-term chemoradiotherapy-related effects on dental development were compared only in the limited area of posterior teeth, because the first panoramic radiograph was of poor quality, 9,5 of as high as 60 Gy, did not significantly affect completion of their root formation.

Another interesting observation was the deterioration of enamel structure and development of caries lesions. Caries development in patients treated for cancer is attributed to post-radiation xerostomia and its duration.²²⁻²⁵ In the present patient, radiation caries was present mainly in the posterior maxillary and mandibular teeth. Minor caries was observed on the anterior teeth of both dental arches, located mainly in their proximal, mesial and distal aspects. Cervical caries indicative of xerostomia, usually manifested as an indirect effect post-irradiation, was not evident. This difference in caries manifestation between the anterior and posterior teeth can be attributed to the difference in the radiation dose received by different tooth groups, achieved by the two-dimensional planning system. Consequently, although caries of the posterior teeth can be attributed to radiation, the corresponding caries lesions in the anterior teeth are not related to radiation-xerostomia effects for two main reasons, namely, the high radiation dose was limited in the posterior teeth, mainly on the second and third molars, and the submandibular and sublingual salivary glands were out of the radiation field and therefore were not affected by radiation, thus obtaining restricted but continuous saliva flow. It is probable that the caries present six years after chemoradiotherapy in our patient was due to poor oral hygiene.

No major skeletal problems attributable to radiotherapy were found in our patient. On the contrary, a more significant degree of aberrant skeletal effects has been expected because the patient received 60 Gy on the upper neck and 40 Gy on the lower neck, and bone growth damage has been reported to occur at doses of 10 to 30 Gy,¹² and micrognathia at doses of 35 Gy.²⁶ The lack of major skeletal effects is probably due to the age of this patient at time of irradiation (14 years) when maxillary growth was almost complete and only residual mandible growth potential remained, probably leading to development of the mandibular retrusion observed six years after chemoradiotherapy. However, the patient's normal mandible sagittal linear value, symphysis morphology, and pogonion prominence six years after treatment, indicates that some compensation had occurred and that a developmental effect existed post-irradiation.

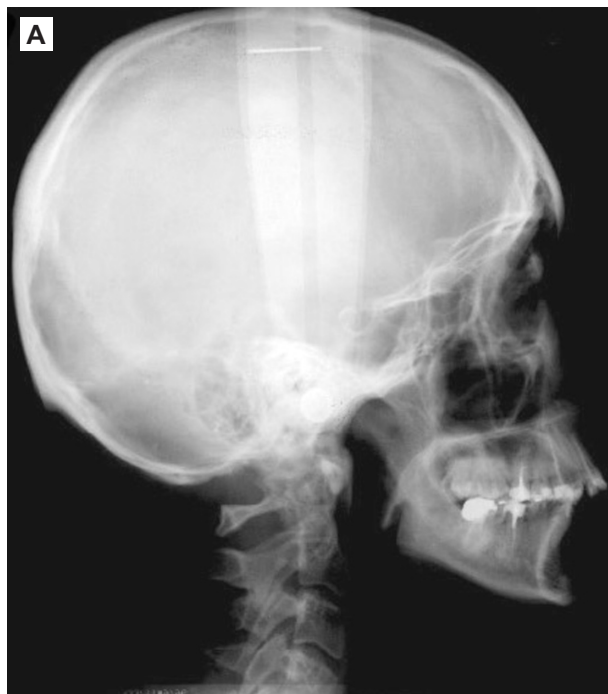


Figure 8 Cephalometric radiograph (A) and tracing (B) of the patient six years after chemoradiotherapy.

Moreover, it seems that the present dental and skeletal relationships in our patient are more the result of evolution of a pre-existing malocclusion than the effect of chemoradiotherapy.

Finally, at the present time, mandible bone density and volume in this patient do not seem to be adversely affected, osteoradionecrosis is not apparent, and bone regenerative capacity had been preserved after third molar extraction post-chemoradiotherapy.

Use of individualized radiation fields by means of a two-dimensional computerized treatment planning system in our

Table 2 Cephalometric analysis according to Ricketts et al²² six years after chemoradiotherapy

| Skeletal relationships | Mean (SD) | Patient values |
|------------------------------------|-----------|----------------|
| Facial axis | 90° ± 3 | 85° |
| Facial angle | 87° ± 3 | 88° |
| Mandibular plane | 26° ± 4 | 25° |
| Lower face height | 47° ± 4 | 45° |
| Mandibular arc | 26° ± 4 | 32° |
| Mandibular corpus length | 66 ± 3 mm | 69 mm |
| Convexity of point A | 2 ± 2 mm | 6 mm |
| Dental relationships | | |
| Lower incisor to A-Pog | 1 ± 3 mm | 0.5 mm |
| Lower incisor inclination to A-Pog | 7° ± 4 | 16° |
| Upper molar to PTV | 1 ± 3 mm | 16 mm |
| Soft tissue relationships | | |
| Lower lip to E-plane | 2 ± 2 mm | 6 mm |

Abbreviation: SD, standard deviation

patient limit the severe damage to maxillofacial, dental, and skeletal structures that usually follows chemoradiotherapy. Teeth and bones were mildly affected, but with an appropriate long-term follow-up program for oral hygiene and an oral care protocol,²⁷ orthodontic treatment could be initiated according to the needs of individual patients.

Disclosure

The authors report no conflict of interest in this work.

References

- Pao WJ, Hustu HO, Douglas EC, Beckford NS, Kun LE. Pediatric nasopharyngeal carcinoma: Long term follow up of 29 patients. *Int J Radiat Oncol Biol Phys*. 1989;17:299–305.
- Uzel Ö, Yörük SÖ, Şahinler I, Turkan S, Okkan S. Nasopharyngeal carcinoma in childhood: Long term results of 32 patients. *Radiation Oncol*. 2001;58:137–141.
- Orbach D, Brisse H, Helfre S, et al. Radiation and chemotherapy combination for nasopharyngeal carcinoma in children: Radiotherapy dose adaptation after chemotherapy response to minimize late effects. *Pediatr Blood Cancer*. 2008;50:849–853.
- Carvalho AL, Nishimoto IN, Califano JA, Kowalski LP. Trends in incidence and prognosis for head and neck cancer in the United States: A site-specific analysis of the SEER database. *Int J Cancer*. 2005;114:806–816.
- Rodriguez-Galindo C, Wofford M, Castleberry RP, et al. Preradiation chemotherapy with methotrexate, cisplatin, 5-fluorouracil, and leucovorin for pediatric nasopharyngeal carcinoma. *Cancer*. 2005;103:850–857.
- Murai T. Case report of radiation injury of teeth and jaws. *Am J Orthod*. 1955;41:802–803.
- Dahlöf G. Craniofacial growth in children treated for malignant disease. *Acta Odontol Scand*. 1998;56:378–382.
- Jaffe N, Toth BB, Hoar RB, Ried HL, Sullivan MP, McNeese MD. Dental and maxillofacial abnormalities in long term survivors of childhood cancer: Effects of treatment with chemotherapy and radiation to the head and neck. *Pediatrics*. 1984;73:816–823.
- Takinami S, Kaga M, Yahata H, Kure A, Oguchi H, Yasuda M. Radiation-induced hypoplasia of the teeth and mandible. A case report. *Oral Surg Oral Med Oral Pathol*. 1994;78:382–384.

10. Kaste SC, Hopkins KP, Bowman LC. Dental abnormalities in long term survivors of head and neck rhabdomyosarcoma. *Med Pediatr Oncol.* 1995;25:96–101.
11. Näsman M, Forsberg C, Dahllöf G. Long term dental development in children after treatment for malignant disease. *Eur J Orthod.* 1997;19:151–159.
12. Carpenter JS. Dental care for children who have received head and neck therapeutic radiation. *J Pedod.* 1978;3:36–51.
13. Guyuron B, Dagsy AP, Munro IR, Ross RB. Effect of irradiation on facial growth: A 7- to 25-year follow-up. *Ann Plast Surg.* 1983;11:423–427.
14. Sonis ST, Elting LS, Keefe D, et al. Perspectives on cancer therapy-induced mucosal injury: Pathogenesis, measurement, epidemiology, and consequences for patients. *Cancer.* 2004;100:1995–2025.
15. Rosenblatt E, Brook OR, Erlich N, Miller B, Joachims HZ, Kuten A. Late visual and auditory toxicity of radiotherapy for nasopharyngeal carcinoma. *Tumori.* 2003;89:68–74.
16. Mertens R, Granzon B, Lassay L, et al. Treatment of nasopharyngeal carcinoma in children and adolescents. Definitive results of a multicenter study (NPC-91-GPOH). *Cancer.* 2005;104:1083–1089.
17. Schwarz E, Chiu G, Keung Leung W. Oral health status of southern Chinese following head and neck irradiation therapy for nasopharyngeal carcinoma. *J Dent.* 1999;27:21–28.
18. Al-Sarraf M, LeBlanc M, Giri PG, et al. Chemoradiotherapy versus radiotherapy in patients with advanced nasopharyngeal cancer: Phase III randomized Intergroup study 0099. *J Clin Oncol.* 1998;16:1310–1317.
19. Brizel DM, Wasserman TH, Henke M, et al. Phase III randomized trial of amifostine as a radioprotector in head and neck cancer. *J Clin Oncol.* 2000;18:4110–4111.
20. Pignon JP, Bourhis J, Domenge C, Designé L. Chemotherapy added to locoregional treatment for head and neck squamous-cell carcinoma: Three meta-analyses of updated individual data. MACH-NC Collaborative Group. *Lancet.* 2000;355:949–955.
21. Möller P, Perrier M. Dento-maxillofacial sequelae in a child treated for a rhabdomyosarcoma in the head and neck. A case report. *Oral Surg Oral Med Oral Path Oral Radiol Endod.* 1998;86:297–303.
22. Ricketts RM, Bench RW, Hilgers JJ, Schulhof R. An overview of computerized cephalometrics. *Am J Orthod.* 1972;61:1–28.
23. Knox JJ, Puodziunas AL, Feld R. Chemotherapy-induced oral mucositis. Prevention and management. *Drugs Aging.* 2000;17:257–267.
24. Marunick MT. The oral effects of radiation therapy. In: Robbins K, Murry T, editors. *Head and Neck Cancer*. San Diego, CA: Singular Publishing Group; 1998.
25. Marunick MT, Seyedsadr M, Ahmad M, Klein B. The effect of head and neck cancer treatment on whole salivary flow. *J Surg Oncol.* 1991;48:81–86.
26. Kaste SC, Hopkins KP. Mandibular growth retardation after radiation therapy for childhood facial tumors. Report of 20 cases with long term follow-up. *Oral Surg Oral Med Oral Pathol.* 1994;77:92–99.
27. Hogan R. Implementation of a dental care protocol and its effects on oral mucositis. *Med Pediatr Oncol.* 2009;26:125–135.

RETRACTED

International Journal of General Medicine

Publish your work in this journal

The International Journal of General Medicine is an international, peer-reviewed open-access journal that focuses on general and internal medicine, pathogenesis, epidemiology, diagnosis, monitoring and treatment protocols. The journal is characterized by the rapid reporting of reviews, original research and clinical studies across all disease areas.

Submit your manuscript here: <http://www.dovepress.com/international-journal-of-general-medicine-journal>

Dovepress

A key focus is the elucidation of disease processes and management protocols resulting in improved outcomes for the patient. The manuscript management system is completely online and includes a very quick and fair peer-review system. Visit <http://www.dovepress.com/testimonials.php> to read real quotes from published authors.