

# The advantages of femtosecond laser-assisted cataract surgery for zonulopathy

This article was published in the following Dove Press journal:  
*International Medical Case Reports Journal*

Takeshi Teshigawara<sup>1-3</sup>  
Akira Meguro<sup>3</sup>  
Sanae Sanjo<sup>1</sup>  
Seiichiro Hata<sup>4</sup>  
Nobuhisa Mizuki<sup>3</sup>

<sup>1</sup>Department of Ophthalmology, Yokosuka Chuoh Eye Clinic, Yokosuka, Kanagawa, Japan; <sup>2</sup>Department of Ophthalmology, Tsurumi Chuoh Eye Clinic, Yokohama, Kanagawa, Japan; <sup>3</sup>Department of Ophthalmology, Yokohama City University School of Medicine, Yokohama, Kanagawa, Japan; <sup>4</sup>Department of Ophthalmology, Yokohama Sky Eye Clinic, Yokohama, Kanagawa, Japan

**Abstract:** Zonulopathy is a major concern if found during cataract surgery as it can cause further complications. Such complications may occur during continuous curvilinear capsulorhexis (CCC), lens fragmentation and intraocular lens (IOL) implantation. Femtosecond laser-assisted cataract surgery (FLACS) devices, such as the LenSx (Alcon Laboratories) are advantageous because they can detect the area and largest point of zonulopathy via anterior segment optical coherent tomography (AS-OCT) before the manual part of the procedure. CCC and lens fragmentation can also minimize further zonular stress. A symmetrical CCC is ideal for IOL implantation in the sulcus with optic capture. In the present study, we did not detect significant zonular dehiscence preoperatively in either of the eyes of our 68-year-old patient when using AS-OCT (CASIA2 Tomey). However, LenSx AS-OCT revealed zonular dehiscence in both eyes, perioperatively. We created CCC and lens fragmentation without causing stress to the zonules. In the subsequent manual part of procedure, we found zonular dehiscence in the same area as indicated by LenSx AS-OCT, which extended to approximately 200° in the right eye and 180° in the left. After lens fragmentation by LenSx, we successfully removed the lens without further zonular dialysis. However, zonular dialysis (>180°) in the right eye was too large to insert an IOL, either in the capsule or the sulcus. Therefore, we performed scleral IOL implantation. In the left eye, we avoided using capsular tension ring (CTR) for IOL placement to avoid further iatrogenic damage to the zonule. Instead, an IOL was inserted into the sulcus with optic capture to reduce the possibility of further stress to the zonula and phimosis. Post-surgically, the patient regained good eyesight in both eyes. This case illustrates the advantages of FLACS in addressing zonulopathy. The consistent creation of CCC and lens fragmentation by FLACS may increase success rates, even in unexpectedly challenging cases.

**Keywords:** femtosecond laser-assisted cataract surgery, phacodonesis, zonular dialysis, optic capture, anterior segment optical coherent tomography

## Introduction

Zonulopathy is a condition characterized by a lack of zonular support for the lens capsule due to zonular weakness or dialysis. This condition may encompass subluxation or dislocation of the lens. The etiology of zonulopathy includes congenital conditions such as Marfan syndrome, homocystinuria, Ehlers–Danlos syndrome and retinitis pigmentosa.<sup>1,2</sup> Zonular weakness or dialysis may also be caused by external trauma and pseudoexfoliation syndrome (PXF).

Regardless of its cause, zonulopathy can make procedures, such as the creation of continuous curvilinear capsulorhexis (CCC), lens fragmentation and intraocular lens

Correspondence: Takeshi Teshigawara  
Department of Ophthalmology, Yokosuka  
Chuoh Eye Clinic, 2-6 Odaki-cho,  
Yokosuka, Kanagawa 238-0008, Japan  
Tel +81 46 827 4001  
Fax +81 46 827 4141  
Email teshitake@gmail.com

(IOL) insertion more challenging. The preoperative detection of zonulopathy is essential to enable surgeons to plan a reasonable surgical strategy. However, currently available preoperative procedures, such as slit lamp examination, anterior segment optical coherent tomography (AS-OCT) and ultrasound biomicroscopy (UBM) all have diagnostic limitations. Indeed, the underlying zonular weakness or dialysis is often not detected until the beginning of surgery. Thus, the creation of CCC, lens fragmentation and IOL insertion are the most crucial aspects of a cataract operation. Nonetheless, these procedures can also lead to further zonular damage.<sup>3</sup> A capsular tension ring (CTR) is a useful device which can prevent further ectopia lentis.<sup>4</sup> However, previous research has indicated that the stress of CTR insertion may cause further dialysis.<sup>5</sup>

Recent advances in the field have shown that a femtosecond laser-assisted surgery (FLACS) device, such as the LenSx (Alcon Laboratories, Fort Worth, TX, USA), may confer significant advantages in addressing these issues. LenSx features two types of AS-OCT: a circle scan and a line scan. The circle scan images the entire eye unrolled in 360° (Figure 1A) and has the ability to capture the existence and area of zonular weakness or dialysis. In contrast, the line scan displays cross-sectional views of the eye, which can show the largest point of zonular weakness or dialysis (Figure 1B). These scans provide more detailed information relating to lens orientation.<sup>6</sup> Furthermore, FLACS can create CCC and lens fragmentation with minimal stress to the zonule.<sup>7</sup> A perfectly sized and shaped CCC by FLACS ensures IOL placement in the sulcus with optic

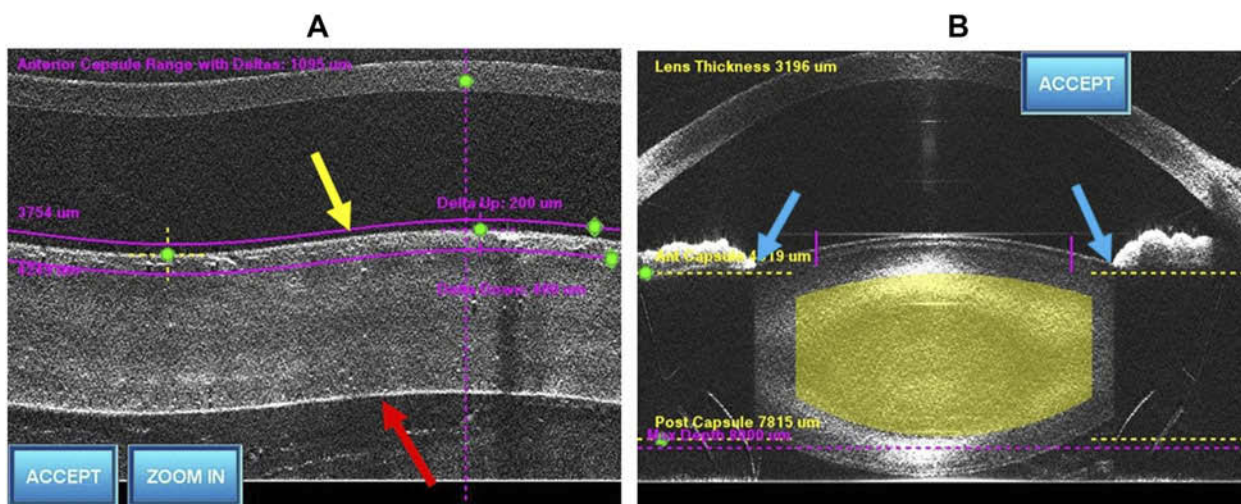
capture, which results in less IOL tilt and decentration, as compared to manual CCC.<sup>8</sup>

This case study demonstrates the advantages of FLACS for cataract surgery with zonulopathy.

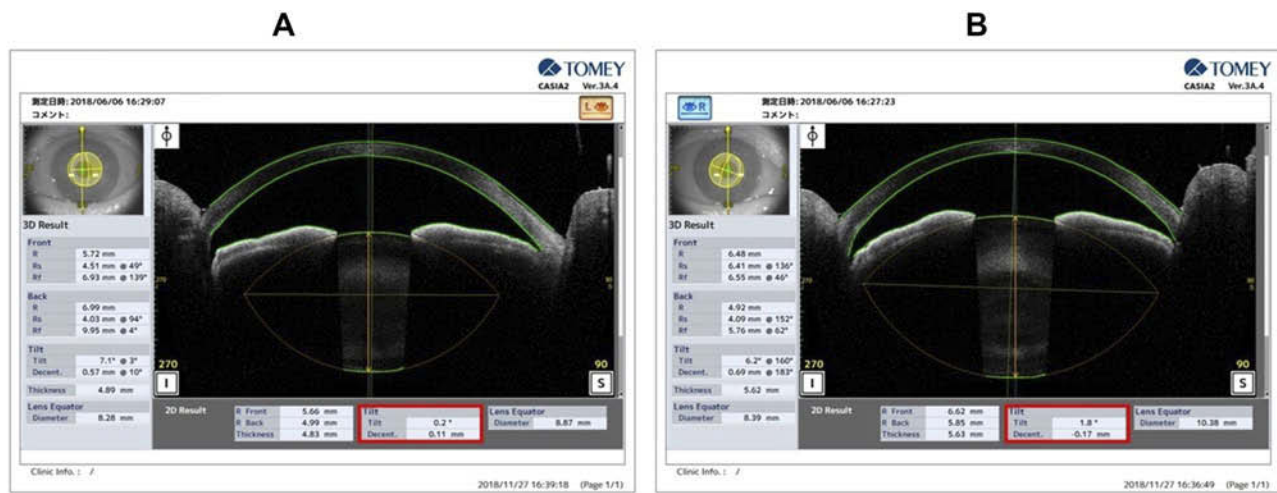
## Case report

A 68-year-old man presented at our clinic with visually significant cataracts bilaterally. There was no systemic disorder, family history, history of eye surgery or ocular contusion. The preoperative corrected distance visual acuity (CDVA) was 20/30 in the right eye and 20/20 in the left eye, with a refraction of  $-6.0 -1.5 \times 140$  and  $-6.5 -1.25 \times 150$ , respectively.

Slit-lamp bio-microscopy was carefully performed in both eyes. No lenticular decentration or malposition, zonular dehiscence, pseudoexfoliation material on the lens capsule or pupil margin, vitreous prolapse, and angle trauma or recession were identified in either eye. The lens edge was flat, which indicated that the zonular fibers were likely to be healthy. In the sitting position, there was no significant difference in anterior chamber depth (ACD) between both eyes, as measured by an optical biometer (IOL Master 700, Carl Zeiss Meditec): 3.02 mm in the right eye and 3.03 mm in the left eye. Intraocular pressure was 14 mmHg in the right eye and 16 mmHg in the left eye. In both eyes, pupil dilation was round and adequate, and there was no abnormality in the posterior segment of either eye. Tilt and decentration measured by AS-OCT were  $1.8^\circ$  and 0.17 mm in the right eye and  $0.2^\circ$  and 0.11 in the left eye, respectively (Figure 2A and B). UBM was not performed in this case since, because, as noted above, there was no indication of phacodonesis in other tests.



**Figure 1** Images from a circle scan (A) and a line scan (B) in the normal eye. In the normal eye, the anterior capsule (yellow arrow) and posterior capsule (red arrow) were parallel in the line scan. There was no abnormal space between the iris and lens in the line scan (blue arrow).



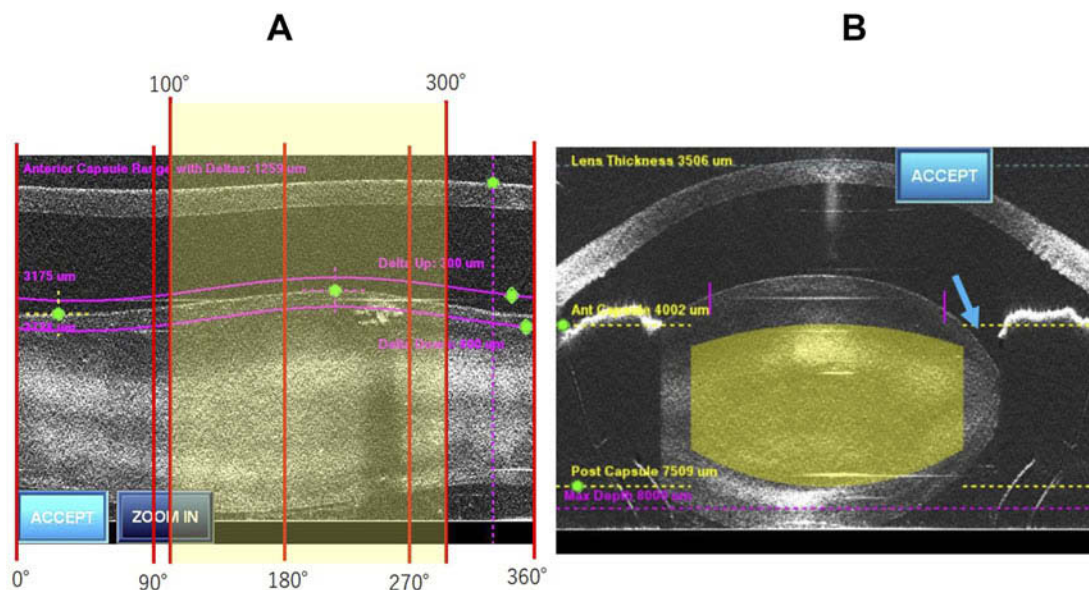
**Figure 2** Preoperative anterior segment optical coherent tomography image in both eyes. There was no significant tilt or decentration of the lens in either of the eyes (red box).

At the patient's request, we planned to carry out FLACS with a LenSx, phacoemulsification, and IOL implantation of bifocal lenses, for both eyes. The operation for the left eye was planned one week after that for the right eye.

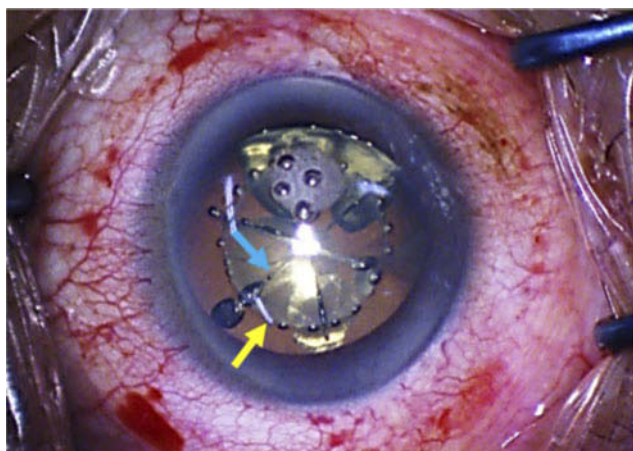
As per routine, the patient lay in the supine position for FLACS with LenSx. Patient interface (PI) was used to dock the right eye in an appropriate manner. The circle scan in LenSx showed that the anterior capsule was not parallel with the posterior capsule, a condition referred to as "Fish pattern." This pattern indicates zonular weakness or dialysis, and extends from 100° to 300° (Figure 3A). The line scan in the LenSx demonstrated the largest point of zonular weakness or

dialysis, which was 210° in this case (Figure 3B). The circle and line scans revealed approximately 200° zonular weakness in total from 100° to 300°; the largest point was 210°. Next, we performed FLACS. A 5.0 mm capsulotomy centered on White to White (WTW) was created with 8.0 mJ of energy (spot and layer separations: 9 μm each) (Figure 4). Nuclear fragmentation was performed using the chop technique with 8.0 mJ of energy (spot and layer separations: 9 μm each) (Figure 4).

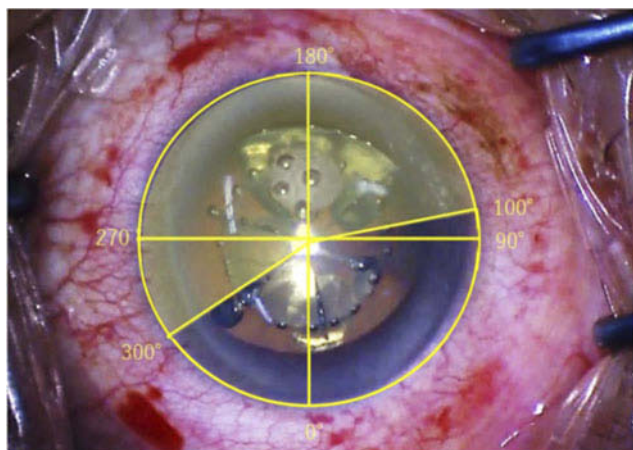
However, when the manual part of the operation was commenced, we observed zonular dialysis in the same area as seen on LenSx AS-OCT (Figure 5). The free-floating anterior capsulotomy was subsequently removed with no



**Figure 3** Images from a circle scan (A) and a line scan (B) in the right eye. The circle scan indicated zonular dehiscence from 100° to 300°. The line scan showed that the largest area of zonular dehiscence was 210° (blue arrow).



**Figure 4** Intraoperative image in the right eye taken during femtosecond laser surgery showing a continuous curvilinear capsulorhexis, 5.0 mm in diameter, centered on White to White (yellow arrow). Nuclear fragmentation was achieved using the chop mode (blue arrow).



**Figure 5** Image of the zonular dehiscence area from 100° to 300° (yellow shadow area).

additional stress to the zonules. Lens fragmentation was also completed by LenSx, and pieces of the lens were smoothly removed with minimal stress to the zonula. The cortex was also carefully removed; at this point, we did not observe any further zonular dialysis or vitreous collapse. Since the zonular dialysis extended to 200° in total, we did not proceed to use the capsule to place the IOL. Instead, we performed the scleral-fixed IOL implantation technique at a later date.

One week after the operation for the right eye, we performed the same procedure in the left eye. Prior to the operation, we repeated our detailed preoperative examinations in the left eye to identify tilt and decentration. As in the first preoperative examination, there was no sign of any tilt or decentration.

A regular docking process was performed in the left eye. The circle scan in LenSx showed the same Fish pattern

between the anterior and posterior capsules. Again, this indicated zonular weakness or dialysis, and extended from 90° to 270° (Figure 6A). A line scan in the LenSx demonstrated the largest point of zonular weakness or dialysis, which was 270° in this case (Figure 6B). Circle and line scans showed approximately 180° zonular weakness in total, from 90° to 270°; the largest point was 180°.

We then performed FLACS. A 5.0 mm capsulotomy, centered on WTW, was created with 8.0 mJ of energy (spot and layer separations: 9 μm each) (Figure 7). Nuclear fragmentation was performed using the chop technique with 8.0 mJ of energy (spot and layer separations: 9 μm each) (Figure 7). Soon after the manual aspect of the operation was commenced, we observed zonular dialysis in the same area as shown by LenSx AS-OCT (Figure 8). CCC was completely free from the capsule and removed with no stress. Lens fragmentation was also completed, and pieces of the lens and cortex were smoothly removed. We did not identify any further zonular dialysis or vitreous collapse. Since the zonular dehiscence extended to approximately 180°, we did not insert the CTR as this may have caused further iatrogenic zonular dialysis. Alternatively, a three-piece IOL was inserted into the sulcus using the optic capture technique in a CCC created by FLACS with a perfect circular shape and size (Figure 9)

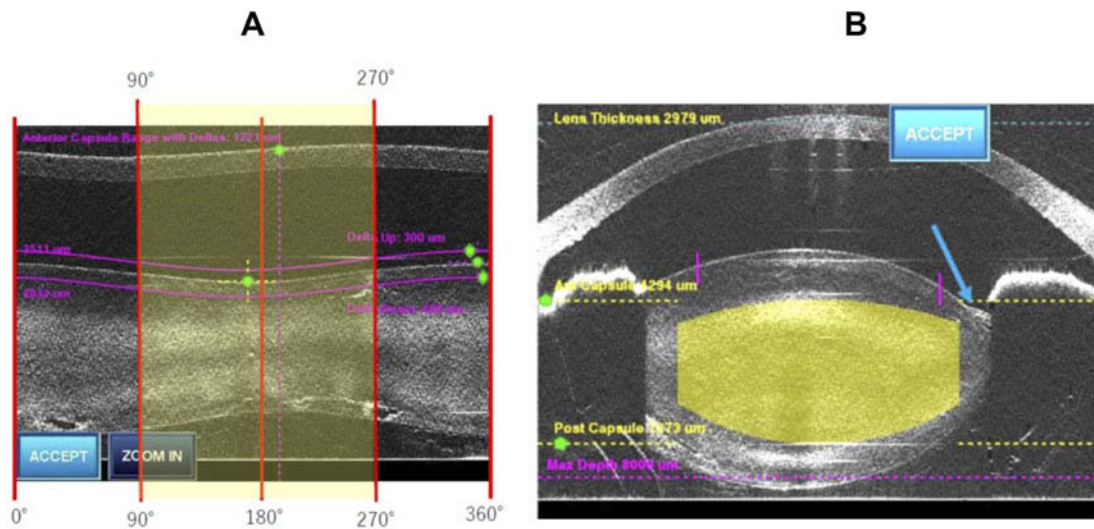
One month postoperatively, the refraction was +0.25–0.25×100 in the right eye and 0.00–0.25×180 in the left eye. Corrected distance visual acuity (CDVA) was 30/20 in both eyes. One month post-operatively, CASIA2 AS-OCT demonstrated that there was no significant tilt and decentration in the IOL with optic capture in the left eye (Figure 10).

The patient provided informed written consent for the publication of his case details and the accompanying images. Yokosuka Chuoh Eye Clinic, Yokohama Tsurumi Chuoh Eye Clinic, and Yokohama City University, all approved the publication of the details of this case.

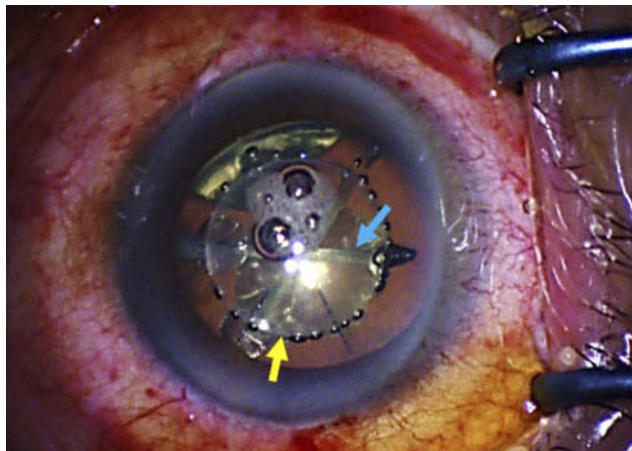
## Discussion

This case study highlights the advantages of FLACS for cataract surgery with zonulopathy. Despite the introduction of a range of devices for cataract surgery with zonulopathy, this operation is still a daunting challenge, particularly for novice surgeons.

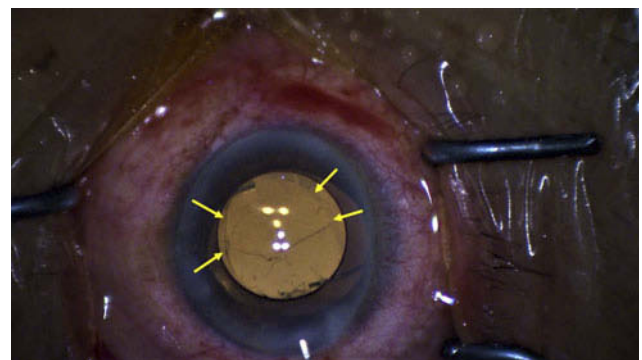
Pre-operative clinical evaluation of the ectopia lentis begins with taking histories, such as general family history and a specific history relating to trauma and/or systemic disorders. The most common case of zonulopathy is pseudoexfoliation syndrome (PXF). Following



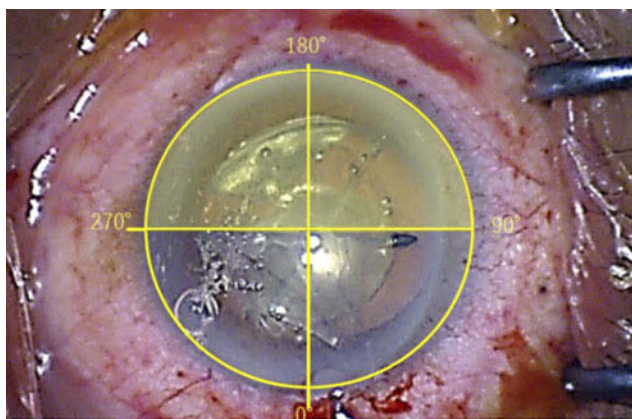
**Figure 6** Image of circle scan (A) and line scan (B) in the left eye. The circle scan indicated zonular dehiscence from 90° to 270° (yellow shadow area). The line scan showed the largest area of zonular dehiscence was 180° (blue arrow).



**Figure 7** Intraoperative image in the left eye taken during femtosecond laser surgery showing a continuous curvilinear capsulorhexis, 5.0 mm in diameter, centered on White to White (yellow arrow). Nuclear fragmentation was successfully achieved using the chop mode (blue arrow).



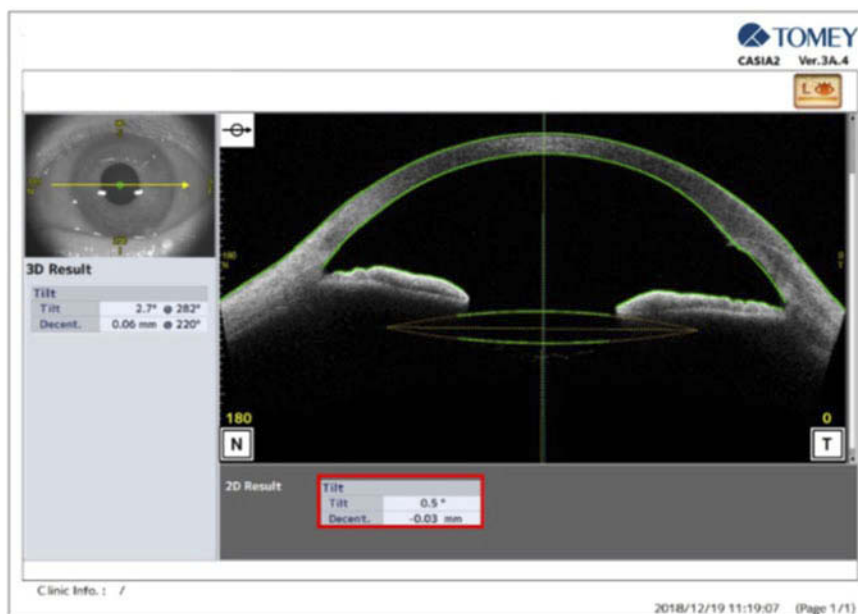**Figure 9** Image of optic capture involving the three-piece intraocular lens. The edge of the continuous curvilinear capsulorhexis is indicated by the yellow arrows.



**Figure 8** Image of the zonular dehiscence area from 90° to 270° (yellow shadow area).

history-taking, various ophthalmic examinations are performed to detect ectopia lentis pre-operatively, including slit-lamp biomicroscopy, AS-OCT and UBM. Strategies to tackle surgery involving zonulopathy differ according to the degree of zonulopathy. Therefore, it is imperative for surgeons to be comfortable identifying and managing zonulopathy.<sup>7</sup> However, despite thorough clinical evaluation by experienced eye doctors, it is often not until the operation has begun that underlying zonulopathy is revealed.

Some previous studies have investigated tilt and decentration in the lens. Based on the results of this research, the mean tilt and decentration ranges from 3° to 6° and from 0.11 mm to 0.24 mm, respectively.<sup>9,10</sup> In our case, tilt and decentration of the lens were within the average range for both eyes based on pre-operative clinical evaluations. Thus, there was no indication of zonulopathy preoperatively.



**Figure 10** Image of anterior segment optical coherent tomography in the left eye one month after the operation. There was no significant tilt and decentration in the intraocular lens with optic capture (red box).

Because of the circle and line scans in LenSx, zonulopathy was successfully detected before the subsequent manual aspect of the procedures. In addition to its detection, the scans also yielded information relating to the location and area of zonulopathy, which was very useful because it allowed us to formulate a plan to achieve successful IOL insertion. AS-OCT in the supine position probably allowed the detection, which was not possible in the pre-operative clinical examination in the sitting position.<sup>3</sup>

A complete CCC is the most essential factor for successful phacoemulsification and capsule preservation, especially in cases involving zonulopathy. Nonetheless, in such cases, even puncturing the anterior capsule is not always easy, as there is a lack of zonular counter traction. FLACS does not rely on counter traction from the zonule in order to complete CCC, unless the lens is excessively tilted.<sup>11</sup> Even in our case, despite a relatively wide area of zonulopathy, especially in the right eye, we were able to create a perfectly sized and shaped CCC by LenSx, with minimal stress to remove the free capsule.

Phacoemulsification can be another challenging procedure with zonulopathy. Hydrodissection and viscodissection are imperative to reduce stress to the zonule while mobilizing the lens.<sup>3</sup> Insufficient hydrodissection and viscodissection can cause excessive traction on pre-existing weakened zonular fibers. FLACS creates gas bubbles around the nucleus during lens fragmentation, referred to as pneumodissection, which allows gentle nuclear rotation with minimum stress to the

zonula.<sup>3</sup> The standard manual technique of nucleus disassembly and removal can lead to additional stress to the already weakened zonular region; however, lens fragmentation with FLACS is also useful because it limits unnecessary stress to the capsule.<sup>7</sup>

Capsular tension rings (CTRs) are an effective tool with which to support the area of zonular dialysis.<sup>12</sup> In a previous study, Jacob et al demonstrated that the success rate of IOL implantation in the bag with CTR was over 90% in cases where zonular dialysis was less than 150°. However, as CTR can cause extension of existing zonular dialysis, severe zonulopathy is a contraindication to CTR placement.<sup>13</sup> In our case, it was approximately 200° in the right eye and slightly over 180° in the left eye. Therefore, we were reluctant to use CTR to support zonular laxity.

IOL selection depends upon the degree of zonular laxity and the type of capsular support device available. As mentioned earlier, if zonulopathy is below 150°, in the bag IOL with CTR may be the most common option. IOL and CTR insertion into the bag may cause sufficient stress to lead to further zonular dialysis. Therefore, in cases involving a more severe degree of zonulopathy, the best option is a three-piece IOL in the sulcus with optic capture. The haptics of IOL in the sulcus, independent from the zonules, can provide additional centration and support. This procedure can reduce damage to the zonular region and the possibility of phimosis in addition to the long-term centration of the IOL.<sup>14</sup> FLACS makes the procedure much easier, as the CCC created by FLACS is

a perfectly symmetrical and consistent size. In a previous study, Cheer et al reported that FLACS achieved over 90% success rates in terms of retaining the capsular bag and implanting an IOL in the ectopia lentis with at least 6 clock hours of zonulopathy.<sup>15</sup> In another study, Crema et al demonstrated that FLACS might be effective in patients with Marfan syndrome with severe lens subluxation, and offer the benefit of minimizing further zonular damage.<sup>16</sup>

This case report demonstrated the advantages of using FLACS for cataract operations in a patient with zonulopathy. The benefit of having circle and line scan images allowed surgeons to identify the area of zonular dialysis that could not be identified preoperatively. FLACS does not rely on counter support from the zonular region, as long as the lens tilts excessively. Using this technique, it is also possible to create a CCC of perfect size and shape. In addition, lens fragmentation by FLACS produces gas bubbles between the lens fragments, which can minimize stress caused by phacoemulsification to the zonule, a condition referred to as pneumodissection. Furthermore, the consistent creation of totally symmetrical CCC by FLACS can often be useful for IOL insertion in the sulcus with optic capture, as this provides additional centration and support, independent of the zonular region.

In conclusion, FLACS is a very useful approach, especially when dealing with cataract surgery in zonular dialysis. Even in cases with PXF or traumatic cataracts, zonula dialysis can sometimes not be detected preoperatively. However, FLACS OCT scans can reveal such undetected zonular weakness. Furthermore, FLACS can minimize the stress to the zonule and allow the successful completion of the most important processes, such as CCC creation and lens fragmentation, which may improve the chances of inserting the IOL in the chosen place. Therefore, it is advantageous for surgeons to apply FLACS, at least in cases with PXF or traumatic cataracts.

## Disclosure

None of the researchers involved in this case study had any affiliations with or involvement in any organization or entity with any financial or non-financial interest. We did not receive any funding for this case study. The authors report no other conflicts of interest in this work.

## References

1. Dureau P. Pathophysiology of zonular diseases. *Curr Opin Ophthalmol*. 2008;19:27–30. doi:10.1097/ICU.0b013e3282f29f01
2. Nelson LB, Maumenee IH. Ectopia lentis. *Surv Ophthalmol*. 1982;27:143–160. doi:10.1016/0039-6257(82)90069-8
3. Hoffman RS, Snyder ME, Devgan U, Allen QB, Yeoh R, Braga-Mele R, ASCRS Cataract Clinical Committee; Challenging/Complicated Cataract Surgery Subcommittee. Management of the subluxated crystalline lens. *J Cataract Refract Surg*. 2013;39(12):1904–1915. doi:10.1016/j.jcrs.2013.09.005
4. Jacob S, Agarwal A, Agarwal A, Agarwal S, Patel N, Lal V. Efficacy of a capsular tension ring for phacoemulsification in eyes with zonular dialysis. *J Cataract Refract Surg*. 2003;29(2):315–321. doi:10.1016/S0886-3350(02)01534-1
5. Ahmed II, Cionni RJ, Kranemann C, Crandall AS. Optimal timing of capsular tension ring implantation: miyake-Apple video analysis. *J Cataract Refract Surg*. 2005;31(9):1809–1813. doi:10.1016/j.jcrs.2005.02.048
6. Donaldson KE, Braga-Mele R, Cabot F, et al.; for the ASCRS Refractive Cataract Surgery Subcommittee. Femtosecond laser-assisted cataract surgery. *J Cataract Refract Surg*. 2013;39:1753–1763. doi:10.1016/j.jcrs.2013.09.002
7. Taravella MJ, Meghpara B, Frank G, Gensheimer W, Davidson R. Femtosecond laser-assisted cataract surgery in complex cases. *J Cataract Refract Surg*. 2016;42(6):813–816. doi:10.1016/j.jcrs.2016.02.049
8. Song C, Baharozian CJ, Hatch KM, Talamo JH. Assessment of surgeon experience with femtosecond laser-assisted cataract surgery. *Clin Ophthalmol*. 2018;6(12):1373–1377. doi:10.2147/OPHTH.S171743
9. Kimura S, Morizane Y, Shiode Y, et al. Assessment of tilt and decentration of the crystalline lens and intraocular lens relative to the corneal topographic axis using anterior segment optical coherence tomography. *PLoS One*. 2017;12(9):e0184066. doi:10.1371/journal.pone.0184066
10. Baumeister M, Neidhardt B, Strobel J, Kohnen T. Tilt and decentration of three-piece foldable high-refractive silicone and hydrophobic acrylic intraocular lenses with 6-mm optics in an intraindividual comparison. *Am J Ophthalmol*. 2005;140(6):1051–1058. doi:10.1016/j.ajo.2005.07.026
11. Nagy ZZ, Kránitz K, Takacs A, Filkorn T, Gergely R, Knorz MC. Intraocular femtosecond laser use in traumatic cataracts following penetrating and blunt trauma. *J Refract Surg*. 2012;28(2):151–153. doi:10.3928/1081597X-20120120-01
12. Gimbel HV, Sun R, Heston JP. Management of zonular dialysis in phacoemulsification and IOL implantation using the capsular tension ring. *Ophthalmic Surg Lasers*. 1997;28(4):273–281.
13. Randleman JB, Ahmed IIK. *Intraocular Lens Surgery: Selection, Complications, and Complex Cases*. New York, NY: Thieme; 2016.
14. Kemp PS, Oetting TA. Stability and safety of MA50 intraocular lens placed in the sulcus. *Eye (Lond)*. 2015;29(11):1438–1441. doi:10.1038/eye.2015.28
15. Chee SP, Wong MH, Jap A. Management of severely subluxated cataracts using femtosecond laser-assisted cataract surgery. *Am J Ophthalmol*. 2017;173:7–15. doi:10.1016/j.ajo.2016.09.021
16. Crema AS, Walsh A, Yamane IS, Ventura BV, Santhiago MR. Femtosecond laser-assisted cataract surgery in patients with Marfan syndrome and subluxated lens. *J Refract Surg*. 2015;31(5):338–341. doi:10.3928/1081597X-20150424-02

### International Medical Case Reports Journal

Dovepress

#### Publish your work in this journal

The International Medical Case Reports Journal is an international, peer-reviewed open-access journal publishing original case reports from all medical specialties. Previously unpublished medical posters are also accepted relating to any area of clinical or preclinical science. Submissions should not normally exceed 2,000 words or 4

published pages including figures, diagrams and references. The manuscript management system is completely online and includes a very quick and fair peer-review system, which is all easy to use. Visit <http://www.dovepress.com/testimonials.php> to read real quotes from published authors.

Submit your manuscript here: <https://www.dovepress.com/international-medical-case-reports-journal-journal>