

Endoscopic vitrectomy in endophthalmitis: initial experience of 33 cases at a tertiary eye care center

This article was published in the following Dove Medical Press journal:
Clinical Ophthalmology

Vivek Pravin Dave¹
Rajeev R Pappuru¹
Mudit Tyagi¹
Avinash Pathengay²
Taraprasad Das¹

¹Smt Kanuri Santhamma Center for Vitreoretinal Diseases, Kallam Anji Reddy Campus, LV Prasad Eye Institute, Hyderabad 500034, Telangana, India; ²Retina and Uveitis Department, GMR Varalaxmi Campus, LV Prasad Eye Institute, Hanumanthawaka Chowk, Visakhapatnam 530040, Andhra Pradesh, India

Purpose: To report the presentation and management outcomes of endophthalmitis with endoscopic vitrectomy.

Methods: This is a retrospective interventional case series conducted at a tertiary eye care center in south India. Thirty three eyes of 33 patients were included. The medical records of the patients who underwent endoscopic vitrectomy for endophthalmitis from April 2014 to March 2018 were reviewed. Data with regard to age, gender, etiology of endophthalmitis, corneal and retinal examination, type of intervention, final anatomic and visual outcome, and the total follow-up were collected. The main outcome measures were the final visual acuity and evisceration rates.

Results: The mean age at presentation was 46.84±19.89 years, with a median age of 50 years. Based on etiology, 13 eyes (39.4%) were post-trauma endophthalmitis, eleven eyes (33.33%) were post-cataract surgery, three eyes (9.09%) were endogenous, three eyes (9.09%) were post-perforated corneal ulcer, two eyes (6.06%) were post-retinal surgery, and one eye (3.03%) was post-combined cataract and corneal surgery. Twenty-four eyes (72.72%) had a favorable anatomic outcome at the last visit, and five eyes (15.15%) had a favorable visual outcome. Of those with unfavorable visual outcome, ten eyes had further visual potential. Sixteen eyes (48.48%) showed a positive culture on microbiologic evaluation. The predominant organism isolated was *Pseudomonas aeruginosa*. Evisceration was required only in one eye (3.03%).

Conclusion: Endoscopic vitrectomy allows early management of endophthalmitis in spite of hazy media. This ensures a reasonable visual outcome, controls the infection, and reduces the incidence of evisceration in these eyes.

Keywords: evisceration, trauma, vitrectomy

Introduction

Endophthalmitis is defined as inflammation of the inner layers of the eye with exudation in the vitreous cavity resulting from intraocular colonization by microorganisms.¹ Unless diagnosed and treated in time, it can lead to severe vision loss. On clinical presentation, endophthalmitis is characterized by varied degree of corneal edema, anterior chamber fibrin, cataract in phakic individuals, and vitritis. The current knowledge suggests that early vitrectomy is indicated in cases of severe endophthalmitis presenting with less than hand motions vision.^{2,3} But in the acute setting, often the surgical view is compromised due to corneal edema, inflammatory membranes, and hemorrhages (in case of trauma). This precludes the possibility of achieving a satisfactory vitrectomy.

Correspondence: Rajeev R Pappuru
Smt Kanuri Santhamma Center for Vitreoretinal Diseases, Kallam Anji Reddy Campus, LV Prasad Eye Institute, Road no 2, Banjara Hills, Hyderabad 500034, Telangana, India
Tel +91 998 903 5551
Email rajeevkrp@gmail.com

An ophthalmic endoscope helps circumvent this restriction and allows visibility into the vitreous cavity bypassing the hazy anterior segment media.⁴⁻⁶ Though the use of endoscopy in ophthalmology has been described in a few isolated series earlier, a detailed description of its usage in managing endophthalmitis is sparse. In the current communication, we describe our experience of treating a series of cases with endophthalmitis using endoscopic visualization.

Methods

Study design

This is a retrospective, non-comparative, consecutive case series conducted at a tertiary eye care center in south India. The study was approved by the institutional ethics committee (the LV Prasad Eye Institute Ethics Committee). The data of all the patients were handled confidentially. As this was a retrospective study and only previous patient records were analyzed, requirement of a patient consent for the same was waived by the ethics committee. It conformed to the tenets of the Declaration of Helsinki. Clinical and microbiologic records of all patients with endophthalmitis who underwent endoscopic vitrectomy between April 2014 and March 2018 were reviewed and analyzed.

Methodology

All demographic and clinical information was collected from the patient's records.

Clinical presentation of patients decided the course of management by the treating physician. Cases either underwent primary endoscopy or underwent endoscopic procedure after initial primary management based on the clinical decision. All patients underwent vitreous biopsy initially, and empirical intravitreal vancomycin (1 mg/0.1 mL) and ceftazidime

(2.25 mg/0.1 mL) were given. Based on culture reports further interventions were planned. Vitreous samples were subjected to basic microbiological testing (calcofluor white, Gram, and Giemsa stains) and culture (aerobic and anaerobic). All patients received topical antibiotics like ciprofloxacin 0.3%, cycloplegics and topical steroids, and oral ciprofloxacin 750 mg twice a day after initial intervention. The outcome at the last visit was evaluated in terms of anatomic and functional outcome. A favorable anatomic outcome was defined as preservation of the globe, absence of hypotony, attached retina, and absence of active inflammation at the last visit. A functional success was defined as a vision of $\geq 20/400$ at the last visit. Evisceration was performed in cases that developed a painful blind eye, had prolapse of intraocular contents due to a corneal perforation, or showed progression to panophthalmitis.

Endoscopy technique

Endoscopy was done using the 20/23G endoscope (E2 Laser and Endoscopy System; EndoOptiks, Inc, Little Silver, NJ, USA) with light and video dual function. The E2 Ophthalmic Laser Endoscopy System console uniquely combines endoscopic imaging and laser treatment capability. The console houses a high-resolution video camera, 175 or 300 W xenon light source and an 810 nm diode laser. The endoscope presents a wide-field image allowing a panoramic intraocular view of the entire retina or a close-up (down to 0.75 mm) and highly magnified view of pathology. The in-built video adapter offers optimum zoom and manual focus of the endoscopic image. The resolution of the 20G camera is 10,000 pixels while that of the 23G camera is 6,000 pixels. The surgical steps included sterile draping of the eye followed by creating two superior sclerotomies as per

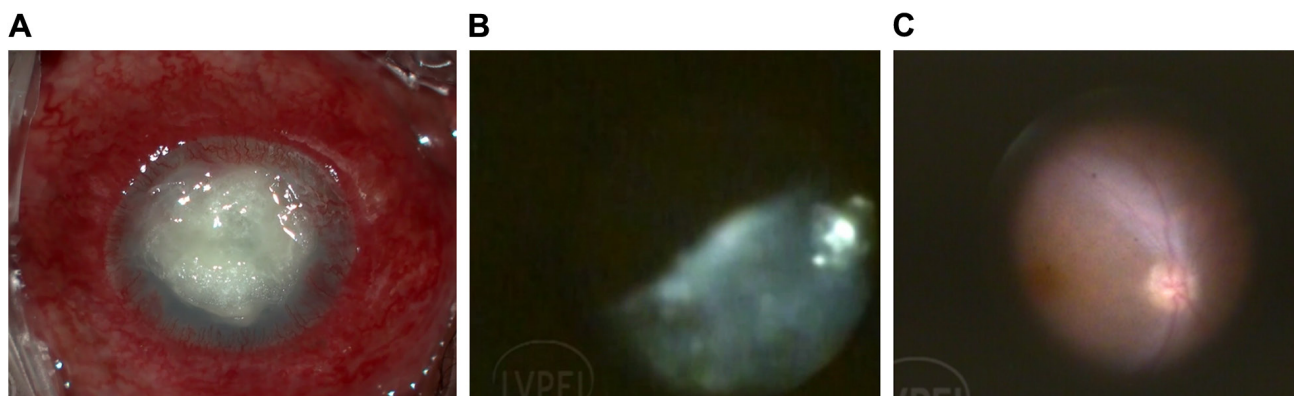


Figure 1 Panel shows endophthalmitis with a post-glue application perforated corneal ulcer with endophthalmitis.

Notes: Endophthalmitis with corneal infiltrates precluding fundus view (**A**). Intraoperative view showing vitreous cutter clearing the exudates (**B**). Clear fundus view after removing the exudates showing relatively healthy retina (**C**). The endoscopic view shows vitreous being removed and finally presenting a healthy looking disc and macula.

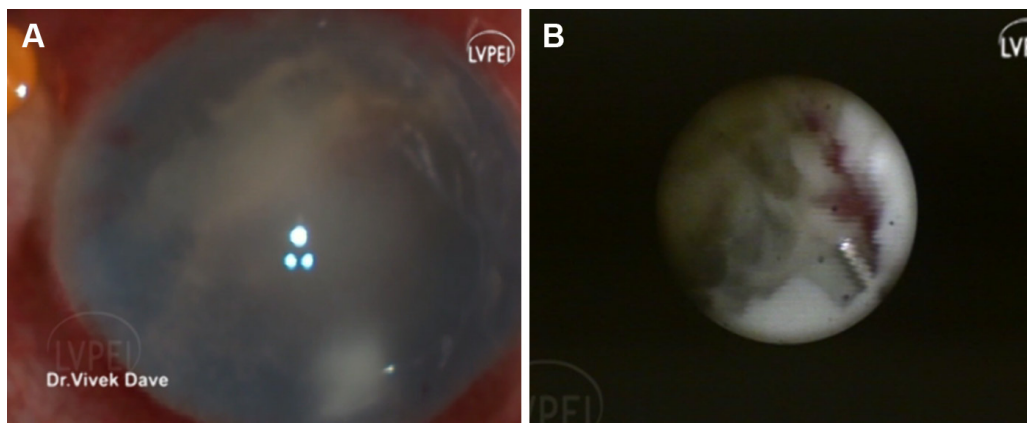


Figure 2 Panel shows endophthalmitis with corneal edema and endoexudates (A) and endoscopic view shows necrotic retina with poor visual prognosis (B).

the surgeon's preference for a standard three-port vitrectomy surgery. The endoscope was then maneuvered to the mid-pupillary retrolental location and position was confirmed on the TV monitor. The vitrector was then moved toward the endoscope to position it in the vitreous cavity. Vitrectomy was then performed under endoscopic visualization. A thorough vitrectomy, to the extent possible, was attempted. The end point of surgery was taken as visibility of the disc and the retina. Wherever possible an attempt was made to induce posterior vitreous detachment (PVD). If a strong adherence was noted on the induction, PVD induction was avoided.

The cases presented with associated retinal detachment, retinal breaks, or foreign bodies, and were treated appropriately (Figures 1–4). In cases with associated retinal detachment, after a thorough anterior and core vitrectomy, a PVD was induced and the vitrectomy was completed. The retina was flattened either with a fluid air

exchange tamponade or a perfluorocarbon liquid (PFCL) tamponade. After flattening, all breaks were lasered and the air/PFCL was exchanged with silicone oil. In cases with associated foreign bodies, after completing the vitrectomy, the foreign bodies were approached using an intraocular magnet, and if magnetic, were removed using the same. Non-magnetic foreign bodies were removed using an intraocular forceps.

Results

In the described time period, 33 eyes diagnosed as having endophthalmitis were managed with endoscopic vitrectomy. The study included 25 males (75.75%) ($P < 0.0001$). The mean age at presentation was 46.84 ± 19.89 years, with a median age of 50 years. Based on the etiology of the disease, 13 eyes (39.4%) were post-trauma endophthalmitis, eleven eyes (33.33%) were post-cataract surgery, three eyes (9.09%)

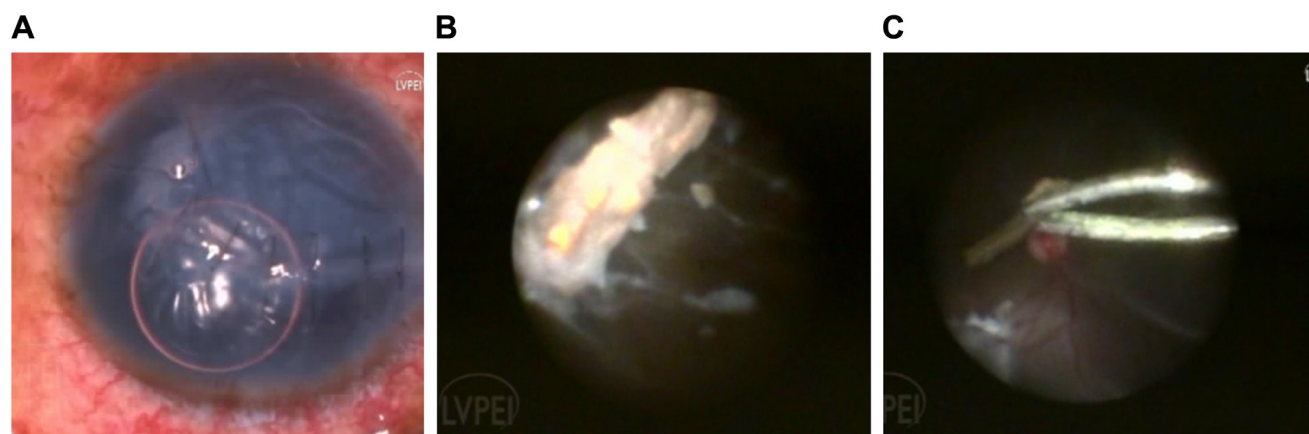


Figure 3 Panel shows a repaired corneal tear with vitreous exudates (A). A wooden foreign body on endoscopic view which is being removed with foreign body forceps (B). Wooden foreign body being removed with a forceps with concurrent retinal detachment (C).

Note: Background shows concurrent retinal detachment (C).

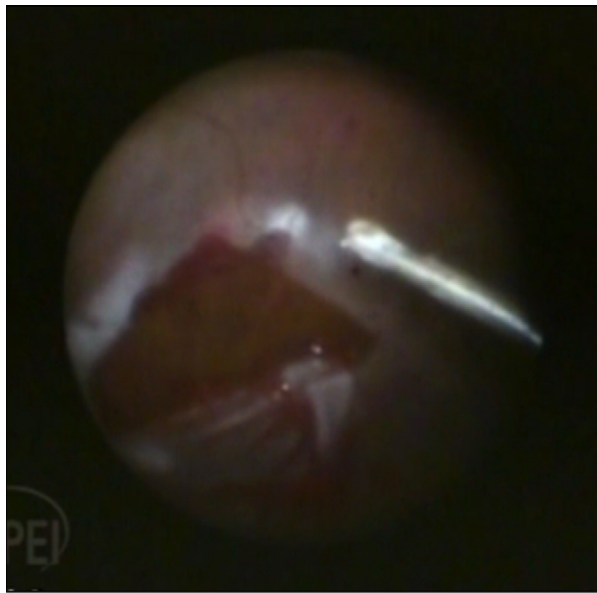

Figure 4 Figure shows retina flattened under perfluorocarbon liquid and a large retinal break.

were endogenous, three eyes (9.09%) were post-perforated corneal ulcer, two eyes (6.06%) as post-retinal surgery, and one eye (3.03%) was post-combined cataract and corneal surgery (Table 1).

Nineteen eyes (57.57%) had only perception of light (PL) vision, whereas 14 eyes (42.42%) had at least hand motions close to face at presentation. Twenty four eyes (72.72%) had a favorable anatomic outcome at the last visit, whereas only five eyes (15.15%) had a favorable visual outcome at the last visit. Among the remaining 28 eyes which had an unfavorable visual outcome at the last visit, ten eyes had further vision potential after a second corneal procedure was planned as assessed by the viability of the retina visualized intraoperatively on endoscopy. Evisceration was required only in one eye. Samples from 16 eyes (48.48%) showed a positive culture on microbiological evaluation. The predominant organism isolated was *Pseudomonas aeruginosa* followed by *Streptococcus pneumoniae* (Table 2).

Table I Demographic and clinical data of endophthalmitis cases undergoing endoscopic vitrectomy

Case no	Gender	Age (years)	Presenting vision	Setting of endophthalmitis	Anterior chamber findings	Interval between start of symptoms and presentation	Cause of poor visualization
1	M	15	PL	Trauma	Hypopyon	2 days	Corneal edema
2	M	46	PL	Trauma	Hypopyon and exudates	4 days	Repaired corneal tear
3	F	74	PL	Post-cataract	No view	6 months	Vascularized cornea
4	M	24	PL	Trauma	Hypopyon	2 days	Corneal edema
5	M	25	PL	Trauma	No view	30 days	Corneal edema
6	M	51	HM	Trauma	Hypopyon	2 days	Corneal edema and infiltrates
7	M	73	HM	Buckle infection	Endoexudates	1 day	Corneal edema
8	M	25	PL	Trauma	Hypopyon	2 days	Repaired laceration
9	M	4	PL	Trauma	Hyphema	3 days	Repaired corneal tear
10	M	60	PL	Endogenous	No view	1 month	Corneal edema
11	M	60	PL	Endogenous	No view	1 month	Corneal edema
12	M	50	PL	Post-corneal ulcer	Hypopyon	10 days	Stromal infiltrate
13	F	72	HM	Post-corneal ulcer	Hypopyon	1 month	Infiltrate with hypopyon
14	F	60	CFCF	Post-cataract surgery	Hyphema and exudates	1 month	Blood stained and endothelial exudates
15	M	30	PL	Post-trauma	Cells and fibrin	1 week	Corneal ring infiltrate and edema
16	M	26	PL	Post-trauma	Hazy view	1 day	Microcystic edema

Discussion

The current study reports the management of cases of endophthalmitis with endoscopic vitrectomy. The ophthalmic endoscope was first introduced by Thorpe in 1934 for the extraction of non-metallic foreign bodies.⁷ Ever since, there have been reports of its usage for various retina- and glaucoma-related pathologies.⁸⁻¹⁰ Our group recently reported the sensitivity of diagnostic endoscopy in prognosticating the posterior segment before conducting a definitive vision-restoring anterior segment procedure.¹¹ In conditions like endophthalmitis where acute management is paramount, but is often obstructed by limited anterior segment visualization, the application of endoscopy is ideal. The other alternative to managing such cases is performing a temporary keratoprosthesis placement, vitrectomy, and then followed by an immediate penetrating keratoplasty.¹² Though a viable option, this process increases the surgical time and the complexity of the surgery, and in case the eye is deemed inoperable on

table, time and energy investment would become void as keratoplasty would still be obligatory. Conversely, it has been shown that both temporary keratoprosthesis and endoscopy have comparable anatomic and visual outcomes in managing cases with ocular trauma and opaque cornea.¹³ The study also suggested that endoscopy allows earlier diagnoses and fewer surgical interventions when compared to keratoprosthesis.

Ben-nun et al described seven cases of corneal edema with posterior segment pathologies managed with endoscopic vitrectomy.⁶ Both the presenting visual acuity and the final visual outcome were better in their series than the current series. This is explained by the fact that only one case in that series had endophthalmitis. One large series of endophthalmitis managed with endoscopy was described by De Smet et al.² They described 15 eyes managed with endoscopy. Post-cataract surgery was the commonest etiology in their series (7/15 eyes [46.67%]). In their series, overall eight patients (53.33%) retained useful vision.

Need for endoscopy	Procedure performed	Follow-up in months	Final visual acuity	Final anatomic outcome	Final visual outcome	Cause of low final vision	Further visual potential
Non-resolving vitritis	PPV + EL + SOI	20	20/320	F	F	Macular scar	N
RIOFB	PPV + EL + IOFB removal	9	No PL	UF	UF	Phthisis	N
Chronic vitreous exudates	PPV	8	CF I m	F	UF	Optic atrophy	N
RIOFB	PPV + EL + IOFB removal	15	PL	UF	UF	RD	N
Non-resolving vitritis with RD	PPV + EL + SOI	3	No PL	UF	UF	Phthisis	N
Vitritis with RIOFB	PPV + EL + SOI + IOFB removal	5	20/400	F	F	Graft failure	Y
Vitritis	PPV + AC wash	2	HM	F	UF	Corneal scar	Y
RIOFB and vitritis	PPV + EL + PPL + IOFB removal	7	20/125	F	F	Corneal scar	Y
Vitritis	PPV + SOI	10	No PL	UF	UF	Phthisis	N
Vitritis	PPV + SOI	6	PL	F	UF	Optic atrophy	N
Vitritis	PPV + SOI	6	PL	F	UF	Optic atrophy	N
Vitritis	PPV	4	HM	F	UF	Corneal scar	Y
Vitritis	PPV	2	HM	F	UF	Corneal scar	Y
Vitritis	PPV + FAE	3	CFCF	F	UF	Corneal scarring	Y
RIOFB and vitritis	PPV + IOFB removal	5	HM	UF	UF	Corneal scarring and RD	N
Vitritis + RIOFB	PPV + IOFB removal	3	No PL	UF	UF	Eviscerated	N

(Continued)

Table 1 (Continued)

Case no	Gender	Age (years)	Presenting vision	Setting of endophthalmitis	Anterior chamber findings	Interval between start of symptoms and presentation	Cause of poor visualization
17	M	71	CFCF	Post-cataract surgery	Hazy view	2 months	Decompensated cornea
18	M	58	HM	Post-cataract surgery	Hypopyon and iris exudates	2 weeks	Microcystic edema
19	F	61	HM	Post-cataract surgery	Hypopyon	4 days	Stromal edema
20	M	51	CFCF	Post-DSEK + cataract surgery	Hazy view	3 days	Microcystic edema
21	M	81	PL	Post-cataract surgery	Hypopyon and hyphema	1 month	Corneal epithelial defect with infiltrate
22	M	28	20/320	Endogenous	Hazy view	1 month	Corneal scar due to resolved keratitis
23	M	35	HM	Post-retinal surgery	Hazy view	3 days	Stromal infiltrate
24	F	36	PL	Post-trauma	Hypopyon	6 days	Stromal infiltrate
25	F	55	PL	Post-cataract surgery	Hypopyon	1 day	Stromal infiltrate
26	F	70	HM	Post-cataract surgery	Fibrin	1 day	Stromal infiltrate
27	M	65	PL	Post-cataract surgery	Hazy view	1 day	Stromal infiltrate
28	M	50	HM	Perforated corneal ulcer	Hazy view	6 weeks	Stromal infiltrate and iris prolapse
29	F	60	PL	Post-cataract surgery	Hazy view	1 day	Stromal infiltrate
30	M	44	HM	Post-trauma	Streaky hypopyon	1 day	Corneal tear with iris prolapse
31	M	24	HM	Post-trauma	AC exudates	1 day	Corneal tear with infiltrate
32	M	22	PL	Post-trauma	Plaque over the iris	1 day	Corneal edema
33	M	40	PL	Post-cataract surgery	Hyphema and hypopyon	1 day	Corneal infiltrate

Abbreviations: CFCF, counting fingers close to face; EL, endolaser; F, favorable; HM, hand motions vision; IOFB, intraocular foreign body; N, no; PL, perception of light; PPV, pars plana vitrectomy; SOI, silicone oil injection; UF, unfavorable; Y, yes; AC, anterior chamber; DSEK, descemet stripping endothelial keratoplasty; RIOFB, retained intraocular foreign body; RD, retinal detachment; BCL, bandage contact lens; CF, counting fingers; PPL, pars plana lensectomy; FAE, fluid air exchange.

In contrast, in the current study, only five eyes (15.15%) had a favorable visual outcome at the last visit. This relatively poorer visual improvement could be explained by the fact that in our series, the predisposing cause was predominantly open globe injury, which itself is an independent risk factor for poor visual outcome. Ren et al¹⁴ have also described a series of endophthalmitis cases that were managed with endoscopic vitrectomy. In their series, akin ours, 16/21 eyes (76.19%) were post-trauma. Useful vision was achieved in 3/21 eyes (14.28%). They too had predominantly post-trauma endophthalmitis (76.19%). Table 3 describes the comparative results of the current study with previous large studies.

In the current study, though the final visual outcome was poor, ten eyes among those with poor visual outcome had

a further scope of vision improvement by a future corneal procedure. This was determined by noting fairly healthy retinæ and discs in those cases during the endoscopic procedure. It is well known that involvement of cornea in cases of endophthalmitis predisposes the eye to risk of evisceration.¹⁵⁻¹⁸ In these studies, the evisceration rates varied from 14% to 43%. These studies suggest that an etiology of trauma, poorer presenting visual acuity, and delayed intervention increase the risk of evisceration. In the current study, where the cases were managed relatively early in spite of poor visualization by endoscopy, the evisceration rate noted was 3.03% (1/33 eyes). This suggests that early intervention by endoscopy causes reduction of the organism load and may lead to containment of the infection. The containment

Need for endoscopy	Procedure performed	Follow-up in months	Final visual acuity	Final anatomic outcome	Final visual outcome	Cause of low final vision	Further visual potential
Vitritis + RD	PPV + EL + SOI	6	HM	UF	UF	Hypotony with ciliary atrophy	N
Persisting vitritis	PPV	3	PL	UF	UF	Hypotony	N
Persisting vitritis	PPV	2	HM	F	UF	Corneal scar	Y
Persisting vitritis	PPV	2	CFCF	F	UF	Resolving corneal infiltrate	Y
Persisting vitritis	PPV + SOI	2	HM	F	UF	Necrotic retina	N
Persisting vitritis	PPV	3	No PL	UF	UF	Phthisis	N
Persisting vitritis	PPV + MP + SOI	5	20/800	F	UF	Coloboma	N
Persisting vitritis	PPV	4	20/400	F	F	Irregular astigmatism	Y
Persisting vitritis	PPV	1	PL	F	UF	Corneal scarring	Y
Persisting vitritis	PPV + SOI	1	PL	F	UF	Corneal scarring	Y
Persisting vitritis	PPV + SOI	1	PL	F	UF	Necrotic retina	N
Vitritis	PPV+ Glue BCL	1	20/320	F	F	Graft with sutures in situ	Y
Vitritis	PPV + EL + SOI	1	HM	F	UF	Persistent epithelial defect	Y
Persistent vitritis	PPV + PPL	2	PL	F	UF	Necrotic retina	N
Persistent vitritis	PPV	2	PL	F	UF	Necrotic retina	N
Vitritis	PPV	1	PL	F	UF	Necrotic retina	N
Vitritis	PPV + SOI	1	PL	F	UF	Corneal scar	Y

of infection avoids the progression of endophthalmitis to panophthalmitis. This progression, if occurs, reduces the possibility of any visual gain drastically.¹⁹ The need to eviscerate an eye also has a psychological impact and can reduce the quality of life.²⁰

This study has its inherent limitations. Due to retrospective nature of the study, we could not assess various confounding factors. Small sample size was a limiting factor to reach a statistical significance of the impact of these factors. Most of the cases in this study were post-trauma endophthalmitis. Trauma itself is a confounding factor for a final poor visual outcome. It would be difficult to differentiate the reason for poor visual recovery in post-trauma endophthalmitis group, as it may be due to trauma or due to subsequent endophthalmitis.

We propose that this technique leads to a reduction in evisceration rates. Though this is not proven directly due to lack of a control arm in the current study, comparison with literature citing evisceration rates in conventional management of endophthalmitis does suggest so.¹⁵⁻¹⁸ As described earlier, a few cases are likely to benefit from further corneal intervention as the posterior segment was deemed viable on endoscopic examination. The final visual acuity obtained in these cases could not be reported, as definitive corneal interventions in these patients are pending as of current writing.

Conclusion

Endoscopic vitrectomy is a unique tool that allows for early detailed surgical intervention in cases of endophthalmitis

Table 2 Microbiological outcome of the cases in the current study

Case number	Cultured organism
1	No growth
2	No growth
3	No growth
4	No growth, Gram-negative bacilli on smear
5	No growth
6	<i>Streptococcus pseudoporcinus</i>
7	<i>Streptococcus pneumoniae</i>
8	No growth, Gram-positive cocci in pairs and chains on smear
9	<i>S. pneumoniae</i>
10	No growth
11	No growth
12	<i>Fusarium solani</i>
13	No growth
14	No growth
15	No growth
16	No growth
17	No growth
18	<i>Candida famata</i>
19	<i>Pseudomonas aeruginosa</i>
20	<i>P. aeruginosa</i> and <i>Exserohilum rostratum</i>
21	Unidentified fungus
22	No growth, Gram-positive cocci in pairs and chains
23	No growth
24	<i>P. aeruginosa</i>
25	<i>P. aeruginosa</i>
26	<i>P. aeruginosa</i>
27	<i>P. aeruginosa</i>
28	No growth
29	<i>P. aeruginosa</i>
30	<i>Klebsiella oxytoca</i>
31	<i>S. pneumoniae</i>
32	No growth
33	<i>P. aeruginosa</i>

Table 3 Comparative outcome of previous studies on endoscopy in endophthalmitis with the current study

Parameters	De Smet et al ²	Ren et al ¹⁴	Current series
Total eyes	15	21	33
Mean age (years)	64	34	47
Male gender (%)	8 (53.33%)	15 (71.42%)	25 (75.75%)
Vision at presentation not more than PL	9 (60%)	12 (57.14%)	19 (57.57%)
Final vision of at least CFCF	8 (53.33%)	7 (33.33%)	9 (27.27%)
Post-cataract surgery etiology	7 (46.66%)	4 (19.04%)	11 (33.33%)
Post-trauma etiology	2 (13.33%)	16 (76.19%)	13 (39.4%)
Mean follow-up (months)	6 ^a	18–36 ^b	4.42±4.21
Culture positivity rate	14 (93.33%)	11 (52.38%)	16 (48.48%)
Evisceration/enucleation rate	4 (26.66%)	2 (9.52%)	1 (3.03%)

Notes: ^aSD is not reported; ^bmean and SD are not reported. Data presented as n (%) unless stated otherwise.

Abbreviations: PL, perception of light; CFCF, counting fingers close to face.

where conventional approach is precluded due to poor media clarity. This may lead to better final visual and anatomic outcomes and obviate the need for evisceration significantly.

Acute endophthalmitis necessitates prompt treatment, often requiring early vitrectomy. This is precluded due to media opacity in most cases. The current study describes the application of endoscopic vitrectomy in such situations, as it helps to operate circumventing the compromised media clarity.

Disclosure

The authors report no conflicts of interest in this work.

References

- Mamalis N. Endophthalmitis. *J Cataract Refract Surg.* 2002;28(5):729–730.
- De Smet M, Ghyczy-Carlborg EAE, Mura M. Endoscopy for the management of severe endophthalmitis. *Acta Ophthalmol Scand.* 2006;84(Supplement 239):96–98.
- Endophthalmitis Vitrectomy Study Group. A randomized trial of immediate vitrectomy and of intravenous antibiotics for the treatment of postoperative bacterial endophthalmitis. *Arch Ophthalmol.* 1995;113:1479–1496.
- Boscher C, Lebuissou DA, Lean JS, Nguyen-Khoa JL. Vitrectomy with endoscopy for management of retained lens fragments and/or posteriorly dislocated intraocular lens. *Graefes Arch Clin Exp Ophthalmol.* 1998;236(2):115–121.
- Valmaggia C, De Smet M. Endoscopic management of neo-vascular glaucoma. *Klin Monatsbl Augenheilkd.* 2004;221:343–346.
- Ben-Nun J. Cornea sparing by endoscopically guided vitreoretinal surgery. *Ophthalmology.* 2001;108(8):1465–1470.
- Thorpe HE. Ocular endoscopy: an instrument for removal of intravitreous nonmagnetic foreign bodies. *Trans Am Acad Ophthalmol.* 1934;39:422–424.
- Norris JL, Cleasby GW, Nakanishi AS, Martin LJ. Intraocular endoscopic surgery. *Am J Ophthalmol.* 1981;91(5):603–606.
- Uram M. Ophthalmic laser microendoscope ciliary process ablation in the management of neovascular glaucoma. *Ophthalmology.* 1992;99(12):1823–1828.
- Uram M. Ophthalmic laser microendoscope endophotocoagulation. *Ophthalmology.* 1992;99(12):1829–1832.
- Reddy Pappuru RR, Tyagi M, Paulose RM, et al. Role of diagnostic endoscopy in posterior segment evaluation for definitive prognostication in eyes with corneal opacification. *Am J Ophthalmol.* 2017;176:9–14.
- Ozimek M, Nowomiejska K, Forlini C, Rejdak R. Posttraumatic endophthalmitis due to tobacco drying wire treated with vitrectomy, temporary keratoprosthesis, and keratoplasty. *Ophthalmol J.* 2016;1(1):36–39.
- Chun DW, Colyer MH, Wroblewski KJ. Visual and anatomic outcomes of vitrectomy with temporary keratoprosthesis or endoscopy in ocular trauma with opaque cornea. *Ophthalmic Surg Lasers Imaging.* 2012;43(4):302–310.
- Ren H, Jiang R, Xu G, et al. Endoscopy-assisted vitrectomy for treatment of severe endophthalmitis with retinal detachment. *Graefes Arch Clin Exp Ophthalmol.* 2013;251(7):1797–1800.
- O'Neill EC, Yeoh J, Fabinyi DC, et al. Risk factors, microbial profiles and prognosis of microbial keratitis-associated endophthalmitis in high-risk eyes. *Graefes Arch Clin Exp Ophthalmol.* 2014;252(9):1457–1462.
- Scott IU, Flynn HW, Feuer W, et al. Endophthalmitis associated with microbial keratitis. *Ophthalmology.* 1996;103(11):1864–1870.
- Tsai YY, Tseng SH. Risk factors in endophthalmitis leading to evisceration or enucleation. *Ophthalmic Surg Lasers.* 2001;32(3):208–212.
- Xuehui L, Ds N, Zheng K. Risk factors for endophthalmitis requiring evisceration or enucleation. *Sci Rep.* 2016;6:28100.
- Pappuru RR, Dave VP, Pathengay A. Endophthalmitis progressing to panophthalmitis: Clinical features, demographic profile and factors predicting outcome. *Semin Ophthalmol.* 2017;19:1–4.
- Ahn JM, Lee SY, Yoon JS. Health-related quality of life and emotional status of anophthalmic patients in Korea. *Am J Ophthalmol.* 2010;149(6):1005–1011.

Clinical Ophthalmology

Publish your work in this journal

Clinical Ophthalmology is an international, peer-reviewed journal covering all subspecialties within ophthalmology. Key topics include: Optometry; Visual science; Pharmacology and drug therapy in eye diseases; Basic Sciences; Primary and Secondary eye care; Patient Safety and Quality of Care Improvements. This journal is indexed on

Submit your manuscript here: <http://www.dovepress.com/clinical-ophthalmology-journal>

Dovepress

PubMed Central and CAS, and is the official journal of The Society of Clinical Ophthalmology (SCO). The manuscript management system is completely online and includes a very quick and fair peer-review system, which is all easy to use. Visit <http://www.dovepress.com/testimonials.php> to read real quotes from published authors.