

# Cohesive Polydensified Matrix<sup>®</sup> cross-linked hyaluronic acid volumizing gel: a magnetic resonance imaging and computed tomography study

P Micheels<sup>1</sup>

S Besse<sup>2</sup>

J Vandeputte<sup>3</sup>

<sup>1</sup>Private Practice, Geneva, Switzerland;

<sup>2</sup>Medimage, Geneva, Switzerland;

<sup>3</sup>Plastic Surgery Unit, AZ Oudenaarde, Oudenaarde, Belgium

**Background:** Concentrated hyaluronic acid (HA) gels with a high degree of cross-linking such as Cohesive Polydensified Matrix<sup>®</sup> (CPM) HA have been designed for long-term facial volume restoration.

**Objective:** To determine the behavior and longevity of CPM HA gel, a case series of subjects underwent magnetic resonance imaging (MRI) or computed tomography (CT) scans several years after their initial treatment.

**Methods:** Six subjects, three from the initial CPM HA Conformité Européenne registration study and three from private practice who had received prior injection of CPM HA for facial volumizing indications agreed to undergo an MRI or CT scan at intervals ranging from 1 to 4 years after the initial treatment. The amount of HA gel originally injected was compared with the amount estimated from volumetric analysis of the MRI and CT scans. The scans were also examined for the signs of any abscess or granuloma formation and to determine the behavior of the HA gel over time.

**Results:** CT and MRI imaging of the six study subjects indicated CPM HA gel persisted for 2–4 years after only a single treatment. In some patients, product was evident in deeper facial fat compartments than originally injected suggesting some diffusion of product had occurred. There was no MRI or CT evidence of abscess or granuloma formation.

**Conclusion:** Our findings indicate that CPM HA volumizing gel has substantial longevity when injected subcutaneously or in deep soft tissues.

**Keywords:** MRI, CT scan, CPM HA volumizing gel, long-lasting results

## Introduction

Facial aging is a complex process involving the deterioration of skin quality and elasticity, reduced muscle tone as well as bone resorption, and soft tissue volume loss.<sup>1</sup> The standard method for correcting facial volume deficits was with fat transfer, with or without surgical soft tissue lifting or excision procedures. More recently, the development of hyaluronic acid (HA)-based volumizing fillers has provided an alternative method of restoring facial volume.<sup>2–8</sup>

A number of volumizing HA fillers are available, which have been manufactured to have unique characteristics by modifying their type and degree of cross-linking as well as total HA concentration. Available fillers therefore vary widely in their physical and chemical characteristics including gel viscosity, gel hardness, gel consistency, extrusion force, diffusion, distribution, bio-integration, and product longevity. Some of the terms used to describe the properties of the different HA gels are described in Table 1. These properties provide HA volumizing gels with great versatility. They may be injected as one or more boluses or in a linear fashion, either


Correspondence: P Micheels  
Private Practice, Avenue de Champel 6,  
1206 Geneva, Switzerland  
Tel +41 22 347 1113  
Email patrickscab@bluewin.ch

submit your manuscript | [www.dovepress.com](http://www.dovepress.com)

Dovepress    

<http://dx.doi.org/10.2147/CCID.S188650>

Clinical, Cosmetic and Investigational Dermatology 2019:12 1–10

 © 2019 Micheels et al. This work is published and licensed by Dove Medical Press Limited. The full terms of this license are available at <https://www.dovepress.com/terms.php> and incorporate the Creative Commons Attribution – Non Commercial (unported, v3.0) License (<http://creativecommons.org/licenses/by-nc/3.0/>). By accessing the work you hereby accept the Terms. Non-commercial uses of the work are permitted without any further permission from Dove Medical Press Limited, provided the work is properly attributed. For permission for commercial use of this work, please see paragraphs 4.2 and 5 of our Terms (<https://www.dovepress.com/terms.php>).

**Table 1** Definitions used to describe the properties of gels produced with different crosslinking technologies

Crosslinking terminology	Definition
Cohesivity <sup>13–15</sup>	The force that unites molecules of a gel or a fluid. Cohesivity keeps the gel from spreading in the surrounding tissues.
Elasticity <sup>13–15</sup>	Physical definition: The resistance to applied shear forces. This value is characterized by the modulus of elasticity, $G'$ . This gel property corresponds to the degree of forward projection or tissue support that the filler can provide Intuitive meaning: The ability for a substance to recover its original shape, after cessation of an externally applied force (eg, a rubber band snapping to its original length)
Plasticity–malleability <sup>13–15</sup>	Plasticity characterizes the malleability of a substance, in other words the possibility to remodel or reshape it. At present, there is no physical measure or measuring scale for this property
Resistance to dynamic compression <sup>13</sup>	Resistance to dynamic compression is described by two notions: elastic modulus $E'$ ( $E'$ prime) and normal force $F_n$ The compression parameters have been recently highlighted in the literature for better characterizing the mechanical properties of HA soft-tissue fillers <sup>13</sup> The introduction of these new parameters provided additional tools to study the behavior of fillers (in addition to the data obtained by previous research under shear-stress conditions) The normal force $F_n$ describes the behavior of fillers under static compression stress. The elastic modulus $E'$ describes the behavior of fillers under dynamic compression condition The knowledge of these new parameters is very important for better predicting the clinical outcomes, especially the volumizing capacity of fillers

**Abbreviation:** HA, hyaluronic acid.

retrograde or anterograde. Linear injections can be combined into fan or fern patterns. Injections can be performed with sharp needles or blunt cannulas of various calibers and lengths and may address one or more tissue layer. The filler may be deposited deep or superficial, including the deep reticular dermis<sup>9–11</sup> (Figure 1), in connective tissue, adipose tissue, or muscle. After injection, the filler may be left as such, or it may be remodeled to a more suitable shape or until it becomes impalpable. As a result, HA dermal fillers have become widely used by physicians and a favorite with patients due to their immediate, natural-appearing effects with minimal adverse events and recovery time.

During 2009–2010, one of the authors (PM) participated in a European multicenter study for Conformité Européenne (CE) registration of a new cross-linked HA volumizing gel produced with the patented Cohesive Polydensified Matrix® (CPM) cross-linking technology.<sup>5</sup> In December 2013, several years after the initial injection, one of the subjects from the CE registration study developed a neurological problem unrelated to injection and underwent magnetic resonance imaging (MRI) investigation. Examination of the MRI scans revealed HA residues several years after the initial treatment had taken place. Previous studies of HA injections for the correction of HIV-associated facial lipoatrophy have demonstrated that CPM HA volumizer gel remains for at least 1 year in the injected area.<sup>6</sup> To further investigate the longevity of CPM HA volumizer gel, three additional subjects from the CE registration study and three subjects from the first author's

private practice agreed to be scanned by MRI or computed tomography (CT). The aim was to observe the behavior of CPM volumizing HA gel several months to several years after injection, the medium- and long-term clinical results, and the amount of product remaining.

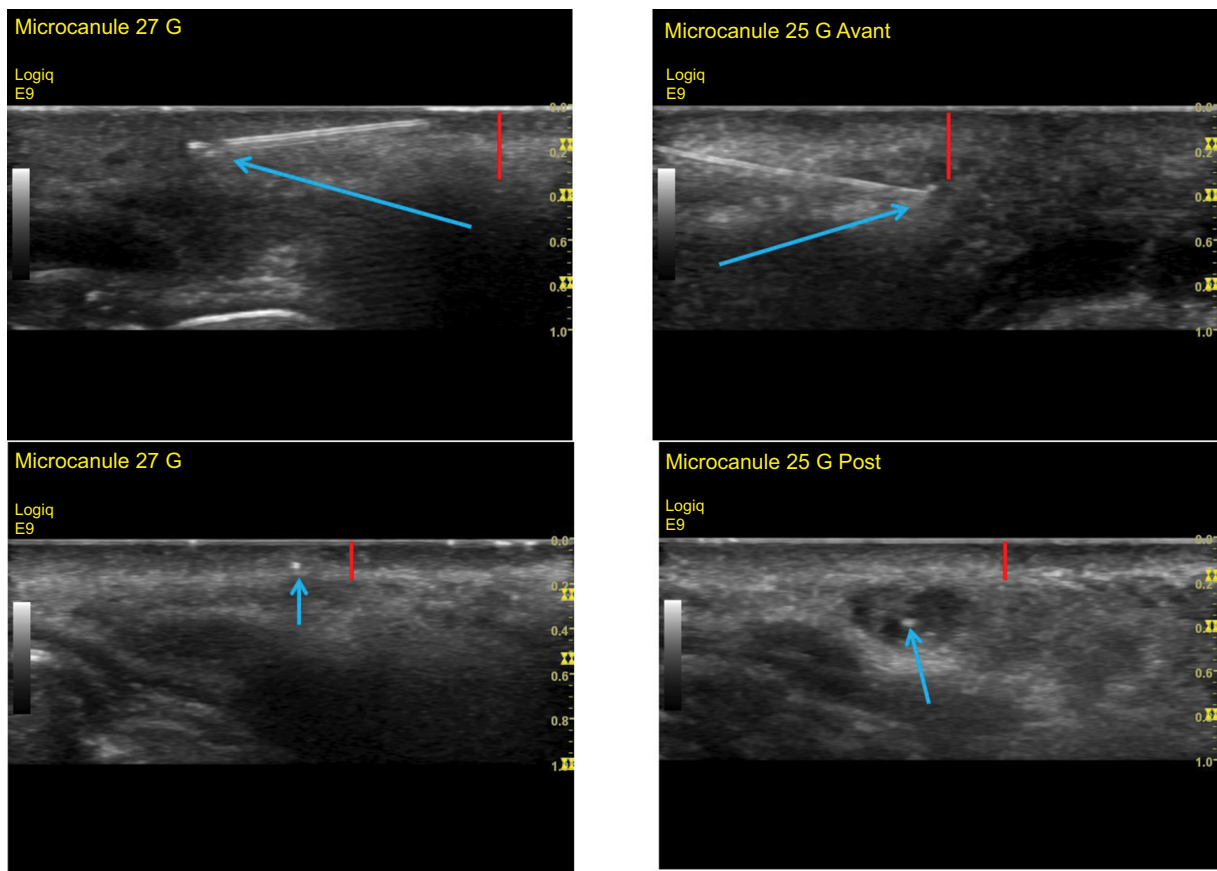
## Materials and methods

This study was conducted in compliance with the Declaration of Helsinki, Good Clinical Practices, and local regulatory requirements. No ethics approval was required as the scans were performed as additional examinations during routine follow-up and did not involve interventional treatment. All subjects provided written informed consent.

## Injection procedure

The HA filler used in this study was 26 mg/mL of CPM volumizing gel (Belotero® Volume; Anteis SA, Geneva, Switzerland). The six subjects were injected by the same physician with a blunt micro-cannula 25 G/40 mm or 27 G/37 mm Magic Needle® (Needle Concept, Paris, France) in fat tissue using a retrograde injection technique (Figure 1).

For each subject in the CE registration study, two prefilled syringes of 2 mL of CPM HA gel were provided as determined in the study protocol: one syringe for the first treatment and a second syringe for an optional touch-up injection. The touch-up injection could be performed at Day 90 but not later than Day 120. The last follow-up appointment was at 18 months. For the private patients, two or more prefilled syringes of 2 mL were injected.



**Figure 1** HA gels can be injected in the deep reticular dermis with a 27 or 25 G microcannula.  
**Notes:** Light blue arrows indicate position of HA gel, and red line indicates depth of dermis.  
**Abbreviation:** HA, hyaluronic acid.

## Imaging protocol

MRI images were acquired with the Achieva 1.5 Tesla (Philips SA Health Systems, Gland, Switzerland). This device has a 3D volume acquisition protocol, which can be used to measure the injected HA volume as well as HA volume remaining at a later date. Acquisition times were 4–5 minutes. The following 3D MRI sequences were used to detect HA gel without a requirement for contrast medium: fluid-attenuated inversion recovery (FLAIR), a technique that suppresses the signal from fluid and thus reinforces the signal from the HA filler, it also has low sensitivity to magnetic field heterogeneities; Echo Gradient (EG) T1-weighted 3D images (3D-T1) to highlight subcutaneous fatty tissue, this sequence has quick density acquisition with easy three-dimensional reconstruction; and T2-weighted 3D images (3D-T2) with fat saturation (FS) to suppress the signal from subcutaneous fat, which appears dark. With FLAIR and 3D-T2 FS sequences, the HA gel appears bright, whereas with the EG 3D-T1 sequence, it appears dark.

MRI image quality can be dramatically degraded by artifacts caused by dental materials distorting the magnetic field and compromising image interpretation.<sup>12</sup> On

MRI, dental implants result in susceptibility artifacts, which can obscure the HA or obscure the anatomy of the area examined, with the size of the artifact related to the magnetic permeability of the dental material. In addition to the implant material, the age of the implant can influence the size and intensity of the susceptibility artifact. When assessing MRI images, only sides of the face free of dental implants or with modern dental implants were examined. In addition, the size of the artifact was graded from –, +, ++, and +++, where – indicated no artifact and +++ indicated a large artifact.

Patients unwilling to undergo an MRI underwent a CT scan (Philips CT Brilliance 64; Philips SA Health Systems, Gland, Switzerland). This device has a helicoidal acquisition with bone and soft tissue reconstruction (3DReco).

## Results

This case series reported on six subjects who were injected with CPM HA gel for the correction of age-associated facial volume loss: three from the CE registration study and three private subjects. Two of the private subjects were HIV positive: one was not receiving any treatment and one was

receiving tritherapy with antiretroviral drugs. The mean age at the time of injection was 60 years (range 46–68 years). The three subjects from the CE registration study were women with a mean age of 66 years (range 64–69 years). The three private patients were all male and had a mean age of 52 years (range 46–57 years). Table 2 summarizes the subjects' treatment history including injection area, volume injected, and injection technique. Subject 1 suffered from claustrophobia and underwent a CT scan. MRI was performed in all the remaining subjects. Subjects 2 and 3 had older type dental implants and, therefore, were only assessed on the side of the face free of implants. Subjects 4–6 had modern implants, and both sides of the face were analyzed.

All three MRI sequences used in this study (FLAIR 3D, EG 3D-T1, and 3D-T2 FS) showed good definition and delimitation of the injected HA gel. However, the contrast

between the injected product and the surrounding structures was better on the 3D-T2 FS sequences. None of the subjects showed any MRI or CT scan evidence of an intense inflammatory reaction, as would be expected in the case of an abscess or granuloma.

## Case series

### Case I

In Subject 1, CPM HA was injected in the left and right cheek hollows in 2010 and it was estimated that over 80% of gel remained in the right cheek hollow and over 90% in the left cheek hollow 4 years later in 2014 (Table 3). Some material was visible in the nasolabial area, probably as a result of an additional filler injection performed in February 2014. Images of Subject 1 before treatment and 48 months after treatment are shown in Figure 2.

**Table 2** Treatment history of the six subjects injected with CPM HA volumizing gel

Subject	Date	Treated area Injection volume (mL)	Total injection volume (mL)	Needle/cannula Injection technique
CE registration study patients				
1	First treatment February 27, 2010	Cheek hollows Right: 0.80 Left: 1.20	Cheek hollows Right: 1.10 Left: 1.70	27 G cannula Retrograde fan technique
	Touch-up June 17, 2010	Cheek hollows Right: 0.30 Left: 0.50		27 G cannula Retrograde fan technique
2	First treatment August 25, 2010	Cheek bones Right: 0.80 Left: 0.80 Upper NLF Right: 0.20 Left: 0.20	Cheek bones Right: 0.80 Left: 0.80 Upper NLF Right: 0.20 Left: 0.20	27 G cannula Retrograde fan technique
3	First treatment June 21, 2010	Cheek hollows Right: 0.80 Left: 1.20	Cheek hollows Right: 1.60 Left: 2.40 Mental crease: 0.30 Tear trough Right: 0.50 Left: 0.50	27 G cannula Retrograde fan technique
	Second treatment November 6, 2012	Cheek hollows Right: 0.80 Left: 1.20 Cheek bones Right: 0.70 Left: 0.70 Mental crease: 0.30  Tear troughs Right: 0.50 Left: 0.50		27 G sharp needle Point by point 27 G cannula Retrograde fan technique
	Third treatment February 17, 2014	Jolidermis® Volume Cheek bones Right: 1.00 Left: 1.00	Cheekbones Jolidermis® Volume Right: 1.70 Left: 1.70	27 G cannula Retrograde fan technique

(continued)

**Table 2** (continued)

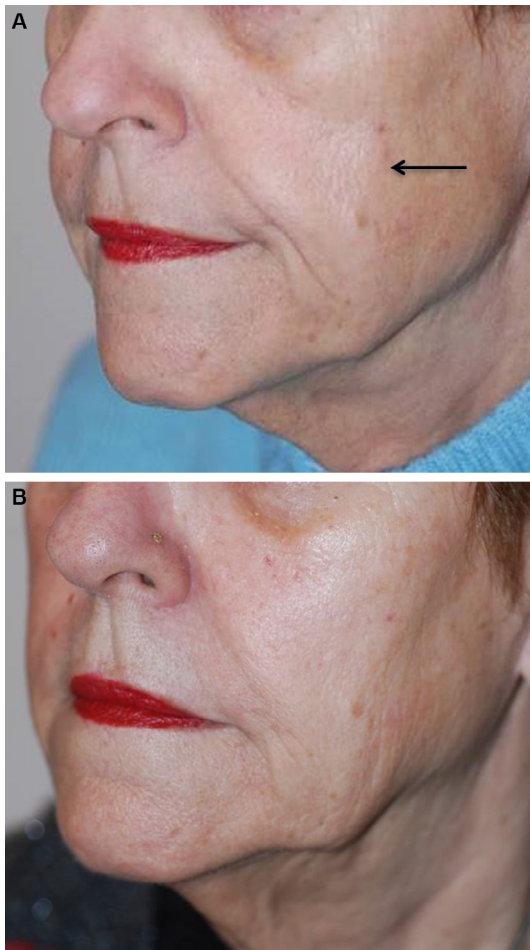Subject	Date	Treated area Injection volume (mL)	Total injection volume (mL)	Needle/cannula Injection technique
Private patients				
4	First treatment November 4, 2013	Cheek hollows Right: 0.80 Left: 0.80 Cheek bones Right: 0.20 Left: 0.20	Cheek hollows Right: 0.80 Left: 0.80 Cheek bones Right: 1.20 Left: 1.20	25 G cannula Retrograde fan technique 25 G cannula Bolus technique
	Second treatment November 18, 2013	Cheek bones Right: 1.00 Left: 1.00		25 G cannula Retrograde fan technique
5	First treatment December 16, 2010	Cheek hollows Right: 0.70 Left: 0.70 Tear troughs Right: 0.10 Left: 0.10 NLF Right: 0.20 Left: 0.20	Cheek hollows Right: 3.00 Left: 3.00 Tear troughs Right: 0.20 Left: 0.20 NLF Right: 0.60 Left: 0.60	25 G cannula Retrograde fan technique 25 G cannula Retrograde linear technique 25 G cannula Retrograde linear technique
	Second treatment February 24, 2011	Cheek hollows Right: 1.60 Left: 1.60 NLF Right: 0.20 Left: 0.20		27 G cannula Retrograde fan technique 25 G cannula Retrograde linear technique
	Third treatment September 1, 2011	Cheek hollows Right: 0.70 Left: 0.70 Tear troughs Right: 0.10 Left: 0.10 Upper NLF Right: 0.20 Left: 0.20		27 G cannula Retrograde fan technique 27 G cannula Retrograde linear technique 25 G cannula Retrograde linear technique
6	First treatment February 28, 2010	Cheek hollows Right: 2.00 Left: 2.00	Cheek hollows Right: 2.00 Left: 2.00 Cheek bones Right: 0.70 Left: 0.70 Marionette lines Right: 0.30 Left: 0.30	27 G cannula Retrograde fan technique
	Second treatment June 27, 2012	Cheek bones Right: 0.70 Left: 0.70 Marionette lines Right: 0.30 Left: 0.30		27 G cannula Retrograde fan technique

**Abbreviations:** CPM, Cohesive Polydensified Matrix®; HA, hyaluronic acid; NLF, nasolabial fold.

**Table 3** Amount of product injected and estimated remaining amount (mL)

	Magnetic susceptibility artifact			Total amount injected (mL)	Estimated remaining amount (mL)
	Flair	EG 3D-T1	3D-T2 FS		
Subject 1	NA	NA	NA		
Cheek hollow					
Right				1.10	0.90
Left				1.70	1.60
Subject 2	R-/L+++	R+/L++	R-/L+		
Cheek bone					
Right				0.80	–
Left				0.80	0.20
Upper NLF					
Right				0.20	–
Left				0.20	0.15
Subject 3	R+++/L–	R++/L–			
Cheek hollow					
Right				1.60	2.10
Left				2.40	–
Mental crease				0.30	
Cheek bone					
Right				1.70	1.40
Left				1.70	–
Tear trough					
Right				0.50	0.41
Left				0.50	–
Subject 4	R++/L+++	R+++/L+++	R++/L+++		
Cheek hollow					
Right				0.80	0.70
Left				0.80	0.65
Cheek bone					
Right				1.20	1.15
Left				1.20	0.80
Subject 5	R++/L++	R+++/L+++	R++/L++		
Cheek hollow					
Right				3.00	2.50
Left				3.00	2.00
NLF					
Right				0.60	0.60
Left				0.60	0.70
Tear trough					
Right				0.20	0.30
Left				0.20	0.40
Subject 6	R+++/L+++	R+++/L+++	R+++/L+++		
Cheek hollow					
Right				2.00	1.60
Left				2.00	1.70
Cheek bone					
Right				0.70	0.50
Left				0.70	0.40
Marionette lines					
Right				0.30	0.10
Left				0.30	0.10

**Abbreviation:** 3D-T1, T1-weighted 3D images; 3D-T2, T2-weighted 3D images; FS, fat saturation; NA, not applicable; NLF, nasolabial fold; –, no treatment.



**Figure 2** Subject 1 before treatment (A) and 48 months (B) after injection of CPM HA volumizing gel.

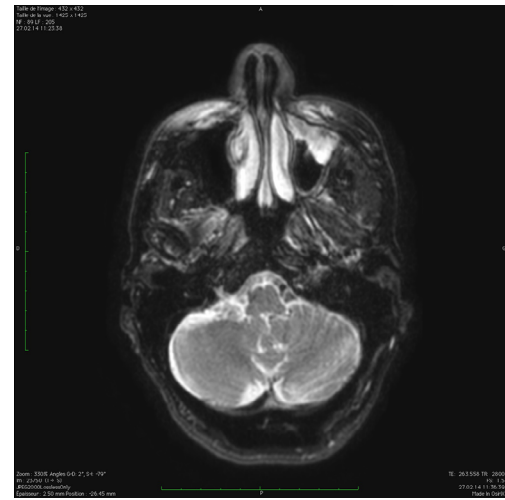**Abbreviations:** CPM, Cohesive Polydensified Matrix®; HA, hyaluronic acid.

### Case 2

In Subject 2, a large amount of HA was visible in the nasolabial folds, possibly due to additional treatment in 2014. A slight extension of the product was visible in the subcutaneous fat of the cheek, and also a slight extension of the product along branches of the facial vein and artery on the left side of the face (Figure 3).

### Case 3

As a part of the CE registration study, Subject 3 received 0.8 mL of CPM HA gel in the right cheek hollow and 1.2 mL in the left cheek hollow in 2010. On completion of the CE registration study in 2012, Subject 3 received further CPM HA injections in the tear trough, cheek hollow, cheek bone, and mental crease. In 2014, Subject 3 had treatment with another HA volumizing gel in both cheek bones receiving 1 mL each side. The estimated volume of HA gel on the 2014 MRI scans was greater than the original amount of filler



**Figure 3** Axial T2 image showing HA in nasolabial folds.

**Notes:** A slight extension of the product in the subcutaneous fat of the cheek and along branches of the facial vein and artery on the left side of the face can also be observed.

**Abbreviation:** HA, hyaluronic acid.

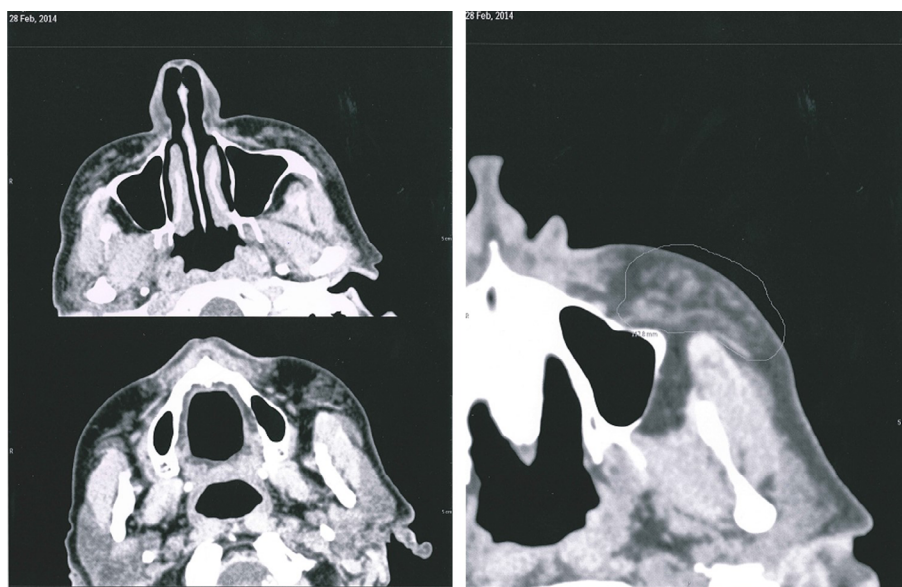
injected in 2010. This may be explained by the additional injections the subject received. For example, the gel injected in the tear trough may have diffused to the cheek hollows. In addition, HA is hydrophilic in nature and the final injections may have led to some mild swelling. In this subject, the HA gel did not spread into the hypodermis or along the vessels.

### Case 4

Subject 4 received CPM HA in the cheek hollows and cheek bones in 2013 and a further treatment in the nasolabial folds just prior to the MRI examination in 2014 (Table 2). MRI volumetric analysis showed more material remaining on the right side compared to on the left side, both in the cheek hollows and cheek bones. Diffusion of the gel into the deep fat compartment was observed, particularly on the left side (Figure 4). This may have been due to subcutaneous injection in the nasolabial folds. A small amount of product was also found to have diffused along the vessels.

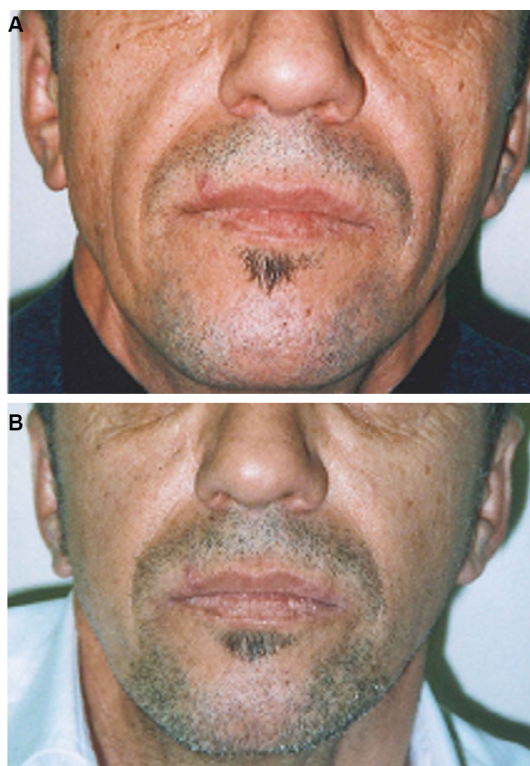### Case 5

Subject 5 received large volumes of CPM HA between 2010 and 2011 as well as treatment of the tear troughs and nasolabial folds with an additional CPM HA gel (CPM Intense) in March 2013. Images before and 15 months after treatment are shown in Figure 5. The gel may have diffused in the area of the cheek hollow because of facial movements in this area, which might explain the larger amounts measured in the right cheek hollow in 2014. Diffusion of the HA gel to the deep fat compartment and along the vessels was visible, most notably on the left side (Figure 6).



**Figure 4** Axial T2 images with fat signal removed.

**Notes:** In the right panel, the injected product residue is circled. Diffusion of the gel into the deep fat compartment was observed, particularly on the left side. This may have been due to subcutaneous injection in the nasolabial folds. A small amount of product was also found to have diffused along the vessels.

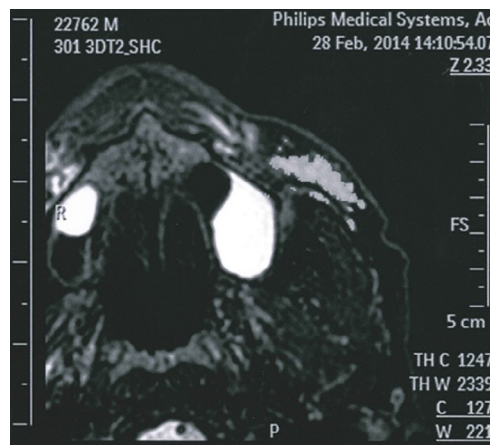


**Figure 5** Subject 5 before treatment (A) and 15 months (B) after injection of CPM HA volumizing gel.

**Abbreviations:** CPM, Cohesive Polydensified Matrix®; HA, hyaluronic acid.

**Case 6**

In Subject 6, large amounts of material were visible. A small amount had diffused to the deep fat compartment but not along the vessels. It is noteworthy that the subject had been



**Figure 6** Axial T2 image of Subject 5 showing diffusion of HA gel into the deep fat compartment and along the vessels, most notably on the left side.

**Abbreviation:** HA, hyaluronic acid.

treated with calcium hydroxylapatite in the temple area in 2013 and had undergone a blepharoplasty.

**Discussion**

The data from this case series indicate that CPM HA volumizing gel was still identifiable on MRI and CT scans between 1 and 4 years after initial injection. In Subjects 1 and 2, in whom no repeat injections were performed following their initial treatment in 2010, a high proportion of the gel was estimated to be remaining on their MRI or CT scans in 2014 following injections in the cheek hollows and upper nasolabial fold. Material was also visible following injection of the cheek bones although to a lesser amount.

The data from Subject 3 were more difficult to interpret as injections were performed in 2010 and 2012, as well as a third treatment in 2014 with a different HA volumizer. When only the cheek hollows were considered, which were treated in 2010 and 2012 with CPM HA volumizer, the amount of product estimated to be remaining in the right cheek hollow in 2014 was 2.10 mL compared with a total amount injected of 1.60 mL. There are several possible explanations for this HA volume increase. HA is hydrophilic in nature, and mild swelling may have been caused by the gel's hygroscopic properties; both HA and bound water have similar signals on MRI making their differentiation difficult. Subject 3 also received injection in the tear trough in 2012, which may have diffused to the cheek hollows and contributed to the increase in volume. Diffusion of HA gel to deeper fat compartments was also observed in the three private practice subjects treated with CPM HA volumizer and has been demonstrated in another study of subjects with HIV-associated lipoatrophy as well as in a comparative study of two volumizing HA gels injected with two different techniques.<sup>6,7</sup> It has been suggested that the diffusion may be a consequence of the anatomy of the thin septae between the fat compartments, which do not appear to form a fully effective barrier.<sup>6</sup>

The current study adds to the data in the literature on the longevity of CPM HA volumizer. A previous serial MRI study in subjects with HIV-associated lipoatrophy demonstrated that the MRI signal intensity for HA and bound water remained constant over the 12-month observation period following subdermal submalar injections.<sup>6</sup> In a split-face study in which CPM HA was compared with another HA volumizer, optimal correction for both products was observed at Month 3 with sustained volume augmentation up to Month 18 in some patients.<sup>8</sup> Sustained volume augmentation with CPM HA was also demonstrated in a postmarketing study of subjects with intermediate-to-severe volume loss in their lateral cheek hollows or cheek bone area, with treatment effects lasting for at least 12 months.<sup>7</sup>

In the current study, the absence of pretreatment imaging precluded quantitative evaluation of any inflammatory reaction or reactive edema. However, in the six subjects examined, the gel was well tolerated with no evidence of any abscess or granula formation.

This study was initiated following the discovery that one patient from the CE registration study had a large amount of CPM HA visible on an MRI scan performed several years after the initial injection. As a result, no pretreatment images were available and some patients had had HA treatments in the intervening time period. In addition, no post-treatment

MRI images were available, which would have allowed us to evaluate the hygroscopic properties of CPM HA. The presence of older dental implants in some patients also limited the number of anatomic areas that could be studied because of magnetic susceptibility artifacts. Nevertheless, despite these limitations and the small number of subjects, our case series supplements previous findings on the longevity of CPM volumizing HA gel when injected subcutaneously or in deep soft tissue.

## Conclusion

Images from MRI and CT scans indicate that CPM HA gel persists for 2–4 years from the time of injection. In some patients, diffusion of the gel to deeper fat compartments had occurred. There was no MRI or CT evidence of abscess or granuloma formation.

## Acknowledgments

This study was sponsored by Merz Pharmaceuticals GmbH, Frankfurt-am-Main, Germany. The authors would like to acknowledge MedImage, RX Institute, Geneva, Switzerland, for their valuable collaboration, Aurélie Brissaud, a radiologist technician at MedImage for her help and collaboration, Samuel Gavard, for his help and explanations, and the study subjects for their participation in this explorative study.

## Disclosure

Dr PM is a consultant or trainer for Allergan, Galderma Switzerland, Merz Aesthetics, and Teoxane. Dr JV is a consultant or trainer for Merz Aesthetics and Advanced Aesthetic Technologies. The other author reports no conflicts of interest in this work.

## References

1. Fitzgerald R, Graivier MH, Kane M, et al. Update on facial aging. *Aesthet Surg J*. 2010;30(Suppl):11S–24.
2. Bugge H, Negaard A, Skeie L, Bergersen B. Hyaluronic acid treatment of facial fat atrophy in HIV-positive patients. *HIV Med*. 2007;8(8):475–482.
3. Carruthers JD, Glogau RG, Blitzer A, Facial Aesthetics Consensus Group Faculty. Advances in facial rejuvenation: botulinum toxin type a, hyaluronic acid dermal fillers, and combination therapies--consensus recommendations. *Plast Reconstr Surg*. 2008;121(5 Suppl):5S–30.
4. Pignatti M, Pedone A, Baccarani A, et al. High-density hyaluronic acid for the treatment of HIV-related facial lipoatrophy. *Aesthetic Plast Surg*. 2012;36(1):180–185.
5. Micheels P, Ascher B, Beilin G. Evaluation clinique de l'efficacité et de la tolérance d'un acide hyaluronique volumateur de technologie CPM® pour le traitement de multiples zones du visage [Clinical efficacy and safety evaluation of a CPM technology volumizing hyaluronic acid gel for the treatment of multiple zones of the face]. *Réalités Thérapeutiques en Dermato-Vénérologie*. 2014;135(9):cahier 3.
6. Becker M, Balagué N, Montet X, et al. Hyaluronic Acid Filler in HIV-Associated Facial Lipoatrophy: Evaluation of Tissue Distribution and Morphology with MRI. *Dermatology*. 2015;230(4):367–374.

7. Micheels P, Vandeputte J, Kravtsov M. Treatment of age-related mid-face atrophy by injection of cohesive polydensified matrix hyaluronic acid volumizer. *J Clin Aesthet Dermatol*. 2015;8(3):28–34.
8. Kerscher M, Agsten K, Kravtsov M, Prager W. Effectiveness evaluation of two volumizing hyaluronic acid dermal fillers in a controlled, randomized, double-blind, split-face clinical study. *Clin Cosmet Investig Dermatol*. 2017;10:239–247.
9. Micheels P. Présentation ultrasonographique des profondeurs d'injection dans le comblement des rides, congrès MAEX-2013 Bruxelles-Belgique. [Injection excellence with Belotero: ultrasound presentation of injection depths for filling wrinkles]. Merz Aesthetics Expert Summit (MAEXS); November 16–17, 2013; Paris, France. French.
10. Micheels P. Presentation of injection depth. XXIVas Jornadas Mediterraneas de confrontaciones terapeuticas en medicina y cirugía cosmetica. May 6–8, 2016; Sitgès, Barcelona, Spain.
11. Micheels P. Superficial reticular dermis injection / mid reticular dermis injection. 14th International Congress of Mesotherapy; Nov 11–13, 2016; Paris, France.
12. Klinke T, Daboul A, Maron J, et al. Artifacts in magnetic resonance imaging and computed tomography caused by dental materials. *PLoS One*. 2012;7(2):e31766.
13. Sundaram H, Rohrich RJ, Liew S, et al. Cohesivity of hyaluronic acid fillers: development and clinical implications of a novel assay, pilot validation with a five-point grading scale, and evaluation of six U.S. Food and Drug Administration-approved fillers. *Plast Reconstr Surg*. 2015;136(4):678–686.
14. Micheels P, Sarazin D, Tran C, Salomon D. Effect of different crosslinking technologies on hyaluronic acid behavior: a visual and microscopic study of seven hyaluronic acid gels. *J Drugs Dermatol*. 2016;15(5):611–617.
15. Gavard Molliard S, Albert S, Mondon K. Key importance of compression properties in the biophysical characteristics of hyaluronic acid soft-tissue fillers. *J Mech Behav Biomed Mater*. 2016;61:290–298.

## Clinical, Cosmetic and Investigational Dermatology

Dovepress

### Publish your work in this journal

Clinical, Cosmetic and Investigational Dermatology is an international, peer-reviewed, open access, online journal that focuses on the latest clinical and experimental research in all aspects of skin disease and cosmetic interventions. This journal is included on PubMed. The manuscript management system is completely online

and includes a very quick and fair peer-review system, which is all easy to use. Visit <http://www.dovepress.com/testimonials.php> to read real quotes from published authors

Submit your manuscript here: <https://www.dovepress.com/clinical-cosmetic-and-investigational-dermatology-journal>