

Sofosbuvir–daclatasvir improves hepatitis C virus–induced mixed cryoglobulinemia: Upper Egypt experience

Amro M Hassan,¹ Heba A Osman,² Hasan S Mahmoud,² Mohammed H Hassan,³ Abdel-Kader A Hashim,⁴ Hesham H Ameen⁵

¹Tropical Medicine Department, Faculty of Medicine, Al-Azhar University (Assiut Branch), Assiut, Egypt; ²Tropical Medicine and Gastroenterology Department, Faculty of Medicine, South Valley University, Qena, Egypt; ³Department of Medical Biochemistry, Faculty of Medicine, South Valley University, Qena, Egypt; ⁴Department of Internal Medicine, Faculty of Medicine, South Valley University, Qena, Egypt; ⁵Clinical Pathology Department, Faculty of Medicine Al-Azhar University (Assiut Branch), Assiut, Egypt

→ Video abstract



Point your Smartphone at the code above. If you have a QR code reader the video abstract will appear. Or use: <http://youtu.be/m1tw0cfXGM>

Correspondence: Mohammed H Hassan Biochemistry, Qena Faculty of Medicine, South Valley University, 83523 Qena, Egypt
Tel +20 109 847 3605
Email mohammedhosnyhasaan@med.svu.edu.eg

Background and aims: Hepatitis C virus (HCV) infection is associated with extrahepatic manifestations such as cryoglobulinemia and accounts for up to 90% of all cases of mixed cryoglobulinemia (MC). The present study aimed to evaluate the effect of sofosbuvir–daclatasvir therapy on symptomatic HCV-related MC and sustained virologic response (SVR) achievement.

Patients and methods: This prospective cohort study was carried out on 120 patients with chronic HCV infection, clinically suspected to have MC, but only 63 of whom were positive for cryoglobulins. HCV-MC patients were treated with sofosbuvir 400 mg and daclatasvir 60 mg once daily for 3 months. The serum cryoglobulins levels, complement 3 (C3), complement 4 (C4) (using ELISA assay kits) and rheumatoid factor (RF) (using immunoturbidimetric assay kit), were measured in the included HCV infected patients (to confirm HCV-MC diagnosis), in addition to quantitative HCV-RNA assays, using real time PCR. All these measurements have been done before starting therapy and 12, 24 weeks post-therapy for assessments of immunological recovery, viral load and SVR.

Results: Significant increase in the serum cryoglobulin levels and RF with significant decrease in C3 and C4 serum levels were detected in only 63 out of 120 included HCV infected patients, upon whom the study has been completed. They showed significant decrease in their mean cryoglobulin levels from 41.47 µg/mL ±12.32 SD to 5.12 µg/mL ±3.59 SD then to 5.09 µg/mL ±3.02 SD, 12 to 24 weeks post-therapy respectively ($p < 0.001$), with significant decline in RF concentrations and rise in C3 and C4 serum levels approaching the normal values. There were improvements in the presenting HCV-MC clinical manifestations in variable degrees, ranging from 5 (71.42%) in patients with glomerulonephritis to 62 (98.4%) in patients with purpura. Eighty-seven percent of the included patients showed complete response (clinical, virological and immunological recovery) and 13% showed partial response (virological and immunological recovery without clinical improvement of cryoglobulinemia associated manifestations).

Conclusion: A combined therapy of sofosbuvir 400 mg and daclatasvir 60 mg once daily for 3 months was associated with a significant decrease in serum cryoglobulin levels and appears as a reasonable treatment option for HCV-associated MC.

Keywords: directly acting antiviral drugs, mixed cryoglobulinemia, HCV

Introduction

Hepatitis C virus (HCV) infection is considered one of the major worldwide health challenges, with an estimated prevalence of more than 177.5 million of HCV-infected adults.¹ Egypt is among the countries with the highest prevalence of HCV in the world, with 5.3 million persons testing positive for HCV antibodies, of whom 3.7 million were HCV-RNA positive.²

HCV infection has been recognized as a common cause of mixed cryoglobulinemia (MC), which could be asymptomatic, and circulating mixed cryoglobulins have been

detected in 40%–60% of patients with chronic HCV.^{3,4} The exact mechanism by which HCV induces MC is still undetermined but may be related to the continuity of HCV in the immune cells and/or chronic immune response stimulation by HCV.⁵ Human leukocyte antigens may also be involved.⁶

MC is characterized by the detection of abnormal proteins, called cryoglobulins, because they are reversibly precipitated in serum below 37°C.⁷ These cryoprecipitable immune complexes are deposited in small- and medium-sized blood vessels, resulting in systemic vasculitis. MC is classified into type I (exclusive IgM monoclonal), type II (IgM monoclonal and IgG polyclonal), and type III (exclusively IgG polyclonal).⁸ Cryoglobulins of types II and III (antigen-antibody complexes) are accompanied by rheumatoid factor (RF), complement activation with subsequent complement consumption, and thereby cause vasculitis^{9,10} while type I is not accompanied by RF or immune complexes, and thus there is no activation of complement, resulting in lower incidence of vasculitis.¹¹ The role of RF in the immune response is undetermined, but it could participate in immune complex clearance by making complexes larger and activating the complement.¹¹

In HCV infection, MC is one of the most frequent extrahepatic manifestations and can cause variable clinical presentations in the form of purpura, weakness, arthralgia, neuropathies, glomerulonephritis, and involvement of other organs.¹²

Before the advent of direct-acting antivirals (DAAs), interferon (IFN)-based regimens produced clinical recovery with subsequent improvement of MC as a result of HCV clearance; however, the side effects of IFN may mimic the MC manifestations, and the relapse rate with IFN-based regimens was high.¹³ Boglione et al¹⁴ reported a study on the treatment of HCV-MC with IFN-free regimens, with or without ribavirin, and concluded that IFN-free regimens were effective and well tolerated in treating HCV-MC and significantly promoted a decrease in cryoglobulins.

There are few data regarding the effect of sofosbuvir–daclatasvir regimen on hepatitis C–related MC, that is increasingly important. Therefore, the present study has been conducted to evaluate the effect of sofosbuvir–daclatasvir as DAAs on symptomatic MC and the percentage of sustained virologic response (SVR) using such combined DAAs therapy among chronic HCV-infected patients.

Patients and methods

Study design and participants

The present prospective cohort study was conducted on 120 chronic HCV-infected patients with the clinical inclusion criteria for MC,¹⁵ purpura, arthralgia, and asthenia (Meltzer's

triad), and only 63 patients were found positive for circulating cryoglobulins with a definite diagnosis of MC, on whom the study has been completed. The patients were recruited from Tropical Medicine and Gastroenterology Departments and Internal Medicine Departments, Qena and Al-Azhar University (Assiut branch) Hospitals-Egypt, which are major tertiary referral centers in Upper Egypt, after obtaining ethical approval from the University Hospital Ethics Committee and an informed written consent from every included patient. This was in addition to 20 – age and sex matched – healthy volunteers selected as controls, on whom serum cryoglobulins assays were done to be comparable with the patients. The study period was from January 1, 2016, to January 1, 2018. All patients were diagnosed and treated with sofosbuvir 400 mg and daclatasvir 60 mg ± ribavirin (800–1,200 mg) once daily for 3 months. Patients were treated according to the Egyptian protocol for treatment of chronic HCV virus infection, which depends on the European Association for the Study of the Liver 2015 guidelines for HCV infection treatment.¹⁶ Pregnancy or presence of dynamic CT imaging of HCC or uncontrolled DM; HbA1c >9%, were excluded from the study. All patients were subjected to complete history taking and full clinical examination including Child-Pugh score and manifestations of MC.

Investigatory workup

- Six milliliter of venous blood was collected from each patient and control under aseptic precautions, of which 2 mL of blood was placed in EDTA containing a vacutainer tube to obtain a complete blood picture in the automated hematology analyzer cell dyne-1800 (Abbott Diagnostics, Lake Forest, IL, USA). Four milliliters of blood was taken in a plain glass tube, and after clotting, the tube was centrifuged at 3,000 rpm for 5 min. Then, the serum was separated for use in estimating liver function (including liver enzymes, albumin, bilirubin-total and direct, prothrombin time, prothrombin concentration, and INR), serum creatinine, protein:creatinine ratio, and RF using Cobas c311 automated chemistry analyzer (Roche Diagnostics, Mannheim, Germany). HBs Ag, HIV antibody, anti-HCV, HCV-RNA levels, cryoglobulins, and complement 3 (C3) and complement 4 (C4) serum assays were done. eGFR was calculated using the Mayo Clinic Quadratic Equation,¹⁷ and urine analysis was done for the included patients.
- RF was measured using an immunoturbidimetric assay kit based on the immunological agglutination principle with enhancement of the reaction by latex, supplied by Roche Diagnostics, catalog No. c501/502. The normal reference range is 0–20 IU/mL.

- Anti-HCV, HBs Ag and HIV antibody testing were performed using commercially available assays (Abbott Laboratories, Abbot Park, IL, USA).
- HCV-RNA was detected by a PCR assay (Cobas Amplicor Roche Molecular Systems Inc., Branchburg, NJ, USA), and serum HCV-RNA levels were quantified by the Cobas Ampli Prep/Cobas TaqMan HCV-RNA assay (Roche Diagnostics) with a lower detection limit at 15 IU/mL.
- The biochemical assessments of cryoglobulin levels C3 and C4 were done using commercially available enzyme-linked immunosorbent assay (ELISA) kits according to the manufacturer's protocol; these kits were supplied by Chongqing Biospes Co., Ltd., Chongqing, People's Republic of China, catalog no. (BYEK2304, BYEK1247, BYEK1247), respectively, using ELISA Multiskan EX Microplate Photometer [STAT FAX-2100; Thermo Scientific, Waltham, MA, USA]. The normal reference ranges for C3 and C4 are 90–180 and 10–40 mg/dL, respectively.
- Fibroscan assessments of the liver fibrotic state,¹⁸ using a fibroscan (FS-502 touch device, Echosens, Paris, France), were done to all included patients, yielding the extent of hepatic fibrosis in a semiquantitative manner as F0-F4.
- All the previously mentioned investigatory workups, in addition to the evaluation of the clinical manifestations of MC, were done to the included patients before starting therapy, at the 12th and 24th weeks posttreatment.
- Renal biopsy for histopathological and immunohistochemical examination was done in patients with clinically suspected glomerulonephritis (proteinuria, hematuria, and/or reduced [eGFR] <60 mL/min/1.73 m²) to confirm the diagnosis of HCV-associated cryoglobulinemic glomerulonephritis.

Therapeutic efficacy points

The judging points regarding the efficacy¹⁹ of sofosbuvir and daclatasvir in improving the condition of HCV-MC patients were as follows:

1. Clinical improvement of the presenting cryoglobulinemic-related manifestations.
2. SVR12, which is defined as undetectable HCV-RNA levels 12 weeks after cessation of treatment.²⁰
3. Disappearance of cryoglobulins in serum.

According to the presence or absence of the 3 previously mentioned criteria, the effect of the used DAAs can be classified into 3 types: complete response if all 3 parameters have been achieved, partial response if SVR12 and SVR24 with

either of the remaining 2, and no response if none of the 3 parameters have been achieved.

Statistical analysis

The data were coded and verified prior to data entry. Computer program Statistical Package for Social Sciences (ver.21) (IBM Corporation, Armonk, NY, USA) was used for analyzing the collected data and for drawing figures. Data were expressed as mean \pm SD and numbers as percentage. Student's *t*-test was used to determine the significance of the numeric variable. *P*-value is considered significant if *P*<0.05 and not significant if *P*>0.05.

Results

Among the 120 included naïve chronic HCV-infected patients with a clinical suspicion of having MC, 57 patients were found negative for cryoglobulins, with their quantitative data of cryoglobulinemia as follows (mean \pm SD of serum cryoglobulins, C3, C4, and RF were 3.5 \pm 2.12 μ g/mL, 97.3 \pm 12.7 mg/dL, 21.5 \pm 3.2 mg/dL, and 5.7 \pm 2.8 IU/mL, respectively). These 57 were excluded from the study, and the study was completed on the 63 patients who proved to have MC by testing positive for serum cryoglobulins. The mean age of the included HCV-MC patients was 54.2 years \pm 8.4 SD; 38 (60.32%) of them were females. All the included patients received the sofosbuvir and daclatasvir therapeutic regimen. From the relative frequencies of the presenting clinical manifestations shown in Table 1, peripheral neuropathy was the most frequent manifestation. Bilateral purpuric lower limb skin lesions due to HCV-MC–induced vasculitis on one of the included patients are shown in Figure 1. Regarding the fibroscan assessments of the cryopositive patients included, 17 (27%) of them were F0-F1, 25 (40%) were F2, 13 (20.5%) were F3, and 8 (12.5%) were F4 with evidence of cirrhosis.

Table 1 Relative frequencies of the presenting clinical manifestations and effect of sofosbuvir and daclatasvir therapy in patients with HCV-MC

Clinical presentations, ^a total N=63	Frequency of affected patients, N (%)	Frequency of improved patients, N (%)
Meltzer's triad	63 (100)	55 (87)
Peripheral neuropathy	33 (52.3)	28 (84.4)
Purpura	63 (100)	62 (98.4)
Glomerulonephritis	7 (11.1)	5 (71.42)

Notes: ^aPatient may present with more than 1 manifestation. Meltzer's triad (purpura, arthralgia, asthenia).

Abbreviation: HCV-MC, hepatitis C virus mixed cryoglobulinemia.

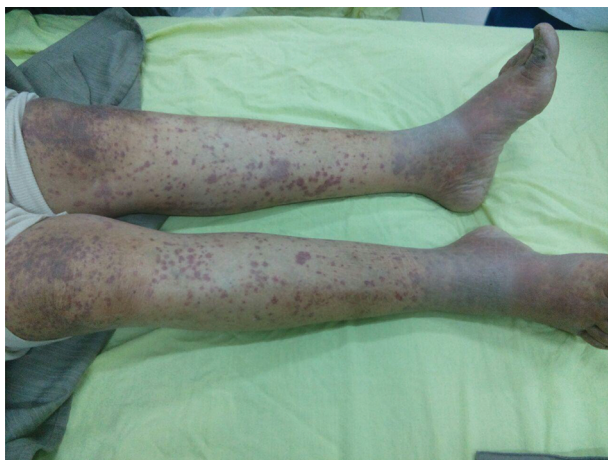

Figure 1 Bilateral purpuric lower limb skin lesions due to HCV-MC-induced vasculitis in one of the included patients.

Abbreviation: HCV-MC, hepatitis C virus mixed cryoglobulinemia.

The mean serum levels of cryoglobulins among HCV-MC was $41.47 \mu\text{g/mL} \pm 12.32 \text{ SD}$ versus $3.33 \mu\text{g/mL} \pm 1.51 \text{ SD}$ among the controls with significant difference ($P < 0.001$) (Figure 2).

Regarding the clinical effects of sofosbuvir and daclatasvir therapy on HCV-MC, which are shown in Table 1, the patients showed significant improvement in their clinical manifestations, especially those presenting with peripheral neuropathy and purpura. Eighty-seven percent of the patients showed complete clinical, virological, and immunological remission, and the remaining 13% showed partial remission in the form of persistence of clinical manifestations with virological and immunological recovery.

The effect of sofosbuvir and daclatasvir therapy on Child-Pugh score, liver fibroscan, and the laboratory measures

among HCV-MC, including viral load, serum cryoglobulins, C3, C4, and RF before 12 and 24 weeks posttherapy, are presented in Table 2, showing significant improvement in Child-Pugh score and liver fibroscan status. There were also significant improvements in hemoglobin levels from $12.49 \text{ g/dL} \pm 1.08 \text{ SD}$ to $13.09 \text{ g/dL} \pm 1.1 \text{ SD}$, platelet counts from $179.17 \times 10^3/\mu\text{L} \pm 84.7 \text{ SD}$ to $201.64 \times 10^3/\mu\text{L} \pm 88.02 \text{ SD}$, and liver functions, serum creatinine and eGFR. The mean serum cryoglobulins decreased significantly from $41.47 \mu\text{g/mL} \pm 12.32 \text{ SD}$ to $5.12 \mu\text{g/mL} \pm 3.59 \text{ SD}$ (Figure 2), with a significant increase in the serum levels of C3 and C4 and a significant decline in RF (Table 2). Also, the quantitative HCV-RNA levels decreased from $1.008 \times 10^6 \text{ IU/mL} \pm 0.912 \times 10^6 \text{ SD}$ to undetectable levels ($< 16 \text{ IU/mL}$) in all the included patients. Repeated measurements of both serum cryoglobulins and viral load at the 24th week posttherapy showed SVR (continuity of undetectable levels for HCV-RNA) in all the included patients (100%) with no relapse increase in the serum cryoglobulins, although some patients continue to have persistent clinical manifestations.

Discussion

MC has been associated with a variety of viral infections, and chronic HCV infection is a recognizable major cause.²¹ The attribution of cryoglobulinemia to HCV represents a successful association in immunology, microbiology, and the clinical medicine field.²² The prevalence of HCV infection-induced MC in the Mediterranean Basin is about 90%, with a female-to-male ratio of 3:1.²³ Our study found that HCV patients proven to have MC showed female predominance, and this was in line with Mohammed et al,²⁴ who reported

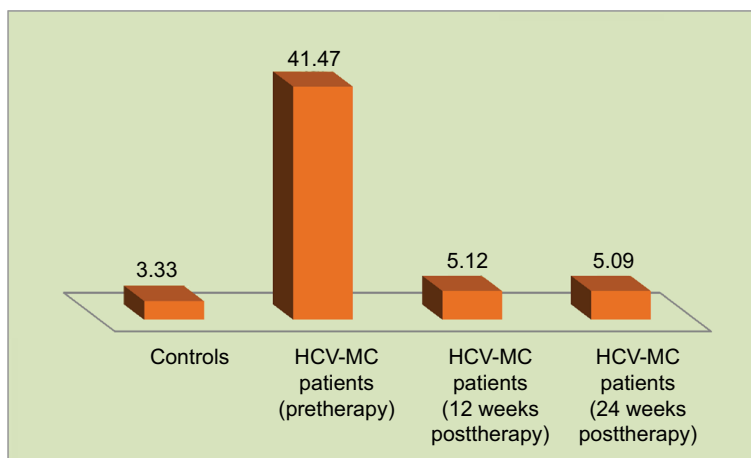


Figure 2 The mean serum levels ($\mu\text{g/mL}$) of cryoglobulins in controls and among HCV-MC patients pretherapy and 12 and 24 weeks posttherapy with sofosbuvir and daclatasvir regimen.

Abbreviation: HCV-MC, hepatitis C virus mixed cryoglobulinemia.

Table 2 The effect of sofosbuvir and daclatasvir therapy on Child-Pugh score, liver fibroscan, and the laboratory measures among HCV-MC

Variables (n=63)	Before therapy	12 weeks posttherapy	24 weeks posttherapy	*P ₁ value	*P ₂ value
Child-Pugh score	5.95±1.96	5.01±1.12	4.50±1.41	0.001	0.000
Liver fibroscan (kPa)	15.21±3.13	13.83±2.61	13.31±2.10	0.001	0.000
Complete blood count (mean ± SD)					
WBC (10 ³ /μL)	6.3800±2.1	6.5690±2.1	6.3161±2.3	0.5	0.5
PLT (10 ³ /μL)	179.17±84.7	201.64±88.02	205.93±92.01	0.003	0.000
HGB (g/dL)	12.49±1.08	13.09±1.1	13.61±1.01	0.000	0.000
Liver functions (mean ± SD)					
Bilirubin (mg/dL)	1.10±0.82	0.93±0.31	0.83±0.21	0.09	0.01
Albumin (g/dL)	3.53±0.70	3.88±0.6	4.01±0.3	0.000	0.000
ALT (U/L)	33.47±11.37	26.71±14.42	24.61±16.42	0.01	0.00
AST (U/L)	36.14±13.67	25.38±7.79	23.12±9.19	0.000	0.000
PT (s)	12.9±1.4	12.2±1.27	11.9±1.13	0.000	0.000
PC (%)	79.29±10.77	74.53±11.5	80.53±10.5	0.000	0.000
INR	1.08±0.19	0.965±0.147	0.832±0.126	0.000	0.000
Creatinine (mg/dL)	1.1±0.89	0.9±0.71	0.7±0.62	0.03	0.01
eGFR (mL/min/1.73 m ²)	62.0±5.6	73.0±6.3	75.0±6.1	0.01	0.00
Cryoglobulin level (μg/mL)	41.47±12.32	5.12±3.59	5.09±3.02	0.000	0.000
Complement 3 (mg/dL)	72.11±12.12	95.13±13.19	112.11±11.07	0.001	0.000
Complement 4 (mg/dL)	20.31±2.12	31.31±2.12	37.31±2.09	0.001	0.000
Rheumatoid factor (IU/mL)	60.53±12.12	15.03±2.02	13.15±1.19	0.000	0.000
PCR level (IU/mL)	1.008×10 ⁶ ±0.912×10 ⁶	Undetectable	Undetectable	–	–

Notes: *P<0.05 indicates significant difference. P₁ = before therapy versus 12 weeks posttherapy; P₂ = before therapy versus 24 weeks posttherapy. Student's t-test was used. **Abbreviation:** HCV-MC, hepatitis C virus mixed cryoglobulinemia; WBC, white blood cell count; PLT, platelet count; HGB, hemoglobin concentration; ALT, alanine transaminase; AST, aspartate transaminase; PT, prothrombin time; PC, prothrombin concentration; INR, international normalization ratio.

that cryoglobulinemia was significantly more common in the female population with HCV.

Clinically, MC is characterized by the classic Meltzer's triad of manifestations in the form of purpura, weakness, and arthralgia, with variable clinical spectrum from skin lesions in the form of recurrent purpura to renal damage and peripheral neuropathy.¹⁹ The incidence of neurological changes in HCV-MC may exceed 60%.²⁵ The association between HCV infection, the presence of cryoglobulinemia, and peripheral neuropathy is well documented²⁶ and is the result of ischemic nerve changes secondary to small vessel vasculitis or necrotizing arteritis of medium-sized vessels.²⁷ In the present study, peripheral neuropathy was the most frequent presentation among the included HCV-MC patients who have Meltzer's triad, followed by purpura. This was in accordance with the findings of Migliaresi et al,²⁸ Zaltron et al,²⁹ Hegab and Sweilam,³⁰ and Bonacci et al.²⁰ In contrast, Lauletta et al³¹ reported Meltzer's triad in 100% of their HCV-MC patients, with 18.1% having glomerulonephritis, while purpura and peripheral neuropathy had the same relative frequency (9.1%). This difference in frequency could

be attributed to the difference in the number of patients included in every study. Neuropathy has been reported in HCV without cryoglobulinemia,³² but with lower frequency and less severity.³³

Because the activity of MC usually correlates with viremia, therapy should be directed toward the potential causal agent.³⁴ The efficacy and safety of all oral DAAs therapy in HCV-MC are largely unknown,³⁵ and very few studies investigate the efficacy of sofosbuvir-based DAA regimens for HCV patients generally and for HCV-MC patients specifically. The results of the current study pertaining to the therapeutic efficacy of the combined use of sofosbuvir and daclatasvir as oral DAAs revealed 100% SVR12 and clearance of cryoglobulins, with significant improvements in Child-Pugh score, liver fibroscan status, hemoglobin levels, platelet counts, liver functions, and eGFR and creatinine levels, with 87% of the included patients showing a complete response and 13% a partial response without any side effects (apparent clinical or laboratory abnormalities). This indicates the higher therapeutic efficacy and safety of sofosbuvir and daclatasvir in managing HCV-MC. In

agreement with these findings, Sise et al³⁵ reported that 83% of HCV-MC patients showed SVR12 rates for sofosbuvir-based DAA regimens. Also, our findings were in line with Saadoun et al³⁶ and Bonacci et al,²⁰ who reported an abrupt decay of HCV-RNA with DAAs with a rapid improvement of the clinical manifestations of MC that may allow the reduction or even cessation of the traditional immunosuppressive therapy. Gragnani et al³⁷ reported that IFN-free DAAs therapy was highly effective and safe for HCV-MC, with an overall 100% rate of clinical response of vasculitis. Emery et al³⁸ conclude in their study that DAAs resulted in high rates of SVR in HCV-MC with excellent safety. However, some of their patients did not have complete clinical or immunological response, suggesting a delay to clinical response, particularly in those with severe vasculitis, which could explain the partial response that occurred in 13% of the included patients observed in our study. This needed long-term follow-up after completion of treatment but was deficient in the present study.

Since serum RF levels are positive in most patients with cryoglobulinemia and the concentrations of RF correlate with cryoglobulin levels, serum RF concentration is routinely analyzed, and the results are included.¹¹ Our findings revealed significantly higher RF with significantly lower C3 and C4 serum levels among the included HCV-MC in comparison with the controls, with significant improvements in their level following DAAs. In line with our data, Boglione et al¹⁴ and Gragnani et al³⁷ reported similar findings.

Conclusion

MC should be considered if HCV-infected patients complaining from unexplained purpura, arthralgia, peripheral neuropathy, weakness, or renal affection, as extrahepatic manifestations are common, especially those related to MC. Chronic HCV-infected patients should be routinely investigated for serum cryoglobulins assay, even if asymptomatic. The present study confirms that DAAs, in the form of sofosbuvir and daclatasvir, are a treatment of choice for HCV infection and should be considered in cases of HCV-MC as they were associated with clinical improvement in most patients.

Study limitations

The lack of a long-term follow-up period after the completion of treatment is a major limitation of this study. Also, asymptomatic MC with HCV was not among the inclusion criteria. All these points need to be taken into consideration in further research.

Disclosure

The authors report no conflicts of interest in this work.

References

- Petruzzello A, Marigliano S, Loquercio G, Cozzolino A, Cacciapuoti C. Global epidemiology of hepatitis C virus infection: an up-date of the distribution and circulation of hepatitis C virus genotypes. *World J Gastroenterol*. 2016;22(34):7824–7840.
- Kandeel A, Genedy M, El-Refai S, Funk AL, Fontanet A, Talaat M. The prevalence of hepatitis C virus infection in Egypt 2015: implications for future policy on prevention and treatment. *Liver Int*. 2017;37(1):45–53.
- Charles ED, Dustin LB. Hepatitis C virus-induced cryoglobulinemia. *Kidney Int*. 2009;76(8):818–824.
- Cacoub P, Comarmond C, Domont F, Savey L, Desbois AC, Saadoun D. Extrahepatic manifestations of chronic hepatitis C virus infection. *Ther Adv Infect Dis*. 2016;3(1):3–14.
- Vigani AG, Macedo-de-Oliveira A, Pavan MH, Pedro MN, Gonçalves FL Jr. Hepatitis C virus infection, cryoglobulinemia, and peripheral neuropathy: a case report. *Braz J Med Biol Res*. 2005;38(12):1729–1734.
- Anis S, Muzaffar R, Zafar MN, et al. Relationship of HLA antigens and cryoglobulinaemia in hepatitis C virus infected patients. *J Pak Med Assoc*. 2007;57(6):300–305.
- Meltzer M, Franklin EC, Elias K, et al. Cryoglobulinaemia a clinical and laboratory study. II. Cryoglobulins with rheumatoid factor activity. *Am J Med*. 1966;40:837–856.
- Gumber SC, Chopra S. Hepatitis C: a multifaceted disease. Review of extrahepatic manifestations. *Ann Intern Med*. 1995;123(8):615–620.
- Trendelenburg M, Schifferli JA. Cryoglobulins in chronic hepatitis C virus infection. *Clin Exp Immunol*. 2003;133(2):153–155.
- Dammacco F, Sansonno D, Piccoli C, Tucci FA, Racanelli V. The cryoglobulins: an overview. *Eur J Clin Invest*. 2001;31:628–638.
- Shihabi ZK. Cryoglobulins: an important but neglected clinical test. *Ann Clin Lab Sci*. 2006;36(4):395–408.
- Ferri C, Sebastiani M, Giuggioli D, et al. Mixed cryoglobulinemia: demographic, clinical and serologic features and survival in 231 patients. *Semin Arthritis Rheum*. 2004;33(6):355–374.
- Saadoun D, RescheRigon M, Thibault V, et al. Peg-IFN/ribavirin/protease inhibitor combination in hepatitis C virus associated mixed cryoglobulinemia vasculitis: results at week 24. *Ann Rheum Dis*. 2014;73(5):831–837.
- Boglione L, Cusato J, Pinna SM, et al. Role of ribavirin in the treatment of hepatitis C virus-associated mixed cryoglobulinemia with interferon-free regimens. *Arch Virol*. 2018;163(4):961–967.
- Ramos-Casals M, Stone JH, Cid MC, Bosch X. The cryoglobulinaemias. *Lancet*. 2012;379(9813):348–360.
- European Association for the Study of the Liver. EASL recommendations on treatment of hepatitis C 2015. *J Hepatol*. 2015;63(1):199–236.
- Levey AS, Bosch JP, Lewis JB, et al. A more accurate method to estimate glomerular filtration rate from serum creatinine: a new prediction equation. Modification of diet in Renal Disease Study Group. *Ann Intern Med*. 1999;130(6):461–470.
- Wang JH, Changchien CS, Hung CH, et al. Liver stiffness decrease after effective antiviral therapy in patients with chronic hepatitis C: longitudinal study using FibroScan. *J Gastroenterol Hepatol*. 2010;25(5):964–969.
- Dammacco F, Racanelli V, Russi S, Sansonno D. The expanding spectrum of HCV-related cryoglobulinemic vasculitis: a narrative review. *Clin Exp Med*. 2016;16(3):233–242.
- Bonacci M, Lens S, Londoño MC, et al. Virologic, clinical, and immune response outcomes of patients with hepatitis C virus-associated cryoglobulinemia treated with direct-acting antivirals. *Clin Gastroenterol Hepatol*. 2017;15(4):575–583.
- Bazerbachi F, Leise MD, Watt KD, Murad MH, Prokop LJ, Haffar S. Systematic review of mixed cryoglobulinemia associated with hepatitis E virus infection: association or causation? *Gastroenterol Rep*. 2017;5(3):178–184.

22. Ragab G, Hussein MA. Vasculitic syndromes in hepatitis C virus: a review. *J Adv Res*. 2017;8(2):99–111.
23. Peveling-Oberhag J, Crisman G, Schmidt A, et al. Dysregulation of global microRNA expression in splenic marginal zone lymphoma and influence of chronic hepatitis C virus infection. *Leukemia*. 2012;26(7):1654–1662.
24. Mohammed RH, ElMakhzangy HI, Gamal A, et al. Prevalence of rheumatologic manifestations of chronic hepatitis C virus infection among Egyptians. *Clin Rheumatol*. 2010;29(12):1373–1380.
25. Costa J, Resende C, de Carvalho M. Motor-axonal polyneuropathy associated with hepatitis C virus. *Eur J Neurol*. 2003;10(2):183–185.
26. Apartis E, Léger JM, Musset L, et al. Peripheral neuropathy associated with essential mixed cryoglobulinemia: a role for hepatitis C virus infection? *J Neurol Neurosurg Psychiatry*. 1996;60(6):661–666.
27. Vital C, Vital A, Cannon MH, et al. Combined nerve and muscle biopsy in the diagnosis of vasculitic neuropathy. A 16-year retrospective study of 202 cases. *J Peripher Nerv Syst*. 2006;11(1):20–29.
28. Migliaresi S, Di Iorio G, Ammendola A, et al. [Peripheral nervous system involvement in HCV-related mixed cryoglobulinemia]. *Reumatismo*. 2001;53(1):26–32. Italian.
29. Zaltron S, Puoti M, Liberini P, et al. High prevalence of peripheral neuropathy in hepatitis C virus infected patients with symptomatic and asymptomatic cryoglobulinaemia. *Ital J Gastroenterol Hepatol*. 1998;30(4):391–395.
30. Hegab DS, Sweilam MAER. Cryoglobulinaemia in Egyptian patients with extrahepatic cutaneous manifestations of chronic hepatitis C virus infection. *Dermatol Res Pract*. 2015;2015:182609.
31. Lauletta G, Russi S, Pavone F, Vacca A, Dammacco F. Direct-acting antiviral agents in the therapy of hepatitis C virus-related mixed cryoglobulinaemia: a single-centre experience. *Arthritis Res Ther*. 2017;19(1):74.
32. Lidove O, Cacoub P, Maisonobe T, et al. Hepatitis C virus infection with peripheral neuropathy is not always associated with cryoglobulinaemia. *Ann Rheum Dis*. 2001;60(3):290–292.
33. Nemni R, Sanvito L, Quattrini A, Santuccio G, Camerlingo M, Canal N. Peripheral neuropathy in hepatitis C virus infection with and without cryoglobulinaemia. *J Neurol Neurosurg Psychiatry*. 2003;74(9):1267–1271.
34. Hernandez-Rodriguez J, Alba MA, Prieto-Gonzalez S, Cid MC. Diagnosis and classification of polyarteritis nodosa. *J Autoimmun*. 2014;48–49:84–89.
35. Sise ME, Bloom AK, Wisocky J, et al. Treatment of hepatitis C virus-associated mixed cryoglobulinemia with direct-acting antiviral agents. *Hepatology*. 2016;63(2):408–417.
36. Saadoun D, Pol S, Ferfar Y, et al. Efficacy and safety of sofosbuvir plus daclatasvir for treatment of HCV-associated cryoglobulinemia vasculitis. *Gastroenterology*. 2017;153(1):49–52.
37. Gragnani L, Visentini M, Fognani E, et al. Prospective study of guideline-tailored therapy with direct-acting antivirals for hepatitis C virus-associated mixed cryoglobulinemia. *Hepatology*. 2016;64(5):1473–1482.
38. Emery JS, Kuczynski M, La D, et al. Efficacy and safety of direct acting antivirals for the treatment of mixed cryoglobulinemia. *Am J Gastroenterol*. 2017;112(8):1298–1308.

Infection and Drug Resistance

Publish your work in this journal

Infection and Drug Resistance is an international, peer-reviewed open-access journal that focuses on the optimal treatment of infection (bacterial, fungal and viral) and the development and institution of preventive strategies to minimize the development and spread of resistance. The journal is specifically concerned with the epidemiology of antibiotic

resistance and the mechanisms of resistance development and diffusion in both hospitals and the community. The manuscript management system is completely online and includes a very quick and fair peer-review system, which is all easy to use. Visit <http://www.dovepress.com/testimonials.php> to read real quotes from published authors.

Submit your manuscript here: <https://www.dovepress.com/infection-and-drug-resistance-journal>

Dovepress