

# Imatinib in the treatment of dermatofibrosarcoma protuberans

Stefanos V Labropoulos  
Evangelia D Razis

1st Medical Oncology Department,  
Hygeia Hospital, Marousi, Greece

**Abstract:** Dermatofibrosarcoma protuberans (DFSP) is a soft tissue tumor with tendency to recur locally and only rarely metastasizes to vital organs. Surgery with wide margins remains the standard treatment. DFSP is characterized by specific chromosomal abnormalities involving the platelet derived growth factor B locus (PDGFB). In the majority of cases a supernumerary ring chromosome containing amplified t(17; 22) translocation or a linear unbalanced t(17; 22) containing the COL1A1–PDGFB fusion gene is present. This molecular event causes aberrant expression of a functional PDGFB leading to activation of PDGFR. Imatinib mesylate is a tyrosine kinase inhibitor with activity against activated PDGFR, and has significant activity against DFSP. Clinical evidence suggests that it has a role in locally advanced and metastatic disease and clinical trials are ongoing examining its role in this rare but potentially fatal sarcoma.

**Keywords:** dermatofibrosarcoma protuberans, PDGFB, ring chromosome, imatinib mesylate

## Introduction

Dermatofibrosarcoma protuberans (DFSP) is a rather uncommon soft tissue tumor of mesenchymal origin arising in the dermis. It is regarded as having intermediate malignant potential between that of dermatofibroma (common fibrous histiocytoma) and malignant fibrous histiocytoma (MFH) (Weiss2001). It is one of several malignancies with defined aberrant molecular pathways that appear to be necessary for the sustained growth of neoplastic cells. The majority of DFSPs harbor at the cytogenetic level a rearrangement of chromosomes 17 and 22, manifested by the translocation t(17; 22) (q22; q13) or by a supernumerary ring chromosome containing several copies of the t(17:22) breakpoint region. These chromosomal abnormalities involve the platelet-derived growth factor B locus (PDGF-B) and render DFSPs responsive to targeted therapy with the tyrosine kinase inhibitor imatinib mesylate (McArthur 2004, 2006; Abrams 2006). The aim of this review is to examine recent evidence regarding treatment of DFSP with imatinib mesylate and other targeted therapies.

## Clinical and pathologic features

DFSP accounts for less than 2% of all soft-tissue sarcomas (less than 0.1% of all cancers). It presents in all ages, including children, but the median age of patients with DFSP is 39–45 years. According to a review of 264 cases (Rutgers 1992) there is a slight male predominance (57% males, 43% females). Thus, it has a similar pattern of incidence as other mesenchymal sarcomas who present more commonly in the same age group. Most common location is the trunk (50%) but it can present in the proximal extremities (30%) and head and neck (10%–15%) (Laskin 1992). There are rare cases involving the hands and feet. Some locations like the head and neck pose unique problems since complete surgical removal can be disfiguring. The usual presentation is an asymptomatic indurated plaque that may be red, brown, violaceous, or flesh colored.

Correspondence: Stefanos V Labropoulos  
1st Medical Oncology Department,  
Hygeia Hospital, RM60, Marousi, 15123,  
Greece  
Tel +30 210 6867165  
Fax +30 210 6867175  
Email slabropoulos@yahoo.com

This plaque can be misdiagnosed for several years but it finally progresses to a firm raised and protuberant nodule that is fixed to the skin but not to deeper tissues. Sometimes it can present as a sclerotic or soft, depressed plaque.

The rarity and variability in presentation of this disease leads to delayed or incorrect diagnosis. DFSP lesion size can range from 1 to 5 cm, although some reports describe lesions up to 40 cm. Ulceration and local bleeding have been reported too. Telangiectasias can be present at the overlying skin and, if left untreated, DFSP may infiltrate fascia, muscle and even bone. During this phase, patients may report local pain.

Histological evaluations show a dense array of spindle-shaped tumor cells with slender nuclei, intercellular collagen deposition, and small capillary blood vessels throughout. Tumors show a storiform or cartwheel pattern and polymorphism (Weiss 2001). Median mitotic rate is low usually less than four mitoses per 10 high-power fields. At the periphery of lesions, malignant cells mix into the dermal fibroblast matrix. The majority of DFSPs are CD34 positive by immunostaining. This is of great assistance to the pathologist since this is a valuable but non-specific marker for the diagnosis. Most of the time, this CD34 positivity is diffuse but some cases show patchy pattern (Sirvent 2003). CD34 is expressed in hematopoietic progenitors including some leukemias, in endothelial cells and in some benign and malignant tumors. This feature of DFSP is hypothesis generating regarding its origin since recent studies support the existence of a common mesenchymal stem cell (Jiang 2002).

The diffuse pattern of infiltration of subcutaneous tissues by DFSP may be the reason for the high propensity for local recurrence. Metastasis is quite unusual.

There are two important variants of DFSP. Pigmented DFSP, also known as Bednar's tumor, displays a varying degree of melanin-containing dendritic cells interspersed in the tumor. Most authors believe that this variant does not have prognostic implication. On the other hand the fibrosarcomatous variant of DFSP (FS-DFSP) is characterized by foci of high grade fibrosarcoma, in at least 5% of the total DFSP area. The fibrosarcoma variant has been found in reviews to have a great propensity of local recurrence (58%) and metastasis (15%). Due to these features FS-DFSPs require more extensive local treatment and closer follow up for possible development of metastases (McArthur 2004, 2006; Abrams 2006).

## Cytogenetics and molecular features of DFSP

Cytogenetics analyses of DFSP have shown supernumerary ring chromosomes (Bridge 1990). Further research led to

the discovery that this ring chromosome is derived from chromosome 22 and contain low level amplified sequences from 17q22-qter and 22q10-13.1 or t(17; 22) usually unbalanced. This translocation results in the fusion of the COL1A1 and PDGFB genes. The breakpoint on chromosome 17 involves different regions of the COL1A1 gene, from exon 6 to exon 47 within the  $\alpha$ -helical region, but the breakpoint on chromosome 22 always involves the first intron of PDGFB. In this way, PDGFB is placed under the control of the COL1A1 promoter that is more transcriptionally active than its own promoter. Processing this fusion gene leads to the formation of a functional PDGFB protein (O'Brien 1998; Shimizu 1999).

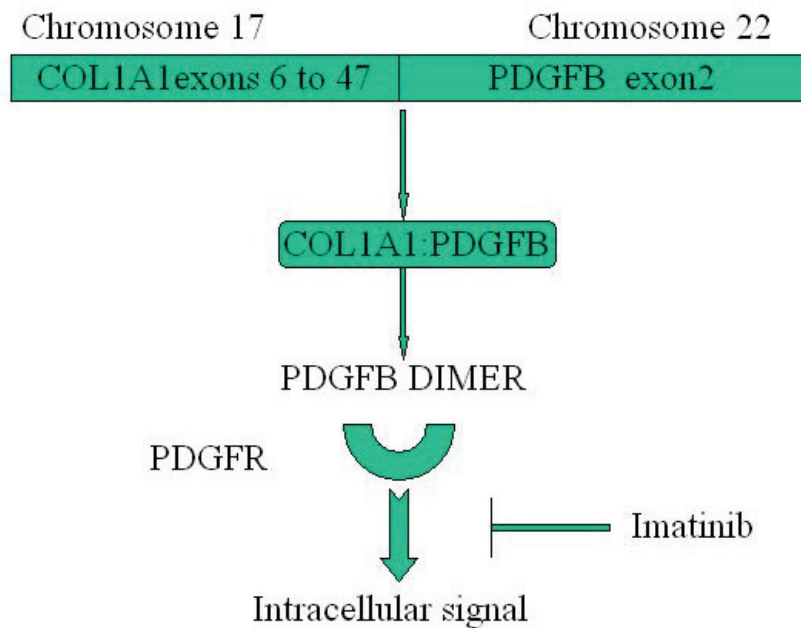
Thus, deregulated activation of PDGF-B is the critical molecular event in DFSP (see Figure 1). The linear translocation is mostly found in pediatric cases (Pedeutour 1996; Sirvent 2003). This makes DFSP a neoplasm where the same molecular event, the COL1A1-PDGFB fusion, occurs on both supernumerary rings and linear chromosomes with an age-related pattern. There is no correlation between the breakpoint location on chromosome 17 and the age of the patient or the histological subtype (Sirvent 2003).

The DFSP molecular events can be examined using fluorescence in-situ hybridization (FISH) or multiplex RT-PCR. For RT-PCR, a combination of various forward primers for COL1A1 and one reverse for PDGF-B need to be used. In Figure 2, cytogenetic analysis of our previously published case report is shown. The advantage of FISH is that it can be performed on paraffin-embedded tissue but it is challenging due to the unbalanced translocation characterizing DFSP.

In approximately 8% of DFSP the COL1A1-PDGFB fusion is not found suggesting that other genes may be involved in these cases, or that there is a cryptic rearrangement of COL1A1 or PDGFB.

PDGFB acts as a ligand for both PDGFR $\alpha$  and PDGFR $\beta$ . In a seminal paper phosphorylation level of PDGFR $\beta$  was examined in five DFSP tumor specimens by Western blot prior to treatment with imatinib. DFSP autocrine/paracrine PDGFR $\beta$  phosphorylation was at least 10-fold lower than the PDGFR $\alpha$  phosphorylation in a gastrointestinal stromal tumor sample (McArthur GA 2005). On the other hand, imatinib mesylate, a tyrosine kinase inhibitor of PDGFRs has clinical activity in DFSP, as will be discussed later. Thus, DFSP cells do not require high level of phosphorylation of PDGFRs and are 'addicted' to low levels of activation of receptor tyrosine kinases (Sirvent 2003).

Together with the specific ring and der(22) chromosomes associated with COL1A1 and PDGFB, additional



**Figure 1** COL1A1-PDGFB fusion acts as a fully functional PDGFB activating PDGFR. Imatinib as a PDGFB receptor tyrosine kinase inhibitor blocks intracellular signal transduction.

chromosomal abnormalities have been described in DFSP. The most common is trisomy 8, and less frequently trisomy 5 (Sirvent 2003).

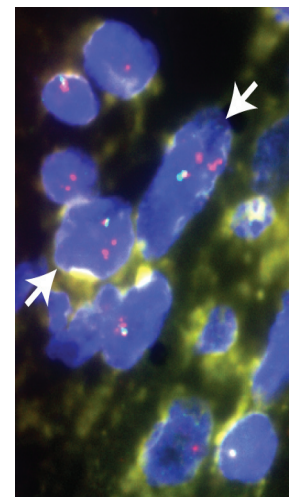
### Standard treatment

The standard treatment of DFSP is wide surgical excision. Some authors suggest the use of Mohs' micrographic surgery where assessment of the margins is performed intra-operatively. With this modality the amount of tissue excised can be minimized especially in visible areas. However, it is not available in many hospitals.

Excellent results have been published (Bowne 2000; Fiore 2005) using 2.5 cm margins but sometimes these wide margins lead to the need of reconstructive surgery. In the most recent study (Fiore 2005) from Milan, the outcome of patients with primary or recurrent DFSP was examined. This review included two hundred eighteen patients surgically treated at one institution over twenty years. In the 136 patients with primary DFSP margins were positive in 11.8% cases while in the 82 patients with recurrent disease margins were positive in 14.6% of cases. Reconstructive surgery was needed in 30% of all cases, more frequently in relapsed disease and in patients with head and neck locations. Long-term outcome was excellent with a local relapse rate of 4% and with a distant metastatic rate of 2% both at a median follow up of 10 years. In this study there were seven patients with FS-DFSP and two of them developed distant metastases and eventually died. In contrast, out of

211 patients with classic DFSP, only 3 developed distant metastases, and two of them were progression free after excision of metastases.

The role of radiotherapy in DFSP is not extensively studied. Retrospective series have shown that radiotherapy is of benefit in the management of margin positive disease and in cases where adequate wide excision would result in major cosmetic



**Figure 2** Dual-color PDGFB FISH showing PDGFB rearrangement in most cells. Arrows indicate two cells in which a normal chromosome 22 (red-green paired signals) and an abnormal ring-chromosome (cluster of red signals) are seen. The full complement of FISH signals is not seen due to the nuclear slicing effect in a four-micron section, and because the image conveys a single plane of focus. Copyright © 2005. Reprinted with permission from Labropoulos SV, Fletcher JA, Oliveira AM, et al. 2005. Sustained complete remission of metastatic dermatofibrosarcoma protuberans with imatinib mesylate. *Anticancer Drugs*, 16:461–6.

**Table 1** Clinical experience with imatinib in DFSP

Patients	Histology	Stage	Dose mg/day	Response	Cytogenetics	Reference
2	DFSP-FS	Metastatic	400	One PR One PD	Complex t(17; 22) present	Maki
1	DFSP	Metastatic	800	Path CR	Complex t(17; 22) present	Rubin
1	DFSP-FS	Metastatic	400	CR	Present t(17; 22) by FISH	Labropoulos
1	DFSP-FS	Metastatic	400	PR	COL1A1-PDGFB by FISH	Misutani
1	DFSP	Metastatic	400	PR	Not reported	Baars
1	DFSP	Metastatic	400	SD by RECIST PR by PET	Not reported	Kaspar
2	DFSP-FS	Metastatic	800	One PR One SD	Complex with t(17; 22) Complex no t(17; 22)	McArthur
8	DFSP	Locally advanced	800	Two CR Two path CR Four PR Resection	t(17; 22) t(17; 22) t(17; 22)	McArthur

or functional deficits. Radiation doses of 50–60 Gy should be considered (Suit 1996; Ballo 1998). The good results obtained with imatinib in advanced cases suggest the need for a direct comparison of these two treatment modalities.

## Targeted therapy

The fusion protein derived from the translocation of COL1A1-PDGFB acts in the cells as fully functional PDGF-B. This functional PDGF-B-like protein form homodimers and, by an autocrine and paracrine loops, promote ligand driving proliferation through the two receptors PDGFR $\alpha$  and PDGFR $\beta$ . Since PDGFR $\beta$  is the major isoform expressed in DFSP, the t(17; 22) derived fusion protein most likely acts as this receptor's ligand (see Figure 1). In vitro evidence suggests that when this fusion protein was expressed in a stable NIH 3T3 cell line, it caused morphological transformation and increased growth of cells. Cells transformed with the COL1A1-PDGFB gene as well as cell cultures derived from patients with DFSP are inhibited by the tyrosine kinase inhibitor imatinib mesylate (Glivec or STI-571; Novartis, Basel, Switzerland) (Greco 2001, Sjoblom 2001).

Several published reports indicate that imatinib has significant activity against DFSP (Table 1). The first experience was published in 2002 (Maki 2002). Two patients with metastatic DFSP were treated with imatinib at 400 mg/d after failure of chemotherapy. Available tissue showed that both had fibrosarcomatous DFSP and one of the two cases was karyotyped. The karyotype showed two ring chromosomes but there was no involvement of 22q13 where the PDGFB gene is located. This patient had a transient response during the first month of treatment but then progressed and died of his disease. The second reported patient did not have a karyotype performed but had a very good partial response

after 2 months of imatinib with resolution of superior vena cava syndrome and pulmonary metastases. This response was sustained at 6 months of treatment.

The same year in a different case report a patient with unresectable metastatic DFSP was treated with imatinib at 400 mg twice daily (Rubin 2002). He had presented with a paraspinal mass, and after 2 weeks of treatment he had clinical improvement. FDG-PET showed normalization of glucose uptake. During 4 months of imatinib treatment the tumor shrank by 75%, allowing the resection of the mass. No viable tumor cells were seen in the resected specimen indicating a complete pathologic remission to imatinib mesylate. This pathologic finding is a proof of concept of the dichotomy between anatomic imaging studies and response to sarcoma treatment. This patient had a complex karyotype with a 22q13 translocation with an unidentified partner. No ring chromosome and no t(17; 22) was identified.

The largest study with imatinib in DFSP patients was reported in 2005 and involved both locally advanced and metastatic disease (McArthur 2005). This study was a multicenter phase II trial of imatinib at the dose of 400 mg twice daily and involved 10 patients. This high dose was well tolerated except in one patient who required reduction to 600 mg/d. This study is of interest since it included molecular, cytogenetic and kinase activation profiles in order to evaluate possible correlation of tumor profile with response to imatinib. In four patients, biopsies were performed before and after 28 days of treatment. Eight patients had locally advanced disease and two achieved pathologic complete remission (CR) and two radiologic CR. The other four had partial responses and with subsequent surgical resection were rendered disease free. Follow up of these patients ranged from 88 to 845 days. Notably all patients with locally

advanced disease had partial (50%) or complete remission to imatinib. All of these patients had a typical ring chromosome t(17; 22). Two patients had metastatic disease. One had a good partial response for 6 months on imatinib treatment but subsequently developed disease progression. The second patient with metastatic disease had no clinical response to imatinib and died of complications of a pathologic fracture 21 days after starting imatinib. Both of these patients had complex karyotypes. The one who did not respond clinically did not harbor PDGF-B rearrangement by FISH in paraffin tumor sections or in cytogenetic preparations. The one who responded for 6 months had the t(17; 22) translocation with several copies of a ring chromosome. FISH for PDGF-B confirmed the t(17; 22) in the ring chromosomes.

As described previously pretreatment phosphorylation levels of PDGFR- $\beta$  were performed in DFSP samples and revealed low level of activity suggesting that the malignant phenotype of this disease does not require high level or upregulation of kinase activity. Thus inhibition of low-level receptor tyrosine kinase activity is effective since the tumor cells are addicted to this signaling mechanism. This is in contrast with findings of high-level receptor tyrosine kinase activity of PDGF-A in GIST tumors.

In several patients matched pretreatment and on-therapy tumor biopsy specimens were obtained. During imatinib treatment the specimens had reduced cellularity and hyaline changes. PDGFB by FISH showed persistence of the t(17; 22) translocation in the spindle-cell component of the disease. Of interest the translocation was found in only 20% of these spindle cells suggesting that most of them were either reactive or cells lacking the t(17; 22) translocation (McArthur GA 2005).

In our case report (Labropoulos 2005), a patient with locally recurrent and metastatic to the lungs fibrosarcomatous DFSP was treated with imatinib at 400 mg/d. This patient was resistant to previous anthracycline chemotherapy and had both soft tissue and lung metastases. Within the first month of treatment clinical response was observed at the local site and subsequent FDG-PET and CT demonstrated complete radiologic response. The lung lesions were not FDG avid, but this was thought to be explained by their size (maximal diameter 8mm), which was below the resolution of the PET scanner. However, by CT scans these lesions disappeared during treatment with imatinib. FISH study of the tumor with novel probes demonstrated PDGFB rearrangement in most cells (Figure 2). This patient remained in CR on imatinib 400 mg/d for over 2 years and had only mild hematologic toxicity (anemia), and peripheral edema which did not require

interruption of imatinib. Almost at two years on this treatment she developed recurrence both in soft tissues and lungs. Her dose of imatinib was increased to 400 mg twice a day with no response and underwent resection of lung metastases. Subsequently she progressed and is now on second line targeted therapy with the tyrosine kinase inhibitor sunitinib which has activity in imatinib resistant GIST. So far she seems to be responding in soft tissue and pleural based disease with no severe toxicity (unpublished).

In a pediatric case with a large extremity DFSP, response to imatinib was documented by MRI after 23 weeks of neoadjuvant therapy. The dose was 400 mg/m<sup>2</sup> once a day and was further increased to 520 mg/m<sup>2</sup>/day. FISH study of the tumor showed PDGF-B rearrangement. This is the first report of a pediatric DFSP who exhibited response to imatinib. This 18 month old girl had a large lower extremity DFSP (initially assumed to be a hemangioma). Immediate surgical resection would have caused unacceptable functional defects (Price 2005).

Another case report (Kaspar 2006) described a patient with locally recurrent and metastatic DFSP who had undergone surgery 22 times. The patient had a large mesenteric mass with retroperitoneal lymph nodes. He was initially treated at 400 mg/d, which was increased to 400 mg twice a day. Clinical response was seen after the first month of therapy. Metabolic response was documented by FDG-PET both at one month and at 12 weeks on treatment. However by CT the patient had a minor decrease of the mass size classified as stable disease by response evaluation criteria in solid tumors (RECIST). No cytogenetic or RT-PCR data were reported. The use of classical RECIST criteria in imatinib treated GISTs may lead to erroneous conclusions regarding tumor responsiveness. As reported recently in GISTs, a 10% decrease in size or a 15% decrease in density on contrast enhanced CT correlated well with response by PET measurements and was more predictive of time to tumor progression than response by RECIST (Benjamin 2007).

Another partial response of a metastatic DFSP with imatinib was described in a case report from the Netherlands but further details were unavailable (Baars 2003).

Finally a patient with metastatic DFSP to the lungs had a partial response to imatinib 400 mg/d. FISH demonstrated the COL1A1-PDGF-B translocation. This case is presented in a letter form (Mizutani 2004).

In all these reported cases imatinib was well tolerated in the dose range of 400 to 800 mg per day. Experience from larger studies in GIST tumors suggests that the higher dose is more often associated with side effects requiring dose reduction.

Many questions arise from these reports of imatinib activity in this soft tissue sarcoma (Abrams 2006, McArthur 2005). First, does response to imatinib correlate with the cytogenetic findings or histologic features? The first impression is that patients who respond have evidence of PDGF-B rearrangement. Complex cytogenetics and/or no PDGF-B rearrangement may be negative predictive factors for response to imatinib. Some authors have suggested that histologic features of DFSP such as a fibrosarcomatous component may render these tumors less responsive but other reports and our own experience have shown good response in fibrosarcomatous DFSPs.

Another important question is the dose. The dose of imatinib varies from 400 mg/d to 400 mg twice a day and at this point there is no evidence that there is a dose effect on this disease. One could suggest starting at lower dose and if there is no response increasing the dose to 400 mg twice a day.

The use of RECIST criteria has been questioned in imatinib treated GISTs. In some of the case reports regarding imatinib treated DFSPs response was earlier and sometimes only evaluable by FDG-PET raising similar questions to the ones discussed in GISTs (Benjamin 2007). Duration of treatment is another factor and so far, the clinical practice is to continue treatment until disease progression based on the experience with GISTs.

Further important questions include the clinical use of imatinib as neoadjuvant therapy especially in large tumors requiring extensive and potentially disfiguring surgery and the use of imatinib as adjuvant treatment after surgical resection in cases with large tumors or DFSPs with aggressive histologic features. The latter is particularly interesting in view of new evidence that adjuvant imatinib is of benefit to patients with surgically resected large and histologically aggressive GISTs.

Over the last few years many novel targeted agents with tyrosine kinase inhibitor action have become available in the clinic. Some of these agents have activity against PDGFB and some act in multiple pathways including angiogenesis. Two of these agents, sunitinib and sorafenib, are active and approved for patients with metastatic renal cancer, while sunitinib is active in imatinib resistant or progressing GISTs. It will be of great interest to test these drugs in the laboratory against DFSP cell lines to obtain solid evidence of potential activity. In the clinic they could be tried in patients who are refractory or progressing on imatinib and who have no other therapeutic option. Patients who progress on one targeted agent seem to harbor mutations that render them sensitive to a second line targeted agent. Evidence for this

is accumulating from the treatment of chronic myelogenous leukemia (Kantarjian H 2006; Talpaz 2006).

## Clinical trials

Despite the evidence from the above studies imatinib is not yet approved by the American or European regulatory authorities for use in DFSP. Being rare and usually curable by surgery DFSP is a very difficult disease to perform large-scale randomized trials in this disease. At this juncture there are three very important multicenter phase II studies attempting to answer questions regarding the use of imatinib in locally advanced and metastatic DFSP (Abrams 2006).

One study from North America sponsored by National Cancer Institute and by Southwest Oncology Group (SWOG) addresses the issue of using imatinib in patients where local resection of DFSP would have an unacceptable cosmetic result or impairment. Patients are allowed to enter irrespective of having the COL1A1-PDGFB fusion gene but PDGFB studies will be performed on the tumor specimens. Starting dose is 400 mg/d and the dose can be escalated to 400 mg twice a day if there is tumor progression and significant toxicity is absent.

The second study is sponsored by the European Organization for Research and Treatment (EORTC) excludes patients who could be cured by local surgery. Additionally in this study the presence of COL1A1-PDGF-B fusion gene is required. The dose of imatinib is at 400 mg twice a day. The pre-entry criterion of the fusion gene may miss the opportunity to see imatinib activity in patients where neoplasia is driven by alternate partners of PDGF-B.

Both studies aim at accruing 40 patients if activity of imatinib is seen but differ in their endpoints. The American study is examining response rate and the European progression free survival at 14 weeks on treatment.

A third phase II study is activated by the Sarcoma Alliance for Research, and is attempting to look at the molecular activity of imatinib in primary DFSP. Before definitive surgical treatment patients will receive imatinib at 400 mg twice daily for 10 to 14 days. Resected tumor will be studied for molecular effects of imatinib on PDGFR and downstream molecules.

In view of the rarity of this disease and the many questions regarding evidence based use of imatinib, patients and their physicians are strongly encouraged to participate in these studies.

## Conclusions

DFSP is a rare soft tissue sarcoma that can be cured by appropriate surgery in the majority of cases. It has a unique

molecular characteristic involving the PDGF-B locus with the presence of ring chromosomes containing several copies of the t(17; 22) translocation or a linear t(17; 22). In challenging, locally advanced disease and in the rare metastatic cases imatinib mesylate has shown impressive single agent activity with limited toxicity. Several basic science and clinical questions need to be answered by collaborative approach while other novel tyrosine kinase inhibitors need to be tested in imatinib refractory or progressing cases. The knowledge of basic molecular pathways has led to this new therapy for patients with DFSP, and is an example of the potential benefit of translational research in solid tumors.

## References

- Abrams TA, Schuetze SM. 2006. Targeted therapy for Dermatofibrosarcoma Protuberans. *Curr Oncol Rep*, 8:291–6.
- Baars A, Pinedo HM. 2003. Good response to treatment with the selective tyrosine kinase inhibitor imatinib in a patient with metastatic dermatofibrosarcoma protuberans [in Dutch]. *Ned Tijdschr Geneesk*, 147:2072–6.
- Ballo MT, Zagars GK, Pisters P, et al. 1998. The role of radiation therapy in the management of dermatofibrosarcoma protuberans. *Int J Radiat Oncol Biol Phys*, 40:823–7.
- Benjamin RS, Choi H, Macapinlac HA, et al. 2007. We should desist using RECIST, at least in GIST. *J Clin Oncol*, 25:1760–4.
- Bridge JA, Neff JR, Sandberg. 1990. Cytogenetics analysis of dermatofibrosarcoma protuberans. *Cancer Genet Cytogenet*, 49:199–202.
- Bowne WB, Antonescu CR, Leung DH, et al. 2000. Dermatofibrosarcoma protuberans :a clinicopathologic analysis of patients treated and followed at a single institution. *Cancer*, 88:2711–20.
- Fiore M, Miceli R, Mussi C, et al. 2005. Dermatofibrosarcoma protuberans treated as a single institution :a surgical disease with a high cure rate. *J Clin Oncol*, 23:7669–75.
- Greco A, Roccatto E, Miranda C, et al. 2001. Growth-inhibitory effect of STI-571 on cells transformed by the COL1A1/PDGF rearrangement. *Int J Cancer*, 92:354–60.
- Jiang Y, Jahargidar BN, Reinhardt RL, et al. 2002. Pluripotency of mesenchymal stem cells derived from adult marrow. *Nature*, 418:41–9.
- Kaspar B, Lossignol D, Gil T, et al. 2006. Imatinib mesylate in a patient with metastatic disease originating from a dermatofibrosarcoma protuberans of the scalp. *Anticancer Drugs*, 17:1223–5.
- Kantarjian H, Giles F, Wunderle L, et al. 2006. Nilotinib in imatinib-resistant CML and Philadelphia chromosome-positive ALL. *N Engl J Med*, 354:2542–51.
- Laskin WB. 1992. Dermatofibrosarcoma protuberans. *CA Cancer J Clin*, 42:116–25.
- Labropoulos SV, Fletcher JA, Oliveira AM, et al. 2005. Sustained complete remission of metastatic dermatofibrosarcoma protuberans with imatinib mesylate. *Anticancer Drugs*, 16:461–6.
- Maki RG, Awan RA, Dixon RH, et al. 2002. Differential sensitivity to Imatinib of 2 patients with metastatic sarcoma arising from Dermatofibrosarcoma Protuberans. *Int J Cancer*, 100:623–6.
- McArthur GA, Demetri GD, van Oosterom A, et al. 2005. Molecular and clinical analysis of locally advanced dermatofibrosarcoma protuberans treated with imatinib: Imatinib Target Exploration Consortium Study B2225. *J Clin Oncol*, 23:866–73.
- McArthur G. 2004. Molecular targeted treatment for dermatofibrosarcoma protuberans. *Semin Oncol*, 31(2 Suppl 6):30–6.
- McArthur GA. 2006. Dermatofibrosarcoma protuberans: a surgical disease with a molecular savior. *Curr Opin Oncol*, 18:341–6.
- Mizutani K, Tamada Y, Harra K, et al. 2004. Imatinib mesylate inhibits the growth of metastatic lung lesions in a patient with dermatofibrosarcoma protuberans [letter]. *Br J Dermatol*, 151:235–6.
- O'Brien KP, Seroussi E, Dal Chil P, et al. 1998. Various regions within the alpha-helical domain of COL1A1 gene are fused to the second exon of the PDGF gene in dermatofibrosarcomas and giant cell fibroblastomas. *Genes Chromosomes Cancer*, 23:187–93.
- Pedeutour F, Lacur JP, Perrin C, et al. 1996. Another case of t(17; 22)(q22; q13) in an infantile dermatofibrosarcoma protuberans. *Cancer Genet Cytogenet*, 89:175–6.
- Price VE, Fletcher JA, Zielanska M, et al. 2005. Imatinib mesylate: an attractive alternative in young children with large, surgically challenging dermatofibrosarcoma protuberans. *Pediatr Blood Cancer*, 44:511–15.
- Rubin BP, Schuetze SM, Eary JF, et al. 2002. Molecular targeting of platelet-derived growth factor B by Imatinib Mesylate in a patient with metastatic Dermatofibrosarcoma Protuberans. *J Clin Oncol*, 20:3586–91.
- Rutgers EJT, Kroon BBR, Albus-Lutter CE, et al. 1992. Dermatofibrosarcoma protuberans: treatment and prognosis. *Eur J Surg Oncol*, 18:241–8.
- Shimizu A, O'Brien KP, Sjoblom T, et al. 1999. The dermatofibrosarcoma protuberans-associated collagen type Ia 1/platelet-derived growth factor(PDGF) B-chain fusion gene generates a transforming protein that is processed to functional PDGF-BB. *Cancer Res*, 59:3719–23.
- Sjoblom T, Shimizu A, O'Brien KP, et al. 2001. Growth inhibition of dermatofibrosarcoma protuberans tumors by the platelet derived growth factor receptor antagonist STI571 through induction of apoptosis. *Cancer Res*, 61:5778–83.
- Suit H, Spiro I, Mankin HJ, et al. 1996. Radiation in management of patients with dermatofibrosarcoma protuberans. *J Clin Oncol*, 14:2365–9.
- Sirvent N, Maire G, Pedeutour F. 2003. Genetics of dermatofibrosarcoma protuberans family of tumors :from ring chromosomes to tyrosine kinase inhibitor treatment. *Genes Chromosomes Cancer*, 37:1–19.
- Talpaz M, Shah NP, Kantarjian H, et al. 2006. Dasatinib in imatinib-resistant Philadelphia chromosome-positive leukemias. *N Engl J Med*, 354:2531–41.
- Weiss SW, Goldblum JR, eds. 2001. Enginger and Weiss S; Soft tissue tumors 4th ed. St Louis: Mosby.

