

A case of intractable infectious keratitis and subsequent flap necrosis after laser *in situ* keratomileusis

Kazutaka Kamiya
Masayuki Kasahara
Kimiya Shimizu

Department of Ophthalmology,
University of Kitasato
School of Medicine, Japan

Abstract: We report on a patient in whom intractable infectious keratitis and subsequent lamellar flap necrosis necessitating flap amputation after laser *in situ* keratomileusis (LASIK). A 34-year-old woman undergoing LASIK complained of blurred vision and pain in the left eye. The best spectacle-corrected visual acuity was 0.01, and slit-lamp examination showed a marked presence of stromal infiltrates involving the flap and the underlying stroma in that eye. The patient was treated topically with hourly instillation of micronomicin, levofloxacin, and cefmenoxime, together with systemic administration of imipenem, but the left eye developed corneal flap necrosis. We performed surgical debridement of the diseased stroma and excised the lamellar flap. Since nontuberculous mycobacterium was detected on the surgical instruments, we then added oral clarithromycin, and substituted systemic administration of amikacin with that of imipenem. At one month after the flap removal, the visual acuity gradually improved to 0.7, but the stromal opacity of the central cornea and hyperopic shift of +3.0 diopters remained. LASIK can cause intractable keratitis, resulting in significant visual disturbance that presumably results from insufficient antiseptics of the medical instruments used for this surgery, supporting the importance of strict sterilization of these instruments.

Keywords: infectious keratitis, flap necrosis, nontuberculous mycobacterium, sterilization, LASIK

Introduction

Laser *in situ* keratomileusis (LASIK) has gained popularity as an effective means of correcting refractive errors. The onset of infectious keratitis after LASIK has been reported to be a rare complication, but may lead to impairment of visual performance.¹⁻³ It has been demonstrated that infectious keratitis caused by mycobacterium occurs after LASIK.²⁻⁵ We present a case in which intractable infectious keratitis and subsequent lamellar flap necrosis necessitating flap amputation, both presumably resulting from inappropriate sterilization of surgical instruments, occur after LASIK, resulting in significant visual disturbance.

Case report

A 34-year-old woman who had undergone bilateral LASIK one month earlier at another eye clinic was referred to our hospital complaining of blurred vision and pain in the left eye. The best spectacle-corrected visual acuity (BSCVA) on the initial visit was 0.01, and slit-lamp examination showed a marked presence of stromal infiltrates involving the flap and the underlying stroma in that eye (Figure 1). Other ophthalmic examination findings were unremarkable. Corneal scrapings were taken, but the

Correspondence: Kazutaka Kamiya
Department of Ophthalmology, University
of Kitasato School of Medicine, 1-15-1
Kitasato, Sagami-hara, Kanagawa, 228-8555,
Japan
Tel +81 42 778 9012
Fax +81 42 778 9920
Email kamiyak-tky@umin.ac.jp

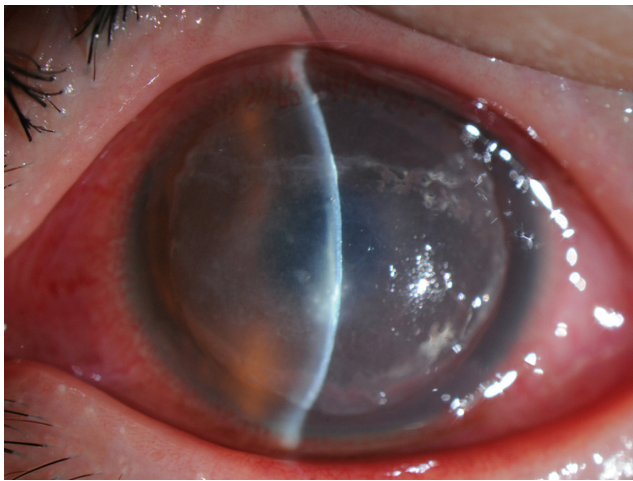


Figure 1 Slit-lamp examination shows marked presence of stromal infiltrates involving the flap and the underlying stroma.

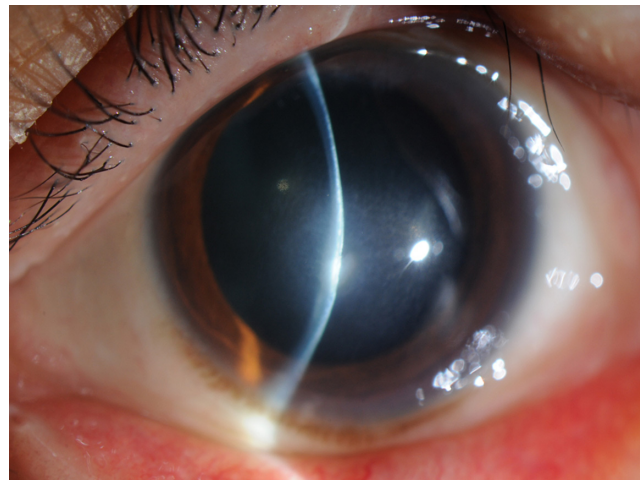


Figure 2 Slit-lamp examination shows the remaining stromal opacity of the central cornea.

results were negative. The stromal bed was irrigated with micronomicin solutions, and the flap was repositioned at the end of the procedure. The patient was treated topically with hourly instillation of 0.3% micronomicin, 0.5% levofloxacin, and 0.5% cefmenoxime, together with systemic administration of imipenem (2 g/day). One week after our initial treatment, the left eye developed corneal flap necrosis and deterioration of other clinical findings. After obtaining informed consent, we performed surgical debridement of the diseased stroma and excised the lamellar flap to facilitate drug penetration. Since the health care center disclosed that nontuberculous mycobacterium was detected on the surgical instruments, including the microkeratomers, we then added oral clarithromycin (400 mg/day), and substituted systemic administration of amikacin (400 mg/day) with that of imipenem as the treatment regimen. At one month after the flap removal, the BSCVA gradually improved to 0.7, but the stromal opacity of the central cornea and hyperopic shift of +3.0 diopters (D) remained (Figure 2). No complications (such as iatrogenic keratectasia or recurrent infection) occurred during the three-month observation period.

Discussion

Mycobacterium is an aerobic, Gram-positive bacterium that is present extensively in the environment, for example, in dust, water, soil, and on animals. It has been reported to be one of the major causative organisms of infectious keratitis after LASIK, appearing especially in the late postoperative period.²⁻⁵ A cluster of 67 cases of infectious keratitis after LASIK appeared between September 2008 and January 2009 in the referring institution and nontuberculous mycobacterium

was isolated from surgical instruments, according to the health care center. Moreover, the antibiotic therapy used initially was not very effective against this post-LASIK keratitis. Thus, we strongly suspect that this infection was caused by nontuberculous mycobacterium, possibly due to intraoperative contamination, although we did not identify the causative organism in our cultures of corneal scrapings. If the organism cultured from corneal scrapings had been in accordance with nontuberculous mycobacterium isolated from surgical instruments, we would have been able to confirm the authenticity of the results. The information from the health care center appears to support the importance of strict sterilization of the medical instruments used for refractive surgery.

This case report emphasizes the difficulties of management of infectious keratitis after LASIK. The patient was treated empirically without microbiologic investigation, resulting in delay of diagnosis and appropriate therapy in this institution. Although a variety of organisms may be involved in infectious keratitis occurring after LASIK,¹⁻³ we should bear in mind that nontuberculous mycobacterium is a possible source of severe post-LASIK infection.

Our findings indicate that LASIK can cause intractable keratitis, resulting in significant visual disturbance that presumably results from insufficient antisepsis of the medical instruments used for this surgery. Surgeons must be responsible for strict sterilization, since this can reduce the risk of infectious keratitis after refractive surgery.

Disclosures

The authors have no financial or proprietary interests in the materials presented herein.

References

1. Gimbel HV, Penno EE, van Westenbrugge JA, Ferensowicz M, Furlong MT. Incidence and management of intraoperative and early postoperative complications in 1000 consecutive laser in situ keratomileusis cases. *Ophthalmology*. 1998;105:1839–1847.
2. Solomon R, Donnenfeld ED, Azar DT, et al. Infectious keratitis after laser in situ keratomileusis: results of an ASCRS survey. *J Cataract Refract Surg*. 2003;29:2001–2006.
3. Chang MA, Jain S, Azar DT. Infections following laser in situ keratomileusis: an integration of the published literature. *Surv Ophthalmol*. 2004;49:269–280.
4. Winthrop KL, Steinberg EB, Holmes G, et al. Epidemic and sporadic cases of nontuberculous mycobacterial keratitis associated with laser in situ keratomileusis. *Am J Ophthalmol*. 2003;135:223–224.
5. John T, Velotta E. Nontuberculous (atypical) mycobacterial keratitis after LASIK: current status and clinical implications. *Cornea*. 2005;24:245–255.

Clinical Ophthalmology

Publish your work in this journal

Clinical Ophthalmology is an international, peer-reviewed journal covering all subspecialties within ophthalmology. Key topics include: Optometry; Visual science; Pharmacology and drug therapy in eye diseases; Basic Sciences; Primary and Secondary eye care; Patient Safety and Quality of Care Improvements. This journal is indexed on

Submit your manuscript here: <http://www.dovepress.com/clinical-ophthalmology-journal>

Dovepress

PubMed Central and CAS, and is the official journal of The Society of Clinical Ophthalmology (SCO). The manuscript management system is completely online and includes a very quick and fair peer-review system, which is all easy to use. Visit <http://www.dovepress.com/testimonials.php> to read real quotes from published authors.