

Treatment of wide-based epiglottic cyst by microdebrider

Cheng-Ming Luo^{1,2}
Shih-Wei Yang^{1,3}
Tai-An Chen^{1,2}

¹Department of Otolaryngology-Head and Neck Surgery, Chang Gung Memorial Hospital, Keelung Taiwan; ²College of Medicine, Chang Gung University, Taoyuan, Taiwan; ³Graduate Institute of Clinical Medical Sciences, Chang Gung University College of Medicine, Taoyuan, Taiwan

Abstract: Epiglottic cyst is not an unusual disease in the larynx. Although it is usually a benign lesion, airway problems may occur due to a large cyst. Surgical excision is usually the treatment of choice, with low recurrence. Because of the limited view and mobility of laryngoscopes, there is sometimes difficulty in the procedure of excision or marsupialization, especially in wide-based epiglottic cysts. The microdebrider has been widely used in treatment of otolaryngological diseases, and specialized blades were designed for laryngeal lesions. We report the use of a microdebrider for treatment of wide-based epiglottic cysts in six patients. The follow-up period ranged from five months to 62 months without recurrence. One hand-powered instrument provided a clear surgical field for precise removal of the cyst and synchronized suction, and increased mobility of the laryngoscope held in the other hand. In comparison to traditional microinstrumentation and carbon dioxide laser, the microdebrider offered a rapid and effective alternative in treatment of wide-based epiglottic cyst.

Keywords: epiglottic cyst, microdebrider, laryngeal blade

Introduction

Although epiglottic cyst is a benign disease, its size and location may result in airway complications.¹ The treatment of choice is surgical removal. Laryngoscope with microsurgery is sometimes time-wasting and difficult to perform in a small surgical field, especially for wide-based epiglottic cyst. A powered instrument provides precise cutting through immediate exposure of the surgical field, and synchronized suction removes blood and specimen fragments. This technique is practical and time-saving, with rare recurrence.² For the treatment of epiglottic cyst, in addition to laryngomicrosurgery with traditional microinstrumentation and carbon dioxide laser, the laryngeal blade microdebrider offers a valuable and effective alternative.

Materials and methods

From August 1999 through December 2000, six patients with wide-based epiglottic cyst received surgical procedure under general anesthesia, using a laryngoscope and long-armed laryngeal blade equipped with a microdebrider. The ages of the patients ranged from 42 to 84. All patients underwent general anesthesia via transoral endotracheal intubation. The direct laryngoscope was held in one hand to explore the cyst, and the Xomed XPS shaver system with laryngeal blades (Xomed Surgical Products, Inc. [Medtronic], Jacksonville, FL, USA) was held in the other hand to perform surgery. The instrumentation is shown in Figure 1. Different cutting tips were used for rapid debulking of the cyst and delicate removal of residual lesions (Figure 2). The cyst

Correspondence: Tai-An Chen
Department of Otolaryngology-Head and Neck Surgery, Chang Gung Memorial Hospital, No 222 Mai Chin Road, Keelung City, 204, Taiwan
Tel +886 2 2431 3131 Ext 2445
Fax +886 2 2431 3161
Email entchen@adm.cgmh.org.tw

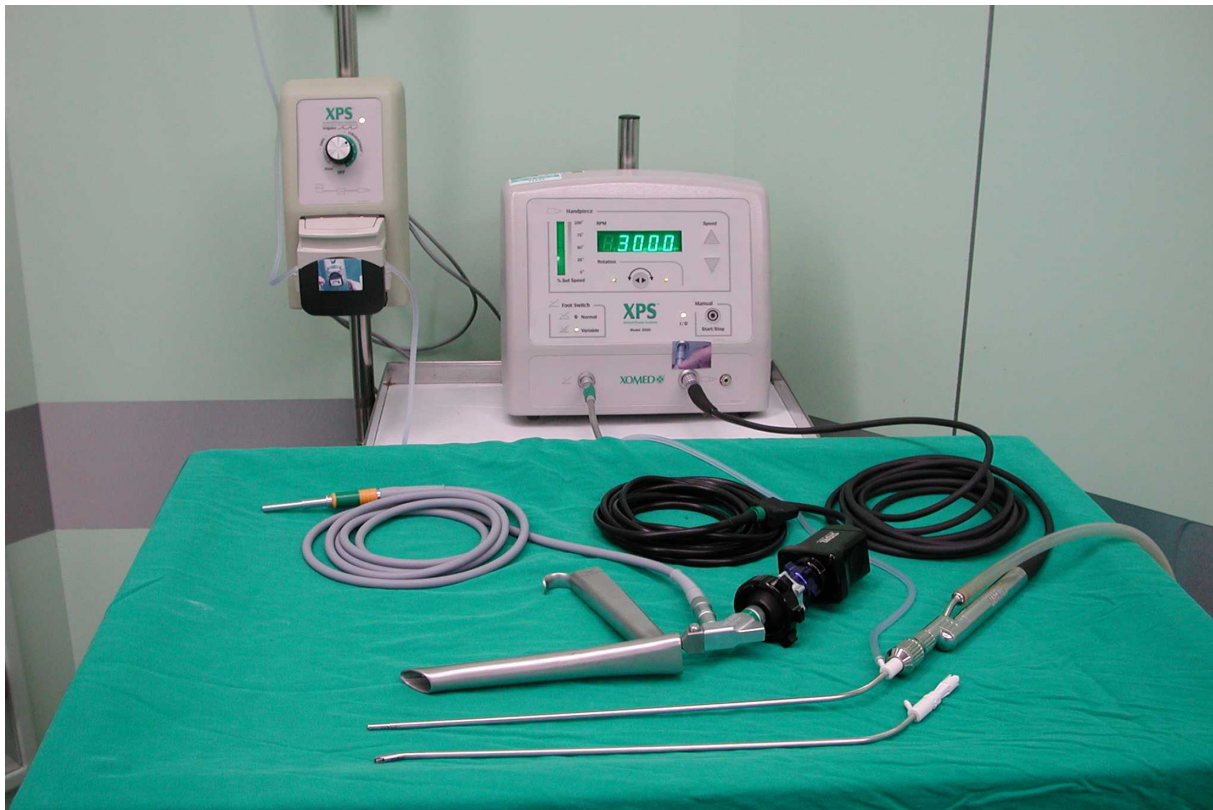

Figure 1 Powered instrumentation with laryngeal blade and video system.



Figure 2 Two kinds of blade.

was deroofed with care to avoid damage of epiglottic cartilage (Figures 3–6). Specimens were collected at the time of surgery via an in-line specimen trap. The bleeding of surgical field could be controlled by compression of epinephrine-soaked gauzes. The data of all patients are summarized in Table 1.

Results

All patients stayed in ward of the hospital after operation for one day and then were followed up in the outpatient department (OPD) regularly. The specimens collected from the trap were adequate for histological diagnosis. The follow-up period ranged from five months to 62 months. There was no recurrence noted during the regular OPD follow-up.

Discussion

Epiglottic cyst is a benign tumor, contributing about 4.3% to 6.1% of all laryngeal benign tumors. Although it is a benign lesion, its presentation of symptom ranges from asymptomatic to lethal outcome, depending on its size and location. Epiglottic cyst can occur at all ages, and the most common is in the sixth decade.¹

According to Asherson's classification, there are three kinds of laryngeal cysts: (1) ductal cysts, (2) saccular cysts, and (3) thyroid-cartilage foraminal cysts, which are rare. Ductal cysts are common, and result in obstruction of collecting ducts of the salivary glands in the larynx. They are also called retention cysts or mucous cysts. Ductal cysts occurred at any place of the larynx, mainly located within the mucous membrane, covered with squamous or ciliated columnar epithelium. Saccular cysts are delivered from the saccule of the laryngeal appendage, and are also called

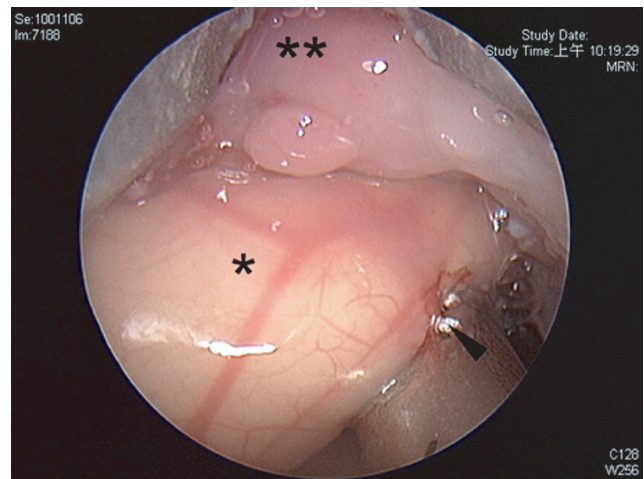


Figure 4 Epiglottic cyst*, lingual tonsil area**, arrow shows cutting edge of blade.

congenital embryonic cysts. They are often seen in neonates, although sometimes in adults. Saccular cysts are larger than ductal cysts, and can occur in the laryngeal ventricle, vocal cords, false cords, and the aryepiglottic fold. Saccular cysts are submucosal lesions and covered with complete mucosa. Thyroid-cartilage foraminal cysts occur in thyroid cartilage protruded with mucosa. Epiglottic cysts are often ductal cysts, and the most common location is the lingual surface of the epiglottis. Sometimes they extend to the aryepiglottic fold or the laryngeal surface of the epiglottis. The differential diagnosis includes thyroglossal duct cyst, lymphangioma, hemangioma, chondroma, lingual thyroid, and papilloma.³

The correct diagnosis of epiglottic cyst depends on disease history-taking and physical examination. The lesion can be seen with indirect laryngeal mirror or flexible

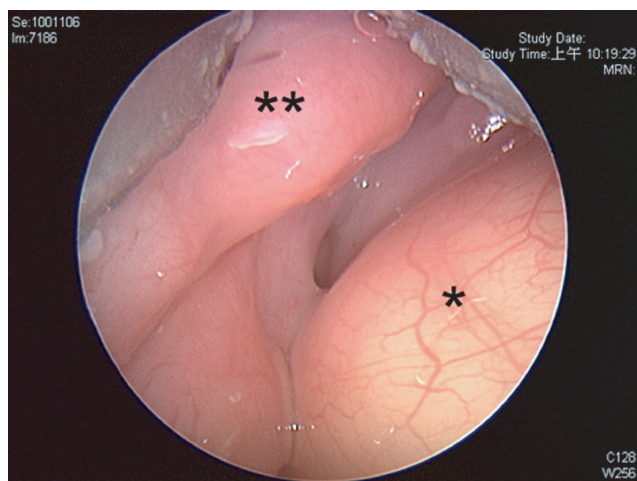


Figure 3 Laryngoscopic view. Epiglottic cyst*, lingual tonsil area**.

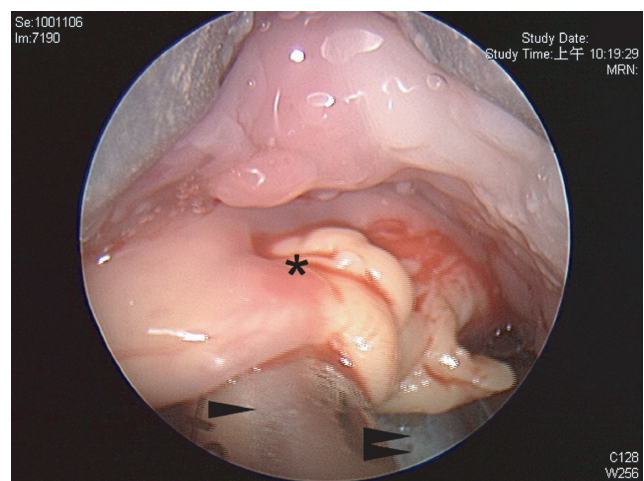


Figure 5 Ruptured cyst*, arrow shows blade, double arrow shows endotracheal tube.

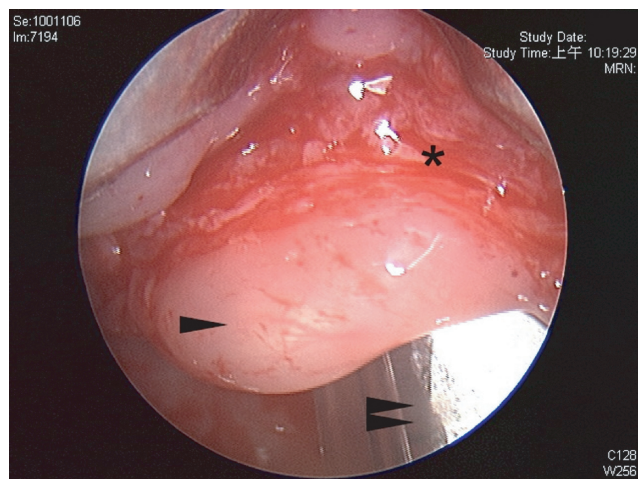


Figure 6 Deroofed cyst* wound, arrow shows epiglottis, double arrow shows endotracheal tube.

fiberoptic laryngoscopy. Other examinations such as neck lateral plain film, thyroid scan, and computed tomography scans also provide useful information for diagnosis.

The treatment of choice for epiglottic cyst is surgical removal. Usually, surgeons use traditional laryngomicrosurgery or carbon bicarbonate laser under microscopy.⁴ Complete excision of the cyst reduces recurrence, but it needs longer surgical and anesthetic time.⁵ Also, the surgical field is limited under microscopy, and the mobility of the laryngoscope is also restricted during surgical excision. It is more difficult to remove a wide-based epiglottic cyst in a small and immobile surgical field. In addition, during excision of wide-based cyst by traditional instrumentation, the surgical field will be easily blurred by blood accumulation. The surgical field may be better with laser surgery, but it is also not easy to excise wide-based epiglottic cyst with poor mobility and need to adjust laryngoscope and microscope frequently.

Microdebriders have been widely used in the otolaryngological field for sinus surgery, adenoidectomy, uvulopalatopharyngoplasty, laryngeal and tracheal lesions.

Table 1 The data of patients receiving removal of epiglottic cysts with powered microdebrider

Patient no.	Age	Sex	Postsurgery follow-up (month)	Recurrence
1	46	Male	28	No
2	49	Male	62	No
3	49	Male	31	No
4	42	Male	46	No
5	84	Male	14	No
6	47	Female	5	No

We report here the use of microdebrider for treatment of wide-based epiglottic cyst.⁶⁻¹⁰ The powered instrument, or microdebrider, equipped with long-armed laryngeal blade provided precise cutting through immediate exposure of the surgical field and synchronized suction.^{11,12} The blade with suction grasps a point of the cystic wall, and the surgeon made a through cutting of the mucosa by paddle controller. At the same time, the suction removes surrounding blood to keep the surgical field clear. All these functions were controlled in one hand, while the laryngoscope could be held in the other hand or in fixed condition. The laryngoscope was equipped with endoscope and video-monitor system to provide a magnified view. Wide-based epiglottic cyst usually extended beyond one surgical field, so we could adjust the laryngoscope immediately to proper position for further cyst deroofing. Hemostasis was usually achieved by compression of epinephrine gauze, and electrocauterization was rarely needed. Although the microdebrider produce fragments of tissue which were smaller than those obtained by conventional excision, histological diagnosis was possible by using a standard in-line suction trap on the microdebrider.¹³

In addition to traditional surgery with microinstrumentation and laser surgery, the laryngeal blade microdebrider offers a valuable and effective alternative. The surgeon should be familiar with the characteristics and operation of the powered instrument to avoid unnecessary complications.

Disclosure

The authors report no conflicts of interest in this work.

References

- Lam HC, Abdullah VJ, Soo G. Epiglottic cyst. *Otolaryngol Head Neck Surg.* 2000;122(2):311.
- Flint PW. Powered surgical instruments for laryngeal surgery. *Otolaryngol Head Neck Surg.* 2000;122(2):263–266.
- DeSanto LW, Devine KD, Weiland LH. Cysts of the larynx – classification. *Laryngoscope.* 1970;80(1):145–176.
- Su CY, Hsu JL. Transoral laser marsupialization of epiglottic cysts. *Laryngoscope.* 2007;117(7):1153–1154.
- Kawaida M, Kohno N, Kawasaki Y, Fukuda H. Surgical treatment of large epiglottic cysts with a side-opened direct laryngoscope and snare. *Auris Nasus Larynx.* 1992;19(1):45–50.
- Koltai PJ, Chan J, Younes A. Power-assisted adenoidectomy: total and partial resection. *Laryngoscope.* 2002;112(8 Pt 2 Suppl 100):29–31.
- Murray N, Fitzpatrick P, Guarisco JL. Powered partial adenoidectomy. *Arch Otolaryngol Head Neck Surg.* 2002;128(7):792–796.
- Parsons DS, Bothwell MR. Powered instrument papilloma excision: an alternative to laser therapy for recurrent respiratory papilloma. *Laryngoscope.* 2001;111(8):1494–1496.
- Rodriguez K, Murray N, Guarisco JL. Power-assisted partial adenoidectomy. *Laryngoscope.* 2002;112(8 Pt 2 Suppl 100):26–28.
- Yanagisawa E, Weaver EM. Endoscopic adenoidectomy with the microdebrider. *Ear Nose Throat J.* 1997;76(2):72–74.

11. Nuyens M, Zbaren P, Seifert E. Endoscopic resection of laryngeal and tracheal lesions using the microdebrider. *Acta Otolaryngol.* 2006;126(4):402–407.
12. Sant'Anna GD, Mauri M. Use of the microdebrider for Reinke's edema surgery. *Laryngoscope.* 2000;110(12):2114–2116.
13. McGarry GW, Gana P, Adamson B. The effect of microdebriders on tissue for histological diagnosis. *Clin Otolaryngol Allied Sci.* 1997;22(4):375–376.

Medical Devices: Evidence and Research

Dovepress

Publish your work in this journal

Medical Devices: Evidence and Research is an international, peer-reviewed, open access journal that focuses on the evidence, technology, research, and expert opinion supporting the use and application of medical devices in the diagnosis, treatment and management of clinical conditions and physiological processes. The identification of novel

devices and optimal use of existing devices which will lead to improved clinical outcomes and more effective patient management and safety is a key feature. The manuscript management system is completely online and includes a quick and fair peer-review system. Visit <http://www.dovepress.com/testimonials.php> to read real quotes from authors.

Submit your manuscript here: <http://www.dovepress.com/medical-devices-evidence-and-research-journal>