

Choroidal neovascular membrane following clear lens extraction

Banu Turgut Öztürk
Hürkan Kerimoğlu
Ümit Kamaş
Şaban Gönül
Süleyman Okudan

Selçuk University, Meram
Faculty of Medicine, Department
of Ophthalmology, Meram, Konya,
Turkey

Purpose: To emphasize the effect of an inflammatory event like lens extraction on choroidal neovascularization.

Case report: A 56-year-old woman was referred due to decreased vision in the right eye after bilateral clear lens extraction. The anterior segment examination was unremarkable and intraocular lenses were in the bag of both eyes. Fundus examination of the right eye revealed a choroidal neovascularization with retinal hemorrhage on the nasal edge and a predominantly classic subfoveal choroidal neovascularization was observed in fluorescein angiography. The photodynamic therapy raised the visual acuity from 37 letters to 62 letters at the first month follow-up visit. The membrane showed no sign of leakage at the control fluorescein angiography performed at the 3rd month and visual acuity remained the same.

Conclusion: The etiology of choroidal neovascularization has been subject to debate for many years. This case supports the suspects on the triggering effect of cataract surgery.

Keywords: high myopia, clear lens extraction, choroidal neovascularization

Introduction

Choroidal neovascularization (CNV) representing new blood vessels emanating from the choroid into the subretinal pigment epithelium, subretinal space or a combination of both, is a major source of vision loss in a variety of chorioretinal diseases (Green and Wilson 1986; Grossniklaus and Green 2004). Myopia is the second most common underlying disease of CNV after age related macular degeneration (Soubrane and Coscas 2006). It may be detected in 5%–10% of those with an axial length of 26.5 mm or more or with $>5D$ myopia (Grossniklaus and Green 1992; Soubrane and Coscas 2006). Though the breaks in Bruch's membrane (lacquer cracks) and atrophic areas has been demonstrated to increase susceptibility to the development of CNV, the triggering effect is still a matter of debate (Fernandez-Vega et al 2003; Soubrane and Coscas 2006). Here we presented CNV following clear lens surgery in a degenerative myopic patient without predisposing lacquer cracks.

Case report

A 46-year-old woman was referred to our clinic due to decreased vision in the right eye after bilateral clear lens extraction 4 months ago. According to the referring clinicians report her visual acuity was 20/25 in both eyes following an uncomplicated surgery. In our examination the patient's visual acuity was 20/63 with a correction of $-2.50D$ on the right eye and 20/25 with a correction of $-2.75D$ on the left eye. The anterior segment examination was unremarkable and intraocular lenses were in the bag of both eyes. Ultrasound examination revealed an axial length of 28 mm in both eyes and the patient declared her refraction to be $-23D$ preoperatively. Fundus examination of the right eye revealed a choroidal neovascular membrane with retinal hemorrhage on the nasal edge in addition to peripapillary atrophy (Figure 1).

Correspondence: Banu Turgut Öztürk
Selçuk Üniversitesi,
Meram Tıp Fakültesi, Göz
Hastalıkları AD, 42080-Meram/Konya,
Turkey
Tel +90 332 223 65 67
Fax +90 332 223 61 81
Email btozturk@selcuk.edu.tr,

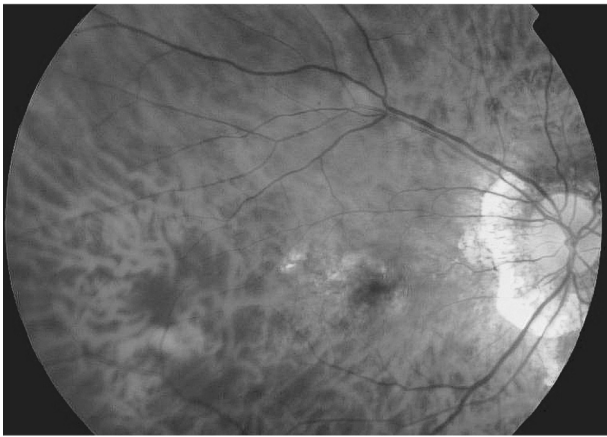


Figure 1 Fundus photographs of the case showing the choroidal neovascular membrane and peripapillary atrophy.

Following confirmation of the diagnosis with optical coherens tomography (Figure 2) and classification of the lesion as predominantly classic subfoveal choroidal neovascular membrane according to fluorescein angiography findings (Figure 3), photodynamic therapy with a spot size of 3800 microns is applied to the lesion. Visual acuity scored according to AREDS (Age Related Eye Disease Study) rose from 37 letters to 62 letters at the first month follow-up visit. The fluorescein angiography performed at the third month control visit showed just staining of the lesion and the visual acuity remained at the same level.

Discussion

Among the myopic fundus pathologies, CNV is the most common vision threatening complication (Avila et al 1984). A number of pathophysiologic pathways have led to the concept that CNV is a nonspecific wound repair response involving various degrees of inflammation (Grossniklaus

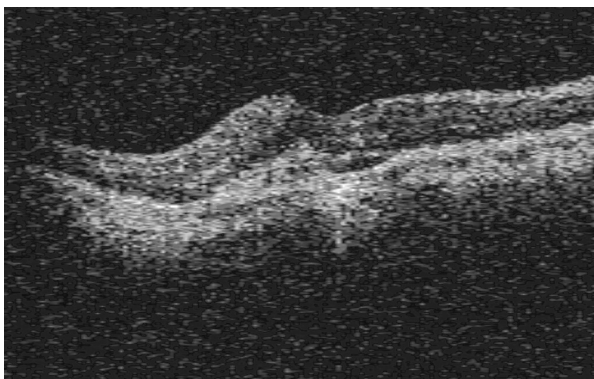


Figure 2 Optical coherens tomography images of the choroidal neovascularization.

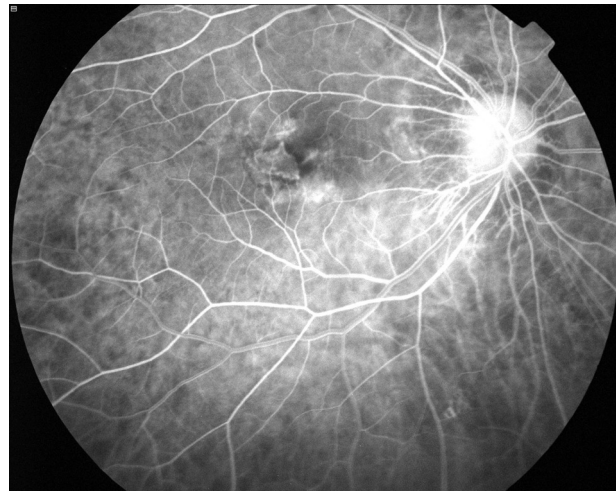

Figure 3 Fundus fluorescein angiography images showing the choroidal neovascular membrane.

et al 1992). In our case it is much debated whether the postoperative inflammation plays an inciting angiogenic role or the removal of the natural blue-light barrier induces the formation of choroidal neovascularization in the predisposed eye (Bradley et al 2005). Ruiz-Moreno et al (2004) suggested that surgical trauma was the cause of the development of CNV after cataract surgery in myopic eyes, while Blair and Ferguson (1979) claimed that the changes in the choroidal hemodynamics allow pre-existing new blood vessels to leak or bleed.

Lacquer cracks are considered as a significant predisposition for CNV according to the study of Fernandez-Vega et al (2003) who reported CNV after clear lens extraction in all patients with preoperative macular lacquer cracks. Our case report emphasizes the existence of other unknown factors in a myopic fundus as any Bruch membrane abnormality was lacking in the preoperative examination though not proved by fluorescein angiography. The study of Hayashi et al (2006) also found no difference between eyes with and without preoperative macular lacquer cracks for the development of CNV however the existence of myopic CNV in the fellow eye was stated as a risk factor for the operated eye. Another remarkable point in our case is the absence of any CNV in the left eye which was subject to the same procedures and following reactions. It raises questions about other triggering factors which are so far unknown.

Although the mechanism is not clear, prompt preoperative macular evaluation possibly with fluorescein angiography and attention to symptoms that might herald the presence of choroidal neovascularization is strongly recommended for degenerative myopic patients before clear lens extraction to

salvage vision. Otherwise an unsatisfied patient claiming your operation for the continuously decreasing visual acuity is inevitable.

Note

Presented as poster in Mediterranean Retina II 2006.

References

- Avila MP, Weiter JJ, Jalkh AE, et al. 1984. Natural history of choroidal neovascularization in degenerative myopia. *Ophthalmology*, 91:1573–81.
- Blair CJ, Ferguson J Jr. 1979. Exacerbation of senile macular degeneration following cataract extraction. *Am J Ophthalmol*, 87:77–83.
- Bradley TS, Belani S, Ho AC. 2005. Light energy, cataract surgery, and progression of age-related macular degeneration. *Curr Opin Ophthalmol*, 16:166–9.
- Fernandez-Vega L, Alfonso JF, Villacampa T. 2003. Clear lens extraction for the correction of high myopia. *Ophthalmology*, 110:2349–54.
- Green WR, Wilson DJ. 1986. Choroidal neovascularization. *Ophthalmology*, 93:1169–76.
- Grossniklaus HE, Green WR. 2004. Choroidal neovascularization. *Am J Ophthalmol*, 137:496–503.
- Grossniklaus HE, Green WR. 1992. Pathologic findings in pathologic myopia. *Retina*, 12:127–33.
- Grossniklaus HE, Martinez JA, Brown VB, et al. 1992. Immunohistochemical and histochemical properties of surgically-excised subretinal neovascular membranes in age-related macular degeneration. *Am J Ophthalmol*, 154:464–72.
- Hayashi K, Ohno-Matsui K, Futagami S, et al. 2006. Choroidal neovascularization in highly myopic eyes after cataract extraction. *Jpn J Ophthalmol*, 50:345–8.
- Ruiz-Moreno JM, Tavalato M, Montero JA, et al. 2004. Choroidal neovascularization in myopic eyes after phakic refractive lens and iris claw implantation. *Eur J Ophthalmol*, 14:159–62.
- Soubrane G, Coscas GJ. 2006. Choroidal neovascular membrane in degenerative myopia. In: Ryan SJ ed. *Retina*. 4th ed. California: Elsevier Mosby, vol II:1116–33.

