

# Anterior segment dysgenesis in a child with factor VII deficiency

Francis Beby<sup>1</sup>  
 Sandrine Meunier<sup>2</sup>  
 Pierre Cochat<sup>3</sup>  
 Olivier Roche<sup>4</sup>  
 Florent Aptel<sup>1</sup>  
 Carole Burillon<sup>1</sup>  
 Philippe Denis<sup>1</sup>

<sup>1</sup>Department of Ophthalmology, Edouard Herriot Hospital, Lyon, France; <sup>2</sup>Haemophilia Care Center, Department of Hemostasis, Edouard Herriot Hospital, Lyon, France; <sup>3</sup>Department of Pediatrics, Edouard Herriot Hospital, Lyon, France; <sup>4</sup>Department of Ophthalmology, Necker-Enfants Malades Hospital, Paris, France

**Purpose:** To describe the first case of anterior segment dysgenesis associated with factor VII congenital deficit (hypoproconvertinemia).

**Method:** A 2-month-old child with factor VII deficiency was referred to our clinic because of corneal opacities. The child was born to consanguineous parents and severe factor VII deficiency was diagnosed on the third day of life because of gastrointestinal bleeding.

**Result:** Ocular examination under anesthesia showed bilateral corneal opacities with adherent iris strands and peripheral anterior synechiae. The intra-ocular pressure was normal in both eyes and there were neither signs of cataracts nor glaucomatous optic nerve damage.

**Conclusion:** This observation provide new information on the possible ocular findings in patients with hypoproconvertinemia. Based on this report, we suggest that careful coagulation screening should be considered in children who possess idiopathic anterior segment dysgenesis aiming at identifying the possible coagulation disorder.

**Keywords:** anterior segment dysgenesis, factor VII deficit, hypoproconvertinemia, corneal opacity, intracranial hemorrhage

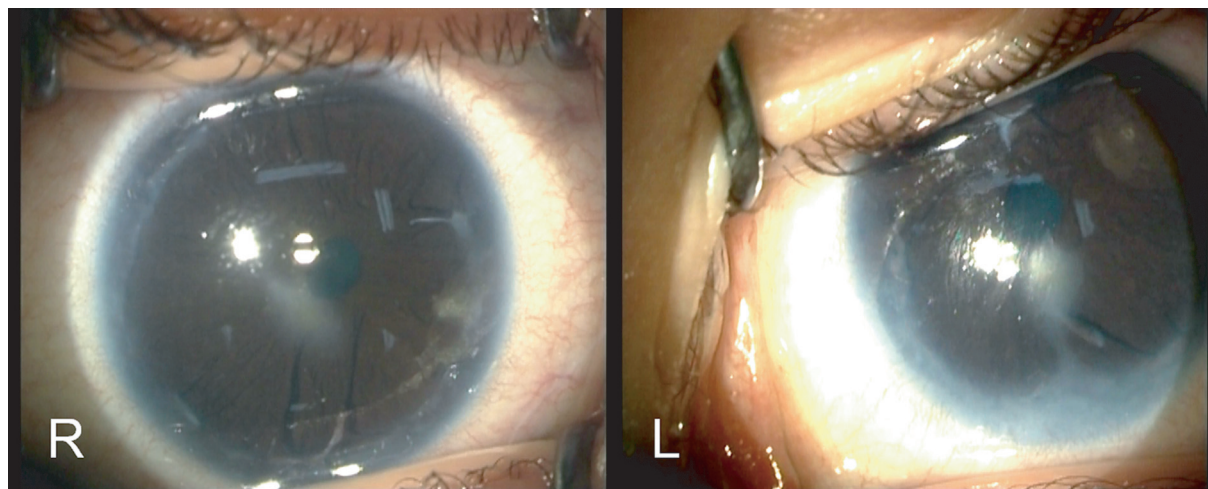
## Introduction

The purposes of this case report are double: (1) to provide new information on the possible ocular findings in patients with hypoproconvertinemia (factor VII deficit), (2) to suggest a careful coagulation screening in children who possess idiopathic anterior segment dysgenesis.

## Case report

A 2-month-old female baby was admitted with seizures leading to a diagnosis of subdural hematoma due to factor VII deficiency. The child was born to consanguineous parents after a normal pregnancy and delivery. There was no history of maternal intrauterine infection, toxemia or exposure to alcohol or drugs. Severe hypoproconvertinemia was diagnosed on the third day of life (factor VII activity below 2% of normal) because of gastrointestinal bleeding. She had no associated systemic abnormalities, no mental retardation and there was no family history of bleeding disorder or ocular abnormality. After urgent decompressive craniectomy and evacuation of hematoma, the child was referred to our clinic because of corneal opacities. The child showed no symptoms of conjunctivitis or keratitis in the neonatal period. Both pupils constricted to light stimulus, and no afferent pupillary defect could be seen. Careful ocular examination under anesthesia showed bilateral corneal opacities with adherent iris strands and peripheral anterior synechiae (Figure 1). On gonioscopy of the right eye, there were two localized iris adhesions to Schwalbe's line, in the 2-O'clock and 6-O'clock meridians. Gonioscopy of the left eye showed a white iris membrane with peripheral iris adhesion to clear cornea visible between 4- and 9-O'clock positions. There was no sign of neovascularization or staining with fluorescein. The intra-ocular pressure was normal in both eyes and there were neither signs of cataracts, ocular inflammation nor glaucomatous

Correspondence: Francis Beby  
 Department of Ophthalmology, Edouard Herriot Hospital, 30 Rue du Professeur Florence, 69003 Lyon, France  
 Tel +33 42 617 7966  
 Fax +33 42 617 7966  
 Email beby.francis@neuf.fr



**Figure 1** Operating room photographs of right eye (R) and left eye (L) showing paracentral corneal opacities with peripheral anterior synechiae and adhesions between the iris and the cornea.

optic nerve damage. Since the visual axis was not obstructed by corneal opacities, penetrating keratoplasty was not required. The patient was followed at two-month interval periods for a total of 12 months. Corneal opacities and intra-ocular pressure remained stable in both eyes during the follow-up period.

## Discussion

Hypoproconvertinemia is a rare autosomal recessive hemorrhagic disorder with a wide heterogeneous clinical pattern. The most severe form may be associated with severe hemorrhagic symptoms such as massive intracranial bleeding with a high mortality rate (Ingerslev and Kristensen 1998). To date, there are very little published data about the possible ocular findings associated with the bleeding disorder (Brooks et al 2006). To the best of our knowledge, this is the first report of anterior segment dysgenesis observed in a child with hypoproconvertinemia. In our case, possible diagnoses that must be considered include Peters anomaly, Axenfeld-Rieger anomaly and posterior embryotoxon. Classically, Peters anomaly presents as a central defect consisting of central corneal leucoma and adherence of iris and lens capsule to the cornea (Peters 1906; Maillette de Buy Wenniger-Prick and Hennekam 2002), Axenfeld-Rieger anomaly is a dominantly inherited ocular malformation characterized by corectopia or polycoria with iris hypoplasia (Lines et al 2002), and posterior embryotoxon represents a defect of the angle with a prominent and anteriorly displaced Schwalbe line but without corneal opacification (Sim et al 2004). Another congenital abnormality called fibrous congenital iris membranes, can lead to white iris membrane with peripheral iris adhesions, but the abnormality is always unilateral and cause pupillary

distortion with progressive occlusion or seclusion of the pupil (Robb 2001). Finally, none of these diseases appears to be a convincing diagnosis in our case. Therefore, we suggest the possibility that the ocular malformation may be part of the general disorder. Another possibility is that the patient could have a variety of other autosomal recessive mutations in other ocular genes. According to this view, further genetic investigations are needed in order to definitively establish the relationship between the two disorders. In our observation, the dysplasia of the anterior chamber may potentially lead to progressive corneal opacification and/or glaucoma, therefore requiring keratoplasty or filtering surgery, respectively. This fact is particularly important because most factor VII-deficient patients do have a surgical risk due to excessive blood loss during surgical procedures. Consequently, we suggest that careful coagulation screening should be considered in children who possess idiopathic anterior segment dysgenesis aiming at identifying the possible coagulation disorder and prevent perioperative bleeding in affected patients.

## Disclosure

**Research grants:** none.

**Financial support:** none.

**Competing interests:** the authors declare that they have no competing interests.

## References

- Brooks BP, Meck JM, Haddad BR, et al. 2006. Factor VII deficiency and developmental abnormalities in a patient with partial monosomy of 13q and trisomy of 16p: case report and review of the literature. *BMC Med Genet*, 7:2.
- Ingerslev J, Kristensen HL. 1998. Clinical picture and treatment strategies in factor VII deficiency. *Haemophilia*, 4:689–96.

- Lines MA, Kozlowski K, Walter MA. 2002. Molecular genetics of Axenfeld-Rieger malformations. *Hum Mol Genet*, 11:1177–84.
- Maillette de Buy Wenniger-Prick LJ, Hennekam RC. 2002. The Peters' plus syndrome: a review. *Ann Genet*, 45:97–103.
- Peters A. 1906. Ueber angeborene Defektbildung der Descemetischen Membran. *Klin Mbl Augenheilkd*, 44:27–40, 105–19.
- Robb RM. 2001. Fibrous congenital iris membranes with pupillary distortion. *Trans Am Ophthalmol Soc*, 99:45–50.
- Sim KT, Karri B, Kaye SB. 2004. Posterior embryotoxon may not be a forme fruste of Axenfeld-Rieger's Syndrome. *J AAPOS*, 8:504–6.

