

Long-term radiotherapy related complications in children with head and neck cancer: Another era for pediatric oncologic pathology

Nikolaos Eleftheriadis²
 Christos Papaloukas¹
 Damianos Eleftheriadis¹
 Apostolos Hatzitolios²
 Ioulia Ioannidou-Marathiotou³
 Kiki Pistevou-Gompaki¹

¹Department of Radiation Oncology, AHEPA University Hospital; ²Propedeutic Department of Internal Medicine, AHEPA University Hospital; ³Department of Orthodontics, School of Dentistry, Aristotle's University of Thessaloniki, Greece

Abstract: Long-term radiotherapy-related complications in children with head and neck cancer have been frequently reported, especially facial growth disorders and dental abnormalities. We report on two male children (8 and 14 years old) with head and neck cancer, who were successfully treated with chemoradiotherapy and presented with growth deficiency of middle face and mandible hypoplasia, eight years and one year later, respectively. These severe growth complications attributed to chemoradiotherapy, while the patients survived primary malignancy. Patient age at irradiation was significantly correlated with the severity of disorders. We consider late sequelae in children with head and neck cancer due to chemoradiotherapy another era for pediatric oncologic pathology for prevention, if possible, or to manage them efficiently.

Keywords: radiotherapy, head and neck cancer, growth disorders

Introduction

Nasopharyngeal carcinoma (NPC) is scarcely reported in children,¹⁻³ more often of undifferentiated type, while combined chemoradiotherapy constitutes the treatment of choice for this malignancy with promising results.³⁻⁵ Overall survival between 50% and 77% is reported.²⁻⁴ However, the high radiation doses needed to be effective, resulted in long-term toxicity with hard and soft tissues growth complications, particularly in young children that still present growth potential.^{4,5} Particularly, facial growth retardation, dental abnormalities, visual/orbital problems, neuroendocrine dysfunction, cognitive toxicity, and hypothyroidism have been reported in children with head and neck cancer post-irradiation.^{6,7} Patient age at irradiation is significantly correlated with the severity of disorders.^{8,9} Xerostomia, oral mucositis, late visual and auditory toxicity have also been reported as frequent and potentially severe complications of radiotherapy.^{10,11}

The idea of pediatric oncologic pathology has been recently proposed by Lacey and Clarke,¹² who reported on two children with leukemia, treated with combined radiotherapy and chemotherapy, survived from malignancy but suffered in long-term from bilateral slipped capital femoral epiphyses (SCPE) or bilateral avascular femoral head necrosis, respectively, as a consequence of radiochemotherapy.

We would like to further report on two male children (8 and 14 years old) with head and neck cancer, who were successfully treated with combined chemoradiotherapy, survived malignancy, but presented with growth deficiency of middle face and mandible hypoplasia, eight years and one year later, respectively.

Case report A

A 16-year-old male presented to the outpatient radiotherapy–oncology department, with severe growth deficiency of middle and lower face (Pierre Robin-like syndrome),

Correspondence: Kiki Pistevou-Gompaki
 Radiation-Oncology Department,
 AHEPA University Hospital, Gigenon 2,
 N Mihaniona, PC 57019, Thessaloniki,
 Greece
 Tel +30 2310 994 727
 Fax +30 2310 994 722
 Email kipiste@med.ath.gr

mandible hypoplasia, and poor oral hygiene for further evaluation and treatment. He had an eight-year known history of nasopharyngeal undifferentiated squamous cell carcinoma (NPC), histologically diagnosed (according to World Health Organization, Type II cT3cN3T0, grade IV).

At that time, he was successfully treated with combined chemoradiotherapy according to the following protocol: radiotherapy followed by adjuvant endoxan–fluouracil–vincristine chemotherapy at 28-day intervals for two years.

Radiotherapy plan was conducted by two dimensional (2D) computerized treatment planning system (Telemaque Technos, Technologies-Informatiques SA, Trappes, France). Primary site and bilateral upper neck received 60 Gy in 33 fractions over 6.5 weeks and lower neck–supraclavicular fossae received 40 Gy in 22 fractions over 4.5 weeks. A two-phase technique was used.

Following conventional simulation and using a Cobalt-60 gamma rays unit, radiotherapy was initially delivered by large parallel-opposed lateral fields to a dose of 36 Gy given in four weeks, 180 cGy per day. Treatment field extended superiorly to the inferior orbital margin, inferiorly to C6 spinous process, anteriorly to the anterior border of masseter muscle and posteriorly to T2 spinous process, encompassing all macroscopic disease, including spinal cord. To cover undetectable microscopic disease, the clinical target volume included the base of the skull, posterior half of nasal cavity, nasopharynx, base of sphenoid, para-pharyngeal space, lateral pharyngeal, posterior and upper deep cervical nodes. Brainstem, optic chiasm and anterior half of the orbit were shielded. During the second phase of treatment the parallel-opposed lateral fields were reduced posteriorly to exclude the spinal cord and a further dose of 24 Gy was given over 2.5 weeks, 180 cGy per day, achieving a total dose of 60 Gy in 33 fractions.

The size of the malignancy before and after treatment was estimated with magnetic resonance imaging (Figures 1A, B). A complete response both of the primary tumor and the locoregional lymph nodes was achieved one month after the end of the treatment (Figures 1C, D).

Since then he is totally asymptomatic and free of malignancy. Clinical examination during the eight-year follow-up post-irradiation showed partial mandible mobility and opening, mild xerostomia, mandible skeletal relation type II with mandible hypoplasia while the mouth opening was slightly deteriorated (higher opening diameter 35 mm). Multiple caries lesions were found on almost all teeth, but the lesions of the canines, premolars, and molars were more significant. Patient's oral hygiene was poor with plaque accumulation, severe localized inflammatory gingivitis, and gingival hyperplasia.

Radiological examination and cephalometric analysis showed sagittal symmetric hypoplasia of the lower facial part, microgenia, maxillary protrusion in relation to the anterior skull base, mandibular retrusion, dolichofacial growth pattern, normal lower facial height, normal mandibular length and posterior rotation of the mandible (clockwise rotation). Lower incisors were positioned in a normal distance to A/Pog plane, but with lingual inclination. The lower lip was found in posterior position in relation to the esthetic line and the nose seemed pronounced. Maxilla was narrow anteriorly, maxillary anterior teeth presented crowding and mandibular dental arch presented spaces distal to canines.

Mandible hypoplasia was characterized as traumatic post-irradiation hypoplasia of condyloid apophysis, while the deteriorating mouth opening attributed to periarticular tissue fibrosis. Oral hygiene guidelines in combination with tooth tissue replacement were given to our patient.

Case report B

A 15-year-old male with xerostomia was presented to the radiotherapy–oncology department for evaluation and management. The patient had one-year history of epipharyngeal carcinoma successfully treated with combined chemoradiotherapy. He was initially administered a total radiation dose of 6500 rads followed by chemotherapy with vincristine–cyclophosphamide–5-fluouracil–abirblastine at 28-day intervals for six months. Radiotherapy plan was conducted by 2D computerized treatment planning system (Telemaque Technos).

Since the completion of chemoradiotherapy, he is totally free from malignancy. One-year post-irradiation clinical examination revealed decreased mouth opening, oral xerostomia, multiple caries lesions on almost all teeth, skeletal mandible relations type I and vertical dolicholic face with soft tissue hypoplasia of parotic area. Radiological examination and cephalometric analysis showed lower normal development, with normal splanchnic skull with small mandible corner.

Decreased mouth opening and vertical dolicholic face outline were attributed to post-irradiation soft tissue fibrosis and parotid atrophy, while the small mandible corner attributed to traumatic effect of radiotherapy to the cartilage of condyloid apophysis. Oral hygiene guidelines in combination with tooth tissue replacement were also given to this patient.

Discussion

Long-term radiotherapy-related complications in children with head and neck cancer have been frequently reported

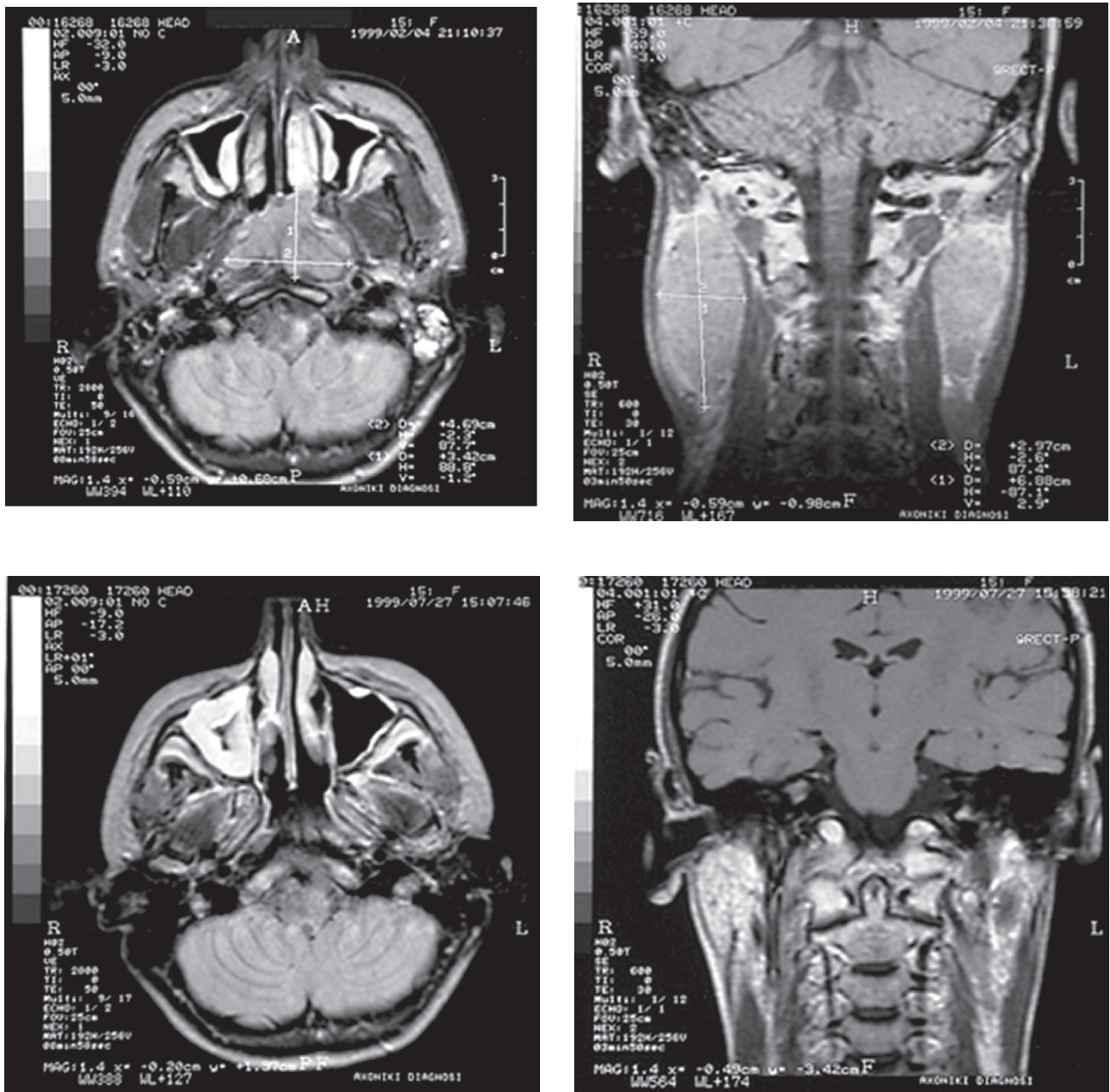


Figure 1 Magnetic resonance image showing the size of malignancy before treatment with chemoradiotherapy **A, B**, and the response after treatment **C, D**.

in literature, especially facial growth retardation, dental abnormalities, visual/orbital problems, neuroendocrine dysfunction, cognitive toxicity, and hypothyroidism.^{6,7} Frequency and severity of radiotherapy related effects are generally depended on total radiation dose, dose per session, type of tumor irradiated and radiation technique (treatment planning system). The lower harmful radiation dose reported is probably 1800–2000 rads.^{8,9} Developing bones are radio-sensitive with a consequence of the normal development deteriorating post-irradiation.

Moreover, the severity of developmental disturbances is related to patient age and treatment onset. The younger the age, especially prior to six years, the more severe the abnormalities,^{8,9} as was the case in our patients. Patient A, who was younger (8 years old) at the time of irradiation, presented more severe abnormalities than patient B (14 years old). Particularly, in patient A, who was irradiated when aged eight, when dentification was mixed and developmental activity of condyloid apophysis was also intense, more serious lesions were found, in relation to patient B, who was

irradiated when aged 14, when skeletal development was almost completed. Xerostomia, oral mucositis, late visual and auditory toxicity have also been reported as frequent and potentially severe complications of radiotherapy.^{10,11}

Nasopharyngeal carcinoma (NPC) is extremely rare in children¹⁻³ with overall survival between 50% and 77%.²⁻⁴ Combined chemoradiotherapy constitutes the treatment of choice for this malignancy, with promising results,³⁻⁵ which was also the case in patient A. However, the high radiation doses administered resulted in long-term toxicity with hard and soft tissues growth complications (middle face deficiency and mandible hypoplasia), particularly in our 8-year-old child who still had growth potential.^{4,5}

Sagittal type mandible hypoplasia presents wide range of clinical manifestations, from slight hypoplasia to severe Pierre Robin-like syndrome, as in our patient A and is characterized as traumatic post-irradiation symmetric severe hypoplasia or agenesis of condyloid apophysis. Furthermore, periarticular tissue fibrosis of temporomandibular articulation as a consequence of irradiation resulted in decreased mouth opening and articular motility limitation in patient A.

Moreover, soft tissue fibrosis and parotid atrophy resulted in vertical dolicholic face, while the small mandible corner in patient B was attributed to traumatic effect of radiotherapy to the cartilage of condyloid apophysis.

Many of these patients finally survive malignancy, but still suffer from severe morbidity due to the above complications, which need combined management and specific measures, such as surgical reconstruction and hormonal therapy.^{6,7} Lacey and Clarke¹² recently introduced the term pediatric oncologic pathology to mark a new era for pediatric oncologists. They reported on two children with leukemia treated with combined radiotherapy and chemotherapy, who survived malignancy, but suffered in the long-term from bilateral SCPE or bilateral avascular femoral head necrosis, respectively, as a consequence of radiochemotherapy.

According to our study, we consider late sequelae in children with head and neck cancer due to chemoradiotherapy

as another era for pediatric oncologic pathology in order for prevention, if possible, or to manage them efficiently.

Disclosure

The authors report no conflicts of interest in this work.

References

1. Pao WJ, Hustu HO, Douglas EC, Beckford NS, Kun LE. Pediatric nasopharyngeal carcinoma: long term follow up of 29 patients. *Int J Radiat Oncol Biol Phys.* 1989;17:299–305.
2. Uzel Ö, Yörük SÖ, Şahinler I, Turkan S, Okkan S. Nasopharyngeal carcinoma in childhood: long term results of 32 patients. *Radiation Oncol.* 2001;58:137–141.
3. Orbach D, Brisse H, Helfre S, et al. Radiation and chemotherapy combination for nasopharyngeal carcinoma in children: radiotherapy dose adaptation after chemotherapy response to minimize late effects. *Pediatr Blood Cancer.* 2008;50:849–853.
4. Carvalho AL, Nishimoto IN, Califano JA, Kowalski LP. Trends in incidence and prognosis for head and neck cancer in the United States: A site-specific analysis of the SEER database. *Int J Cancer.* 2005;114:806–816.
5. Rodriguez-Galindo C, Wofford M, Castleberry RP, et al. Preradiation chemotherapy with methotrexate, cisplatin, 5-fluorouracil, and leucovorin for pediatric nasopharyngeal carcinoma. *Cancer.* 2005;103:850–857.
6. Paulino AC, Simon JH, Zhen W, Wen BC. Long-term effects in children treated with radiotherapy for head and neck rhabdomyosarcoma. *Int J Radiat Oncol Biol Phys.* 2000;48(5):1489–1495.
7. Raney RB, Asmar L, Vassilopoulou-Sellin R, et al. Late complications of therapy in 213 children with localized, nonorbital soft-tissue sarcoma of the head and neck: A descriptive report from the Intergroup Rhabdomyosarcoma Studies (IRS)-II and -III. IRS Group of the Children's Cancer Group and the Pediatric Oncology Group. *Med Pediatr Oncol.* 1999;33(4):362–371.
8. Michalski JM, Meza J, Breneman JC, et al. Influence of radiation therapy parameters on outcome in children treated with radiation therapy for localized parameningeal rhabdomyosarcoma in Intergroup Rhabdomyosarcoma Study Group trials II through IV. *Int J Radiat Oncol Biol Phys.* 2004;59(4):1027–1038.
9. Dahllöf G. Craniofacial growth in children treated for malignant disease. *Acta Odontol Scand.* 1998;56:378–382.
10. Sonis ST, Elting LS, Keefe D, et al. Perspectives on cancer therapy-induced mucosal injury: pathogenesis, measurement, epidemiology, and consequences for patients. *Cancer.* 2004;100:1995–2025.
11. Rosenblatt E, Brook OR, Erlich N, Miller B, Joachims HZ, Kuten A. Late visual and auditory toxicity of radiotherapy for nasopharyngeal carcinoma. *Tumori.* 2003;89:68–74.
12. Lacey E, Clarke N. The big idea: paediatric oncological pathology – a new phenomenon. *J R Soc Med.* 2008;101(6):324–326.