

Lower eyelid lengthening surgery targeting the posterior layer of the lower eyelid retractors via a transcutaneous approach

Hirohiko Kakizaki
Masahiro Zako
Masayoshi Iwaki

Department of Ophthalmology, Aichi
Medical University, Nagakute-cho,
Aichi-gun, Aichi-ken, Japan

Abstract: The lower eyelid retractors consist of double layers, the posterior layer of which is the main tractional component. Therefore, shortening of the posterior layer of the lower eyelid retractors causes lower eyelid retraction or cicatricial entropion. Based on this concept, we report a modified lower eyelid lengthening surgery involving complete recession of the posterior layer of the lower eyelid retractors by way of a transcutaneous approach that leaves the palpebral conjunctiva intact and inserts ear cartilage as a rigid spacer between the lower edge of the tarsal plate and the recessed anterior layer of the lower eyelid retractors. This procedure completely extirpated the preoperative maladjusted states of lower eyelid retraction and cicatricial entropion. Our procedure also prevented postoperative discomfort of the ocular surface due to the intact palpebral conjunctiva. As well, lower eyelid mobility and contour were good and within their respective permissible ranges. The lower eyelid lengthening surgery focusing on the posterior layer of the lower eyelid retractors using auricular cartilage via a transcutaneous approach is a useful procedure for lower eyelid retraction or cicatricial entropion.

Keywords: posterior layer of the lower eyelid retractors, lower eyelid retraction, cicatricial entropion, ear cartilage, transcutaneous approach

Introduction

Shortening of the posterior lamella of the lower eyelid causes lower eyelid retraction (Henderson 1965; Harvey and Anderson 1981; Baylis et al 1985; Bartley and Kay 1989; Kerstern et al 1990; Cohen and Shorr 1992; Gardner et al 1992; Olver et al 1998; Fay et al 2001; Wearne et al 2001; Moon et al 2005; Patel et al 2005) or entropion (Bartley and Kay 1989; Cohen and Shorr 1992; Goldberg et al 1999), for which the shortened posterior lamella needs to be lengthened for treatment (Henderson 1965; Harvey and Anderson 1981; Baylis et al 1985; Bartley and Kay 1989; Kerstern et al 1990; Cohen and Shorr 1992; Gardner et al 1992; Olver et al 1998; Goldberg et al 1999; Fay et al 2001; Wearne et al 2001; Moon et al 2005; Patel et al 2005). The posterior layer of the lower eyelid retractors has to be targeted then because it represents the site of the pathology of such diseases (Kakizaki et al 2006a). Although the lower eyelid retractors were originally thought to consist of a complicated single layer (Hawes and Dortzbach 1982), they have now been revealed to be composed of a definite double layer (Kakizaki et al 2006a), consisting of anterior and posterior layers. The posterior layer, which is comprised of dense fibers of the capsulopalpebral fascia with scattered smooth muscle fibers and continues to the tarsus, is the main tractional component of the lower eyelid retractors (Kakizaki et al 2006a). Surgical operations targeting the posterior layer of the lower eyelid retractors for involutional lower eyelid entropion (Kakizaki et al 2007a) or reverse ptosis (Kakizaki et al 2007b), the pathologies of which are in the lower eyelid retractors, have been reported with good results.

Correspondence: Hirohiko Kakizaki
Department of Ophthalmology, Aichi
Medical University, Nagakute-cho, Aichi-
gun, Aichi-ken,
480-1195, Japan
Tel +81 561 62 3311
Fax +81 561 63 7255
Email cosme@d1.dion.ne.jp

The transconjunctival approach has been always taken in lower eyelid lengthening surgeries (Henderson 1965; Harvey and Anderson 1981; Baylis et al 1985; Bartley and Kay 1989; Kerstern et al 1990; Cohen and Shorr 1992; Gardner et al 1992; Olver et al 1998; Goldberg et al 1999; Fay et al 2001; Wearne et al 2001; Moon et al 2005; Patel et al 2005; Ben Simon et al 2006). The shortened posterior lamellae of the lower eyelid retractors can be lengthened by spacer techniques (Baylis et al 1985; Bartley and Kay 1989; Kerstern et al 1990; Cohen and Shorr 1992; Gardner et al 1992; Goldberg et al 1999; Fay et al 2001; Wearne et al 2001; Moon et al 2005; Patel et al 2005; Ben Simon et al 2006) or nonspacer techniques, such as recession, tenotomy or extirpation of the lower eyelid retractors (Henderson 1965; Harvey and Anderson 1981; Olver et al 1998). Since the latter techniques have limited indications (Olver et al 1998; Wearne et al 2001) because of their lack of rigidity or postoperative fibrous contraction, spacer techniques are usually selected (Cohen and Shorr 1992; Olver et al 1998; Wearne et al 2001). The hard palate mucosa and nasal turbinate mucosa are often used as autologous spacers (Bartley and Kay 1989; Kersten et al 1990; Cohen and Shorr 1992; Wearne et al 2001; Patel et al 2005; Ben Simon et al 2006), since they have a mucosal surface of appropriate rigidity (Cohen and Shorr 1992; Wearne et al 2001). Although keratinization can occur, it only irritates the ocular surface (Kersten et al 1990; Ben Simon et al 2006; Cohen and Shorr 1992). As an alternative material, ear cartilage is sometimes used via a transconjunctival approach (Baylis et al 1985; Moon et al 2005), and some of this remains exposed and requires removal (Kersten et al 1990). Although acellular human dermis is sometimes used as a substitution for autologous materials, evaluations of its use are not consistent because of a tendency to contract (Sullivan and Dailey 2003; Li et al 2005). In many cases, the transconjunctival approach for lower eyelid lengthening is not suitable for maintaining a stable environment of the ocular surface. Successfully keeping the palpebral conjunctiva intact, namely a transcutaneous approach, is essential for maintaining a sound ocular surface environment.

In the present study, we report a modified lower eyelid lengthening surgery that completely recesses the posterior layer of the lower eyelid retractors by way of a transcutaneous approach to keep the palpebral conjunctiva intact. Ear cartilage is inserted between the lower edge of the tarsal plate and the recessed anterior layer of the lower eyelid retractors. We used ear cartilage as a rigid spacer (Olver et al 1998)

since it does not produce any exudates or keratin, whereas hard palate mucosa does (Cohen and Shorr 1992) and so is not suitable for confined spaces.

Patients and methods

The outcomes of patients receiving lower eyelid lengthening surgery between 2005 and 2006 were reviewed, as a retrospective case series, from clinical records held at the Department of Ophthalmology, Aichi Medical University. A total of 6 lower eyelids in 5 patients were then included in the study. The average age of the patients was 41.5 years (range: 24–79 years).

Indications for the surgery are thyroid-related lower eyelid retraction and cicatricial lower eyelid entropion, the pathological foci of which are in the lower eyelid retractors. Cases without pathological foci in the lower eyelid retractors, such as marginal entropion or compromised orbicularis action, were not included in this study.

Preoperative data of lower eyelid retraction patients are shown in Table 1. The position of the lower eyelid was measured relative to the lower corneal limbus in the primary position of gaze. Overall, 3 eyelids in 2 patients with thyroid-associated ophthalmopathy (TAO) showed lower eyelid retractions with entropion. Of these 2 patients, 1 (bilateral 3-mm retraction) demonstrated proptosis (19 mm OU) after a repeated modified Hotz procedure for lower eyelid entropion (Duke-Elder SS and MacFaul PA 1976). Modified Hotz procedure is used for entropion surgeries in which, via a trans-cutaneous incision, the pretarsal part of the orbicularis oculi muscle and the lower edge of the tarsus are sutured to evert the lower eyelid margin. On the other hand, the other patient (5-mm right and 4-mm left retractions) showed proptosis (26 mm OU) after right-sided twice-repeated modified Hotz procedures for lower eyelid entropion (Duke-Elder SS and MacFaul PA 1976). Despite the large amount of proptosis, this patient chose not to undergo orbital decompression and so only underwent an operation on the right lower eye-

Table 1 Preoperative data of lower eyelid retraction patients

Case number and side	1R	1L	2R	2L	3R	3L
Lower eyelid retraction (mm)	3	3	5	4	1	3
Proptosis (mm)	19	19	26	26	16	16
Preoperative intervention	None	None	Hotz	None	None	SS

Abbreviations: R, right; L, left; SS, squint surgery.

lid. As well, 1 left eyelid in 1 patient without proptosis (16 mm OU) showed a simple lower eyelid retraction after an earlier surgery for a squint (inferior rectus muscle recession) (Wearne et al 2001) due to an eye movement disorder caused by TAO. The other 2 right eyelids each had cicatricial entropion after repeated modified Hotz procedures for lower eyelid entropion (Duke-Elder SS and MacFaul PA 1976).

The lower eyelid mobility during a downward gaze and the contour of the lower eyelids were also estimated. Clinical data of the lower eyelid retraction cases were analyzed by Wilcoxon signed ranks test using the SPSS software 8.0 (SPSS, Chicago, Illinois). Statistical significance was defined as $P < 0.05$.

Surgical technique

Details of our operative methods for the exposure of the sheet-like lower lid retractors have been reported elsewhere (Kakizaki et al 2005, 2007a); actually as described for involuntal

entropion repair. For a retracted lower eyelid (Figure 1A), first, local anaesthesia was performed with 2 ml of 2% lidocaine and epinephrine (1:100,000 dilution). After exposing the retractors as much as possible (Figure 1B), the double layers of the retractors were clearly discerned (Figure 1C). In the cases here, the posterior layer of the lower eyelid retractors was always shrunken toward the orbit. Next, the lateral and medial horns of the lower eyelid retractors were incised at a width of 17 mm to disconnect the traction via the horns (Figure 1D). The harvested auricular cartilage was then interposed between the lower edge of the tarsus and the distal edge of the anterior layer of the lower eyelid retractors, while the posterior layer remained unfixated to any structures (Figure 1E). The cartilage was fixed with 5 sutures on each of the distal and proximal sides (Figure 1F). The volume of harvested auricular cartilage for the retraction patients was twice that of the retraction from the lower corneal limbus (Kersten et al 1990) with 1 mm of

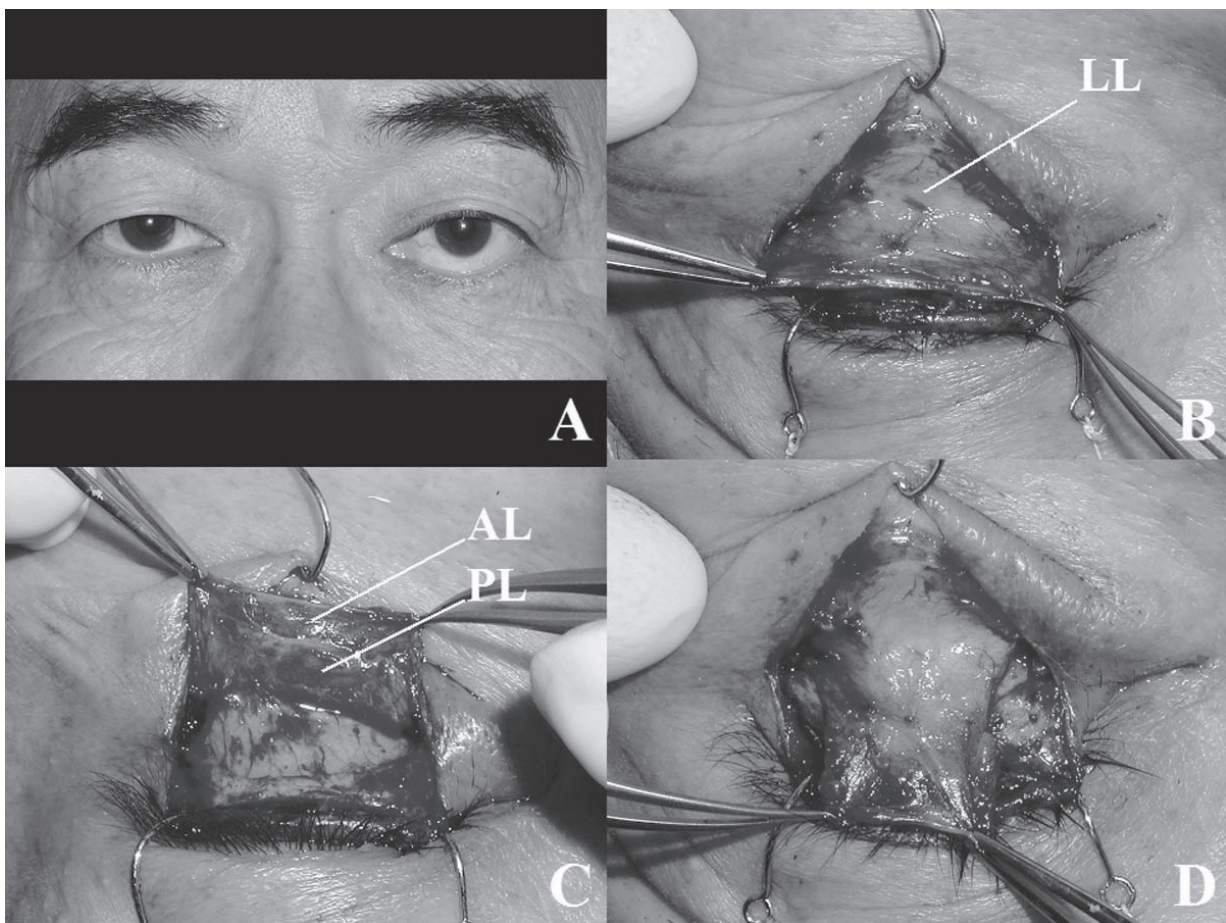


Figure 1A A 3-mm left lower eyelid retraction caused by previous surgery for a squint (inferior rectus muscle recession) is shown.

Figure 1B The anterior surface of the lower eyelid retractors is shown. Part of the Lockwood ligament can be seen.

Figure 1C The posterior surface of the lower eyelid retractors is shown. The double layers of the retractors can be clearly discerned. The posterior layer of the lower eyelid retractors is always shorter than the anterior layer.

Figure 1D The lateral and medial horns of the lower eyelid retractors are incised at the width of 17 mm.

extra volume in the proximal and distal margins, respectively, for sutures, while the height of the harvested auricular cartilage for the entropion patients was 4 mm (Cohen and Shorr 1992) (horizontal length in both groups was always constant at 17 mm). At the end of the procedure, the pretarsal orbicularis oculi muscle and the lower edge of the tarsus were secured at three points, which were permanently confined so that they did not touch the cilia on the ocular surface. The skin was sutured with interrupted 6-0 nylon sutures (Figure 1G); after which two tarsorrhaphy sutures were placed (Feldman et al 1992; McInnes et al 2006).

Results

The retracted lower eyelids were all elevated successfully to around the lower corneal limbi, with an average elevation of

2.88 mm (Table 2). However, outcomes were not statistically significant ($P = 0.066$). The entropion eyelids were improved in all cases. Although the minimum observation period was 3 months (ranging up to 23 months, mean follow-up time: 11.6 months), no exacerbation of the lower eyelid retraction or recurrence of entropion occurred. The lower eyelid moved down sufficiently during a downward gaze (Figure 1H) and the contour was within a permissible range (Figure 1I). Examples of preoperative and postoperative case photographs are shown in Figure 2.

Discussion

The lower eyelid lengthening procedure described here was clearly shown to recess the main tractional component of the posterior layer of the lower eyelid retractors. The palpebral

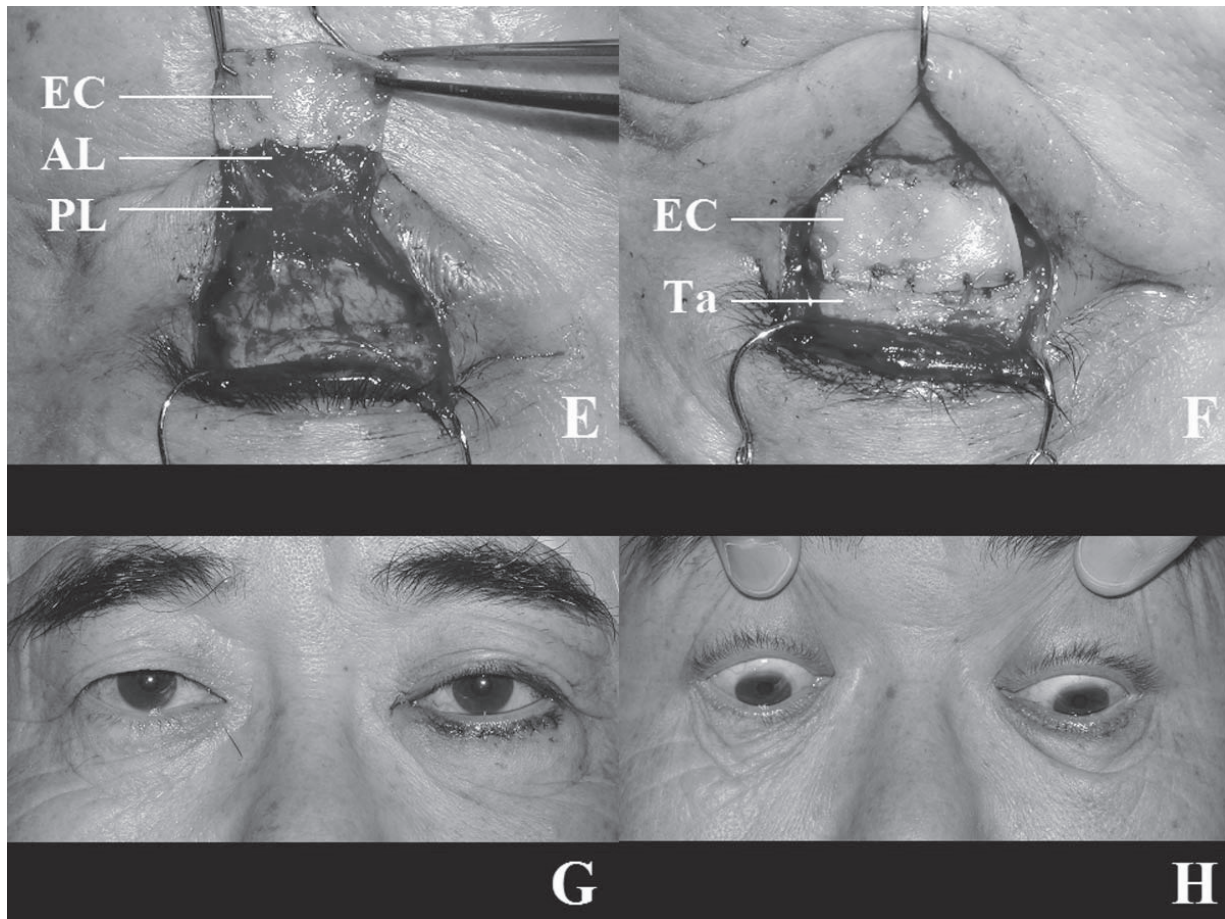


Figure 1E The harvested auricular cartilage is interposed between the lower edge of the tarsus and the distal edge of the anterior layer of the lower eyelid retractors while the posterior layer remains unfixed to any structure. The volume of the harvested cartilage for the retraction patients is twice the retraction from the lower corneal limbus with 1 mm of extra volume in the proximal and distal margins, respectively, for sutures. The height of the harvested cartilage for the entropion patients is 4 mm (horizontal length in both groups is always constant at 17 mm).

Figure 1F The cartilage is fixed with 5 sutures on each of the distal and proximal sides. The suture on the right upper edge is masked by the recessed anterior layer of the lower eyelid retractors in this image.

Figure 1G Sufficient elevation of the lower eyelid is shown. The skin is sutured with interrupted 6-0 nylon sutures.

Figure 1H The rehabilitated left lower eyelid moves down sufficiently during a downward gaze.

Table 2 Postoperative data of lower eyelid retraction patients

Case number and side	IR	IL	2R	3L	Average
Lower eyelid retraction (mm)	0	0	1.5	1	0.63
Retraction improvement (mm)	3	3	3.5	2	2.88

Abbreviations: R, right; L, left

conjunctiva remained intact, which prevented any postoperative discomfort of the ocular surface. Lower eyelid mobility was good and the contour was within a permissible range. We utilised the concept of recession of the lower eyelid retractors (Henderson 1965), in which a lack of rigidity or fibrous contracture (Olver et al 1998) are the main causes of the recurrence of retractions or entropion. These adverse effects were overcome using the skeletal structure of ear cartilage. Since we aimed at complete nullification of the posterior layer of the lower eyelid retractors, the spacer was only sutured to the anterior layer of the lower eyelid retractors.

Detaching the lower eyelid retractors from the subjacent conjunctiva has been thought difficult (Jones 1968). Therefore, lower eyelid lengthening surgeries have, to date, been performed via a transconjunctival approach. This procedure has always been successful in recessing the posterior layer of the lower eyelid retractors, to which both structural and epithelial elements were reconstructed using a spacer (Olver et al 1998; Fay et al 2001). However, not every spacer was suitable for the ocular surface due to keratinization or mechanical irritation (Kersten et al 1990), and so patients often experienced discomfort on the ocular surface. Although most of these adverse symptoms improved over the postoperative

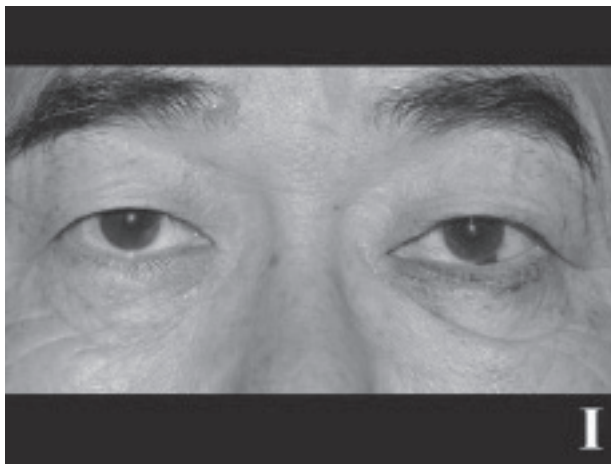


Figure 11 The contour of the left lower eyelid is within the permissible range.

Abbreviations: LL, Lockwood ligament; AL, anterior layer of the lower eyelid retractors; PL, posterior layer of the lower eyelid retractors; EC, ear cartilage; Ta, tarsus.

time course (Kersten et al 1990), patients were obliged to endure rather unpleasant conditions. We therefore believe that it is obviously logical not to harm the palpebral conjunctiva during recession of the lower eyelid retractors.

Auricular cartilage, which is hardly absorbed even in the long term (Ortiz-Monasterio et al 1981), is seen as a desirable spacer in a confined space because it does not produce any exudates or keratin (Cohen and Shorr 1992). However, it can present some adverse effects via the transconjunctival approach (Kersten et al 1990). Since the harvested cartilage is resilient, it has a curved contour, and a shallow incision on the concave surface can increase its flexibility and allow it to be flattened (Moon et al 2005). However, the margin of the cartilage is easily trimmed for fitting into the recipient bed (Moon et al 2005). Although a lower eyelid with inserted ear cartilage have been thought to be immobile during a downward gaze (Kersten et al 1990; Wearne et al 2001; Moon et al 2005), and to have an unnatural lid contour (Kersten et al 1990; Wearne et al 2001; Moon et al 2005), none of the patients in the present study exhibited any of these adverse states. Thus, we believe ear cartilage is an appropriate material for lengthening lower eyelids.

The orbicularis action can cause lower eyelid entropion (Collin and Rathbun 1978). That is, the pretarsal part of the orbicularis oculi muscle is always stable on the tarsus, but the preseptal part can move comparatively freely and override the pretarsal part (Kakizaki et al 2006b). The trans-cutaneous approach can prevent this overriding because of anterior cicatrisation. As well, fixing sutures between the tarsus and the pretarsal part of the orbicularis oculi muscle may help prevent the overriding of the preseptal part onto the pretarsal part. As anterior cicatrisation does not occur in the trans-conjunctival approach, the trans-cutaneous approach is more effective.

The scar might cause, however, further vertical traction on the lower eyelid and result in a less favorable outcome, because the main problem with trans-cutaneous lower eyelid surgery is scar formation in the anterior and middle lamellae of eyelids (skin, orbicularis and orbital septum) (Shorr and Fallor 1985; Shorr 1995). However, the operative invasion in the present procedure was essentially limited in the posterior lamella. As well, we did not remove any skin and did not dissect the layer between the orbicularis oculi muscle and the orbital septum, which enabled the anterior and middle lamellae to have an appropriate volume. In addition, the retracted or shortened posterior lamella was elongated by the auricular cartilage. For these reasons, we believe further vertical traction on the lower eyelid does not occur so severely as to affect the vertical lower eyelid height.

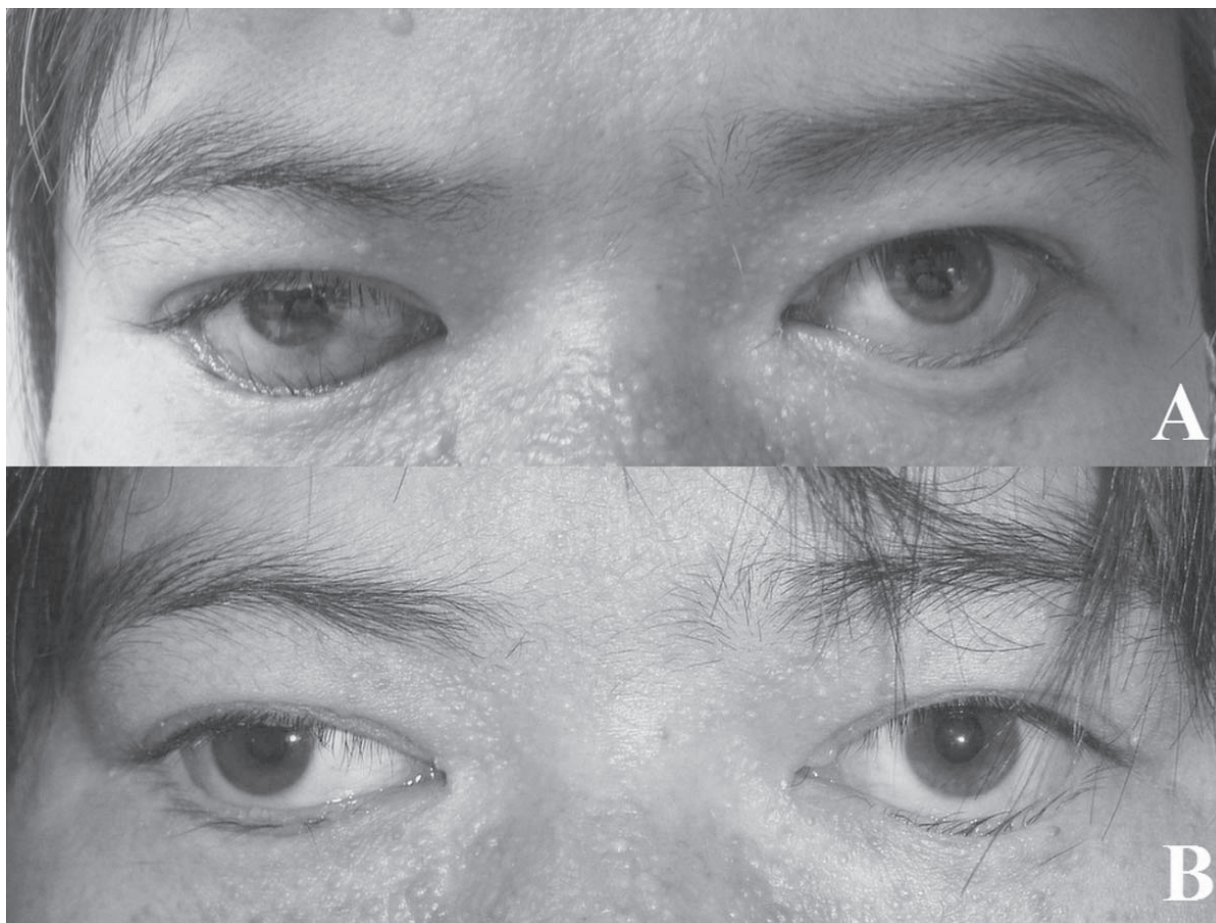


Figure 2A The patient shows 5-mm right and 4-mm left retractions from the lower corneal limbi with proptosis of 26 mm OU. Just the right lower eyelid took two Hotz procedures for the lower eyelid entropion.

Figure 2B After lower eyelid lengthening surgery, the right lower eyelid retraction and cicatricial entropion are sufficiently improved.

A midface lift with lateral canthal resuspension has recently been applied to lower eyelid retractions, such as in post-blepharoplasty, midface descent, and thyroid-related orbitopathy (Ben Simon et al 2006). It is important to note in the present procedure whether the anterior or middle lamella is targeted or not for therapy. Thyroid-related lower eyelid retraction, the main pathology for which is in the posterior lamella, is well treated by just our present procedure. As well, for entities including anterior and middle lamellae as well as the posterior lamella (Shorr 1995; Li et al 2005), such as in post-blepharoplasty lower eyelid retraction, our procedure also can help improve the pathology, simultaneously with rehabilitation of the anterior and middle lamellae. However, the present procedure cannot be separately applied to the cases with just anterior or middle lamellar cicatrix (Shorr and Fallor 1985; Shorr 1995) because our method only targets the posterior lamellar pathology.

Because of the small sample size, statistically significant outcomes could not be demonstrated in this study. However, the lower eyelid lengthening procedure clearly elevated retracted or cicatricial lower eyelids, and improved cicatricial entropion. Lower eyelid lengthening surgery focusing on the posterior layer of the lower eyelid retractors using auricular cartilage insertion via a transcutaneous approach was shown to be a useful procedure for lower eyelid retraction or cicatricial entropion.

Disclosure

There is no financial support or interest related to this manuscript.

References

- Bartley GB, Kay PP. 1989. Posterior lamellar eyelid reconstruction with a hard palate mucosal graft. *Am J Ophthalmol*, 107:609–12.
- Baylis HI, Perman KI, Fett DR, et al. 1985. Autogenous auricular cartilage grafting for lower eyelid retraction. *Ophthal Plast Reconstr Surg*, 1:23–7.

- Ben Simon GJ, Lee S, Schwarcz RM, et al. 2006. Subperiosteal midface lift with or without a hard palate mucosal graft for correction of lower eyelid retraction. *Ophthalmology*, 113:1869–73.
- Cohen MS, Shorr N. 1992. Eyelid reconstruction with hard palate mucosa grafts. *Ophthal Plast Reconstr Surg*, 8:183–95.
- Collin JRO, Rathbun JE. 1978. Involutional entropion. A review with evaluation of a procedure. *Arch Ophthalmol*, 96:1058–64.
- Duke-Elder SS, MacFaul PA. 1976. Abnormalities of the palpebral aperture. In: System of Ophthalmology vol. XIII—The Ocular adnexa. London, Henry Kimpton, pp 573–81.
- Fay AM, Pieroth L, Rubin PA. 2001. An animal model of lower eyelid spacer grafting with a cellular dermis. *Ophthal Plast Reconstr Surg*, 17:270–5.
- Feldman KA, Putterman AM, Farber MD. 1992. Surgical treatment of thyroid-related lower eyelid retraction: a modified approach. *Ophthal Plast Reconstr Surg*, 8:278–86.
- Gardner TA, Kennerdell JS, Buerger GF. 1992. Treatment of dysthyroid lower lid retraction with autogenous tarsus transplants. *Ophthal Plast Reconstr Surg*, 8:26–31.
- Goldberg RA, Joshi AR, McCann JD, et al. 1999. Management of severe cicatricial entropion using shared mucosal grafts. *Arch Ophthalmol*, 117:1255–9.
- Harvey JT, Anderson RL. 1981. The aponeurotic approach to eyelid retraction. *Ophthalmology*, 88:513–24.
- Hawes MJ, Dortzbach RK. 1982. The microscopic anatomy of the lower eyelid retractors. *Arch Ophthalmol*, 100:1313–8.
- Henderson JW. 1965. Relief of eyelid retraction: A surgical procedure. *Arch Ophthalmol*, 74:205–16.
- Jones LT. 1968. A new concept of the orbital fascia and rectus muscle sheaths and its surgical implications. *Trans Am Acad Ophthalmol*, 72:755–64.
- Kakizaki H, Zako M, Mito H, et al. 2005. Modified operation to correctly detect and fix the lower eyelid retractor in involutional entropion. *Jpn J Ophthalmol*, 49:330–2.
- Kakizaki H, Zhao J, Nakano T, et al. 2006a. The lower eyelid retractor consists of definite double layers. *Ophthalmology*, 113:2346–50.
- Kakizaki H, Zhao J, Zako M, et al. 2006b. Microscopic anatomy of asian lower eyelids. *Ophthal Plast Reconstr Surg*, 22:430–3.
- Kakizaki H, Zako M, Kinoshita S, et al. 2007a. Posterior layer advancement of the lower eyelid retractor in involutional entropion repair. *Ophthal Plast Reconstr Surg*, In press.
- Kakizaki H, Zako M, Iwaki M. 2007b. Reverse ptosis repair targeting the posterior layer of the lower lid retractor. *Ophthal Plast Reconstr Surg*, In press.
- Kersten RC, Kulwin DR, Levartovsky S, et al. 1990. Management of lower-lid retraction with hard-palate mucosa grafting. *Arch Ophthalmol*, 108:1339–43.
- Li TG, Shorr N, Goldberg RA. 2005. Comparison of the efficacy of hard palate grafts with acellular human dermis grafts in lower eyelid surgery. *Plast Reconstr Surg*, 116:873–8.
- McInnes AW, Burroughs JR, Anderson RL, et al. 2006. Temporary suture tarsorrhaphy. *Am J Ophthalmol*, 142:344–6.
- Moon JW, Choung HK, Khwarg SI. 2005. Correction of lower lid retraction combined with entropion using an ear cartilage graft in the anophthalmic socket. *Korean J Ophthalmol*, 19:161–7.
- Olver JM, Rose GE, Khaw PT, et al. 1998. Correction of lower eyelid retraction in thyroid eye disease: a randomised controlled trial of retractor tenotomy with adjuvant antimetabolite versus scleral graft. *Br J Ophthalmol*, 82:174–80.
- Ortiz-Monasterio F, Olmedo A, Oscoy LO. 1981. The use of cartilage grafts in primary aesthetic rhinoplasty. *Plast Reconstr Surg*, 67:597–605.
- Patel MP, Shapiro MD, Spinelli HM. 2005. Combined hard palate spacer graft, midface suspension, and lateral canthoplasty for lower eyelid retraction: a tripartite approach. *Plast Reconstr Surg*, 115:2105–14.
- Shorr N, Fallor MK. 1985. “Madame Butterfly” procedure: combined cheek and lateral canthal suspension procedure for post-blepharoplasty, “round eye,” and lower eyelid retraction. *Ophthal Plast Reconstr Surg*, 1:229–35.
- Shorr N. 1995. “Madame Butterfly” procedure: Total lower eyelid reconstruction in three layers utilizing a hard palate graft: Management of the unhappy post-blepharoplasty patient with round eye and scleral show. *Int J Aesthetic Restorative Surg*, 3:3–26.
- Sullivan SA, Dailey RA. 2003. Graft contraction: a comparison of acellular dermis versus hard palate mucosa in lower eyelid surgery. *Ophthal Plast Reconstr Surg*, 19:14–24.
- Wearne MJ, Sandy C, Rose GE, et al. 2001. Autogenous hard palate mucosa: the ideal lower eyelid spacer? *Br J Ophthalmol*, 85:1183–7.

