

Bedside echo for chest pain: an algorithm for education and assessment

Richard Amini
Lori A Stolz
Jeffrey Z Kartchner
Matthew Thompson
Nicholas Stea
Nicolaus Hawbaker
Raj Joshi
Srikanth Adhikari

Department of Emergency Medicine,
University of Arizona Medical Center,
Tucson, AZ, USA

Background: Goal-directed ultrasound protocols have been developed to facilitate efficiency, throughput, and patient care. Hands-on instruction and training workshops have been shown to positively impact ultrasound training.

Objectives: We describe a novel undifferentiated chest pain goal-directed ultrasound algorithm-focused education workshop for the purpose of enhancing emergency medicine resident training in ultrasound milestones competencies.

Methods: This was a cross-sectional study performed at an academic medical center. A novel goal-directed ultrasound algorithm was developed and implemented as a model for teaching and learning the sonographic approach to a patient with undifferentiated chest pain. This algorithm was incorporated into all components of the 1-day workshop: asynchronous learning, didactic lecture, case-based learning, and hands-on stations. Performance comparisons were made between postgraduate year (PGY) levels.

Results: A total of 38 of the 40 (95%) residents who attended the event participated in the chest pain objective standardized clinical exam, and 26 of the 40 (65%) completed the entire questionnaire. The average number of ultrasounds performed by resident class year at the time of our study was as follows: 19 (standard deviation [SD]=19) PGY-1, 238 (SD=37) PGY-2, and 289 (SD=73) PGY-3. Performance on the knowledge-based questions improved between PGY-1 and PGY-3. The application of the novel algorithm was noted to be more prevalent among the PGY-1 class.

Conclusion: The 1-day algorithm-based ultrasound educational workshop was an engaging learning technique at our institution.

Keywords: point-of care ultrasound, algorithm education, education, chest pain, bedside ultrasound, POCUS

Introduction

Point-of-care ultrasound (POCUS) continues to expand in all aspects of medicine. POCUS is a useful bedside diagnostic tool that can decrease the time to diagnosis and help determine a patient's disposition.¹⁻³ Goal-directed ultrasound protocols have been developed to facilitate efficiency, throughput, and patient care.^{1,4-7} These protocols are taught at numerous institutions and the most prevalent is the focused assessment with sonography for trauma, which is a ubiquitously used, goal-directed ultrasound protocol for assessment of an hypotensive patient after blunt abdominal trauma.⁸

This increasing use of POCUS was the impetus that drove the Accreditation Council for Graduate Medical Education to require emergency medicine (EM) residents to demonstrate competency in bedside ultrasound.⁹⁻¹¹ As a result, majority of the EM residency programs now integrate ultrasound training into the resident curriculum.¹²⁻¹⁴

Correspondence: Richard Amini
Department of Emergency Medicine,
University of Arizona Medical Center, PO
Box 245057, Tucson, AZ 85724-5057,
USA

Tel +1 520 626 9604

Fax +1 520 626 2480

Email richardamini@gmail.com



One of these requirements is training in bedside echocardiography; however, there is no standard format for education or assessment.¹² It is known that ultrasound hands-on instruction and training workshops have been demonstrated to positively impact ultrasound training. We describe a novel undifferentiated chest pain goal-directed ultrasound algorithm-focused education workshop for enhancement of the EM resident's training in ultrasound milestones.

Methods

Study design and setting

This was a single-center cross-sectional study conducted at an academic medical center. The study participants were 40 EM residents (postgraduate year [PGY]-1 to PGY-3) with varying ultrasound experience. Participation in the study was voluntary. This study was reviewed and approved by the University of Arizona institutional review board authority. Informed consent from participants was not required as per IRB. Data were collected from August 2014 to September 2014.

Algorithm-based ultrasound education

A 1-day educational workshop focusing on POCUS was integrated into one of the weekly EM residency didactic sessions. The educational theme for the ultrasound workshop was "The evaluation of patients with undifferentiated chest pain." During these educational sessions, a novel goal-directed ultrasound algorithm was used as a model for teaching and learning the sonographic approach to a patient with undifferentiated chest pain (Figure 1). This workshop was developed based on the recommendations made by the Council of

Emergency Medicine Residency Directors and the Academy of Emergency Ultrasound regarding the ultrasound competency skills necessary to evaluate and care for patients with undifferentiated chest pain.⁹ Instructors for this course were EM faculty, fellows, and residents with expertise in POCUS.

Educational curriculum

Prior to the ultrasound workshop, the residents were provided asynchronous learning assignments that included the novel goal-directed ultrasound algorithm, reading materials, video lectures, and information regarding other educational websites. The educational tools selected for asynchronous learning describe or demonstrate the POCUS applications relevant to patients with undifferentiated chest pain. The sonographic algorithm guided the instruction provided during the workshop. For example, during the cardiac ultrasound station, students were taught to look for sonographic signs consistent with pericardial effusion, aortic root dissection or aneurysm, ventricular size irregularities, global cardiac function, and ventricular wall motion irregularities. Trained actors were used as human models for the skill stations described in Table 1. This workshop was designed as a tool to improve ultrasound milestone education; during the different stations, residents were reminded that a normal echocardiogram does not rule out cardiac pathology. Residents were informed of the risks of misdiagnoses while they improve upon their echocardiography skills. Finally, residents were reminded that bedside echocardiography does not eliminate the need for patient medical history, physical examination, and blood sampling.

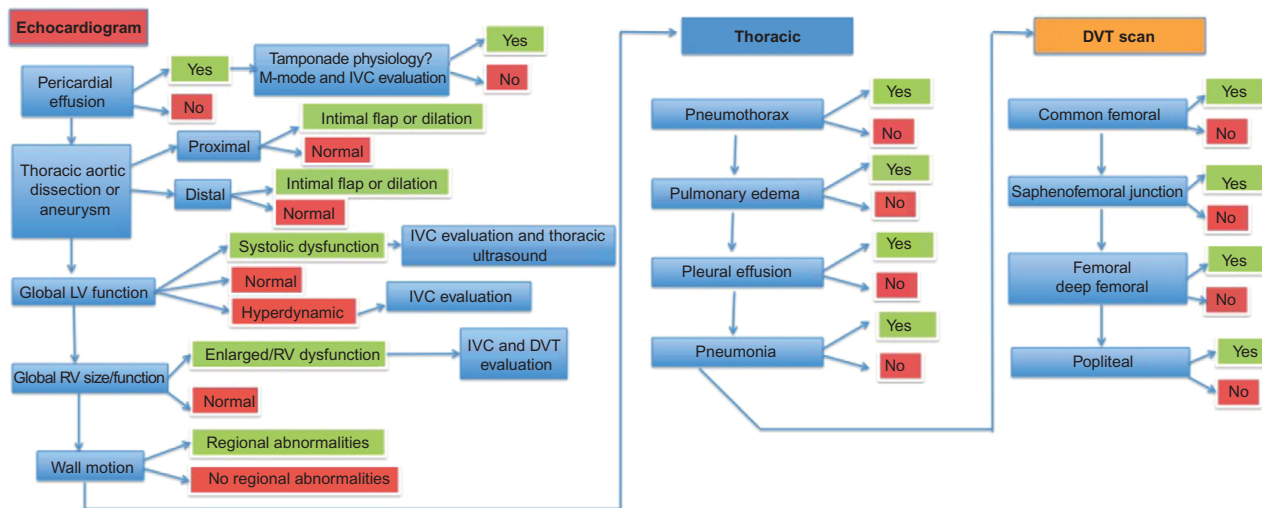


Figure 1 Undifferentiated chest pain sonographic algorithm.

Abbreviations: DVT, deep vein thrombosis; LV, left ventricle; RV, right ventricle; IVC, inferior vena cava.

Table 1 Skills station descriptions

Focused cardiac ultrasound	
Sonographic skills station	Learning objectives
The undifferentiated chest pain ultrasound algorithm: case-based review (30 minutes)	How to approach the undifferentiated chest pain patient using the ultrasound algorithm. In this station, residents were provided clinical scenarios with focused cardiac ultrasound images and clips. These cases demonstrated a variety of findings such as right ventricular dilatation, decreased cardiac function, wall motion abnormality, inferior vena cava evaluation, etc. While reviewing clinical images with the residents, the instructor described how the different components of the ultrasound algorithm can help improve patient care and decrease the time to a clinical diagnosis and disposition.
Focused cardiac ultrasound: hands-on station (30 minutes)	How to perform a focused cardiac ultrasound as it pertains to the goal-oriented undifferentiated chest pain algorithm. In this live model station, residents were given hands-on instruction on performing a focused cardiac ultrasound to help guide the management and diagnosis of undifferentiated chest pain. They were taught the methods necessary to obtain basic echo views, including subxiphoid, parasternal long, parasternal short, and apical four chamber. These views were then used to teach recognition and interpretation of IVC collapsibility, wall motion abnormalities, global ventricular function, pericardial effusion, tamponade physiology, and right ventricular dilatation.
Focused thoracic ultrasound: hands-on station (30 minutes)	How to perform a focused thoracic and lower extremity ultrasound, as it pertains to the goal-oriented undifferentiated chest pain algorithm. In this station, residents were taught to perform focused thoracic ultrasound on a model. This included identification of basic anatomy and lung sliding as well as identification of pneumothorax, pulmonary edema, focal pneumonia, and pleural effusion. Residents were also taught how to perform lower extremity ultrasound to evaluate for deep vein thrombosis at the level of the common femoral vein, saphenofemoral junction, and popliteal vein.
Undifferentiated chest pain ultrasound algorithm: objective standardized clinical examination (30 minutes)	Evaluation of resident performance on a focused cardiac ultrasound. In this station, the residents were required to perform a focused ultrasound for one of the three different clinical scenarios. One example was: "55-year-old male presents to the ER complaining of chest pain for 30 minutes. Patient is diaphoretic and mildly short of breath." Residents were allowed to perform a focused cardiac, thoracic, or lower extremity ultrasound, as it pertained to the ultrasound algorithm. Ultrasound videos and images pertinent to the case scenario were shown to the residents. The residents provided their final diagnosis at the end of the case to complete this station.

Abbreviations: ER, emergency room; IVC, inferior vena cava.

Assessment

Resident assessment of the algorithm-specific skills consisted of a 14-item multiple-choice questionnaire (Figure S1) and a hands-on objective standardized clinical exam (OSCE) (Figure S2). One month after the workshop, the students were surveyed on how many times they had incorporated the algorithm into their practice (Figure S3).

Data analysis

All analyses were performed using Stata 11 (StataCorp LP, College Station, TX, USA). Data are presented as means and percentages with 95% confidence intervals (CIs) and standard deviations (SDs). Continuous variables were compared between the PGY groups using the Student's *t*-test and Wilcoxon signed-rank test. The statistical level of significance was set at $P < 0.05$.

Results

A total of 38 of the 40 (95%) residents who attended the event participated in the chest pain OSCE, and 26 of 40 (65%) completed the entire questionnaire. The average number of

ultrasounds performed by the resident class year at the time of our study was as follows: 19 (SD=19) interns, 238 (SD=37) juniors, and 289 (SD=73) seniors. The average scores on the OSCE were 89% (SD=9) interns, 85% (SD=13) juniors, and 82% (SD=11) seniors. The average scores on the questionnaire were 70% (SD=16) interns, 82% (SD=7) juniors, and 77% (SD=15) seniors.

All the residents (100%) agreed that the undifferentiated chest pain ultrasound algorithm was useful in providing a stepwise approach to learning. Ninety-six percent (95% CI, 90%–100%) of residents agreed that the undifferentiated chest pain ultrasound algorithm was easy to understand. One student recommended that a mnemonic should be created to facilitate memorization of the algorithm.

One month after completion of the 1-day session, the residents were surveyed on how often they had incorporated the algorithm into their practice. Forty-two percent (95% CI, 22%–61%) had not used it, 42% (95% CI, 22%–61%) had used it on one to three occasions, 8% (95% CI, 0%–19%) had used in four to six times in the past month, and 8% (95% CI, 0%–19%) had used it more than six times.

Discussion

Due to the updated recommendations from the Accreditation Council for Graduate Medical Education EM milestone statement regarding ultrasound education, resident education and assessment should be adjusted accordingly.⁹ Whereas the assessment of most EM skills is conducted during clinical practice, ultrasound education and assessment can be restricted due to limited numbers of ultrasound-credentialed faculty at a given institution. As a result, education and assessment must be supplemented so that these new milestones can be met uniformly. Currently, there is no recommended standard for education or assessment of ultrasound milestones.^{12,15}

The Council of Emergency Medicine Residency Directors and the Academy of Emergency Ultrasound statement includes “Undifferentiated chest pain and/or dyspnea” as one of the clinical syndromes in which EM residents are expected to display ultrasound competency.⁹ This is a broad and complex clinical scenario that creates a challenge with regard to training and assessing EM residents. To overcome this challenge, we created a novel, goal-directed ultrasound algorithm to serve as the central focus of training during a workshop dedicated to teach ultrasound milestones. The use of goal-directed ultrasound protocols improves emergency department flow, efficiency, and patient care.^{1,4-7} A patient with undifferentiated chest pain is a complex scenario that is ideal for POCUS. These patients have sizable differential diagnoses and the literature demonstrates these patients are most likely to benefit from POCUS.¹⁻³ Similar algorithms exist for the diagnostic differentiation of other complex clinical scenarios (BLUE protocol, RUSH protocol), but the evaluation of these protocols as educational tools has not yet been explored.^{6,7} For this reason, our algorithm-based workshop was conducted during resident conference/didactic time.

To our knowledge, this is the first educational workshop that is led by the milestone recommendations and uses an algorithm protocol to direct education. Previous educational documents regarding POCUS have incorporated the use of asynchronous learning, didactic lectures, hands-on practical training, and ultrasound simulation models.^{16,17} From these previous studies, it would appear that, to successfully engage residents during conference sessions dedicated to POCUS, a balance should be attempted between hands-on training, concept education, and assessment. For this reason, the novel algorithm was introduced at multiple stages of learning and in conjunction with a variety of different educational strategies: as a part of asynchronous learning, didactic lectures, and during practical training.

The utilization of the OSCE as an assessment measure has been previously validated.^{18,19} Previous studies have used the OSCE when evaluating the efficacy of the focused assessment with sonography for trauma exam as an education tool for residents, but none have studied the efficacy of using more complex algorithms (BLUE protocol, RUSH protocol) as resident teaching tools.²⁰ Jones et al¹⁷ performed a study in which EM residents were given goal-directed echocardiography training and were then required to obtain adequate windows and identify anatomy. The use of the OSCE as an assessment tool, in the present study, not only demands the residents to obtain adequate windows and identify anatomy, but to follow a logical diagnostic sequence depending on the clinical scenario presented. The algorithm used during the educational sessions was also used as a method of assessment of resident performance.

All the residents (100%) agreed that the undifferentiated chest pain ultrasound algorithm was useful in providing a stepwise approach to learning. Ninety-six percent of residents agreed that the undifferentiated chest pain ultrasound algorithm was easy to understand. Although all residents performed well during the OSCE, our results demonstrate that the PGY-1 class performed best on the OSCE, which is unexpected given the average number of scans performed by this class was 19 (SD=19). In addition, the PGY-1 class outperformed the PGY-3 class in their ability to apply the chest pain ultrasound algorithm.

There are a few possibilities that may explain why the PGY-1 class was more proficient with the algorithm. It is possible that senior residents were less likely to benefit from a goal-oriented algorithm, as they are more proficient with cardiac ultrasound. It is also possible that senior residents may be less likely to prepare for didactic sessions and perhaps did not review the chest pain algorithm. In addition, the PGY-1 class had just completed an ultrasound boot camp and their ultrasound training was more recent than the PGY-2 and PGY-3 classes. Although the innovative algorithm was more likely to be incorporated by the younger PGY class, the knowledge-based cardiac ultrasound questionnaire scores improved across PGY class. This is expected as clinical knowledge should improve throughout residency training.

This diagnostic algorithm for the undifferentiated chest pain patient is unique and our study indicates that it can be easily learned. Unfortunately, it is possible that the complexity of such an algorithm can make it difficult to incorporate into clinical practice. During the month immediately after this workshop, residents performed 181 cardiac ultrasounds; during the previous 3 months, an average of 155 cardiac

ultrasounds had been performed. Only 8% of residents stated that they had incorporated the undifferentiated chest pain algorithm into their practice more than six times. Future studies should be conducted to determine methods for improving the implementation of this goal-directed ultrasound algorithm in clinical practice as well as its impact on patient outcomes.

Limitations

This study has several limitations, including a small sample size. Furthermore, the education and assessment curriculum was neither pilot tested nor validated prior to implementation. In this study we did not conduct the necessary pretesting of residents required to fully evaluate the overall effectiveness of our novel algorithm and curriculum. Residents' knowledge retention was assessed; however, we did not test the residents' ability to determine pathology, as we could not replicate sonographic pathology in a standardized fashion. During assessment of the OSCE, a checklist was used, which was designed to be dichotomous and simple with the hope of eliminating any bias introduced by the evaluators. This checklist had not been previously validated. Our study was not designed to assess the overall clinical impact of this algorithm-based ultrasound workshop. Furthermore, this ultrasound workshop is not sufficiently capable of teaching all the complexities and nuances of transthoracic echocardiography, nor was the workshop designed to eliminate the need for patient medical history, physical examination, and blood sampling. Finally, the follow-up survey was conducted only 1 month after the session; as a result, the frequency of use of the chest pain algorithm may have been underrepresented.

Conclusion

The 1-day algorithm-based ultrasound educational workshop was an engaging learning technique at our institution.

Acknowledgment

This abstract was presented at the Western Society for Academic Emergency Medicine Annual National Meeting in Tucson, AZ on March 27, 2015.

Disclosure

The authors report no conflicts of interest in this work.

References

- Schmidt GA, Koenig S, Mayo PH. Shock: ultrasound to guide diagnosis and therapy. *Chest*. 2012;142(4):1042–1048.
- Jones AE, Tayal VS, Sullivan DM, Kline JA. Randomized, controlled trial of immediate versus delayed goal-directed ultrasound to identify the cause of nontraumatic hypotension in emergency department patients. *Crit Care Med*. 2004;32(8):1703–1708.
- Manno E, Navarra M, Faccio L, et al. Deep impact of ultrasound in the intensive care unit: the "ICU-sound" protocol. *Anesthesiology*. 2012;117(4):801–809.
- Rose JS, Bair AE, Mandavia D, Kinser DJ. The UHP ultrasound protocol: a novel ultrasound approach to the empiric evaluation of the undifferentiated hypotensive patient. *Am J Emerg Med*. 2001;19(4):299–302.
- Volpicelli G, Lamorte A, Tullio M, et al. Point-of-care multiorgan ultrasonography for the evaluation of undifferentiated hypotension in the emergency department. *Intensive Care Med*. 2013;39(7):1290–1298.
- Perera P, Mailhot T, Riley D, Mandavia D. The RUSH exam: Rapid Ultrasound in SHock in the evaluation of the critically ill. *Emerg Med Clin North Am*. 2010;28(1):29–56, vii.
- Lichtenstein DA, Mezière GA. Relevance of lung ultrasound in the diagnosis of acute respiratory failure: the BLUE protocol. *Chest*. 2008;134(1):117–125.
- Amini R, Stolz LA, Gross A, et al. Theme-based teaching of point-of-care ultrasound in undergraduate medical education. *Intern Emerg Med*. 2015;10(5):613–618.
- Lewis RE, Pearl M, Nomura JT, et al. CORD-AEUS: consensus document for the emergency ultrasound milestone project. *Acad Emerg Med*. 2013;20(7):740–745.
- Noble VE, Nelson BP, Sutingco AN, Marill KA, Cranmer H. Assessment of knowledge retention and the value of proctored ultrasound exams after the introduction of an emergency ultrasound curriculum. *BMC Med Educ*. 2007;7:40.
- Kerwin C, Tommaso L, Kulstad E. A brief training module improves recognition of echocardiographic wall-motion abnormalities by emergency medicine physicians. *Emerg Med Int*. 2011;2011:483242.
- Amini R, Adhikari S, Fiorello A. Ultrasound competency assessment in emergency medicine residency programs. *Acad Emerg Med*. 2014;21(7):799–801.
- Hoyer R, Means R, Robertson J, et al. Ultrasound-guided procedures in medical education: a fresh look at cadavers. *Intern Emerg Med*. Epub 2015 Aug 15.
- Amini R, Kartchner JZ, Stolz LA, Biffar D, Hamilton AJ, Adhikari S. A novel and inexpensive ballistic gel phantom for ultrasound training. *World J Emerg Med*. 2015;6(3):225–228.
- Amini R, Kartchner JZ, Nagdev A, Adhikari S. Ultrasound-guided nerve blocks in emergency medicine practice. *J Ultrasound Med*. 2016;35(4):731–736.
- Parks AR, Atkinson P, Verheul G, Leblanc-Duchin D. Can medical learners achieve point-of-care ultrasound competency using a high-fidelity ultrasound simulator?: a pilot study. *Crit Ultrasound J*. 2013;5(1):9.
- Jones AE, Tayal VS, Kline JA. Focused training of emergency medicine residents in goal-directed echocardiography: a prospective study. *Acad Emerg Med*. 2003;10(10):1054–1058.
- Hofer M, Kamper L, Sadlo M, Sievers K, Heussen N. Evaluation of an OSCE assessment tool for abdominal ultrasound courses. *Ultraschall Med*. 2011;32(2):184–190.
- Newble D. Techniques for measuring clinical competence: objective structured clinical examinations. *Med Educ*. 2004;38(2):199–203.
- Sisley AC, Johnson SB, Erickson W, Fortune JB. Use of an Objective Structured Clinical Examination (OSCE) for the assessment of physician performance in the ultrasound evaluation of trauma. *J Trauma*. 1999;47(4):627–631.

Supplementary materials

1. Which patient position can be used to optimize cardiac views?
 - a. Left lateral decubitus
 - b. Prone position
 - c. Semireclined
 - d. Trendelenburg
2. Right ventricular free wall hypokinesis is associated with which of the following?
 - a. Fluid overload states
 - b. Left-sided heart failure
 - c. Pulmonary embolism
 - d. Tamponade physiology
3. Which of the following is a sign of severely decreased left ventricular function?
 - a. Anterior mitral valve leaflet early point separation from the septal wall of <0.5 cm
 - b. Fractional shortening that is >30%.
 - c. Less than 30% change in size of left ventricle chamber from systole to diastole
 - d. Near total collapse of the left ventricle at the end of systole
4. In the setting of pericardial effusion, one can evaluate for tamponade by looking specifically at which of the following?
 - a. Diastolic collapse of the right ventricle
 - b. Early diastolic filling of the right heart
 - c. Sonographic alternans
 - d. Systolic failure of the left ventricle
5. In a normal heart, the right ventricle is _____ the left ventricle's size.
 - a. Approximately 60% of
 - b. Double
 - c. Equal to
 - d. One-tenth the size of
6. A 55-year-old male with no cardiac history or significant past medical history presents complaining of substernal chest pain. No electrocardiogram is available. You place the probe on and see that the left ventricular free wall in the apical view (a4 view) appears to not be contracting. What is the likely diagnosis?
 - a. Anterior MI
 - b. Inferior MI
 - c. Lateral MI
 - d. Posterior MI
7. Measuring the aortic root to evaluate for proximal thoracic aortic aneurysm, what measurement is accepted as the upper limit of normal when measuring just past (distal to) the sinus of valsalva?
 - a. 2 cm
 - b. 3.5 cm
 - c. 4.5 cm
 - d. Depends on the age of the patient
8. A 50-year-old female with breast cancer presents complaining of sudden onset of shortness of breath. She has a previous diagnosis of deep vein thrombosis (DVT) in her left groin and is now hypotensive and tachycardic. Which ultrasound examination is most likely to be abnormal?
 - a. Aorta
 - b. Cardiac
 - c. Focused assessment with sonography for trauma
 - d. IVC
 - e. Thoracic
9. A 62-year-old male presents with chest pain, shortness of breath, and decreased left ventricular contractility on echo, and numerous B-lines on all lung fields on thoracic ultrasound. What is the next course of action?
 - a. Avoid intravenous fluids
 - b. Discharge
 - c. Normal saline bolus
 - d. Lactate ringer bolus
10. Patient presents complaining of CP and SOB. CP ultrasound algorithm reveals pericardial effusion with diastolic collapse of the right ventricle. PT blood pressure (BP) is 60/30. What is your next step?
 - a. Antibiotics
 - b. Fluids
 - c. Pericardiocentesis
 - d. Pressors
11. A 55-year-old male presents to the emergency department complaining of chest pain for 3 days. BP is 170/90. He was just discharged from an outside facility after three serial and negative troponins, but he continues to have pain. Electrocardiogram is unremarkable. Bedside ultrasound reveals: right ventricle size is 2/3 of left ventricle, mitral valve anterior leaflet appears to touch septal wall during atrial kick, and a proximal aortic root measures 4.8 cm. What is the appropriate next step?
 - a. Administer a fluid bolus
 - b. Lower the patient's BP
 - c. Lower the patient's BP and order a CT-angio of the chest
 - d. Perform bilateral DVT scans
12. What finding is most specific for pneumothorax
 - a. Duh sign
 - b. Goldfish sign
 - c. Lung point sign
 - d. Spine sign
13. You perform a lower extremity ultrasound to evaluate for DVT. Your d-dimer is negative and your bedside DVT scan is also negative. Which of the following is correct?
 - a. Repeat DVT ultrasound in 1 week
 - b. Start the patient on Lovenox
 - c. Without a radiology ultrasound we are useless
 - d. Your workup is complete, no further imaging required
14. When scanning a patient's RUQ, you see structures that appear to be hypoechoic when compared to liver. You suspect fluid. What additional finding can help you diagnose an effusion?
 - a. Duh sign
 - b. Hepatization of the lung sign
 - c. Lung point sign
 - d. Spine sign

Figure S1 Questionnaire

Abbreviations: BP, blood pressure; MI, myocardial infarction; IVC, inferior vena cava; CP, chest pain SOB, shortness of breath; PT, patient; CT, computed tomography; RUQ, right upper quadrant.



1. Introduce yourself to the patient			0	1
2. Enters patient identifiers			0	1
3. Select correct transducer/preset:				
a. Phased array (cardiac)			0	1
b. Curved or linear probe (thoracic)			0	1
c. Linear (deep vein thrombosis scan)			0	1
4. Places patient in proper position/probe correct location and correct orientation on patient			0	1
5. Adjust instrument controls: to optimize image				
a. Optimize (when necessary)			0	1
b. Adjust depth			0	1
c. Dual image (necessary for deep vein thrombosis studies)			0	1
6. Demonstrate knowledge of anatomy imaged in parasternal long axis view (you as the instructor ask them to freeze and name as many structures as they can.)				
a. Right ventricle			0	1
b. Left ventricle			0	1
c. Left atrium			0	1
d. Left ventricular outflow tract/aortic root			0	1
e. Descending aorta			0	1
f. Mitral valve			0	1
g. Aortic valve			0	1
7. Quality assessment				
1	2	3	4	5
No recognizable structure. No objective data. Could not obtain parasternal long axis view	Minimally recognizable structures. Insufficient for diagnosis. Two chambers or less.	Recognizable structures. Minimal criteria for diagnosis. Valves not great but all else visualized well.	All structures imaged well. Criteria met for diagnosis. All the above seven structures visualized. Perhaps not perfect cut of valves or oblique ventricle	Excellent images. Criteria met for diagnosis. Perfect symmetry and valves are crisp. I would put this in my lecture PowerPoint.
8. Undifferentiated chest pain algorithm				
Subxyphoid			0	1
Inferior vena cava			0	1
Parasternal long axis			0	1
Parasternal short axis			0	1
Apical four chamber			0	1
Anterior chest/pleural line evaluation			0	1
Costophrenic/pleural effusion evaluation			0	1
Deep vein thrombosis – femoral			0	1
Deep vein thrombosis – popliteal			0	1
9. Resident knows the four points of a deep vein thrombosis scan			0	1
10. Case diagnosis:			0	1
11. Prepares the machine for the next user			0	1

Figure S2 Undifferentiated chest pain objective standardized clinical exam

Notes: Not performed =0; performed =1.

- | | |
|--|---|
| <ol style="list-style-type: none"> 1. The use of the undifferentiated chest pain ultrasound algorithm was useful to gain a stepwise approach to this kind of patient. <ol style="list-style-type: none"> 1. Strongly agree 2. Somewhat agree 3. Somewhat disagree 4. Strongly disagree 2. The undifferentiated chest pain ultrasound algorithm was easy to understand. <ol style="list-style-type: none"> 1. Strongly agree | <ol style="list-style-type: none"> 2. Somewhat agree 3. Somewhat disagree 4. Strongly disagree <ol style="list-style-type: none"> 3. I have used the undifferentiated chest pain ultrasound algorithm on my patients in the emergency department _____. <ol style="list-style-type: none"> 1. 0 times 2. 1–3 times 3. 4–6 times 4. >6 times |
|--|---|

Figure S3 Follow-up survey

Advances in Medical Education and Practice

Dovepress

Publish your work in this journal

Advances in Medical Education and Practice is an international, peer-reviewed, open access journal that aims to present and publish research on Medical Education covering medical, dental, nursing and allied health care professional education. The journal covers undergraduate education, postgraduate training and continuing medical education

including emerging trends and innovative models linking education, research, and health care services. The manuscript management system is completely online and includes a very quick and fair peer-review system. Visit <http://www.dovepress.com/testimonials.php> to read real quotes from published authors.

Submit your manuscript here: <http://www.dovepress.com/advances-in-medical-education-and-practice-journal>