

Gefitinib and high-dose fractionated radiotherapy for carcinomatous encephalitis from non-small cell lung carcinoma

Eric T Wong^{1,2}
Julian K Wu^{2,3}
Anand Mahadevan^{2,4}

¹Department of Neurology, ²Brain Tumor Center and Neuro-Oncology Unit, ³Division of Neurosurgery, and ⁴Department of Radiation Oncology, Harvard Medical School, Beth Israel Deaconess Medical Center, Boston, MA, USA

Abstract: Carcinomatous encephalitis is a rapidly fatal form of metastasis caused by miliary spread of systemic cancer into the brain parenchyma. The diagnostic criteria and optimal treatment for this disease are not well defined. We report a patient with rapid neurologic deterioration from carcinomatous encephalitis from lung adenocarcinoma. She was treated with gefitinib and high-dose fractionated whole brain radiotherapy, and eventually improved neurologically and was discharged home on hospital day 48. Gefitinib and high-dose fractionated radiotherapy may have synergistic activity in patients with carcinomatous encephalitis from non-small cell lung cancer having favorable prognostic factors. More importantly, timely recognition of this disease and the use of large fraction radiation therapy are necessary to control rapid neurologic deterioration.

Keywords: brain metastases, Gefitinib, radiation

Introduction

Widespread cerebral metastases manifesting in a miliary pattern are known as “carcinomatous encephalitis” or “miliary metastases” (Madow and Alper 1951). This condition is seldom reported because of rapid patient demise and poor visualization on head CT or MRI due to microscopic metastases that have not yet developed tumor vasculature (Madow and Alper 1951; Nemzek et al 1993; Shirai et al 1997; McGuigan et al 2005). But as these tumors increase in size, enhancement would appear due to tumor angiogenesis (Hanahan and Weinberg 2000; Folkman 2002) and concurrent subarachnoid spread is possible. Although whole brain radiation is the standard treatment for brain metastases, there have been no reported cases to our knowledge describing a clinical response. We report here a patient with rapid neurologic deterioration from carcinomatous encephalitis from non-small cell lung cancer that was reversed by gefitinib and high-dose fractionated whole brain radiation, resulting in clinical improvement in cognition, resolution of tonsillar herniation and reversal of limb posturing and eye movement abnormalities.

Case report

A 39-year-old Chinese woman, non-smoker, experienced a 2-week history of progressive holocranial headaches, disorientation to time and place, dressing apraxia, and low back pain. Gadolinium-enhanced head MRI showed multiple hemorrhagic and ring-enhancing lesions in bilateral cerebral and cerebellar hemispheres (Figures 1a and 1b), accompanied by mild edema without obstructive hydrocephalus or herniation. She received dexamethasone 24 mg daily and was transferred to our hospital 2 days later. A body CT demonstrated a large mass in the upper lobe of left lung, as well as multiple enhancements in the liver and lumbar vertebral bodies without epidural disease. Her respective CEA and LDH levels were rapidly rising to 69 ng/ml and

Correspondence: Eric T Wong
Brain Tumor Center and Neuro-Oncology Unit, Beth Israel Deaconess Medical School, 330 Brookline Avenue, Boston, MA 02215, USA
Tel +1 617 667 1665
Fax +1 617 667 1664
Email ewong@bidmc.harvard.edu

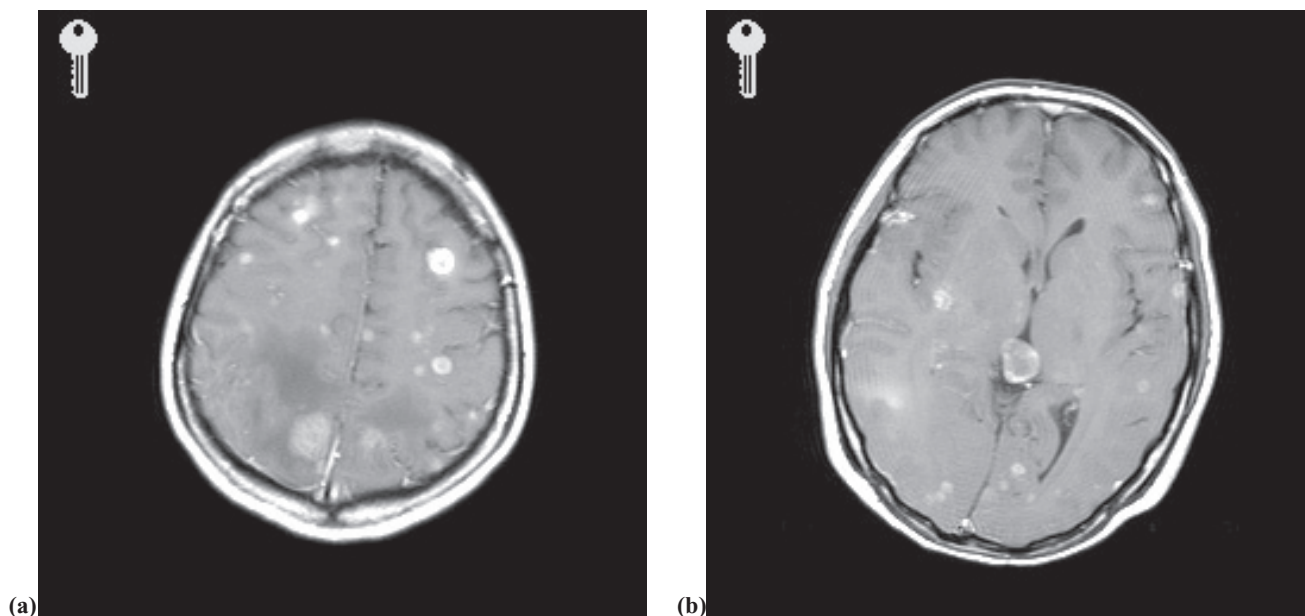


Figure 1 Day 4 axial post-gadolinium T1-weighted MRI prior to whole brain radiation, demonstrating multiple small enhancing lesions throughout brain parenchyma (a) and (b).

1,457 units/l. Biopsy of a liver lesion demonstrated adenocarcinoma, suggesting stage IV non-small cell lung carcinoma. On hospitalization day 8, she received carboplatin (AUC 6) and paclitaxel (200 mg/m²) and experienced increasing headaches and vomiting. On day 11, after receiving 1 mg lorazepam and 20 mg dexamethasone prior to whole brain radiation, she became unresponsive and had left-arm flexor posturing. Her radiation was withheld. She received 0.2 mg intravenous flumazenil, 10 mg dexamethasone, and 1,000 mg phenytoin without improvement. A head CT showed increased cerebral edema with tonsillar herniation. Following intravenous mannitol, an intraventricular drain was placed at bedside. Her left arm flexor posturing resolved but she remained minimally responsive to verbal commands; she also had downbeat nystagmus and right conjugate eye deviation. On day 12, she began whole brain radiation with daily doses of 400 cGy for 5 days to a total dose of 2,000 cGy. On day 13, she started gefitinib at 250 mg daily and her phenytoin was switched to levetiracetam, a non-P450-enzyme-inducing anticonvulsant. By day 17, she became alert, appropriately responsive to verbal commands, and conversing in 2- to 3-word sentences. She had conjugate deviation of both eyes to the left on command. On day 30, CSF from her ventricular drain showed 5 WBC, 15 mg/dL protein, 121 mg/dL glucose, positive cytology for malignant cells, and positive for cultures for coagulase-negative *Staphylococcus*. She was treated with intrathecal and intravenous vancomycin. After 7 days of negative CSF cultures, she underwent ventriculoperitoneal

shunt placement. Her respective CEA and LDH dropped to 22 ng/mL and 419 units/L. She was discharged home on day 48 on gefitinib and levetiracetam, and later followed up in our ambulatory clinic. Two months after discharge, she returned to work part-time and ambulated with a cane. A repeat gadolinium-enhanced head MRI on day 68 showed near complete resolution of brain metastases (Figures 2a and 2b). But her liver and vertebral metastases only had a partial response.

Discussion

The metastases in our patient were located deep in the brain parenchyma and at the gray-white matter junction pointing to hematogenous spread of her lung adenocarcinoma. Her rapid neurologic deterioration associated with diffuse cerebral edema suggests that there were more metastases than could be visualized on MRI, indicating carcinomatous encephalitis as the likely diagnosis. However, the diagnostic criteria for this disease are poorly defined but clinicians often based their diagnosis on the presence of multiple non-enhancing parenchymal brain metastases in a miliary pattern as key findings. Such a narrowly defined criterion has limitations, and it does not incorporate clinical data and our understanding of tumor biology. First, gadolinium enhancement probably occurs when a tumor reaches a size large enough to promote angiogenesis (Folkman 2002). Although miliary tumors in carcinomatous encephalitis are non-enhancing initially, they would enhance eventually on MRI as they grow over time.

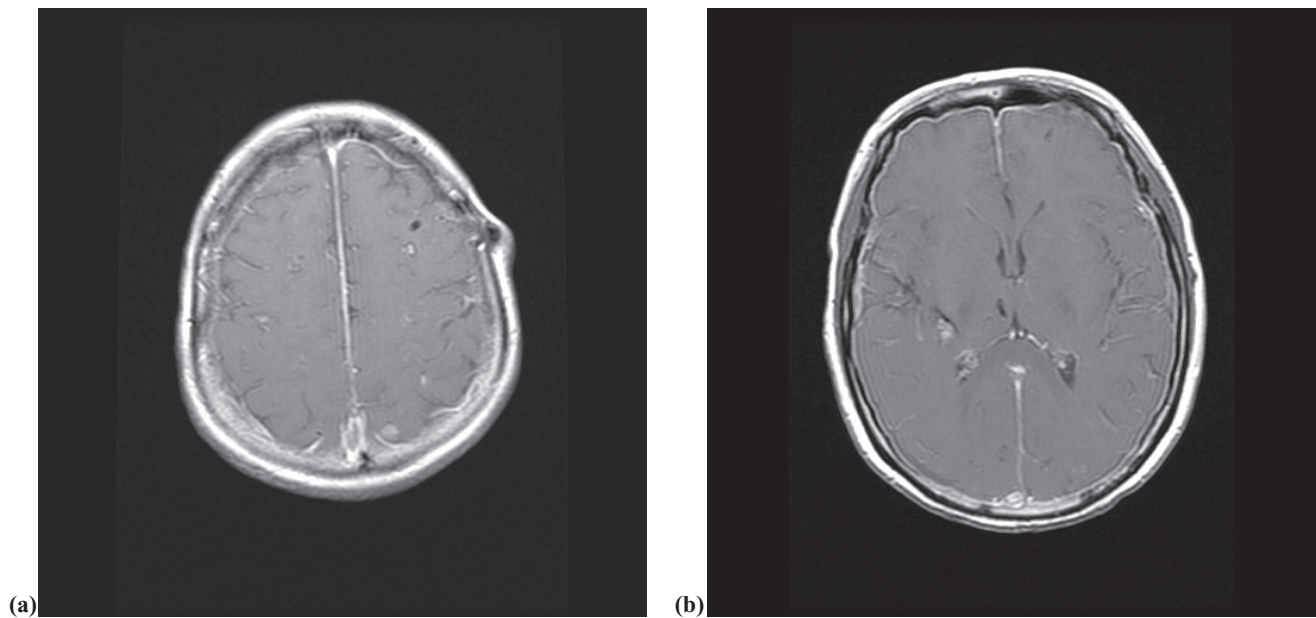


Figure 2 Day 69 axial post-gadolinium T1-weighted MRI after gefitinib and whole brain radiation, demonstrating resolution of multiple metastatic lesions (a) and (b). The pachymeningeal enhancement is related to ventriculoperitoneal shunting.

Second, rapid generalized neurologic deterioration is common in these patients. Lastly, given the rapid tumor progression, tumor cell infiltration into the subarachnoid space could be a natural progression of carcinomatous encephalitis.

In the United States, whole brain cranial irradiation at 300 cGy per fraction \times 10 fractions is the standard treatment for patients with brain metastases, particularly for those patients with poor performance status. However, due to her rapid neurological deterioration, our patient needed a radiation schedule that would offer the quickest response. Borgelt et al (1980) compared four treatment regimens, 200 cGy \times 20, 250 cGy \times 15, 200 cGy \times 15, and 300 cGy \times 10, and noted equivalent clinical radiobiological efficacy. We chose a high-dose fractionated schedule of 400 cGy \times 5 (Borgelt 1981) to achieve rapid tumor response and neurological improvement.

Gefitinib is a small molecule tyrosine kinase inhibitor of epidermal growth factor receptor (EGFR) that produced dramatic radiologic and clinical responses in 10% of patients with non-small cell lung cancer (Kris 2003). Female gender, non-smokers, adenocarcinoma histology, and Asian descent were prognostic factors favoring a response (Fukuoka 2003; Miller 2004). Somatic mutations that led to in-frame deletions and missense substitutions in the ATP-binding pocket of EGFR were responsible for this exquisite sensitivity to gefitinib (Sordella 2004; Han 2005; Mitsudomi 2005). We do not know the EGFR mutation status in our patient. But given

her gender, adenocarcinoma histology, lack of a smoking history, and Asian descent, she would be likely to have EGFR mutations that confer a favorable response to gefitinib. Furthermore, at standard dose of 250 mg daily or higher, gefitinib has efficacy against metastases in the brain parenchyma and leptomeninges (Katz 2003; Jackman 2006).

We think that the combination of gefitinib and high-dose fractionated cranial irradiation was responsible for this patient's rapid recovery and complete response in the brain. The neurological improvement seen in our patient was unlikely a result of gefitinib alone, since her liver and bone metastases had a limited response. There is preclinical data to support this notion because a combination of gefitinib and radiation had an additive cytotoxic effect on A431 cells (vulvar carcinoma cells that have high levels of EGFR) in vitro and a synergistic anti-tumor effect on GEO (human colon carcinoma), A549 (human non-small cell carcinoma), and MCF-7 (human breast carcinoma) xenografts in nude mice (Bianco 2002; Giocanti 2004). Interestingly, there was decreased tumor expression of transformation growth factor α , vascular endothelial growth factor, and basic fibroblast growth factor (Bianco 2002), suggesting mechanisms other than inhibition of EGFR signaling may be at work.

References

- Bianco C, Tortora G, Bianco R, et al. 2002. Enhancement of antitumor activity of ionizing radiation by combined treatment with the selective epidermal growth factor receptor-tyrosine kinase inhibitor ZD1839 (Iressa). *Clin Cancer Res*, 8:3250–8.

- Borgelt B, Gelber R, Kramer S, et al. 1980. The palliation of brain metastases: final results of the first two studies by the Radiation Therapy Oncology Group. *Int J Radiat Oncol Biol Phys*, 6:1–9.
- Borgelt B, Gelber R, Kramer S, et al. 1981. Ultra-rapid high dose irradiation for palliation of brain metastasis: final results two studies of the Radiation Therapy Oncology Group. *Int J Radiat Oncol Biol Phys*, 7:1633–8.
- Folkman J. 2002. Role of angiogenesis in tumor growth and metastasis. *Semin Oncol*, 29:15–18.
- Fukuoka M, Yano S, Giaccone G, et al. 2003. Multi-institutional randomized phase II trial of gefitinib for previously treated patients with advanced non-small-cell lung cancer. *J Clin Oncol*, 21:2237–46.
- Giocanti N, Hennequin C, Rouillard D, et al. 2004. Additive interaction of gefitinib ('Iressa', ZD1839) and ionizing radiation in human tumour cells in vitro. *Br J Cancer*, 91:2026–33.
- Han SW, Kim TY, Hwang PG, et al. 2005. Predictive and prognostic impact of epidermal growth factor receptor mutation in non-small-cell lung cancer patients treated with gefitinib. *J Clin Oncol*, 23:2493–501.
- Hanahan D, Weinberg RA. 2000. The hallmarks of cancer. *Cell*, 100:57–70.
- Jackman DM, Holmes AJ, Lindeman AJ, et al. 2006. Response and resistance in a non-small cell lung cancer patient with an epidermal growth factor receptor mutation and leptomeningeal metastases treated with high-dose gefitinib. *J Clin Oncol*, 24:4517–20.
- Katz A, Zalewski P. 2003. Quality-of-life benefits and evidence of antitumor activity for patients with brain metastases treated with gefitinib. *Br J Cancer*, 89 (Suppl 2):S15–18.
- Kris MG, Natale RB, Herbst RS, et al. 2003. Efficacy of gefitinib, an inhibitor of the epidermal growth factor receptor tyrosine kinase, in symptomatic patients with non-small cell lung cancer. *JAMA*, 16:2149–58.
- Madow L, Alper BJ. 1951. Encephalitic form of metastatic carcinoma. *Arch Neurol*, 65:161–73.
- McGuigan C, Bigham S, Johnston D, et al. 2005. Encephalopathy in a patient with previous malignancy but normal brain imaging. *Neurology*, 65:165.
- Miller VA, Kris MG, Shah N, et al. 2004. Bronchioalveolar pathologic subtype and smoking history predict sensitivity to gefitinib in advanced non-small cell lung cancer. *J Clin Oncol*, 22:1103–9.
- Mitsudomi T, Kosaka T, Endoh H, et al. 2005. Mutations of the epidermal growth factor receptor gene predict prolonged survival after gefitinib treatment in patients with non-small-cell lung cancer with postoperative recurrence. *J Clin Oncol*, 23:2513–20.
- Nemzek W, Poirer B, Salamat MS, et al. 1993. Carcinomatous encephalitis (miliary metastases): Lack of contrast enhancement. *Am J Neuroradiol*, 14:540–2.
- Shirai H, Imai S, Kajihara Y, et al. 1997. MRI in carcinomatous encephalitis. *Neuroradiology*, 39:437–40.
- Sordella R, Bell DW, Haber DA, et al. 2004. Gefitinib-sensitizing EGFR mutations in lung cancer activate anti-apoptotic pathways. *Science*, 305:1163–7.