

Progression to macula-off tractional retinal detachment after a contralateral intraoperative intravitreal bevacizumab injection for proliferative diabetic retinopathy

Michael W Stewart
Michael L Stewart

Department of Ophthalmology,
Mayo Clinic, Jacksonville, FL, USA

Dear editor

In a recent edition of *Clinical Ophthalmology*, Zlotcavitch et al presented a case of progressive diabetic traction retinal detachment in the fellow eye 1 week after vitrectomy with intravitreal bevacizumab.¹ This interesting observation extends previous original work by the same authors in which proliferative diabetic retinopathy was noted to regress following a bevacizumab injection into the fellow eye.² Several points pertaining to this thought-provoking report deserve further discussion.

Bevacizumab exits the eye through the trabecular meshwork and choroidal circulation, and enters the bloodstream unchanged. Since the intravitreal half-life of bevacizumab in human eyes is considerably shorter than the intravascular half-life (9.8 days³ vs 20 days⁴), the drug accumulates in the circulation. Concentrations increase initially, peak at approximately 2 weeks, and then decrease exponentially as intraocular concentrations fall further. Bevacizumab circulates to the fellow eye and enters both the vitreous and anterior chamber, although it remains unclear whether intravitreal or intravascular drug is primarily responsible for vascular inhibition. Since intravascular bevacizumab contacts neovascular endothelium directly, the blood concentration of bevacizumab, and not the intravitreal concentration, may be the primary determinant of contralateral effects.

Rabbit⁵ and monkey⁶ models, along with a small human study,⁷ show that bevacizumab exits the eye more rapidly following vitrectomy. The magnitude of the intravitreal half-life reduction varies between reports, but the 46% decrease contended by Zlotcavitch et al resulting in a human half-life of 5.3 days, is a reasonable assumption. With these rates in mind, we mathematically modeled the time-dependent intravitreal and intravascular bevacizumab concentrations in patients before and after vitrectomy. Using the half-lives mentioned above, the concentrations of bevacizumab following a 1.25 mg intravitreal injection are as follows:

Pre-vitrectomy: eye $[B]_v = 0.3125 * e^{-0.0707t}$; serum $[B]_s = 0.00078 * (e^{-0.033t} - e^{-0.0707t})$

Post-vitrectomy: eye $[B]_v = 0.3125 * e^{-0.131t}$; serum $[B]_s = 0.0005577 * (e^{-0.033t} - e^{-0.131t})$

where $[B]_v$ is the intravitreal concentration of bevacizumab and $[B]_s$ is the serum concentration of bevacizumab. The time-dependent concentrations of bevacizumab in both vitreous and serum can be seen in Figure 1.

Correspondence: Michael W Stewart
Department of Ophthalmology, Mayo
Clinic, 4500 San Pablo Rd, Jacksonville,
FL 32224, USA
Tel +1 904 953 2232
Fax +1 904 953 7040
Email stewart.michael@mayo.edu

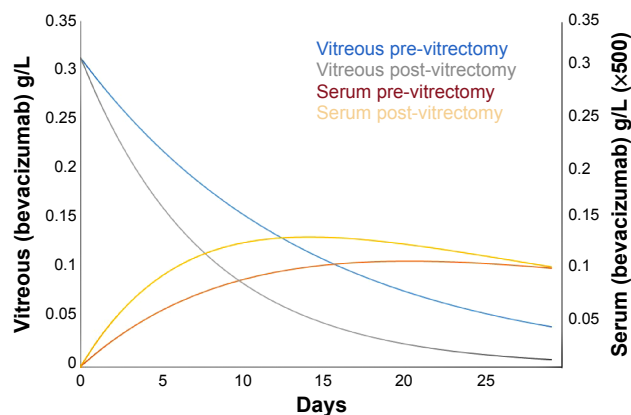


Figure 1 Time-dependent vitreous and serum bevacizumab concentrations in patients before and after vitrectomy.

Notes: In post-vitrectomy patients, the vitreous concentration falls more rapidly, leading to faster accumulation in the serum. The serum concentrations are amplified by a factor of 500 to fit the graph.

Several important observations regarding serum concentrations and the resultant exposure of the fellow eye to bevacizumab can be made from the graph. In a post-vitrectomy patient, the serum concentration rises faster and peaks earlier than in a pre-vitrectomy patient, with maximum concentrations at 14 days and 20 days, respectively. More importantly, the serum concentration at 7 days in a post-vitrectomy patient is 1.53 times that in a pre-vitrectomy patient and the area under the curve ratio through 7 days is 1.6 times. Therefore, a vitrectomy significantly increases the exposure of the fellow eye to bevacizumab during the first week, which helps to explain the observation made by Zlotcavitch et al.

As a monoclonal antibody against vascular endothelial growth factor (VEGF), bevacizumab works by decreasing the concentration of unbound (metabolically active) VEGF.

In eyes with proliferative diabetic retinopathy, the degree of fibrosis depends upon the relative amounts of connective tissue growth factor and VEGF. The introduction of bevacizumab alters the ratio of connective tissue growth factor to VEGF in favor of fibrosis,⁸ as occurred in this case.

Disclosure

The authors report no conflicts of interest in this communication.

References

1. Zlotcavitch L, Flynn HW Jr, Avery RL, Rachitskaya A. Progression to macula-off tractional retinal detachment after a contralateral intraoperative intravitreal bevacizumab injection for proliferative diabetic retinopathy. *Clin Ophthalmol*. 2015;9:69–71.
2. Avery RL, Pearlman J, Pieramici DJ, et al. Intravitreal bevacizumab (Avastin) in the treatment of proliferative diabetic retinopathy. *Ophthalmology*. 2006;113:1695.e1–e15.
3. Krohne TU, Eter N, Holz FG, Meyer CH. Intraocular pharmacokinetics of bevacizumab after a single intravitreal injection in humans. *Am J Ophthalmol*. 2008;146:508–512.
4. Avastin. Bevacizumab solution for intravenous infusion prescribing information. Available from: http://www.gene.com/download/pdf/avastin_prescribing.pdf. Accessed January 21, 2015.
5. Christoforidis JB, Xie Z, Jiang A, et al. Serum levels of intravitreal bevacizumab after vitrectomy, lensectomy and non-surgical controls. *Curr Eye Res*. 2013;38:761–766.
6. Kakinoki M, Sawada O, Sawada T, Saishin Y, Kawamura H, Ohji M. Effect of vitrectomy on aqueous VEGF concentration and pharmacokinetics of bevacizumab in macaque monkeys. *Invest Ophthalmol Vis Sci*. 2012;53:5877–5880.
7. Beer PM, Wong SJ, Hammad AM, Falk NS, O'Malley MR, Khan S. Vitreous levels of unbound bevacizumab and unbound vascular endothelial growth factor in two patients. *Retina*. 2006;26:871–876.
8. Van Geest RJ, Lesnik-Oberstein SY, Tan HS, et al. A shift in the balance of vascular endothelial growth factor and connective tissue growth factor by bevacizumab causes the angiofibrotic switch in proliferative diabetic retinopathy. *Br J Ophthalmol*. 2012;96:587–590.

Authors' reply

Leonid Zlotcavitch¹

Harry W Flynn Jr²

Robert L Avery³

Aleksandra Rachitskaya²

¹University of Miami, Miller School of Medicine, ²Bascom Palmer Eye Institute, Department of Ophthalmology, University of Miami, Miller School of Medicine, Miami, FL, USA; ³California Retina Consultants, Santa Barbara, CA, USA

Correspondence: Harry W Flynn Jr
900 NW 17th St, Miami, FL 33136, USA
Tel +1 305 326 6303
Fax +1 305 326 6417
Email hflynn@med.miami.edu

Dear editor

We read with interest the comments of Stewart et al regarding our case of progressive diabetic traction retinal detachment in the fellow eye 1 week after vitrectomy with the use of intravitreal bevacizumab.¹ The letter to the editor estimates the vitreous and serum time-dependent concentrations of

bevacizumab after an intravitreal injection in vitrectomized and non-vitrectomized eyes. These calculations support the clinical course observed in our patient. Further studies are necessary to quantitatively assess the possible bilateral effect of intravitreal medications and the effects of vitrectomy on the pharmacodynamics of anti-vascular growth factor agents. Although the bilateral response to a unilaterally injected medication is usually beneficial, one should be cognizant of potential progression of diabetic traction retinal detachment.

Disclosure

The authors report no conflicts of interest in this communication.

Reference

1. Zlotcavitch L, Flynn HW Jr, Avery RL, Rachitskaya A. Progression to macula-off tractional retinal detachment after a contralateral intraoperative intravitreal bevacizumab injection for proliferative diabetic retinopathy. *Clin Ophthalmol*. 2015;9:69–71.

Clinical Ophthalmology

Publish your work in this journal

Clinical Ophthalmology is an international, peer-reviewed journal covering all subspecialties within ophthalmology. Key topics include: Optometry; Visual science; Pharmacology and drug therapy in eye diseases; Basic Sciences; Primary and Secondary eye care; Patient Safety and Quality of Care Improvements. This journal is indexed on

Submit your manuscript here: <http://www.dovepress.com/clinical-ophthalmology-journal>

Dovepress

PubMed Central and CAS, and is the official journal of The Society of Clinical Ophthalmology (SCO). The manuscript management system is completely online and includes a very quick and fair peer-review system, which is all easy to use. Visit <http://www.dovepress.com/testimonials.php> to read real quotes from published authors.