

# Optical coherence tomography findings in paraneoplastic pseudovitelliform lesions in melanoma-associated retinopathy

Michael Javaheri<sup>1</sup>  
 Rahul N Khurana<sup>1</sup>  
 Rizwan A Bhatti<sup>1</sup>  
 Jennifer I Lim<sup>2</sup>

<sup>1</sup>Doheny Retina Institute, Doheny Eye Institute, Department of Ophthalmology, University of Southern California, Keck School of Medicine, Los Angeles, CA, USA; <sup>2</sup>Eye and Ear Infirmary, Department of Ophthalmology, University of Illinois, Chicago, IL, USA

**Purpose:** To report an unusual case of paraneoplastic pseudovitelliform lesions associated with melanoma-associated retinopathy (MAR).

**Design:** Observational case report.

**Methods:** Retrospective review of the ophthalmic examination, fundus photography, fluorescein angiography, electroretinogram (ERG), and optical coherence tomography (OCT) of a patient with MAR.

**Results:** A 65-year-old Caucasian man with a two-year history of metastatic melanoma was referred for evaluation of a six-month history of nyctalopia. Funduscopy examination in both eyes revealed multiple, creamy, yellow, pseudovitelliform lesions in the posterior pole, varying in size from 100–500 µm, at the level of the outer retinal/retinal pigment epithelium (RPE) junction, coalescing along the inferior portion, with overlying macular neurosensory detachments. OCT showed bilateral macular neurosensory detachments with multiple small areas of high reflectivity at the level of the outer retinal/RPE junction. ERG demonstrated a selective loss of the b-wave and a normal a-wave under dark adapted, scotopic conditions.

**Conclusion:** Clinicians should be aware of this atypical presentation of MAR that may include pseudovitelliform retinal findings.

**Keywords:** cancer-associated retinopathy, melanoma-associated retinopathy, optical coherence tomography, paraneoplastic syndrome, paraneoplastic pseudovitelliform retinopathy

Melanoma-associated retinopathy (MAR) is a rare paraneoplastic condition in patients with metastatic melanoma associated with an acute loss of vision, nyctalopia, and visual photopsias. The electroretinogram (ERG) in MAR resembles congenital stationary night blindness, with a markedly reduced b-wave and a normal dark-adapted a-wave (Potter et al 1999; Borkowski et al 2001; Zacks et al 2001). In addition, circulating antibodies to retinal bipolar cells have been associated with MAR (Potter et al 1999; Borkowski et al 2001; Zacks et al 2001; Palmowski et al 2002). In the majority of MAR cases, examination of the fundus reveals no abnormalities, although vascular attenuation and optic nerve pallor have been reported (Potter et al 1999; Borkowski et al 2001; Zacks et al 2001). We describe an unusual case of MAR in a patient with visceral malignant melanoma with associated pseudovitelliform retinal findings.

## Case report

A 65-year-old Caucasian male with a two-year history of metastatic melanoma was referred for a six-month history of nyctalopia. Melanoma was initially diagnosed in his small bowel, and later noted to also involve his kidneys, bladder, and brain. Past medical history was otherwise significant for well controlled hypertension. On examination, best-corrected visual acuity was 20/40 in both eyes. Pupillary exam,

Correspondence: Jennifer I Lim  
 Eye and Ear Infirmary, University of Illinois, 1855 W Taylor Street, Mail Code 648, Suite 2.50, Chicago, IL 60612, USA  
 Email jennyylim@uic.edu

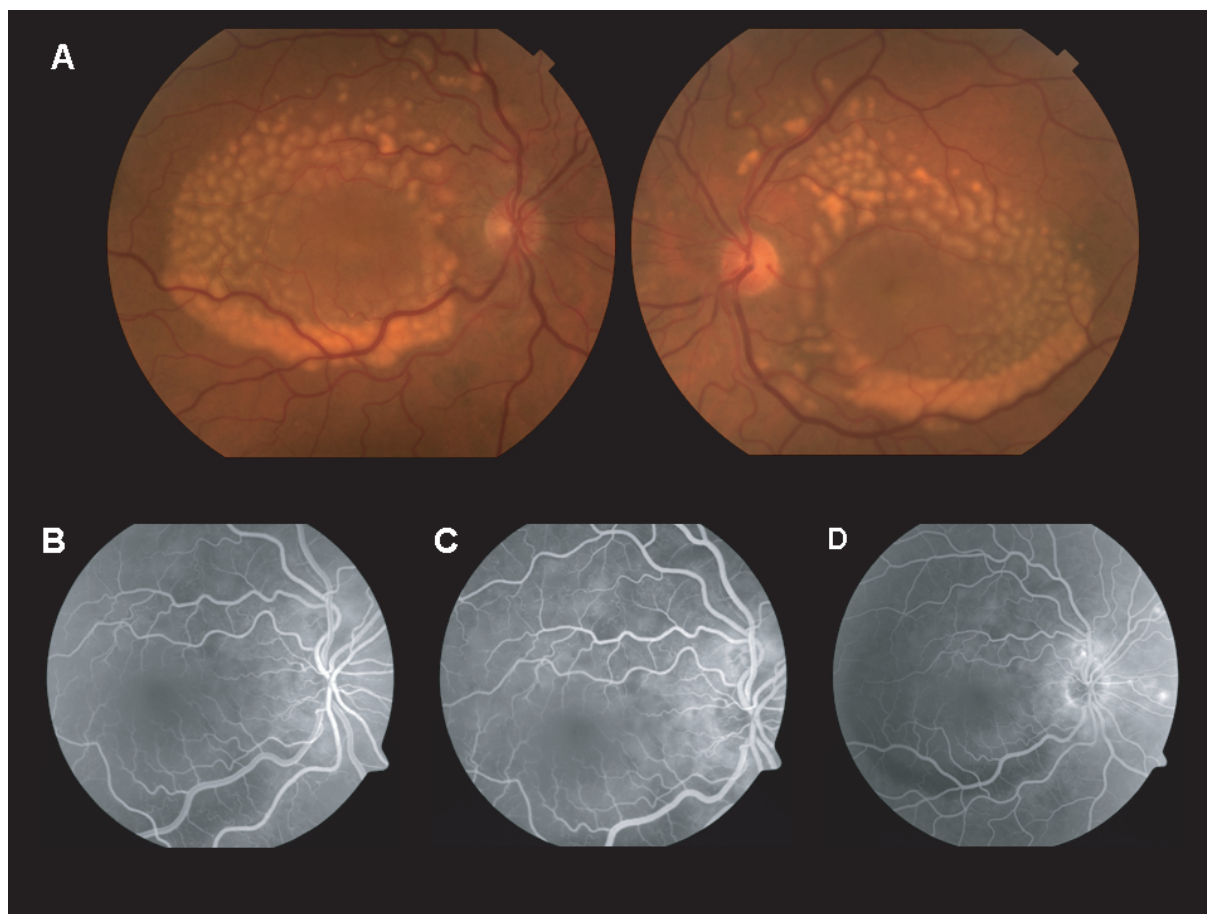
color plates, and intraocular pressures were all within normal limits. Anterior segment examination was significant for mild nuclear sclerosis in both eyes.

Funduscopy examination in both eyes revealed multiple, creamy, yellow, pseudovitelliform lesions in the posterior pole, varying in size from 100–500  $\mu\text{m}$ , at the level of the retinal pigment epithelium (RPE)/outer retinal junction, coalescing along the inferior portion, with overlying macular neurosensory and RPE detachment (Figure 1A). Fluorescein angiography demonstrated bilateral, symmetric areas of blocked fluorescence secondary to the fundus lesions with early leakage into the overlying neurosensory and RPE detachment (Figure 1B-D). Indocyanine green angiography was not performed. Optical coherence tomography (OCT) showed bilateral macular neurosensory detachments with multiple small areas of high reflectivity at the level of the outer retinal/RPE junction (Figure 2). ERG demonstrated a selective loss of the b-wave and a normal a-wave under

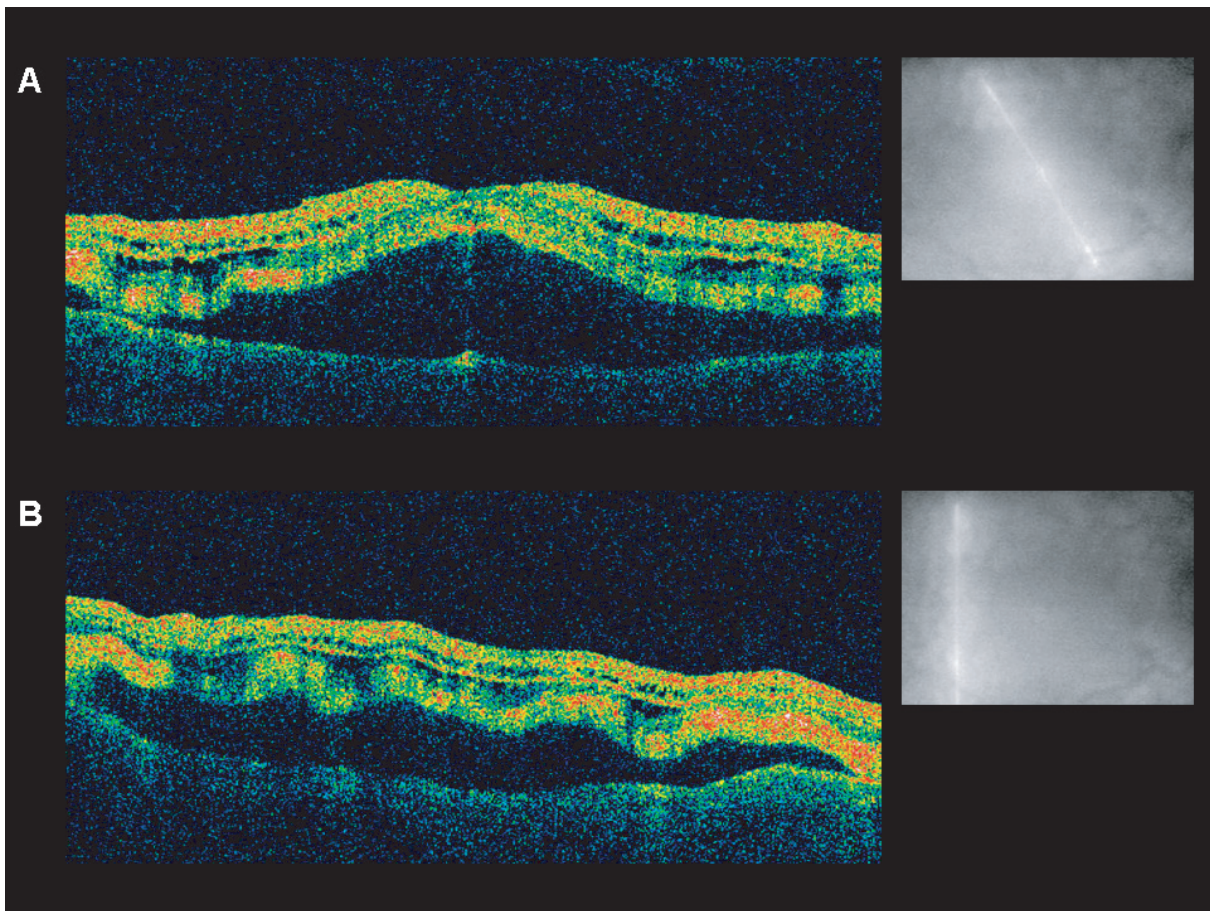
maximal dark-adapted, scotopic conditions (negative ERG). These findings were not evident on exam one year earlier. A blood test for circulating antibodies to recoverin (23 kD) was negative. Prior to obtaining additional samples for antibodies to retinal bipolar cells, the patient died.

## Comment

The complaint of nyctalopia combined with his clinical history and ERG findings suggest the diagnosis of MAR. The unusual finding was the presence of bilateral, symmetric, vitelliform lesions with neurosensory detachments. In the majority of cases, MAR is not associated with any retinal findings (Potter et al 1999; Borkowski et al 2001; Zacks et al 2001). Borkowski and colleagues (2001) were the first to describe two patients with MAR with unusual oval lesions at the level of the retinal pigment epithelium or choroid. They believed that these lesions could be part of the MAR spectrum, resulting from IgG antibodies against retinal bipolar cells. IgG antibodies are



**Figure 1** Fundus photography and fluorescein angiography. **A:** Fundus photography of both eyes revealed symmetric, multiple creamy yellow vitelliform lesions in the posterior pole arranged in a honeycomb pattern, varying in size from 100–500  $\mu\text{m}$ , at the level of the RPE/outer retina, coalescing along the inferior portion, with overlying macular neurosensory detachments. Few lesions were noted outside the posterior pole. **B-D:** Fluorescein angiography of the right eye at thirty-eight seconds, sixty-four seconds, and one hundred and eighty-seven seconds exhibiting small areas of blocked fluorescence secondary to the vitelliform retinal lesions with early leakage into the overlying neurosensory detachment. There is widespread blockage seen inferiorly along the vessels where the lesions have coalesced.



**Figure 2** Optical coherence tomography. **A:** Optical coherence tomography of the macula through the foveal center shows areas of both neurosensory fluid and RPE detachment. There are multiple areas of high reflectivity along portions of the outer retina and retinal pigment epithelium. Some areas of cystic retinal change area also present. **B:** Optical coherence tomography of the macula through the lateral edge of the vitelliform lesions shows both neurosensory and RPE detachment with multiple areas of high reflectivity along portions of the outer retina and retinal pigment epithelium. Note the corrugated appearance of the outer retina/RPE secondary to the vitelliform lesions.

thought to be responsible for the visual symptoms in MAR, by affecting depolarizing bipolar cells of the “ON-pathway” in both rods and cones (Potter et al 1999; Borkowski et al 2001; Palmowski et al 2002). There have been reports of neurosensory and RPE detachments with subsequent development of subretinal deposits in MAR (Zacks et al 2001; Palmowski et al 2002). Sotodeh and colleagues (2005) further described three patients with MAR-related paraneoplastic vitelliform retinopathies, including one patient with a choroidal melanoma with almost identical pseudovitelliform fundus findings to our patient. Unfortunately, neither an ERG nor an anti-retinal antibody test was reported for the patient.

Our case is also the first case of MAR associated with visceral malignant melanoma (small bowel). Although direct metastatic retinal invasion is a possibility, the lesions were not pigmented, appeared to be in the outer retinal/RPE junction clinically, and were not associated with retinal hemorrhages or edema. Without histopathologic confirmation, we cannot be certain as to the origin of these lesions in

our patient. Although we believe the patient presented with a variant of MAR, certainly Best’s disease and adult-onset vitelliform macular dystrophy must also be considered.

## Disclosure

None of the authors have any proprietary interest in any aspect of this manuscript.

## References

- Borkowski LM, Grover S, Fishman GA, et al. 2001. Retinal findings in melanoma-associated retinopathy. *Am J Ophthalmol*, 132:273–5.
- Palmowski AM, Haus AH, Pfohler C, et al. 2002. Bilateral multifocal chorioretinopathy in a woman with cutaneous malignant melanoma. *Arch Ophthalmol*, 120:1756–61.
- Potter MJ, Thirkill CE, Dam OM, et al. 1999. Clinical and immunocytochemical findings in a case of melanoma-associated retinopathy. *Ophthalmology*, 106:2121–5.
- Sotodeh M, Paridaens D, Keunen J, et al. 2005. Paraneoplastic vitelliform retinopathy associated with cutaneous or uveal melanoma and metastases. *Klin Monatsbl Augenheilkd*, 222:910–14.
- Zacks DN, Pinnolis MK, Berson EL, et al. 2001. Melanoma-associated retinopathy and recurrent exudative retinal detachments in a patient with choroidal melanoma. *Am J Ophthalmol*, 132:578–81.

