

Pegaptanib sodium for neovascular age-related macular degeneration: clinical experience in the UK

Sobha Sivaprasad
Nachiketa Acharya
Phil Hykin

Moorfields Eye Hospital, London, UK

Abstract: The pathogenesis of age-related macular degeneration (AMD) is unclear, but it can take either a neovascular/exudative/wet form, characterized by choroidal neovascularization (CNV), or a dry form. No treatments are available for the dry form, but there are a number of pharmacological interventions that inhibit vascular endothelial growth factor (VEGF), which is central to the pathogenesis of CNV and neovascular AMD. Available anti-VEGF agents either target all active VEGF isoforms (eg, ranibizumab), or take a more selective approach and inhibit only VEGF₁₆₅ (eg, pegaptanib sodium). Current guidance on their use is equivocal and restrictive at best, resulting in associated difficulties in securing adequate, timely funding for treatment. The Moorfields Eye Hospital undertook an audit of 70 patients receiving intravitreal (ITV) pegaptanib sodium on a *pro re nata* (*prn*) dosing schedule. Despite initial funding delays, the audit recorded superior treatment outcomes compared with those reported in the VISION trials at 12 weeks: 88% of audit patients maintained stable vision, 29% gained vision and 6% experienced severe vision loss compared with 70%, $\geq 6\%$ and $\leq 10\%$ of patients in VISION at 54 weeks, respectively. The audit indicates a positive correlation between patients with better baseline visual acuity (VA) and improved therapeutic benefits, including a greater likelihood of both vision gain and vision preservation. Experience at Moorfields also suggests that pegaptanib sodium is more useful in occult lesions than minimally classic lesions, and clinical experience suggests that combination therapies may offer the best approach with anti-VEGF therapies. Further randomized clinical trials will help better determine the optimal treatment strategies with pegaptanib sodium in neovascular AMD.

Keywords: age-related macular degeneration, choroidal neovascularization, vascular endothelial growth factor, pegaptanib sodium, visual outcomes, funding

Introduction

Age-related macular degeneration (AMD) is the leading cause of severe visual loss in people aged over 50 years in the developed world (Bressler 2004). Early AMD is clinically characterized by yellow deposits, known as drusen, and changes in pigmentation of the retina. Late AMD develops when there is an in-growth of new blood vessels (a process known as choroidal neovascularization [CNV]) that bleed into the subretinal space. This more advanced form of the condition is known as neovascular/exudative/wet type AMD. Dry AMD describes situations in which the macula atrophies (geographic atrophy).

Both these late forms of AMD usually lead to severe loss of central vision, which results in patients experiencing difficulties with tasks such as reading, writing, driving, and facial recognition. The visual impairment experienced by elderly sufferers who have bilateral AMD can have a severely disabling impact. Furthermore the condition predominates in older patients in whom the resultant visual impairment can be compounded by other comorbid disabilities. Visually disabled patients are more prone to

Correspondence: Sobha Sivaprasad
King's College Hospital, Denmark Hill,
London, SE5 9RS, UK
Tel +44 20329 94548
Fax +44 20329 93738
Email senswathi@aol.com

falls (Ivers et al 1998), and people with rapidly deteriorating vision also tend to experience more depression and anxiety, and a reduction in independence, compared with the general population, irrespective of their age (Augustin et al 2007).

The Macular Photocoagulation Study Group demonstrated that the mean visual acuity (VA) in eyes with untreated subfoveal CNV was 20/500 at four years after first examination for the disease (Macular Photocoagulation Study Group 1996). Other researchers have noted that the most severe cases of bilateral neovascular AMD (VA = 20/800 or worse) result in a deterioration of health-related quality of life comparable to that resulting from a severe stroke (Williams et al 1998). It is of little wonder, therefore, that AMD-related visual impairment and its consequences pose a significant burden on health care utilization (Lotery et al 2007; Soubrane et al 2007). As a result of the substantial quality of life and economic burden posed by AMD, there is considerable interest in therapies that may treat, and even prevent, the disease.

Delaying disease progression

The pathogenesis of AMD is unclear (Guymer and Chong 2006) and cigarette smoking remains the only widely accepted modifiable risk factor for its primary prevention. Patients seeking advice on AMD prevention should be encouraged to stop smoking (Kelly et al 2004). However, a recent systematic review indicated that there is insufficient evidence to support the role of dietary antioxidants supplements for the primary prevention of early AMD (Chong et al 2007).

A formulation of vitamins C 500 mg and E 400 IU, beta-carotene 15 mg, and zinc 80 mg (shown to reduce the risk of developing advanced AMD by 25% in high-risk patients enrolled in the Age-Related Eye Disease Study) is recommended in patients at intermediate risk of AMD, or who have advanced AMD in one eye (Age-Related Eye Disease Study Research Group [AREDS] 2001). In addition, recent data suggest that high dietary intake of macular xanthophylls lutein and zeaxanthin is associated with a lower risk of advanced AMD development. Similarly, long-chain polyunsaturated fatty acids derived from fish consumption are associated with a decreased risk of developing advanced AMD (Age-Related Eye Disease Study Research Group 2007). No treatments are available for the dry form of AMD.

Pharmacological interventions for neovascular AMD

Vascular endothelial growth factor (VEGF) plays a pivotal role in the pathogenesis of CNV, the hallmark of wet AMD

(Kaiser 2006), and the introduction of intravitreal (ITV) injections of anti-angiogenic agents targeted against the VEGF molecule led to an almost immediate paradigm shift in the treatment of the disease.

Pegaptanib sodium

Pegaptanib sodium (Macugen[®]; Pfizer/OSI/Eyetech Pharmaceuticals) is one of two anti-VEGF agents that have been approved by the European Agency for the Evaluation of Medicinal Products (EMA) for the treatment of neovascular AMD. It is a pegylated ribonucleic acid aptamer that binds human VEGF₁₆₅. Pegaptanib sodium differs from other anti-VEGF therapies in that it binds near the heparin-binding domain of VEGF-A, thus preventing VEGF₁₆₅ and larger isoforms from attaching to the VEGF receptors, making it a selective anti-VEGF agent, rather than one that targets all active VEGF-A isoforms (Gragoudas et al 2004). The VEGF Inhibition Study in Ocular Neovascularization (VISION) demonstrated that pegaptanib sodium is a safe and efficacious treatment for neovascular AMD (Gragoudas et al 2004). The study comprised 2 concurrent prospective, randomized, double-blind, placebo-controlled, dose-ranging clinical trials in which patients with neovascular AMD received 1 of 3 doses of pegaptanib sodium ITV or sham injections every 6 weeks for 48 weeks. Patients were included if they were 50 years of age or older and had subfoveal CNV secondary to AMD with best corrected VA of between 20/40 and 20/320 in the study eye and 20/800 or better in the other eye. At 12 months, 70% of pegaptanib sodium-treated patients in VISION lost <15 letters compared with 55% of sham-treated patients ($p < 0.001$). In addition, more patients in the pegaptanib sodium study arm gained ≥ 0 letters than did sham-treated patients (33% vs 23%, respectively; $p = 0.003$).

Ranibizumab

Ranibizumab (Lucentis[®]; Genentech, Inc), was the second anti-VEGF agent to gain EMA approval for the treatment of neovascular AMD. It is a chimeric molecule derived from a murine full-length monoclonal antibody (MAb) A4.6.1. The humanized fragment antigen binding (FAB) form of the molecule is affinity-matured to generate ranibizumab (rhuFab V2) (Chen et al 1999). Unlike the selective nature of pegaptanib sodium, ranibizumab binds to, and inhibits, the biologic activity of all active forms of VEGF-A and their active degradation products (Rosenfeld et al 2005).

The efficacy of ranibizumab was evaluated in patients with minimally classic or occult CNV secondary to AMD in the Minimally classic/occult trial of the Anti-VEGF antibody Ranibizumab In the treatment of Neovascular AMD (MARINA). The double-blind, placebo-controlled trial randomized patients to monthly injections of either 0.3 mg or 0.5 mg ranibizumab or sham. At 12 months, 95% of ranibizumab-treated patients experienced visual improvement or stabilization compared with 62% of those receiving placebo at ($p < 0.0001$) (Rosenfeld et al 2006a). More ranibizumab-treated patients experienced visual improvement of ≥ 15 letters compared with sham-treated patients ($p < 0.0001$). In addition, the proportion of patients with 20/40 vision (or better) at 12 months increased 3-fold in the ranibizumab-patient group compared with baseline, whereas the number of patients with 20/40 vision (or better) decreased in the sham study arm.

Ranibizumab was also investigated in patients with predominantly classic CNV secondary to AMD treated in the anti-VEGF ANTibody for the treatment of predominantly classic CHORoidal neovascularization in AMD (ANCHOR) study. The 2-year, double-blind, placebo-controlled clinical trial randomized patients to monthly treatment regimens of either 1–2 doses of ranibizumab and sham verteporfin photodynamic therapy [PDT], or sham injection and verteporfin PDT. At 1 year, approximately 94% (0.3 mg) and 96% (0.5 mg) of ranibizumab-treated patients maintained (defined as a loss in VA < 15 letters) or experienced an improvement in vision compared with approximately 64% of patients treated with sham injection arm ($p < 0.0001$). A statistically significant difference in VA from baseline to 12 months was also seen in the ranibizumab-treated patients compared with those receiving PDT alone (Brown et al 2006).

Bevacizumab

The humanized form of ranibizumab is known as bevacizumab (Avastin®; Genentech, Inc). Although bevacizumab is approved for the treatment of metastatic colorectal cancer and is not indicated for the treatment of neovascular AMD, it is currently being prescribed off-label in the ophthalmology community (Michels et al 2005). The rationale for its use in the eye is based on anecdotal evidence from several observational studies that suggest it may be an effective treatment for neovascular AMD. To date, no adverse events related to the drug have been reported (Fung et al 2006; Rosenfeld 2006), but further studies and clinical trials are required to establish its efficacy and safety profile in this off-license indication. Such trials are ongoing.

Anti-VEGF therapy and clinical practice

Budgetary implications

All patients in the pegaptanib sodium and ranibizumab clinical trials received a course of treatment, independent of patient response. Pegaptanib sodium was administered 6-weekly and ranibizumab every 4 weeks, both demanding treatment schedules that are difficult to incorporate in the job-plan of a typical medical retina consultant.

In clinical practice, it is not just time, but also cost that must be taken into consideration and factored into treatment budgets. This is increasingly true as public awareness of available therapies reaches an all-time high, bringing with it an associated increase in demand for (and expectations of) treatment outcomes among patients. Therefore, in reality, a *pro re nata* (*prn*) dosing schedule has to be adopted that is both clinically efficacious and cost-effective.

Treatment and re-treatment

There are several factors that should be taken into consideration when making treatment and re-treatment decisions in an attempt to maximize vision gain. If a clinical trial protocol is not in place, clinicians should use both functional and anatomic criteria (including VA, clinical examination and optical coherence tomography [OCT]) to guide treatment and re-treatment decisions (Brown et al 2007). Although there are published data on re-treatment criteria, clinical experience indicates a need to consider each patient for re-treatment individually, based on several local and systemic features, in order to maximize the benefit-risk ratio (Rosenfeld et al 2006b; Fung et al 2007). Presented below is data summarizing clinical experience of the use of ITV pegaptanib sodium on a *prn* dosing schedule from Moorfields Eye Hospital, London, UK.

Clinical experience at Moorfields Eye Hospital

Procedure for funding

There are two regulatory bodies in the UK that examine the clinical and cost-effectiveness of newly licensed treatments and provide recommendations for their use. In England and Wales the relevant body is the National Institute for Health and Clinical Excellence (NICE), whereas Scotland is regulated by the Scottish Medicines Consortium (SMC). At present, PDT is the only NICE-approved treatment for neovascular AMD, approved for patients with subfoveal,

predominantly classic CNV with a VA between 6/12 and 6/60. There are approximately 50 designated PDT centers in the UK and patients from other hospitals are referred to these sites for treatment.

Pegaptanib sodium and ranibizumab are both currently under appraisal by NICE for the treatment of neovascular AMD. Bevacizumab is not under consideration as it is not licensed for use in this indication. Draft NICE guidance on the agents was published in June 2007, but recommended ranibizumab for patients with predominantly classic CNV in the better eye only, and pegaptanib sodium not at all within the NHS. Implementation of this restrictive guidance would translate into <25% of patients with AMD being eligible for treatment and NICE is now re-considering the initial draft in conjunction with new economic modeling of the drugs. A revised draft is still awaited at the time of writing. In contrast, the SMC approved unrestricted use of both pegaptanib sodium and ranibizumab for treatment of patients with neovascular AMD in Scotland.

While they await the revised NICE recommendations, Primary Care Trusts (PCTs) and the Strategic Health Authority (SHA) within each region have started funding the use of the agents based on local protocols. As a result, there are regional variations in the nature and rate of funding for both drugs.

Clinical experience with pegaptanib sodium

Pegaptanib sodium was licensed for use by the EMEA in January 2006 and a service was subsequently launched in March 2006 at Moorfields Eye Hospital, in London, UK. Seventy patients were enrolled in the service for treatment.

The first port of call for a patient who presents with neovascular AMD is often the local optometrist. Most hospitals that provide an AMD service have a fast-track referral system that aims to ensure patients are seen at the Medical Retina Clinic within 2 weeks. The retinal specialist then confirms the diagnosis, both clinically and with ancillary tests such as fundus fluorescein angiography (FFA) and/or OCT.

Initially, funding for anti-VEGF treatment in the UK was on a named-patient basis and was restricted to patients with occult and minimally classic CNV lesions who had VA between 6/12 and 6/60 in their second eye. This meant that when a medical retinal specialist diagnosed a patient with the above criteria, an application for funding for the patient was submitted to the local PCT and treatment began only after approval was obtained. As the VISION study was the first randomized controlled trial (RCT) published, the primary outcome measure adopted in clinical practice was

that of the VISION study, and treatment was restricted to patients with minimally classic and occult CNV with recent progression of disease.

Audit methodology

A prospective digital database was created before the service began and data were collected on all patients from baseline.

Pegaptanib sodium care pathway

Baseline clinical examinations included best-corrected VA (BCVA), FFA, and OCT examination. All patients had BCVA, clinical examination, and OCT every 6 weeks; FFA was carried out during every fourth visit. All patients received the first three ITV injections of pegaptanib sodium; thereafter at the fourth visit, injections were given if: there was persistent sub-retinal fluid (SRF) or intra-retinal fluid (IRF) with a loss of 5 letters; if new SRF or IRF was present; or if there were new signs of disease activity, including an increase in lesion size or new hemorrhage. Numerical values of OCT thickness (μm) were not considered to assess whether repeat treatment was needed.

Aim of the audit

The audit aimed to compare the visual outcome of the Moorfields patient cohort with those of the patients in the VISION study. On this basis, it was hypothesized that at 12 weeks: at least 70% of patients should have stable vision (loss of <15 letters in the Early Treatment Diabetic Retinopathy Study [ETDRS]); $\geq 6\%$ should gain vision (gain of ≥ 15 letters ETDRS); and $\leq 10\%$ of treated eyes should have severe visual loss (loss of ≥ 30 letters ETDRS). Waiting times, from funding request to time of treatment, were also recorded and assessed within the set standard of 2 weeks.

Funding issues

Funding for the therapy was applied on named-patient basis to the PCT that served the region to which the patient's general practitioner (GP) was situated. The speed of approval varied between PCTs and ranged between 3–125 days. As anti-VEGF agents are not currently approved for use in neovascular AMD, PCTs are under no funding obligations at this time. Of the applications submitted, 12% were refused funding and 10% received no response. Some PCTs restricted funding to certain subgroups of lesion types and range of VA. However, more applications are being approved now than when the service first started. Of those patients in whom

funding was approved, 3% were not treated. The reason for this was mainly because the potential for visual stabilization was limited, either due to the formation of disciform scar and/or because the patient's vision had already degraded too far. Some patients opted for private treatments (self-paid) or were too ill to have the treatment.

Performance against standards

A comparison of the audit outcomes and those of the VISION study are summarized in Table 1 and Figure 1. Figure 2 also illustrates the superior visual outcome recorded for the Moorfields cohort compared with patients in the VISION study. It must be stressed that this cohort was given a *prn* dosing schedule and that the final follow-up was at 42 weeks, in contrast to the VISION study in which pegaptanib sodium was given every 6 weeks and where the results were analyzed at 54 weeks and 102 weeks.

The visual outcomes recorded at the Moorfields service were better in patients with occult lesions than in those with minimally classic lesions (see Figure 3). Six of the 9 patients in the cohort who had minimally classic lesions opted for treatment with bevacizumab at 6 months because of a lack of improvement (or a worsening) in their symptoms.

Combination therapy

Most of the patients receiving pegaptanib sodium during the audit were granted funding for ranibizumab when it was licensed, due to the superiority of the ANCHOR and MARINA trial results compared with those of VISION. In addition, a few patients that received initial treatment with pegaptanib sodium went on to receive ITV bevacizumab, following a series of case-series that suggest bevacizumab may offer greater vision improvement. Seven patients were treated with pegaptanib sodium following bevacizumab treatment while they awaited NHS funding for pegaptanib sodium. Eight patients received ranibizumab after pegaptanib sodium therapy.

Table 1 Comparison of VISION study versus Moorfields treatment outcomes

VA	Moorfields 0.3 mg Macugen	VISION 0.3 mg Macugen	VISION Sham
Stable	88%	70%	55%
Gain	29%	6%	2%
SVL	6%	10%	22%
	42 weeks n = 24	54 weeks n = 294	54 weeks n = 296

Abbreviation: SVL, severe visual loss.

The follow-up data on those patients who switched anti-VEGF therapy are limited to comment on visual outcomes because patients who received bevacizumab privately, and those within the NHS who were switched from pegaptanib sodium to ranibizumab had a mean period of follow-up of only 6 weeks.

Adverse events

Of the total 200 injections administered during the audit: there were no cases of endophthalmitis, traumatic cataract or retinal detachment; 1 patient lost 32 letters after the first injection of pegaptanib sodium due to a large sub-retinal hemorrhage; 2 patients safely received ITV pegaptanib sodium 2 weeks post myocardial infarction, and 2 patients on warfarin received ITV pegaptanib sodium without event.

Audit recommendations

Clinical standards and outcomes

The pegaptanib sodium visual outcome recorded in the Moorfields patient cohort were better than those seen in the VISION study, and the audit indicates a positive correlation between patients with better baseline VA and improved therapeutic benefits, including a greater likelihood of both vision gain and vision preservation. However, it must be conceded that the VISION and Moorfields inclusion criteria did differ slightly.

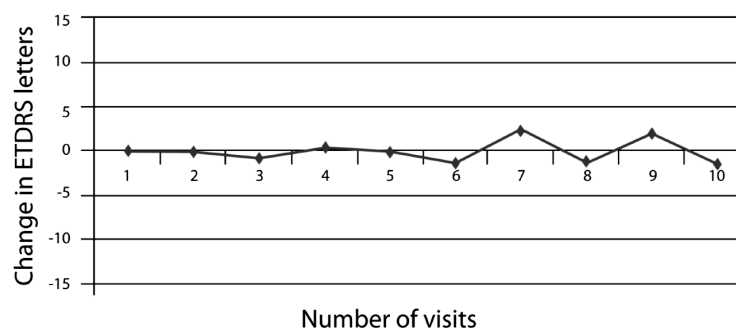


Figure 1 Mean change in visual acuity during Moorfields audit.

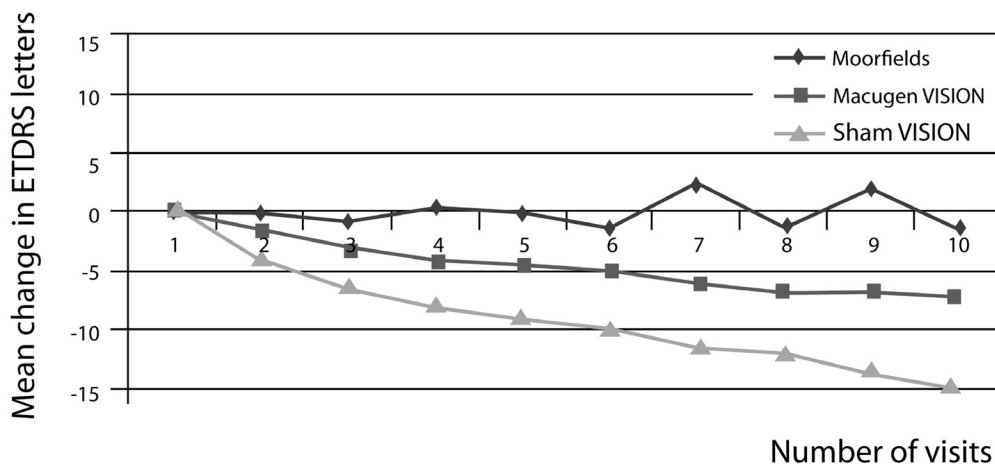


Figure 2 Comparison of VISION study versus Moorfields audit visual outcomes.

It should be noted that, despite the fact that funding of treatment was delayed for some patients, the visual outcomes were still superior to those recorded in the VISION study. The audit also showed that the average delay for funding at 6 months following commencement of the service was 43 days, but that this delay decreased to 21 days at 12 months. The reason for the improved waiting time may be due to pressure from increased public awareness of the new treatments as well as that of funding agencies. It is anticipated that the funding issues will be further resolved following publications of the full NICE recommendations.

Organization of patient pathway

The audit identified treatment delays that need to be addressed, including a need for better education of patients, primary care physicians and optometrists. Secondary care providers should establish rapid access AMD clinics to

fast-track patients who present with neovascular AMD at their local optometrist so that they receive their clinical examination, FFA, and OCT as a one-stop clinic. Funding agencies should allocate resources for the development of such services so that prior approval for each patient is not required and so that the first treatment can be initiated as soon as the diagnosis is established.

The audit of this service also revealed the need for dedicated personnel and sessions during the treatment and follow-up of these patients. The maintenance of a prospective database also helps to identify patients who fail to attend clinic appointments, and so aids in subsequent follow up and monitoring of potential side-effects associated with these new therapies.

Another important requirement is the need for changes to existing infrastructure. The Moorfields anti-VEGF service is demanding and requires space to carry out investigations and also clean rooms for treatment. Advance planning for

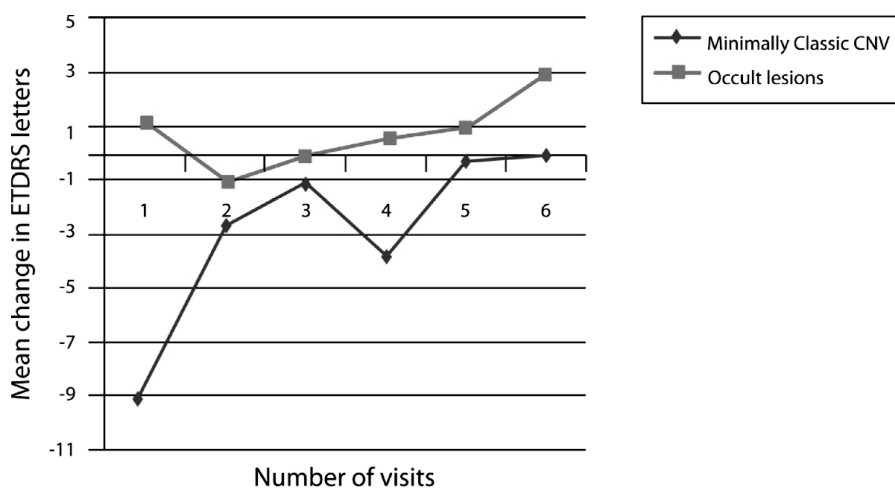


Figure 3 Change in visual acuity in different choroidal neovascularization subtypes seen in Moorfields audit patients.

space and personnel is required in anticipation of the rapid expansion of the service. It is difficult to sustain such a demanding service and more hub-and-spoke centers need to be developed. It is also important that the patients be treated and monitored by medical retinal specialists to maximize strict adherence to the diagnostic and re-treatment criteria for both clinical efficacy and cost-effectiveness.

Clinical role for pegaptanib sodium in neovascular AMD

Clinical experience at Moorfields with pegaptanib sodium suggests that the visual outcomes achievable with this selective VEGF inhibitor at 12 weeks are better in clinical practice than was reported from the VISION study, despite the *prn* dosing schedule. Similar results have also been reported elsewhere (Quiram et al 2007), combining to raise questions as to the validity of the cost-effectiveness data based on the VISION study.

The exact role of pegaptanib sodium in the treatment of neovascular AMD remains to be explored. The limited clinical experience available suggests that combination therapies may offer the best approach with these agents. The ophthalmology community is certainly impressed by the visual gain that may occur following treatment with ranibizumab therapy, but concerns over the cardiovascular safety of pan-VEGF inhibition persist. The interim report of the SAILOR study indicates a slight elevation in the risk of stroke in patients with a history of recent strokes following treatment with ranibizumab (Rosenfeld et al 2006b). As a result, the main role for pegaptanib sodium may be in patients with increased cardiovascular risks, including patients with recent stroke, myocardial infarction and other thromboembolic phenomena. Pan-VEGF inhibition in uncontrolled hypertension may also be contraindicated as VEGF is a potent vasodilator that regulates blood flow to organs and reduction of VEGF levels results in an increase in blood pressure. Lutun and Carmeliet have proposed that hypertension and proteinuria directly reflect systemic VEGF inhibition and could be used as surrogate markers for systemic VEGF depletion to sub-critical levels (Lutun and Carmeliet 2004). Both hypertension and proteinuria were not noted with pegaptanib sodium in the VISION study.

Trials of ranibizumab have provided sufficient evidence that the therapeutic response to the agent is greatest during the first three months of treatment, when given at monthly intervals. Switching the treatment regimen from monthly to quarterly injections has been shown to result in a decline in initial benefit (Rosenfeld et al 2006b). Given that the visual

gain seen in trials was limited after the first 3–4 injections of ranibizumab, it may be useful to switch patients to pegaptanib sodium when there are signs of persistent activity of the neovascular lesion without significant change in VA. It is important to compare the effect of a single pan-VEGF inhibition to initial induction (initial loading dose) with pan-VEGF inhibition and then maintenance with pegaptanib sodium. Observations from numerous trials involving ranibizumab also showed the need to individualize re-treatment regimens, based on patient-specific diagnostic monitoring. It is important to provide a holistic approach and to update the medical history of these patients at each visit.

Conclusions

The optimal treatment strategy with anti-VEGF agents in neovascular AMD is yet to be established and requires further investigation of existing treatments in both RCTs and in clinical practice.

Following its use in clinical practice, experience at Moorfields Eye Hospital suggests that results following treatment with pegaptanib sodium for occult and minimally classic CNV may be better than those reported from the VISION study despite the use of a *prn* dosing schedule. These data also suggest that pegaptanib sodium may be more useful in slow-growing, occult lesions than aggressive lesions with a classic component. Yet this area also requires further investigation in order to improve understanding of the precise indications for pegaptanib.

An ideal anti-VEGF therapy for CNV should: act specifically on the CNV; offer a good safety profile; have a low-risk route of administration; be effective in all lesion types, and (most importantly) result in vision improvement. None of the existing anti-VEGF agents meets all these criteria and therefore, like cancer therapy, it may be best to pursue an individualized induction-maintenance regimen based on clinical examination, diagnostic monitoring and medical evaluation. Despite the availability of these agents, their impact on the rate of blind registration due to neovascular AMD remains to be investigated.

References

- Age-Related Eye Disease Study Research Group. 2001. A randomized, placebo-controlled, clinical trial of high-dose supplementation with vitamins C and E, beta carotene, and zinc for age-related macular degeneration and vision loss: AREDS report No 8. *Arch Ophthalmol*, 119:1417–36.
- Augustin A, Sahel JA, Bandello F, et al. 2007. Anxiety and depression prevalence rates in age-related macular degeneration. *Invest Ophthalmol Vis Sci*, 48:1498–503.
- Bressler NM. 2004. Age-related macular degeneration is the leading cause of blindness. *JAMA*, 291:1900–1.

- Brown DM, Kaiser PK, Michels M, et al; ANCHOR Study Group. 2006. Ranibizumab versus verteporfin for neovascular age-related macular degeneration. *N Engl J Med*, 355:1432–44.
- Brown DM, Regillo CD. 2007. Anti-VEGF Agents in the Treatment of Neovascular Age-related Macular Degeneration: Applying Clinical Trial Results to the Treatment of Everyday Patients. *Am J Ophthalmol*, 144:627–37.
- Chen Y, Wiesmann C, Fuh G, et al. 1999. Selection and analysis of an optimized anti-VEGF antibody: crystal structure of an affinity-matured Fab in complex with antigen. *J Mol Biol*, 293:865–81.
- Chong EW, Wong TY, Kreis AJ, et al. 2007. Dietary antioxidants and primary prevention of age related macular degeneration: systematic review and meta-analysis. *BMJ*, 335:755.
- Fung AE, Lalwani GA, Rosenfeld PJ, et al. 2007. An optical coherence tomography-guided, variable dosing regimen with intravitrealranibizumab (Lucentis) for neovascular age-related macular degeneration. *Am J Ophthalmol*, 143:566–83.
- Fung AE, Rosenfeld PJ, Reichel E. 2006. The International Intravitreal Bevacizumab Safety Survey: using the internet to assess drug safety worldwide. *Br J Ophthalmol*, 90:1344–9.
- Gragoudas ES, Adamis AP, Cunningham ET Jr, et al; VEGF Inhibition Study in Ocular Neovascularization Clinical Trial Group. 2004. Pegaptanib for neovascular age-related macular degeneration. *N Engl J Med*, 351:2805–16.
- Guymer RH, Chong EW. 2006. Modifiable risk factors for age-related macular degeneration. *Med J Aust*, 184:455–8.
- Ivers RQ, Cumming RG, Mitchell P, Attebo K. 1998. Visual impairment and falls in older adults: the Blue Mountains Eye Study. *J Am Geriatr Soc*, 46:58–64.
- Kaiser PK. 2006. Antivascular endothelial growth factor agents and their development: therapeutic implications in ocular diseases. *Am J Ophthalmol*, 142:660–8.
- Kelly SP, Thornton J, Lyratzopoulos G, et al. 2004 Smoking and blindness. *BMJ*, 328:537–8.
- Lotery A, Xu X, Zlatava G, Loftus J. 2007. Burden of illness, visual impairment and health resource utilisation of patients with neovascular age-related macular degeneration: results from the UK cohort of a five-country cross-sectional study. *Br J Ophthalmol*, 91:1303–7.
- Luttun A, Carmeliet P. 2004. Angiogenesis and lymphangiogenesis: highlights of the past year. *Curr Opin Hematol*, 11:262–71.
- Macular Photocoagulation Study Group. 1996. Occult choroidal neovascularisation. Influence on visual outcome in patients with age-related macular degeneration. *Arch Ophthalmol*, 114:400–12.
- Michels S, Rosenfeld PJ, Puliafito CA, et al. 2005. Systemic bevacizumab (Avastin) therapy for neovascular age-related macular degeneration twelve-week results of an uncontrolled open-label clinical study. *Ophthalmology*, 112:1035–47.
- Quiram PA, Hassan TS, Williams GA. 2007. Treatment of naive lesions in neovascular age-related macular degeneration with pegaptanib. *Retina*, 27:851–6.
- Rosenfeld PJ. 2006. Intravitreal avastin: the low cost alternative to lucentis? *Am J Ophthalmol*, 142:141–3.
- Rosenfeld PJ, Brown DM, Heier JS, et al; MARINA Study Group. 2006a. Ranibizumab for neovascular age-related macular degeneration. *N Engl J Med*, 355:1419–31.
- Rosenfeld PJ, Rich RM, Lalwani GA. 2006b. Ranibizumab: Phase III clinical trial results. *Ophthalmol Clin North Am*, 19:361–72.
- Rosenfeld PJ, Schwartz SD, Blumenkranz MS, et al. 2005. Maximum tolerated dose of a humanized anti-vascular endothelial growth factor antibody fragment for treating neovascular age-related macular degeneration. *Ophthalmology*, 112:1048–53.
- San Giovanni JP, Chew EY, Clemons TE, et al; Age-Related Eye Disease Study Research Group, et al. 2007. The relationship of dietary carotenoid and vitamin A, E, and C intake with age-related macular degeneration in a case-control study: AREDS Report No. 22. *Arch Ophthalmol*, 125:1225–32.
- Soubrane G, Cruess A, Lotery A, et al. 2007. Burden and health care resource utilization in neovascular age-related macular degeneration: findings of a multicountry study. *Arch Ophthalmol*, 125:1249–54.
- Williams RA, Brody BL, Thomas RG, et al. 1998. The psychosocial impact of macular degeneration. *Arch Ophthalmol*, 116:514–20.