

Oculogyric crisis in a patient taking metoclopramide

Yaran Koban
Metin Ekinci
Halil Huseyin Cagatay
Zeliha Yazar

Department of Ophthalmology,
Faculty of Medicine, Kafkas University,
Kars, Turkey

Abstract: Oculogyric crisis is an acute dystonic reaction of the ocular muscles characterized by bilateral dystonic elevation of visual gaze lasting from seconds to hours. This reaction is most commonly explained as an adverse reaction to drugs such as antiemetics, antipsychotics, antidepressants, antiepileptics, and antimalarials. Although the incidence of metoclopramide-induced acute dystonic reactions has been reported as 25% in children, there have been few published cases on oculogyric crisis in general. It is important to be able to recognize this ocular side effect because, without a thorough patient history, symptoms can be confused with other diseases such as versive seizures, paroxysmal tonic upward gaze, and encephalopathy. In this paper, we report a case of oculogyric crisis induced by metoclopramide.

Keywords: oculogyric crisis, dystonic reactions, metoclopramide

Introduction

Metoclopramide is a benzamide selective dopamine D2 receptor antagonist that is used as an antiemetic, with side effects that are seen frequently in children.¹ The commonest and most important side effects of metoclopramide are acute extrapyramidal symptoms, which require immediate treatment.^{2,3} Acute dystonic reactions occur as contractions of the muscles, opisthotonus, torticollis, dysarthria, trismus, and oculogyric crisis.⁴ Although the incidence of metoclopramide-induced acute dystonic reactions has been reported to be 25% in children, there are few published cases on oculogyric crisis in general.^{5,6} We report a case of a 13-year-old girl, referred to the Department of Ophthalmology, Faculty of Medicine, Kafkas University, Kars, Turkey from the emergency room, who had developed a metoclopramide-induced oculogyric crisis.

Case report

A 13-year-old female patient presented to the emergency department with double vision and involuntary upward and lateral deviation of the eyes. Three days earlier, she had presented at an outpatient clinic and metoclopramide therapy was started at 0.5 mg/kg three times daily for vomiting of 2 days' duration. After treatment, the frequency of vomiting was reduced, but her eyes became deviated upward, starting from 30 minutes before presentation (Figure 1). On initial presentation, she was aware of this situation and was in severe distress. On neurological examination, her consciousness was clear. Sustained conjugate upward and lateral deviation of the eyes (oculogyric crisis), and neck stiffness when only the neck muscles were contracted, were observed. Physical examination did not reveal any other dyskinetic movement. The patient could bring her eyes back to primary position with extreme effort, but she could not sustain the

Correspondence: Yaran Koban
Kafkas Universitesi Tip Fak, Goz
Hastaliklari AD, 36000, Kars, Turkey
Tel +90 507 707 8180
Fax +90 474 225 1193
Email yarankoban@yahoo.com.au

effort, and the eyes resumed their eccentric position within seconds. On ophthalmic examination, she exhibited isocoria, with her pupils giving indirect and direct light reflexes. Ocular motility and visual acuity could not be evaluated due to the presence of oculogyric crisis. Her intraocular pressures and biomicroscopic and fundoscopic findings were unremarkable. Vitals were normal and results of complete blood count, liver and kidney function tests, and electrolytes were within normal values. Based on the history and physical examination findings, a diagnosis of metoclopramide-induced dystonia was made. The drug was discontinued and the patient was treated with intravenous diphenhydramine 1 mg/kg. The symptoms disappeared rapidly, within 30 minutes of commencing treatment, and the patient was discharged after approximately 4 hours of admission with complete recovery. She remained well at follow-up 1 week later.

Discussion

Acute dystonic reactions are extrapyramidal side effects due to alteration of the dopaminergic–cholinergic balance in the nigrostriatum.⁷ Medication-induced acute dystonia can be a side effect of treatment with antiemetics, antipsychotics, antidepressants, antiepileptics, antimalarials, and other drugs.^{7,8} Such drugs produce acute dystonic reactions through a nigrostriatal dopamine D2 receptor blockade, which results in an excess of striatal cholinergic output.⁹ These drug-induced side effects are dose independent.⁸ Metoclopramide, the most commonly prescribed antiemetic, may cause acute dystonic reactions at any age even if it is used at therapeutic dosages. The incidence of these reactions secondary to metoclopramide is 0.2%, but in old and young patients this incidence increases to as high as 25%.⁵ Metoclopramide-induced side effects are also known to appear more frequently in female patients, at high drug doses, in patients with a family history of neurological disease, in those who are treated with neuroleptics, and in patients whose family members have developed acute dystonic reactions due to metoclopramide.^{5,10,11}

Acute dystonic reactions include contractions of the muscles, especially in the facial, trapezius, and dorsal levator scapulae and rhomboid muscles; opisthotonus; torticollis; dysarthria; trismus; and oculogyric crisis.⁴ Oculogyric crisis is characterized by a temporary period of frequent spasms of eye deviation, particularly upward, each spasm lasting from seconds to hours and the entire episode lasting from days to weeks.^{8,12} The spasm may be preceded or accompanied by disturbing emotional symptoms, including anxiety, restlessness, compulsive thinking, sensations of increased brightness,

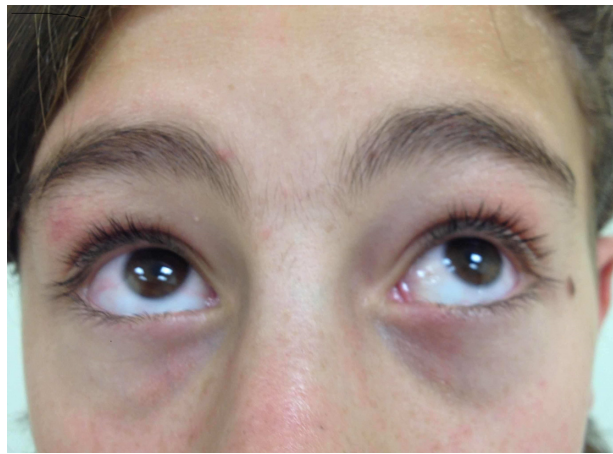


Figure 1 Metoclopramide-induced oculogyric crisis.

or distortions of visual background.¹³ Although oculogyric crisis usually occurs as a side effect of drugs, it can be seen in patients with postencephalitic parkinsonism, brainstem encephalitis, Wilson's disease, and cystic glioma, for whom the onset of the crisis is positional.^{14–17} Versive seizures, paroxysmal tonic upward gaze, eye movement tics, and retinal disease must also be excluded from the differential diagnosis. Epilepsy can manifest as oculogyric seizures, also called versive seizures. Wyllie et al defined versive seizures as clonic or tonic head and eye deviations, unquestionably forced and involuntary, resulting in sustained unnatural positioning of the head and eyes.¹⁸ Versive seizures with upgaze deviation can simulate oculogyric crises, but they are associated with an alteration of consciousness and electroencephalogram abnormalities.¹⁸ Paroxysmal tonic upward gaze is characterized by infantile or early childhood onset, with episodes of sustained conjugate upward deviation of the eyes. It can be distinguished from oculogyric crisis by the presence of neck flexion and concomitant episodic ataxia.¹⁹ Eye movement tics in children are seen between the ages of 6 and 12 years and are characterized by a stereotyped conjugate deviation of the eyes upward and outward. Oculogyric crisis is more sustained than eye movement tics.²⁰ In our case, neurologic and ophthalmologic examinations and vitals were normal. The results of complete blood count, liver and kidney function tests, and electrolytes were within normal values. Based on the history and physical examination findings, a diagnosis of metoclopramide-induced dystonia was made.

Conclusion

Although the incidence of metoclopramide-induced acute dystonic reactions has been reported to be 25% in children, there have been few cases published on oculogyric crisis

in general.^{5,6} Without a thorough history, symptoms can be confused with other diseases, such as partial epileptic seizure with versive movements and eye movement tics. It is necessary for ophthalmologists to recognize this ocular side effect in children with oculogyric crisis, because recognizing this adverse effect could help avoid the trouble of going through detailed and exhaustive neurological examinations and investigations.

Disclosure

The authors alone are responsible for the content and writing of the paper and report no conflicts of interest in this work.

References

- Hibbs AM, Lorch SA. Metoclopramide for the treatment of gastroesophageal reflux disease in infants: a systematic review. *Pediatrics*. 2006;118(2):746–752.
- Batts KF, Munter DW. Metoclopramide toxicity in an infant. *Pediatr Emerg Care*. 1998;14(1):39–41.
- Carey MJ, Aitken ME. Diverse effects of antiemetics in children. *N Z Med J*. 1994;107(989):452–453.
- Low LC, Goel KM. Metoclopramide poisoning in children. *Arch Dis Child*. 1980;55(4):310–312.
- Yis U, Ozdemir D, Duman M, Unal N. Metoclopramide induced dystonia in children: two case reports. *Eur J Emerg Med*. 2005;12(3):117–119.
- Lou E, Abou-Zeid N. A case of metoclopramide-induced oculogyric crisis in a 16-year-old girl with cystic fibrosis. *South Med J*. 2006;99(11):1290–1291.
- Bateman DN, Rawlins MD, Simpson JM. Extrapyramidal reactions with metoclopramide. *Br Med J (Clin Res Ed)*. 1985;291(6500):930–932.
- Bhachech JT. Aripiprazole-induced oculogyric crisis (acute dystonia). *J Pharmacol Pharmacother*. 2012;3(3):279–281.
- Busari OA, Fadare J, Agboola S, Gabriel O, Elegbede O, Oladosu Y. Chloroquine-induced acute dystonic reactions after a standard therapeutic dose for uncomplicated malaria. *Sultan Qaboos Univ Med J*. 2013;13(3):E476–E478.
- van der Padt A, van Schaik RH, Sonneveld P. Acute dystonic reaction to metoclopramide in patients carrying homozygous cytochrome P450 2D6 genetic polymorphisms. *Neth J Med*. 2006;64(5):160–162.
- Silfeler I, Arica V, Arica S, Dogan M. Development of acute dystonia in three brothers due to metoclopramide. *J Res Med Sci*. 2012;17(3):308–309.
- Liu GT, Carrazana EJ, Macklis JD, Mikati MA. Delayed oculogyric crises associated with striatocapsular infarction. *J Clin Neuroophthalmol*. 1991;11(3):198–201.
- Lavin PJM, Donahue S. Neuro-ophthalmology: the efferent visual system. Gaze mechanisms and disorders. In: Daroff RB, Fenichel GM, Marsden CD, Bradley WG, editors. *Neurology in Clinical Practice*. 3rd ed. Boston, MA: Butterworth Publishing; 2000:699–720.
- Onuaguluchi G. Crises in post-encephalitic parkinsonism. *Brain*. 1961;84(3):395–414.
- Matsumura K, Sakuta M. Oculogyric crisis in acute herpetic brainstem encephalitis. *J Neurol Neurosurg Psychiatry*. 1987;50(3):365–366.
- Lee MS, Kim YD, Lyoo CH. Oculogyric crisis as an initial manifestation of Wilson's disease. *Neurology*. 1999;52(8):1714–1715.
- Stechison MT. Cystic glioma with positional oculogyric crisis. *J Neurosurg*. 1989;71(6):955–957.
- Wyllie E, Lüders H, Morris HH, Lesser RP, Dinner DS. The lateralizing significance of versive head and eye movements during epileptic seizures. *Neurology*. 1986;36:606–611.
- Ozbay OE. Idiopathic paroxysmal tonic upward gaze. *Pediatr Neurol*. 2012;47(4):306–308.
- Binyon S, Prendergast M. Eye-movement tics in children. *Dev Med Child Neurol*. 1991;33(4):352–355.

Clinical Ophthalmology

Publish your work in this journal

Clinical Ophthalmology is an international, peer-reviewed journal covering all subspecialties within ophthalmology. Key topics include: Optometry; Visual science; Pharmacology and drug therapy in eye diseases; Basic Sciences; Primary and Secondary eye care; Patient Safety and Quality of Care Improvements. This journal is indexed on

Submit your manuscript here: <http://www.dovepress.com/clinical-ophthalmology-journal>

Dovepress

PubMed Central and CAS, and is the official journal of The Society of Clinical Ophthalmology (SCO). The manuscript management system is completely online and includes a very quick and fair peer-review system, which is all easy to use. Visit <http://www.dovepress.com/testimonials.php> to read real quotes from published authors.