

Central retinal artery occlusion in association with fibromuscular dysplasia

Ahmet Altun¹
Gulengul Altun²
Osman Okan Olcaysu³
Sevda Aydin Kurna¹
Suat Fazil Aki¹

¹Clinic of Ophthalmology, Fatih Sultan Mehmet Education and Research Hospital, Istanbul, Turkey; ²Department of Pediatrics, Yeditepe University, Istanbul, Turkey; ³Clinic of Ophthalmology, Erzurum Region Education and Research Hospital, Erzurum, Turkey

Abstract: A 14 year-old female, whose chief complaint was severe vision loss in the right eye for 2 days, presented to the Clinic of Ophthalmology of Fatih Sultan Mehmet Education and Research Hospital. The patient had been attending follow-up visits for 4 years, following a diagnosis of fibromuscular dysplasia by the Clinic of Pediatrics. The patient underwent a complete ophthalmologic, angiographic, hematologic, and systemic evaluation. Fundus fluorescein angiography was performed immediately, because of the cherry-red spot sign in the macula of the right eye. Fundus fluorescein angiography revealed evidence of marked stasis of the retinal arterial circulation in the right eye. Best corrected visual acuity was 20/400 in the right eye and 20/20 in the left eye.

Keywords: retina, artery, occlusion, fibromuscular, dysplasia

Introduction

Fibromuscular dysplasia (FMD) is a rare heterogeneous group of noninflammatory, nonatherosclerotic vascular diseases that involves small and medium sized arteries such as the renal or craniocervical artery.¹ Although FMD has been associated with genetic and hormonal anomalies, coagulation disorders, stress, and smoking, the true cause of FMD remains unknown. FMD is pathologically characterized by circumferential or eccentric collagen deposition, and is classified according to the arterial wall layer that is primarily affected, ie, intima, media, or adventitia. Injury of the media is the most common.² Renal artery involvement is the most common manifestation and FMD is thought to be an important cause of systemic hypertension due to renal arterial stenosis.³ FMD is the second most frequent cause of renal artery stenosis after atherosclerosis. Atherosclerotic renal arterial stenosis mostly affects elderly patients. Conversely, FMD predominantly affects young Caucasian women.⁴

Hypertension, transient ischemic attack, headache, syncope, and subarachnoid hemorrhage are common clinical manifestations, whereas ocular manifestations are rarely mentioned.^{1,5} Clinical manifestations correlate with the affected site. Involvement of internal carotid, vertebral, visceral, iliac, subclavian, brachial, peripheral pulmonary, and popliteal arteries has been also reported.^{1,6-8} Involvement of retinal arteries is rare and it has been reported in just three cases in the literature. With this paper, we would like to present a case of central retinal artery occlusion (CRAO) with a previously known diagnosis of FMD, who received renal artery surgery because of persistent arterial hypertension 3 years ago.

Correspondence: Ahmet Altun
Zumrutevler Mahallesi, Nish Adalar Sitesi,
Blok: 3/35, Maltepe, Istanbul, Turkey
Tel +90 506 366 2876
Email aaltun06@gmail.com

Case report

A 14-year-old girl with a previous diagnosis of FMD was referred to the clinic of ophthalmology with the complaint of severe blurring in the right eye for 2 days. She had a diagnosis of FMD for 4 years. According to her medical history, obtained from the patient file belonging to the Department of Pediatrics, she had unusually high systemic blood pressure (180/110 mmHg), recorded at a regular visit. After realizing decreased flow in her left renal artery by Doppler ultrasonography, she received the angiography procedure. The final report of the procedure was that band-like narrowing in the left renal artery gives rise to thought fibromuscular dysplasia with no pathologic finding in vertebral arteries. Two months after establishing the diagnosis of FMD (which was four years ago), she received balloon angioplasty and started captopril to control her systemic blood pressure.

Ocular examination revealed afferent pupillary defect in the right eye. Best corrected visual acuity (BCVA) was 20/400 in the right eye and 20/20 in the left eye. The examination of anterior segment and ocular pressure were bilaterally within normal limits. Because of the cherry-red spot sign in the macula of the right eye, the patient immediately underwent stereoscopic color fundus photography and fluorescein fundus angiography. Fundus examination revealed that the left eye was normal (Figure 1) but that the right eye contained ischemic whitening with a cherry-red spot area (Figure 2). Fluorescein fundus angiography demonstrated abnormal retinal arterial and choroidal dye filling in the early phase in the right eye. CRAO was diagnosed from the characteristic appearance (Figure 3A and B).

There were no systemic risk factors such as diabetes mellitus, hyperlipidemia, or smoking. Hematologic evaluation was also performed and all coagulation parameters were

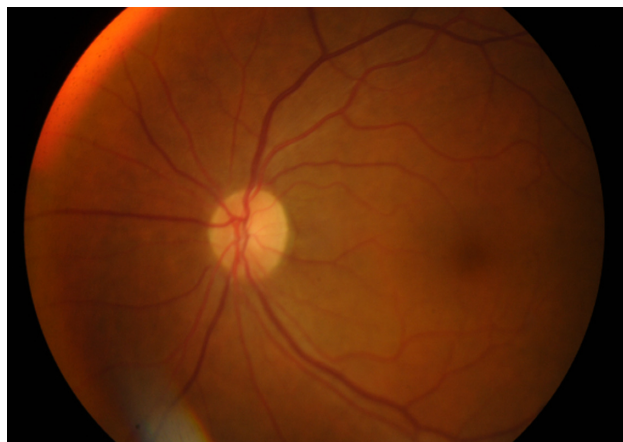


Figure 1 Fundus photography of unaffected left eye.

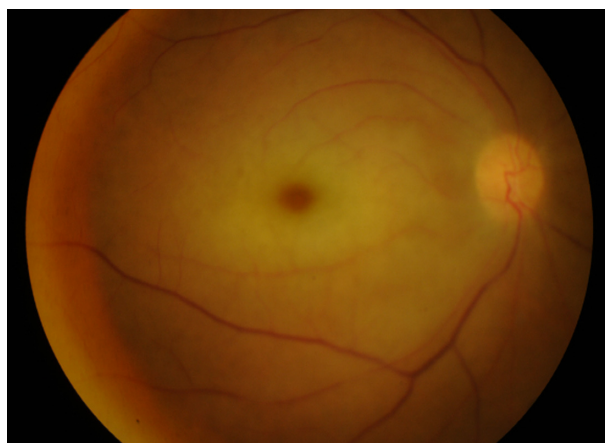


Figure 2 Cherry-red spot appearance due to central retinal artery occlusion in the right eye.

within normal limits. The patient then underwent carotid evaluation and echocardiographic study to determine the source of possible embolism. For carotid evaluation, carotid angiography was performed. Echocardiographic and carotid angiographic findings were within normal limits and there was no source of embolism such as valve or wall lesions. There was no tenderness in the face over the temporal artery.

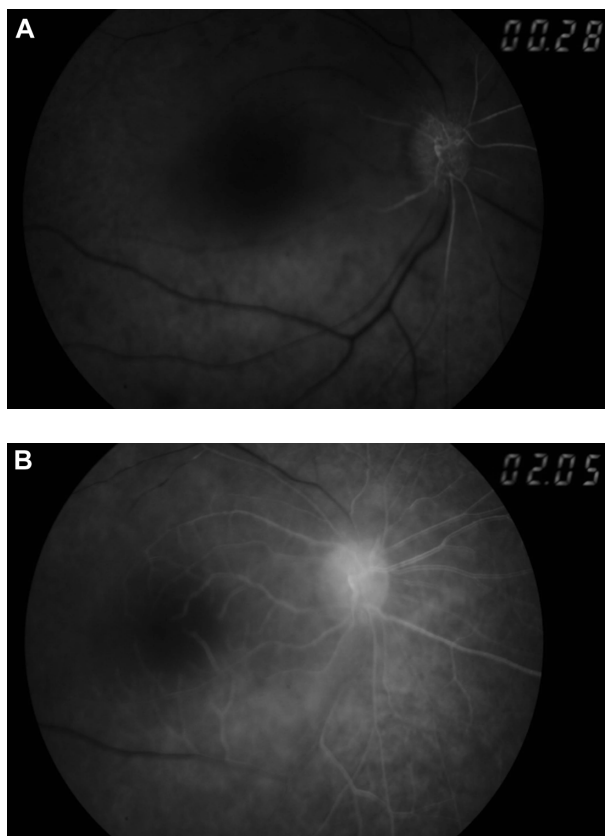


Figure 3 Abnormal retinal arterial and choroidal dye filling in the right eye. **Notes:** (A) Delayed dye filling in early phase of fundus fluorescein angiography of the right eye. (B) Delayed dye filling in late phase of fundus fluorescein angiography of the right eye.

Erythrocyte sedimentation rate, C-reactive protein, and platelet count were all within normal limits.

The systemic blood pressure of the patient was 140/95 mmHg without antihypertensive drugs. She reported that she was taking her systemic antihypertensive drugs irregularly. At the latest visit (6 months ago), the patient's right BCVA decreased to hand motion.

Discussion

FMD is an important cause of renal hypertension. A recent and sudden onset of severe arterial hypertension in a young female patient without systemic pathology may indicate renal artery stenosis due to FMD.³ The pathological diagnosis of FMD is often difficult because it is not possible to biopsy the arterial site of involvement.

CRAO is a well-known ophthalmic emergency resulting in ischemia of the inner retina with dramatic onset of catastrophic visual loss.⁹ It is believed that the site of occlusion in CRAO is usually at the level of the lamina cribrosa. An anatomic study of central retinal arteries showed that the narrowest lumen of the artery is where it pierces the dura mater of the optic nerve sheath.¹⁰ Therefore, in cases of CRAO due to embolism, occlusion at this site is much higher than at any other site.

It is generally believed that the CRAO is always either embolic or thrombotic in origin. Very rarely, vasculitis or trauma can cause CRAO. Elevated erythrocyte sedimentation rate or C-reactive protein level are important signs of giant cell arteritis, which is usually seen in elderly populations over 65 years. In our case, all hematologic parameters were within normal limits.

Managing CRAO remains a therapeutic dilemma. A number of treatment modalities for CRAO have been proposed such as anterior chamber paracentesis, acetazolamide, aspirin, ocular massage, carbogen inhalation, pentoxifylline, isovolumic hemodilution, hyperbaric oxygen, rebreathing of expired CO₂ in a bag, systemic corticosteroids given intravenously, and intra-arterial thrombolysis.^{9,11,12} Thus, it is thought that CRAO is a disease which has many unestablished treatment options.

FMD of the retinal artery is rare in literature.^{5,13,14} We present a case of central artery occlusion in a girl who already had the diagnosis of FMD. Unilateral, severe, and sudden vision loss in patients with FMD should alert pediatricians and ophthalmologists to CRAO. Patients with FMD should be informed of the importance of urgent hospital treatment due to the catastrophic results of CRAO, especially when managed late.

Disclosure

The authors report no conflicts of interest in this work.

References

1. Kirton A, Crone M, Benseler S, et al. Fibromuscular dysplasia and childhood stroke. *Brain*. 2013;136(Pt 6):1846–1856.
2. Rice RD, Armstrong PJ. Brachial artery fibromuscular dysplasia. *Ann Vasc Surg*. 2010;24(2):255. e1–e4.
3. Begelman SM, Olin JW. Fibromuscular dysplasia. *Curr Opin Rheumatol*. 2000;12(1):41–47.
4. Colapinto RF, Stronell RD, Harries-Jones EP, et al. Percutaneous transluminal dilatation of the renal artery: follow-up studies on renovascular hypertension. *AJR Am J Roentgenol*. 1982;139:727–732.
5. Meire FM, De Laey JJ, Van Thienen MN, Schuddinck L. Retinal manifestations in fibromuscular dysplasia. *Eur J Ophthalmol*. 1991;1: 63–68.
6. Prisant LM, Szerlip HM, Mulloy LL. Fibromuscular dysplasia: an uncommon cause of secondary hypertension. *J Clin Hypertens (Greenwich)*. 2006;8(12):894–898.
7. Grau R. Pseudovasculitis: mechanisms of vascular injury and clinical spectrum. *Curr Rheumatol Rep*. 2002;4(1):83–89.
8. Yano T, Kasahara Y, Tanabe N, et al. Juvenile pulmonary hypertension associated with fibromuscular dysplasia. *Intern Med*. 2010;49(22): 2487–2492.
9. Hayreh SS, Zimmerman MB. Central retinal artery occlusion: visual outcome. *Am J Ophthalmol*. 2005;140:376–391.
10. Hayreh SS. *A Study of the Central Artery of the Retina in Human Beings [Master's Thesis]*. Chandigarh: Panjab University; 1958.
11. Atebara NH, Brown GC, Cater J. Efficacy of anterior chamber paracentesis and Carbogen in treating acute nonarteritic central retinal artery occlusion. *Ophthalmology*. 1995;102:2029–2034.
12. Noble J, Weizblit N, Baerlocher MO, Eng KT. Intra-arterial thrombolysis for central retinal artery occlusion: a systematic review. *Br J Ophthalmol*. 2008;92(5):588–593.
13. Sawada T, Harino S, Ikeda T. Central retinal artery occlusion in a patient with fibromuscular dysplasia. *Retina*. 2004;24(3):461–464.
14. Warrasak S, Tapaneya-Olarn W, Euswas A, Sriphojanart S, Sirikulchayanonta V, Leelachaikul P. Fibromuscular dysplasia: a rare cause of cilioretinal artery occlusion in childhood. *Ophthalmology*. 2000;107(4):737–741.

Clinical Ophthalmology

Publish your work in this journal

Clinical Ophthalmology is an international, peer-reviewed journal covering all subspecialties within ophthalmology. Key topics include: Optometry; Visual science; Pharmacology and drug therapy in eye diseases; Basic Sciences; Primary and Secondary eye care; Patient Safety and Quality of Care Improvements. This journal is indexed on

Submit your manuscript here: <http://www.dovepress.com/clinical-ophthalmology-journal>

Dovepress

PubMed Central and CAS, and is the official journal of The Society of Clinical Ophthalmology (SCO). The manuscript management system is completely online and includes a very quick and fair peer-review system, which is all easy to use. Visit <http://www.dovepress.com/testimonials.php> to read real quotes from published authors.