

Unilateral macular edema with central retinal vein occlusion in systemic lupus erythematosus: a case report

Hidetaka Noma¹
Hiroshi Shimizu¹
Tatsuya Mimura²

¹Department of Ophthalmology,
Yachiyo Medical Center, Tokyo
Women's Medical University,

²Department of Ophthalmology,
Medical Center East, Tokyo Women's
Medical University, Tokyo, Japan

Abstract: Central retinal vein occlusion (CRVO) is frequent in patients with systemic lupus erythematosus (SLE), but the treatment of the macular edema with this disease is extremely difficult. We report a case of cystoid macular edema (CME) secondary to unilateral CRVO in a patient with SLE that responded to intravitreal injection of an anti-vascular endothelial growth factor (VEGF) agent. A 33-year-old Japanese woman was referred to our department with unilateral impairment of vision. Microperimetry (MP-1) showed a cessation of foveal sensitivity. Fluorescein angiography showed CME without ischaemia of the macular region or peripheral retina (nonischemic CRVO). A diagnosis of CME and unilateral nonischemic CRVO combined with SLE was made and intravitreal anti-VEGF therapy was given. A sample of aqueous humor was harvested at the start of intravitreal injection after obtaining informed consent. Then the levels of VEGF and monocyte chemoattractant protein (MCP)-1 were measured in the aqueous humor by enzyme-linked immunosorbent assay, revealing that VEGF was 234 pg/mL and MCP-1 was 501 pg/mL. Two weeks later, left eye vision improved to 20/20. Optical coherence tomography (OCT) showed considerable amelioration of retinal swelling and CME. MP-1 showed a marked increase of foveal sensitivity. However, she had recurrence of edema 3 months later. After harvesting aqueous humor again, intravitreal injection of an anti-VEGF agent was repeated for CME. The aqueous VEGF and MCP-1 levels were 156 pg/mL and 360 pg/mL, respectively. These findings suggest that inflammation was improved by intravitreal injection of bevacizumab. Intravitreal injection of anti-VEGF agents may be effective for CME due to nonischemic CRVO in SLE patients if their inflammatory factor levels are low.

Keywords: systemic lupus erythematosus, central retinal vein occlusion, cystoid macular edema, anti-vascular endothelial growth factor agent, vascular endothelial growth factor, monocyte chemoattractant protein-1

Introduction

Systemic lupus erythematosus (SLE) is a chronic autoimmune disorder that affects multiple organs, including the eye.¹ Ocular symptoms are usually due to retinal vascular manifestations of this disease, such as central retinal vein occlusion (CRVO), which is frequent in patients with SLE.² We report an SLE patient with macular edema and unilateral CRVO who responded to intravitreal injection of an anti-vascular endothelial growth factor (VEGF) agent.

Materials and methods

Laboratory test results confirmed the diagnosis of SLE, and revealed leukopenia together with elevation of antinuclear antibody (ANA) and anti-double-stranded

Correspondence: Hidetaka Noma
Department of Ophthalmology, Yachiyo
Medical Center, Tokyo Women's Medical
University, 477-96, Owada-shinden,
Yachiyo, Chiba 276-8524, Japan
Tel +81 47 450 6000
Fax +81 47 458 7047
Email noma-hide@umin.ac.jp

DNA antibody (anti-dsDNA). Antiphospholipid antibodies (both anticardiolipin and lupus anticoagulant) were negative. Serology for syphilis, human immunodeficiency virus 1 and 2, and hepatitis B and C was negative. Blood cultures showed no growth. Urinalysis was within normal limits. Magnetic resonance imaging of the central nervous system (CNS) revealed findings compatible with the diagnosis of CNS vasculitis.

Treatment of cystoid macular edema (CME) was started with intravitreal injection of an anti-VEGF agent (bevacizumab, 1.25 mg/0.05 mL). A sample of undiluted aqueous humor was harvested at the start of intravitreal anti-VEGF therapy after informed consent was obtained following an explanation of the purpose and potential adverse effects of the procedure. This study was performed in accordance with the Helsinki Declaration of 2008 (sixth revision), and our institutional review board of Tokyo Women's Medical University also approved the protocol for collection of aqueous humor. The levels of VEGF and monocyte chemoattractant protein-1 (MCP-1) were measured in the aqueous humor sample by using enzyme-linked immunosorbent assay kits for human VEGF and MCP-1 (R&D Systems, Minneapolis, MN, USA).³ As a result, the VEGF level was 234 pg/mL and the MCP-1 level was 501 pg/mL.

Case report

A 33-year-old Japanese woman was referred to our department with unilateral impairment of vision. Six months earlier, SLE was diagnosed on the basis of a malar rash, polyarthritis, leukopenia, and elevation of ANA and anti-dsDNA antibody.¹ At the initial examination, visual acuity (VA) was 20/100 in the left eye. Superficial and deep intraretinal hemorrhages were scattered throughout the retina, suggesting that the patient had CRVO (Figure 1A). Fluorescein angiography showed CME without ischemia of the macular region or peripheral retina (Figure 1B). Optical coherence tomography (OCT) identified retinal swelling and CME (Figure 1C). Fundus-monitored microperimetry with the MP-1 system (Nidek, Gamagori, Japan) revealed a cessation of foveal sensitivity (Figure 1D).

Two weeks later, VA of the left eye had improved to 20/20. OCT showed marked alleviation of retinal swelling and CME (Figure 2A). However, recurrence of edema was noted after 3 months (Figure 2B) and VA of the left eye decreased to 20/50. After harvesting aqueous humor, intravitreal injection of bevacizumab (1.25 mg/0.05 mL) was performed again for CME. Levels of VEGF and MCP-1 were 156 pg/mL and 360 pg/mL, respectively. The VA of the left eye improved to 20/20 again, while OCT showed marked

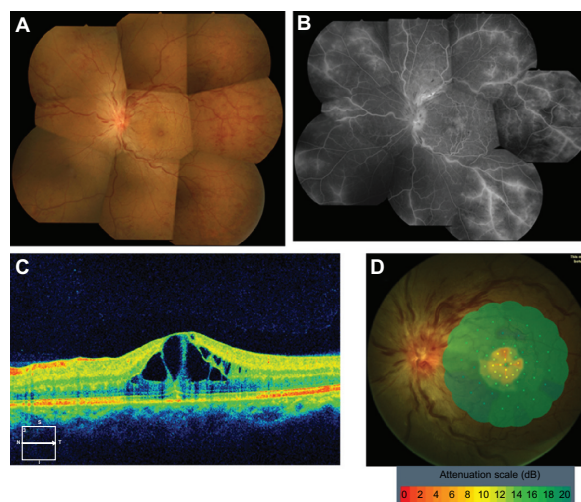


Figure 1 Fundus color photograph (A) of our patient with systemic lupus erythematosus, showing unilateral central retinal vein occlusion. Superficial and deep intraretinal hemorrhages are scattered throughout the retina. Fluorescein angiogram (B) shows a pattern resembling cystoid macular edema (CME) without ischemia of the macula or the peripheral retina. Optical coherence tomography (C) reveals retinal swelling and CME. Fundus-monitored microperimetry with the MP-1 system (D) indicates a cessation of foveal sensitivity.

alleviation of retinal swelling and CME at one week after the second intravitreal injection (Figure 2C). In addition, there was improvement of foveal sensitivity (Figure 2D). During the subsequent 6 months, there was no recurrence of CME.

Discussion

Retinal vascular changes are frequent in patients with SLE.² The classic retinal findings are hemorrhages and cotton

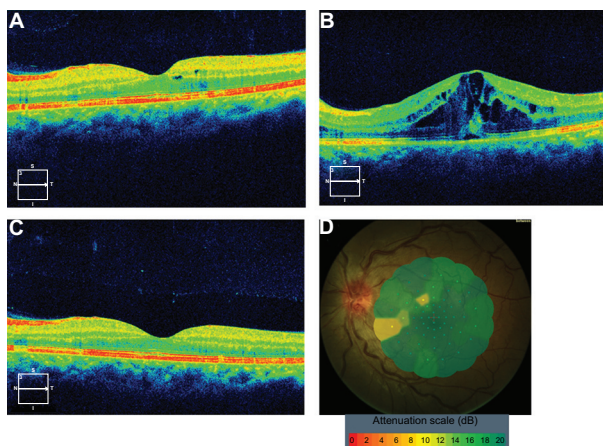


Figure 2 Optical coherence tomography (OCT) (A) shows marked improvement of retinal swelling and cystoid macular edema (CME) at 2 weeks after the first intravitreal injection of bevacizumab. OCT (B) reveals the recurrence of macular edema at 3 months after intravitreal anti-vascular endothelial growth factor (VEGF) therapy. OCT (C) displays marked improvement of retinal swelling and CME at 1 week after the second intravitreal injection of bevacizumab. Fundus-monitored microperimetry with the MP-1 system (D) demonstrates improvement of foveal sensitivity.

wool spots and VA is generally unaffected. If macular edema occurs, however, it leads to visual impairment. In the present patient, visual acuity, retinal sensitivity, and macular edema were all improved by two intravitreal injections of an anti-VEGF agent (bevacizumab). VEGF decreased from 234 to 156 pg/mL after the first injection and MCP-1 also decreased from 501 to 360 pg/mL. This finding is supported by the report that changes of VEGF after intravitreal anti-VEGF therapy significantly associated with changes of MCP-1,⁴ and it suggests that inflammation was improved by intravitreal injection of bevacizumab. It has been reported that anti-VEGF treatment is more effective for nonischemic CRVO than ischemic CRVO,⁵ and we previously reported that aqueous VEGF levels are significantly higher in patients with ischemia than in those without ischemia.⁶ The present patient had nonischemic CRVO with relatively low levels of VEGF (234 pg/mL and 156 pg/mL), which means that she was more likely to respond to intravitreal anti-VEGF therapy.

Conclusion

These findings suggest that inflammation was improved by intravitreal injection of bevacizumab. Intravitreal anti-VEGF

therapy may be effective for CME due to nonischemic CRVO in SLE patients with low levels of inflammatory factors.

Disclosure

Authors report no conflicts of interest in this work.

References

1. Tan EM, Cohen AS, Fries JF, et al. The 1982 revised criteria for the classification of systemic lupus erythematosus. *Arthritis Rheum.* 1982; 25(11):1271–1277.
2. Arevalo JF, Lowder CY, Muci-Mendoza R. Ocular manifestations of systemic lupus erythematosus. *Curr Opin Ophthalmol.* 2002;13(6): 404–410.
3. Noma H, Mimura T, Eguchi S. Association of inflammatory factors with macular edema in branch retinal vein occlusion. *JAMA Ophthalmol.* 2013;131(2):160–165.
4. Funk M, Kriechbaum K, Prager F, et al. Intraocular concentrations of growth factors and cytokines in retinal vein occlusion and the effect of therapy with bevacizumab. *Invest Ophthalmol Vis Sci.* 2009;50(3): 1025–1032.
5. Kriechbaum K, Michels S, Prager F, et al. Intravitreal Avastin for macular oedema secondary to retinal vein occlusion: a prospective study. *Br J Ophthalmol.* 2008;92(4):518–522.
6. Noma H, Funatsu H, Mimura T, Harino S, Sone T, Hori S. Increase of vascular endothelial growth factor and interleukin-6 in the aqueous humour of patients with macular oedema and central retinal vein occlusion. *Acta Ophthalmol.* 2010;88(6):646–651.

Clinical Ophthalmology

Publish your work in this journal

Clinical Ophthalmology is an international, peer-reviewed journal covering all subspecialties within ophthalmology. Key topics include: Optometry; Visual science; Pharmacology and drug therapy in eye diseases; Basic Sciences; Primary and Secondary eye care; Patient Safety and Quality of Care Improvements. This journal is indexed on

Submit your manuscript here: <http://www.dovepress.com/clinical-ophthalmology-journal>

Dovepress

PubMed Central and CAS, and is the official journal of The Society of Clinical Ophthalmology (SCO). The manuscript management system is completely online and includes a very quick and fair peer-review system, which is all easy to use. Visit <http://www.dovepress.com/testimonials.php> to read real quotes from published authors.