

Three-dimensional foveal shape changes after asymptomatic macular posterior vitreous detachment

Kazuyuki Kumagai¹
Masanori Hangai²
Mariko Furukawa¹
Eric Larson³
Nobuchika Ogino⁴

¹Department of Ophthalmology, Kami-iida First General Hospital, Nagoya, Japan; ²Department of Ophthalmology and Visual Sciences, Kyoto University Graduate School of Medicine, Kyoto, Japan; ³Miyazaki Prefectural Nursing University, Miyazaki, Japan; ⁴Nishigaki Eye Clinic, Nagoya, Japan

Purpose: To show a case in which the shape of the fovea changed after an asymptomatic macular posterior vitreous detachment (PVD).

Methods: The foveal shape was determined from the spectral-domain optical coherence tomography (OCT) images before and after a spontaneous macular PVD.

Results: A 66-year-old man with a unilateral macular hole in the right eye presented with a perifoveal PVD in the asymptomatic left eye. One year later, the left eye developed a macular PVD, and OCT measurements showed a 16.7% decrease in the central foveal thickness, and increases in the pit depth by 20.5%, foveola diameter by 14.7%, and pit volume by 19.4%. The thicknesses of the macular subfields of the Early Treatment Diabetic Retinopathy Study were decreased by 13.0% in the central subfield and by 1.4%–6.6% in the other subfields.

Conclusion: The deepening and widening of the fovea after a macular PVD indicate that a PVD can alter the shape of the fovea.

Keywords: posterior vitreous detachment, spectral-domain optical coherence tomography, foveal pit, macular hole

Introduction

The fovea is a highly specialized structure in the human retina where the visual resolution is the highest. An understanding of how the foveal shape and thickness and its physiological properties can affect vision is necessary to comprehend the pathophysiology of retinal diseases related to vitreoretinal interface abnormalities.

Optical coherence tomography (OCT) allows noninvasive observations and measurements of the foveal shape without altering the shape or vitreoretinal interface. Thus, OCT has been able to show various foveal shapes in normal eyes,^{1–8} and significant correlations have been found between the minimum and average foveal thickness and age.^{1–5}

OCT has also demonstrated that age-related posterior vitreous detachments (PVDs) develop initially as perifoveal PVDs,^{9–11} which can lead to the development of a macular hole. In addition, changes in the foveal shape, eg, flattening or irregularity of its contours, have been shown to occur after a spontaneous resolution of a macular PVD in the fellow eyes of patients with a unilateral macular hole.¹² Thus, it is possible that a macular PVD can lead to changes in the foveal shape. However, to the authors' knowledge, there is no published report that documents changes in the foveal shape after a PVD.

Correspondence: Kazuyuki Kumagai
Department of Ophthalmology,
Kami-iida First General Hospital,
2-70 Kami-iida-kitamachi, Kita-ku,
Nagoya, 462-0802, Japan
Tel +81 52 991 3111
Email ganka@kami-iida-hp.jp

We present a case with a unilateral macular hole in which the asymptomatic fellow eye was examined by spectral-domain OCT (SD-OCT) before and after a spontaneous macular PVD developed. We shall show that the development of the macular PVD was accompanied by a change in the shape of the fovea.

Methods

A 66-year-old man underwent successful macular hole surgery on his right eye. The macula of his left eye had a perifoveal PVD, but did not show evident foveal deformations, such as intraretinal cysts or foveal detachment, as a sign for stage 1 macular hole. However, a minute projection was seen in the temporal edge of the fovea, to which the posterior vitreous cortex adhered, indicating that this eye was in the pre-stage 1a macular hole. The best-corrected visual acuity (BCVA) in the left eye was 20/20. Both eyes were examined by biomicroscopy and SD-OCT (Cirrus HD-OCT; Carl Zeiss Meditec, Inc, Dublin, CA, USA) every 6 months, over a 24 month period.

The SD-OCT scans were obtained in the high-definition mode, composed of a raster of 5 B-scans with a 4096 A-scan resolution and 0.25 mm intervals between neighboring B-scans. Five B-scan images of 6 mm length were recorded along the horizontal and vertical axes centered on the fovea. To measure the retinal thickness in the macular region, 6 × 6 mm macular cube scans that consisted of 200 B-scans and 200 A-scans centered on the fovea were recorded. Scans were taken by experienced OCT examiners at least three times at each visit to obtain images with the highest signal intensity of ≥ 7 .

To measure the average regional retinal thicknesses, the retinal thickness map analysis protocol for the macular cube scan was used. The Cirrus HD-OCT (Carl Zeiss Meditec, Dublin, CA, USA) software for the regional retinal thickness maps determined the average retinal thickness in nine macular subfields within a 6 mm diameter circle centered on the fovea as defined in the Early Treatment Diabetic Retinopathy Study (ETDRS).¹³ These subfields included the central (foveal) subfield and the superior, temporal, inferior, and nasal quadrants of the inner and outer rings. The diameter of the central ring was 1 mm; the inner ring was 3 mm; and the outer ring was 6 mm. The average thicknesses of the whole macular area and of the quadrants of the four inner (1–3 mm) and outer (3–6 mm) rings, and the central subfield, were used for the analyses.

Four foveal parameters that represented the foveal pit shape were calculated following the methods of Dubis et al.⁸

From the exported retinal thickness data (internal limiting membrane to retinal pigment epithelium), 180 radially oriented slices through the foveal center were extracted. The foveal center was defined using the automated algorithm (Foveal Finder) built into the SD-OCT system. Each of these thickness profiles was then fit to a difference of Gaussian (DoG) curve. The first derivative of the best-fitting DoG curve provided information about the steepness of the slope of the foveal contour and allowed automated and objective extraction of the depth and slope of the foveal pit. The center of the foveal pit was identified as the central retinal location where the slope was 0, and the rim of the foveal pit was identified as a location of 0 slope. The pit depth was defined as the largest distance between the “pit lid,” ie, a plane fit to the “pit rim,” and the internal limiting membrane. The pit volume was defined as the volume enclosed between the pit lid and the pit. The pit area was defined as the enclosed area of the pit rim.

Case report

A 66-year-old man underwent successful macular hole surgery on his right eye, and had normal-appearing macula on his asymptomatic left eye. However, a perifoveal PVD was detected in the SD-OCT images of the left eye (Figure 1A). One year later, a macular PVD was found in the SD-OCT images of the left eye with a detached posterior hyaloid membrane and an operculum over the fovea (Figure 1B). The SD-OCT B-scan images showed that the fovea appeared flatter than that before the macular PVD. The macular thickness maps and surface maps clearly showed changes in the foveal shape, namely, a widening and deepening of the foveal floor (Figures 1C–F and 2A–D). This flat foveal contour in the left eye remained for 2 years in the SD-OCT images recorded every 6 months. The left eye was asymptomatic and its BCVA remained at 20/20 for the 2 years after the macular PVD in the left eye.

At 1 year after the development of macular PVD, the central foveal thickness decreased by 16.7%, the pit depth deepened by 20.5%, the foveola diameter enlarged by 14.7%, and the pit volume increased by 19.4%, as compared to the values before the macular PVD (initial visit, Table 1). At the same visit, the average regional retinal thickness in the ETDRS chart (Figure 1G and H) was decreased by 1.4% to 13.0% (Table 1). The percentage reduction was highest in the central subfield (–13.0%). Comparable changes were found in the inner ring subfields (3.9% to 6.6%) and in the outer subfield (1.4% to 5.5%).

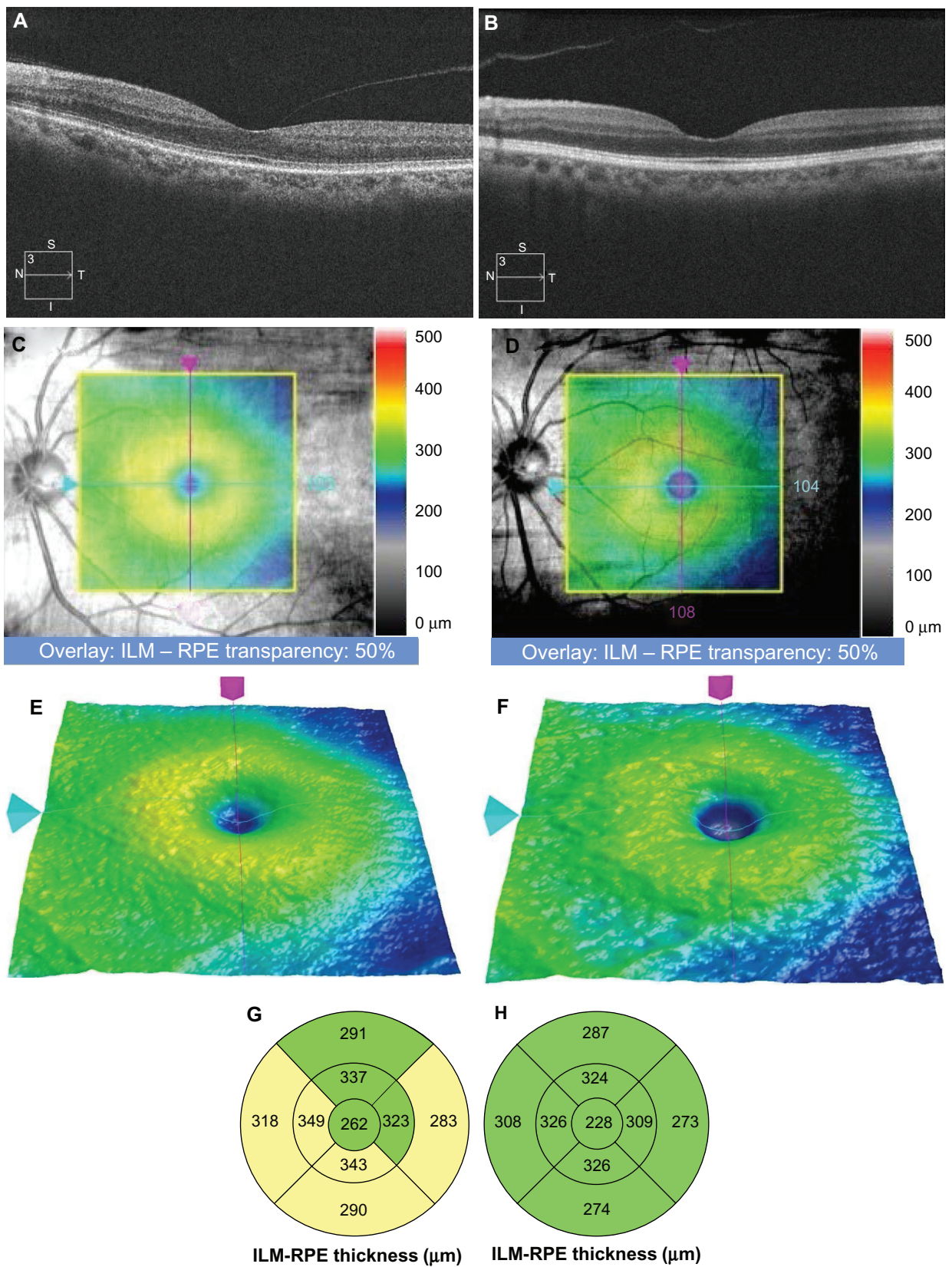


Figure 1 Macular images and retinal thickness maps obtained by SD-OCT before and after the development of a macular PVD. **(A, C, E, and G)** Before the macular PVD; **(B, D, F, and H)** after the macular PVD. **(A and B)** SD-OCT horizontal B-scan images of the retina through the fovea. **(C and D)** Infrared image overlaid by macular thickness map on the SD-OCT cube scans. **(E and F)** Three-dimensional surface map from SD-OCT cube scans. **(G and H)** Average regional macular thickness as per Early Treatment Diabetic Retinopathy Study subfields.¹³
Abbreviations: ILM, internal limiting membrane; PVD, posterior vitreous detachment; RPE, retinal pigment epithelium; SD-OCT, spectral-domain optical coherence tomography.

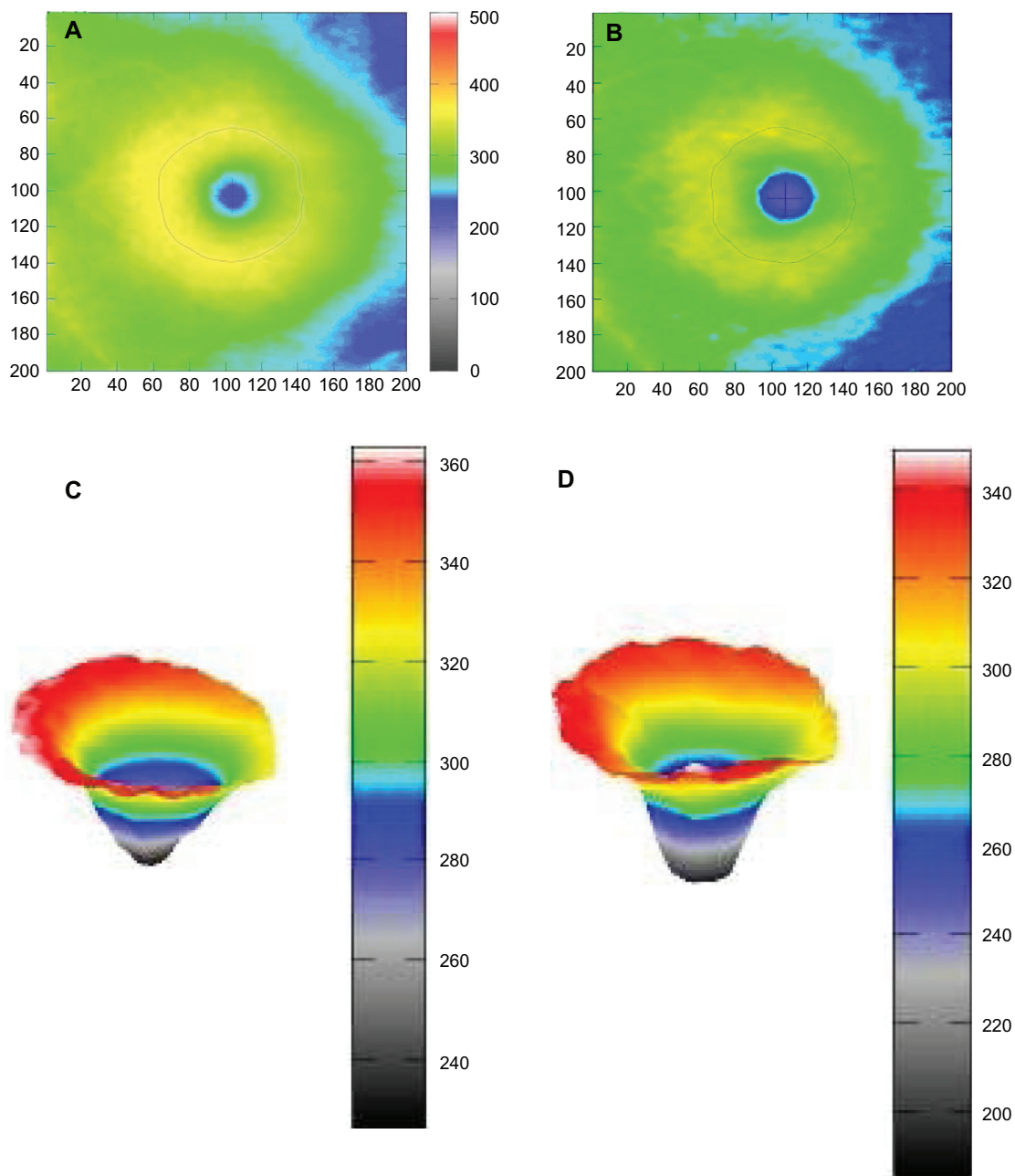


Figure 2 Method of measuring foveal pit shape. (A and C) Before the macular PVD; (B and D) after the development of a macular PVD. (A and B) Foveal rim indicated by red circular lines on the macular thickness maps. Moving away from the foveal center, the rim of the foveal pit is identified as a location of 0 slope. (C and D) Three-dimensional foveal pit shapes between the “pit lid” (a plane fit to the pit rim) and the ILM.

Notes: Pit depth and pit volume were defined as the largest distance and volume between the pit lid and ILM, respectively. Pit area was defined as the enclosed area of the pit rim.

Abbreviations: ILM, internal limiting membrane; PVD, posterior vitreous detachment.

The values of foveal shape parameters did not change significantly during the 2-year follow-up after the development of the macular PVD. The pit depth was 149, 155, 147, 159, and 153 μm , pit volume was 0.145, 0.149, 0.148, 0.160, and 0.151 mm^3 , and central foveal thickness was 179, 179, 178, 176, and 172 μm at 0, 6, 12, 18, and 24 months,

respectively, after the visit when the macular PVD was detected.

Discussion

A macular PVD occurs asymptotically in most individuals.^{10,11} An abnormal foveal shape, such as one with a flat

Table 1 Changes in macular measurements before and 1 year after macular PVD

Thickness parameters	Before macular PVD	After macular PVD	Change rate (%)
Foveal shape parameters			
Central foveal thickness (μm)	215	179	-16.7
Pit depth (μm)	122	147	+20.5
Pit diameter (μm)	2399	2617	+9.1
Foveola diameter (μm)	475	545	+14.7
Pit area (mm^2)	4.18	4.23	+2.4
Pit volume (mm^3)	0.124	0.148	+19.4
ETDRS¹³ subfield			
Central	262	228	-13.0
Inner superior	337	324	-3.9
Inner temporal	323	309	-4.3
Inner inferior	343	326	-5.0
Inner nasal	349	326	-6.6
Outer superior	291	287	-1.4
Outer temporal	283	273	-3.5
Outer inferior	290	274	-5.5
Outer nasal	318	308	-3.1

Abbreviations: ETDRS, Early Treatment Diabetic Retinopathy Study; PVD, posterior vitreous detachment.

or irregular floor, is occasionally found in those eyes with an asymptomatic macular PVD, especially in the fellow eyes of patients with a unilateral macular hole.¹² Such foveal deformation has also been shown to occur after a spontaneous macular hole closure,¹⁴ and it can also occur at the abortion of a stage 1 macular hole.¹⁵ To the best of our knowledge, our case is the first to show a change of the foveal shape to a flat floor following a spontaneous resolution of perifoveal PVD in the same eye. A foveal deformation indicating a stage 1 macular hole was not detected in the SD-OCT images performed every 6 months. The abnormal foveal shape with a macular PVD in otherwise normal eyes may be due to the spontaneous resolution of the perifoveal PVD.

Measurements of the foveal parameters showed a thinning of the central foveal thickness, deepening of the pit, and widening of the foveal floor. The deepening of the pit and widening of the foveal floor would be associated with an increase in the pit volume. Tick et al⁶ showed that a greater pit diameter and deeper foveal pit were correlated with a thinner central fovea in normal eyes. Thinning of the central fovea, deepening of the pit depth, and widening of the foveal floor that occurred after a macular PVD may account for the significant correlation. The results of our measurements suggest that the presence or absence of a macular PVD

needs to be considered in interpreting the measurements in cross-sectional studies.

In our case, the average regional macular thickness decreased after the development of a macular PVD. The decrease was by 36 μm , or a 13.0% reduction in the central foveal thickness; 13 to 23 μm or 3.9% to 6.6% for the inner-ring subfields; and 4 to 16 μm or 1.4% to 5.5% for the outer-ring subfields. The regional macular thickness is classified as “normal,” “borderline thinning/thickening,” and “abnormal thinning/thickening” when the thickness is less than 1 % and 5% of the normative database of healthy eyes, respectively. However, measuring the effects of a macular PVD on the average regional macular thickness was not a function of the OCT diagnostic software. Because the differences and reduction rates in our case were not small, the presence or absence of a macular PVD should be considered in addition to other factors such as age and sex that affect regional macular thickness.

The mechanism by which the macular PVD altered the foveal shape and regional macular thickness was not determined. We suggest two possibilities. One is the release of the tractional force on the fovea by the perifoveal PVD after the development of the macular PVD; that is, an anterior centrifugal traction may have caused the thickening of the fovea, and release of this traction would then lead to the decrease of the foveal thickness, hence the deepening the pit depth and increase in pit volume. The other suggestion is that a loss of superficial foveal tissue occurred during the spontaneous resolution of the perifoveal PVD. In fact, the detached posterior hyaloid membrane showed a highly reflective operculum-like structure in a location corresponding to the fovea. An earlier study have shown that the operculum in eyes with stage 3 macular hole contained glial and/or neuronal tissue.¹⁶ Although histological data are not available for the operculum-like structure during a physiologic PVD, the operculum-like structure may account for the flattening of the foveal shape and thinning of the fovea. Regardless of these speculations, we do not have a clear explanation of why the inner macular thickness decreased after the development of a macular PVD.

Conclusion

The findings in our case suggest that the presence or absence of a macular PVD need to be considered when the foveal shape and regional macular thickness are analyzed. Future studies should investigate the age-dependent changes of the foveal shape by considering the effect of macular PVD on the foveal morphology.

Disclosure

The author reports no conflicts of interest in this work.

References

- Chan A, Duker JS, Ko TH, Fujimoto JG, Schuman JS. Normal macular thickness measurements in healthy eyes using Stratus optical coherence tomography. *Arch Ophthalmol*. 2006;124:193–198.
- Grover S, Murthy RK, Brar VS, Chalam KV. Normative data for macular thickness by high-definition spectral-domain optical coherence tomography (spectralis). *Am J Ophthalmol*. 2009;148:266–271.
- Ooto S, Hangai M, Sakamoto A, et al. Three-dimensional profile of macular retinal thickness in normal Japanese eyes. *Invest Ophthalmol Vis Sci*. 2010;51:465–473.
- Duan XR, Liang YB, Friedman DS, et al. Normal macular thickness measurements using optical coherence tomography in healthy eyes of adult Chinese persons: the Handan Eye Study. *Ophthalmology*. 2010;117:1585–1594.
- Song WK, Lee SC, Lee ES, Kim CY, Kim SS. Macular thickness variations with sex, age, and axial length in healthy subjects: a spectral domain-optical coherence tomography study. *Invest Ophthalmol Vis Sci*. 2010;51:3913–3918.
- Tick S, Rossant F, Ghorbel I, et al. Foveal shape and structure in a normal population. *Invest Ophthalmol Vis Sci*. 2011;52:5105–5110.
- Barak Y, Sherman MP, Schaal S. Mathematical analysis of specific anatomic foveal configurations predisposing to the formation of macular holes. *Invest Ophthalmol Vis Sci*. 2011;52:8266–8270.
- Dubis AM, Hansen BR, Cooper RF, Beringer J, Dubra A, Carroll J. Relationship between the foveal avascular zone and foveal pit morphology. *Invest Ophthalmol Vis Sci*. 2012;53:1628–1636.
- Gaudric A, Haouchine B, Massin P, Paques M, Blain P, Erginay A. Macular hole formation: new data provided by optical coherence tomography. *Arch Ophthalmol*. 1999;117:744–751.
- Johnson MW. Perifoveal vitreous detachment and its macular complications. *Trans Am Ophthalmol Soc*. 2005;103:537–567.
- Uchino E, Uemura A, Ohba N. Initial stages of posterior vitreous detachment in healthy eyes of older persons evaluated by optical coherence tomography. *Arch Ophthalmol*. 2001;119:1475–1479.
- Kumagai K, Hangai M, Larson E, Ogino N. Vitreoretinal interface and foveal deformation in asymptomatic fellow eyes of patients with unilateral macular holes. *Ophthalmology*. 2011;118:1638–1644.
- Early Treatment Diabetic Retinopathy Study Research Group. Grading diabetic retinopathy from stereoscopic color fundus photographs – an extension of the modified Airlie House classification. ETDRS report number 10. *Ophthalmology*. 1991;98:786–806.
- Inoue M, Arakawa A, Yamane S, Watanabe Y, Kadonosono K. Long-term outcome of macular microstructure assessed by optical coherence tomography in eyes with spontaneous resolution of macular hole. *Am J Ophthalmol*. 2012;153:687–691.
- Takahashi A, Nagaoka T, Yoshida A. Stage 1-A macular hole: a prospective spectral-domain optical coherence tomography study. *Retina*. 2011;31:127–147.
- Ezra E, Fariss RN, Possin DE, et al. Immunocytochemical characterization of macular hole opercula. *Arch Ophthalmol*. 2001;119:223–231.

Clinical Ophthalmology

Publish your work in this journal

Clinical Ophthalmology is an international, peer-reviewed journal covering all subspecialties within ophthalmology. Key topics include: Optometry; Visual science; Pharmacology and drug therapy in eye diseases; Basic Sciences; Primary and Secondary eye care; Patient Safety and Quality of Care Improvements. This journal is indexed on

Submit your manuscript here: <http://www.dovepress.com/clinical-ophthalmology-journal>

Dovepress

PubMed Central and CAS, and is the official journal of The Society of Clinical Ophthalmology (SCO). The manuscript management system is completely online and includes a very quick and fair peer-review system, which is all easy to use. Visit <http://www.dovepress.com/testimonials.php> to read real quotes from published authors.