

# Movement of intraretinal fluid from distant branch retinal vein occlusion to the submacular space

Tomohiro Otani  
Yumiko Yamaguchi  
Shoji Kishi

Department of Ophthalmology,  
Gunma University School of Medicine,  
Maebashi, Gunma, Japan

**Background:** Extramacular branch retinal vein occlusion (BRVO) occasionally causes serous macular detachment. We studied the movement of extravasated fluid from BRVO lesions to the submacular space.

**Methods:** We examined nine eyes from nine patients with serous retinal detachment caused by extramacular BRVO. In addition to a comprehensive ophthalmic examination, optical coherence tomography was performed in all nine eyes. Six of the patients also underwent fluorescein angiography.

**Results:** Visual acuity ranged from 0.03 to 0.9 (median 0.5). All nine eyes showed localized macular detachment and retinal edema which extended from the extramacular BRVO to the macula. Fluorescein angiography revealed dye leakage in the extramacular area but no macular leakage in the six eyes examined. Optical coherence tomography revealed serous retinal detachment in the macula and intraretinal swelling, with low reflectivity in the outer retina extending from the distant BRVO toward the detached macula in all nine eyes. Six eyes were treated with laser photocoagulation, covering the entire area of BRVO, and the other three eyes were treated with intravitreal bevacizumab. Serous retinal detachment and retinal swelling resolved within 3 months of treatment in all nine eyes.

**Conclusion:** Distant retinal vascular leakage appears to diffuse through the outer retina to the macula, then permeate into the subretinal space.

**Keywords:** branch retinal vein occlusion, optical coherence tomography, serous macular detachment, fluorescein angiography, outer retina

## Introduction

Macular edema is the most common cause of visual impairment in branch retinal vein occlusion (BRVO). Recently, studies using optical coherence tomography (OCT) have revealed various morphological changes associated with macular edema, including sponge-like retinal swelling, cystic changes, and serous retinal detachment.<sup>1-3</sup> Serous retinal detachment is reported to be present in 15%–30% of patients with diabetic macular edema<sup>1,4,5</sup> and in 15%–80.8% of patients with BRVO.<sup>6-8</sup> Although fluid leakage from permeable macular vessels usually causes macular edema when the distribution of BRVO involves the macula, Finkelstein and Patz reported a distant effect of peripheral BRVO on the macula.<sup>9</sup> We previously reported that the tomographic features of macular edema secondary to distant vascular disorders were caused by serous retinal detachment with slight retinal swelling.<sup>10</sup> In that report, we speculated that the subretinal fluid in the macular area appeared to originate from a distant retinal vascular leakage because fluorescein angiography results revealed dye leakage in the

Correspondence: Tomohiro Otani  
Department of Ophthalmology,  
Gunma University School of Medicine,  
3 Showamachi, Maebashi,  
Gunma 371-8511, Japan  
Tel +81 27 220 8338  
Fax +81 27 233 3841  
Email otanito@showa.gunma-u.ac.jp

extramacular area but not the macular area. Although there have been some reports about macular edema from distant BRVO,<sup>11,12</sup> the pathogenesis remains unclear. In the present study, we investigated the tomographic changes involved in macular edema secondary to peripheral BRVO (not involving the macula) to elucidate the mechanisms of fluid movement from extramacular permeable lesions to the subretinal space at the fovea.

## Materials and methods

We retrospectively studied nine eyes from nine patients (three male and six female; median age 69 [range 49–81] years) who were followed up in our department between July 2003 and April 2012. The follow-up periods ranged from 6 to 24 (median 14) months. This retrospective study was approved by our institutional review board. We defined extramacular BRVO as occluded vessels that did not involve the macular area (5.5 mm in diameter). Inclusion criteria for this study were eyes with serous retinal detachment secondary to extramacular BRVO and a follow-up period of more than 6 months. Exclusion criteria were eyes with poor quality OCT images, serous retinal detachment caused by other etiologies, such as diabetic retinopathy, uveitis, and vitreoretinal interface disease, a history of laser photocoagulation or vitrectomy, and dense media opacity such as cataract or vitreous hemorrhage. In addition to a comprehensive ophthalmic examination, including best-corrected visual acuity, slit-lamp examination, and indirect ophthalmoscopy, time-domain or spectral-domain OCT (Stratus OCT, Cirrus HD-OCT, Carl Zeiss Meditec Inc, Dublin, CA; or Spectralis HRA/OCT, Heidelberg Engineering, Heidelberg, Germany) was performed. Six of the patients also underwent fluorescein angiography. For the OCT examination, vertical and horizontal scans (5–8 mm in length) centered on the fovea were obtained to measure the thickness of the fovea and the subretinal space. We defined foveal thickness as the distance between the inner retinal surface and the retinal pigment epithelium at the central fovea, which included the serous retinal detachment. The thickness of the subretinal space was defined as the distance between the outer surface of the detached retina and the retinal pigment epithelium at the central fovea. In six of nine eyes, laser photocoagulation was applied to the entire area of BRVO within 2 weeks of the initial examination. The other three eyes were treated with intravitreal injection of 1.25 mg bevacizumab (Avastin®, Genentech Inc, San Francisco, CA) within 2 weeks of the first examination.

## Results

The clinical characteristics of the patients are summarized in Table 1. At the time of initial examination, visual acuity ranged from 0.03 to 0.9 (median 0.5). All nine eyes showed localized macular detachment and retinal edema which extended from extramacular BRVO to the macula. The site of occlusion was along the inferior vascular arcade in four eyes, along the superior vascular arcade in two eyes (Figure 1A), superonasal to the optic disk in two eyes (Figure 2A), and inferonasal to the optic disk in one eye (Figure 3A). In four eyes, hard exudates were seen in the macula (Figures 1A and 2A). Fluorescein angiography in six eyes revealed dye leakage in the extramacular area but no macular leakage (Figures 1B and 2B). Widespread nonperfusion of the retinal capillary bed was observed in three of six eyes (Figure 2B). In all nine eyes, OCT showed serous retinal detachment in the macula and outer retinal swelling of low reflectivity extending from the distant permeable lesions toward the fovea (Figures 1C, 2C, and 3B). On the other side across the fovea, slight retinal swelling was seen in the macula in three eyes, but no retinal swelling was found in the other six eyes. Foveal thickness was 280–575  $\mu\text{m}$  (median 425  $\mu\text{m}$ ). The thickness of the subretinal space was 145–373  $\mu\text{m}$  (median 240  $\mu\text{m}$ ). After treatment, serous retinal detachment and retinal swelling were resolved within 3 months in all nine eyes.

## Discussion

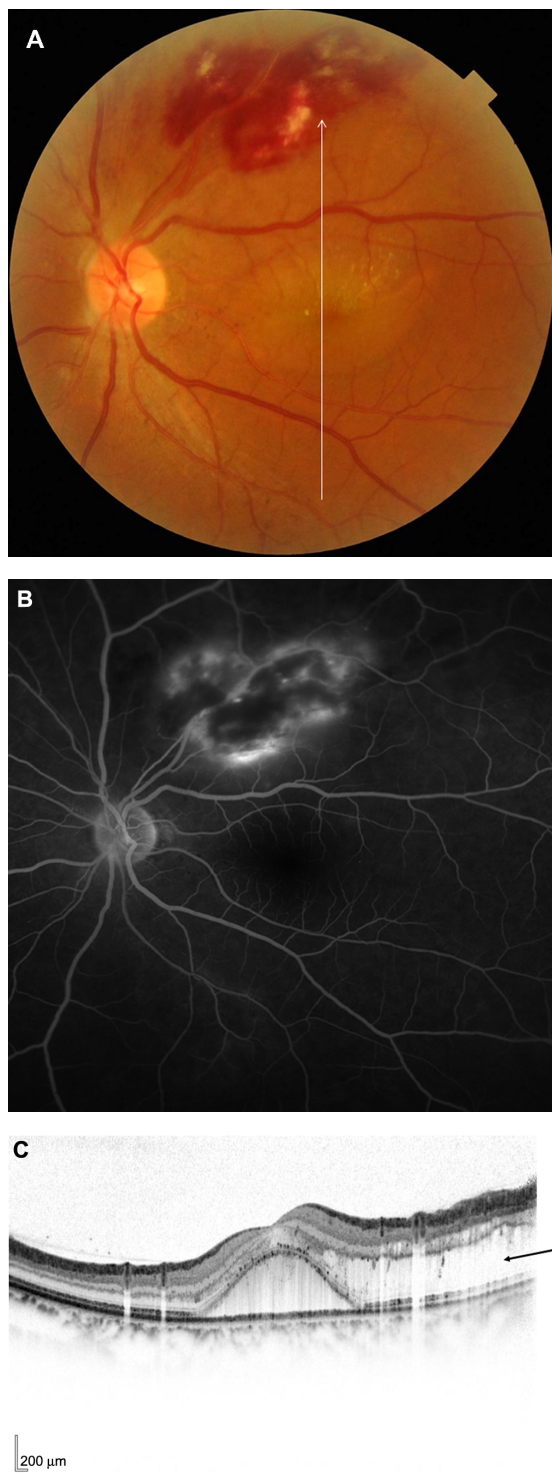
We examined nine patients with a serous macular detachment secondary to an extramacular BRVO. Fluorescein angiography, performed in six of the nine patients, revealed dye leakage in the extramacular area but not in the macular area. OCT revealed serous retinal detachment in the macula, as well as outer retinal swelling. Importantly, our results demonstrated that retinal swelling extended from the extramacular BRVO toward the fovea.

Retinal swelling and cystoid macular edema are usually caused by leakage from retinal vessels, such as in retinal vascular disease and uveitis. Subretinal fluid can also cause structural changes in the detached neurosensory retina.<sup>13</sup> OCT analysis of rhegmatogenous retinal detachment showed intraretinal cyst formation, intraretinal separation, and undulation of the outer detached retina.<sup>13,14</sup> In the acute phase of central serous chorioretinopathy, the neurosensory retina is thickened within the area of serous retinal detachment.<sup>15</sup> As such, it was previously thought that intraretinal edema was a secondary change in serous retinal detachment caused by distant BRVO, and that the subretinal fluid in the macula originated from distant retinal vascular leakage through

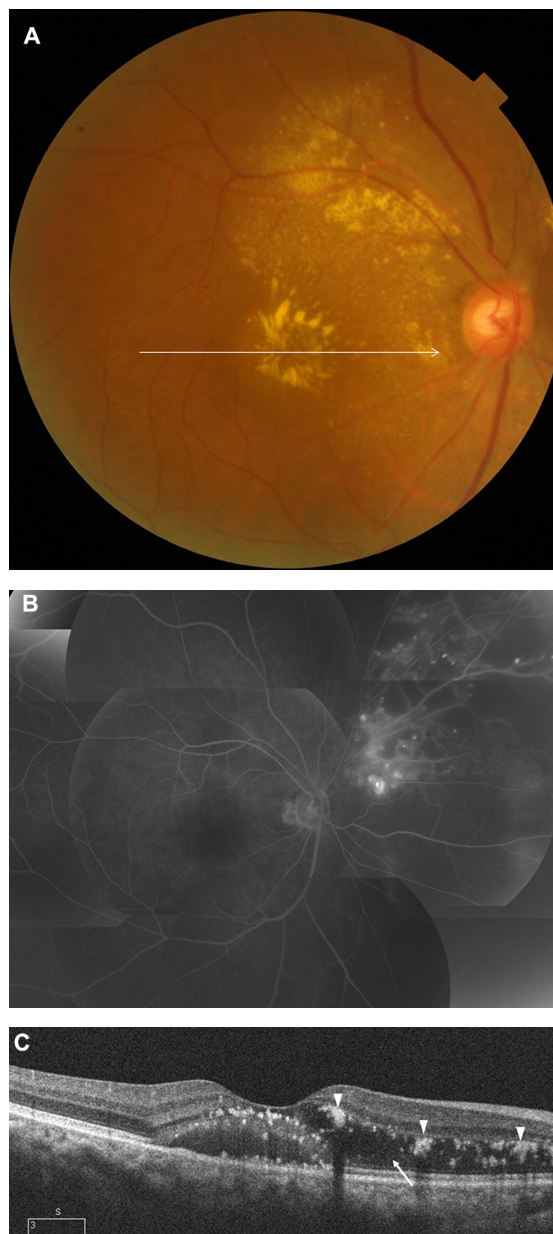
**Table 1** Clinical profiles of the patients

No	Age	Gender	VA		Systemic conditions	FA findings		Type of BRVO	OCT findings			
			Initial	Final		The location of BRVO	The location of dye leakage		The area of nonperfusion	The foveal thickness	The thickness of subretinal space	The presence and location of ORS
1	63	F	0.2	1.2	HBP	Superonasal midperiphery	Superonasal midperiphery	Ischemic	425	232	Nasal to the fovea	Superior to the fovea
2	50	F	0.8	1.5	HBP	Inferotemporal midperiphery	Inferotemporal midperiphery	Ischemic	370	240	Temporal to the fovea	Inferior to the fovea
3	74	F	0.03	0.4	HBP	Inferior midperiphery	Inferior midperiphery	Ischemic	534	292	Nasal to the fovea	Inferior to the fovea
4	57	M	0.8	1.2	HBP	Along the inferior retinal vascular arcade	Along the inferior retinal vascular arcade	Non ischemic	543	333	None	Inferior to the fovea
5	69	M	0.2	0.9	HBP, HC	Superior midperiphery	Not performed	Not performed	539	373	Nasal to the fovea	Superior to the fovea
6	81	F	0.7	1.2	HBP	Along the inferior retinal vascular arcade	Not performed	Not performed	366	170	Nasal to the fovea	Inferior to the fovea
7	74	F	0.9	0.8	Nothing particular	Inferonasal midperiphery	Not performed	Not performed	317	146	Nasal to the fovea	Inferior to the fovea
8	72	F	0.15	0.2	IHD, HL	Superonasal midperiphery	Superonasal midperiphery	Ischemic	280	145	Nasal to the fovea	Superior to the fovea
9	49	M	0.5	1.2	HL	Along the superior retinal vascular arcade	Along the superior retinal vascular arcade	Non ischemic	575	363	Nasal to the fovea	Superior to the fovea
Median	69		0.5	1.2					425	240		

**Abbreviations:** FA, fluorescein angiography; OCT, optical coherence tomography; VA, visual acuity; BRVO, branch retinal vein occlusion; M, male; F, female; HBP, hypertension; HC, hepatitis C; IHD, ischemic heart disease; HL, hyperlipidemia.

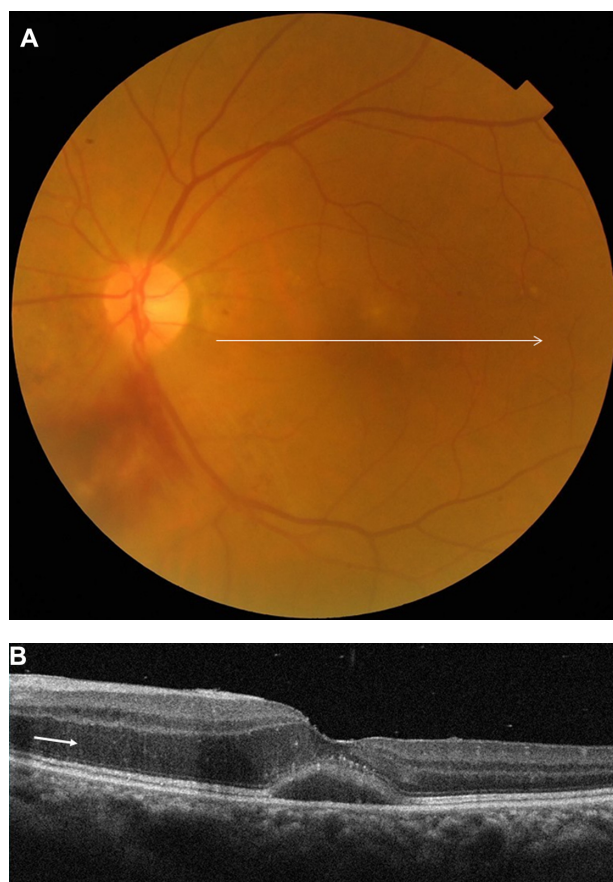


**Figure 1** A 49-year-old man (patient 9) with a branch retinal vein occlusion had a 4-week history of blurred vision in his left eye. Best-corrected visual acuity was 0.5. **(A)** Fundus photograph shows serous macular detachment, hard exudates, and flame-shaped hemorrhages extending from the superior retinal vascular arcade to the superotemporal mid peripheral fundus. The vertical arrow indicates optical coherence tomography scanning lines (8 mm). **(B)** In the late phase of the fluorescein angiogram, there is marked hyperfluorescence of the superior retinal vascular arcade but no dye leakage in the macular area. **(C)** A vertical optical coherence tomography scan shows serous retinal detachment at the fovea and outer retinal swelling, which is evident superior to the fovea (arrow). **Note:** The foveal thickness is 575  $\mu\text{m}$  and the thickness of serous retinal detachment is 363  $\mu\text{m}$ .



**Figure 2** A 72-year-old woman (patient 8) with a branch retinal vein occlusion had a 2-month history of blurred vision in her right eye. Best-corrected visual acuity was 0.15. **(A)** Fundus photograph shows serous macular detachment and hard exudates. The horizontal arrow indicates optical coherence tomography scanning lines (6 mm). **(B)** Fluorescein angiogram reveals dye leakage from retinal vessels and a large area of capillary nonperfusion extending from the optic disk to the superonasal mid peripheral fundus but no dye leakage in the macular area. **(C)** A horizontal optical coherence tomography scan shows a serous retinal detachment at the fovea and outer retinal swelling, which is evident nasal to the fovea (arrow) and hard exudates (arrow heads). **Note:** The foveal thickness is 280  $\mu\text{m}$  and the thickness of the serous retinal detachment is 145  $\mu\text{m}$ .

the subretinal space.<sup>10</sup> However, in the present study, OCT revealed that outer retinal swelling was present not only in the detached retina but also in the attached retina, extending from extramacular permeable lesions toward the fovea. These findings suggest the possibility that distant retinal vascular



**Figure 3** A 74-year-old woman (patient 7) with a branch retinal vein occlusion had a 2-week history of blurred vision in her left eye. Best-corrected visual acuity was 0.9. **(A)** Fundus photograph shows serous macular detachment and a part of the flame-shaped hemorrhages extending from the optic disk to the inferonasal midperipheral fundus. The horizontal arrow indicates optical coherence tomography scanning lines (6 mm). **(B)** A horizontal optical coherence tomography scan shows a serous retinal detachment at the fovea and outer retinal swelling, which is evident nasal to the fovea (arrow).

**Note:** The foveal thickness is 317  $\mu\text{m}$  and the thickness of the serous retinal detachment is 146  $\mu\text{m}$ .

leakage diffuses through the outer retina to the macula and accumulates there. These accumulations may exude from the intraretinal tissue to the subretinal space at the fovea.

Wise and Wangvivat proposed that the macula has an exaggerated pathological response to some generalized retinal disorders, such as retinal vein occlusion, angioid streaks, uveitis, diabetic retinopathy, and Coats' disease.<sup>16</sup> We found that although outer retinal swelling was identified between extramacular lesions and the fovea, it was seldom observed on the other side of the fovea. This indicates that intraretinal leakage tends to accumulate toward the macula, which may constitute an exaggerated macular response. Yamaguchi et al reported that the incidence of serous retinal detachment was higher in a group with major BRVO (defined as BRVO involving a large area outside the vascular arcade in addition to the macular area) than in a group with macular BRVO

(defined as BRVO in which retinal hemorrhage is confined within the major vascular arcade) and that foveal thickness in individuals with major BRVO (mean of 610  $\mu\text{m}$ ) was significantly greater than that in individuals with macular BRVO (mean of 500  $\mu\text{m}$ ).<sup>6</sup> This also indicates that vascular leakage from congested retinal veins outside the macular area is related to retinal swelling and subretinal fluid accumulation in the macula. Although the reason for this exaggerated macular response is unclear, Naumann and Apple proposed the following factors as partially responsible for the occurrence of this phenomenon: increased thickness of the sensory retina in the perifoveal region; special orientation of the fibers of the outer plexiform layer in this region, forming Henle's fiber layer; high content of melanin within retinal pigment epithelial cells in this region; and high concentration of retinal pigment epithelial cells at the posterior pole.<sup>17</sup>

An increased vascular endothelial growth factor level may also cause serous retinal detachment in the macula and outer retinal swelling, because fluorescein angiography showed widespread nonperfusion of the retinal capillary bed in three of six eyes examined. In addition, the fact that serous retinal detachment and outer retinal swelling resolved after laser photocoagulation or intravitreal injection of bevacizumab suggests involvement of vascular endothelial growth factor. However, it is unlikely that macular vessels were directly affected by vascular endothelial growth factor because fluorescein angiography showed no macular leakage. In conclusion, distant retinal vascular leakage seems to diffuse through the outer retina to the macula and permeate into the subretinal space.

## Disclosure

The authors report no proprietary interest in any aspect of this work.

## References

1. Otani T, Kishi S, Maruyama Y. Patterns of diabetic macular edema with optical coherence tomography. *Am J Ophthalmol.* 1999;127(6): 688–693.
2. Spaide RF, Lee JK, Klancnik JK Jr, Gross NE. Optical coherence tomography of branch retinal vein occlusion. *Retina.* 2003;23(3): 343–347.
3. Gaucher D, Sebah C, Erginay A, et al. Optical coherence tomography features during the evolution of serous retinal detachment in patients with diabetic macular edema. *Am J Ophthalmol.* 2008;145(2):289–296.
4. Catier A, Tadayoni R, Paques M, et al. Characterization of macular edema from various etiologies by optical coherence tomography. *Am J Ophthalmol.* 2005;140(2):200–206.
5. Ozdemir H, Karacorlu M, Karacorlu S. Serous macular detachment in diabetic cystoid macular oedema. *Acta Ophthalmol Scand.* 2005;83(1): 63–66.
6. Yamaguchi Y, Otani T, Kishi S. Serous macular detachment in branch retinal vein occlusion. *Retina.* 2006;26(9):1029–1033.

7. Shroff D, Mehta DK, Arora R, Narula R, Chauhan D. Natural history of macular status in recent-onset branch retinal vein occlusion: an optical coherence tomography study. *Int Ophthalmol*. 2008;28(4):261–268.
8. Tsujikawa A, Sakamoto A, Ota M, et al. Serous retinal detachment associated with retinal vein occlusion. *Am J Ophthalmol*. 2010;149(2):291–301.
9. Finkelstein D, Patz A. Distant effect of peripheral branch vein occlusion on the macula. *Trans Am Ophthalmol Soc*. 1988;86:380–388.
10. Otani T, Yamaguchi Y, Kishi S. Serous macular detachment secondary to distant retinal vascular disorders. *Retina*. 2004;24(5):758–762.
11. Taki W, Oohira A, Hirakata A. Macular edema from distant branch retinal vein occlusion improved after vitrectomy. *Jpn J Ophthalmol*. 2009;53(2):184–186.
12. Ueda T, Gomi F, Suzuki M, et al. Usefulness of indocyanine green angiography to depict the distant retinal vascular anomalies associated with branch retinal vein occlusion causing serous macular detachment. *Retina*. 2012;32(2):308–313.
13. Hagimura N, Suto K, Iida T, Kishi S. Optical coherence tomography of the neurosensory retina in rhegmatogenous retinal detachment. *Am J Ophthalmol*. 2000;129(2):186–190.
14. Lee SY, Joe SG, Kim JG, Chung H, Yoon YH. Optical coherence tomography evaluation of detached macula from rhegmatogenous retinal detachment and central serous chorioretinopathy. *Am J Ophthalmol*. 2008;145(6):1071–1076.
15. Iida T, Hagimura N, Sato T, Kishi S. Evaluation of central serous chorioretinopathy with optical coherence tomography. *Am J Ophthalmol*. 2000;129(1):16–20.
16. Wise GN, Wangvivat Y. The exaggerated macular response to retinal disease. *Am J Ophthalmol*. 1966;61(5 Pt 2):1359–1363.
17. Naumann GOH, Apple DJ. *Pathology of the Eye*. New York, NY: Springer-Verlag; 1980.

## Clinical Ophthalmology

### Publish your work in this journal

Clinical Ophthalmology is an international, peer-reviewed journal covering all subspecialties within ophthalmology. Key topics include: Optometry; Visual science; Pharmacology and drug therapy in eye diseases; Basic Sciences; Primary and Secondary eye care; Patient Safety and Quality of Care Improvements. This journal is indexed on

Submit your manuscript here: <http://www.dovepress.com/clinical-ophthalmology-journal>

Dovepress

PubMed Central and CAS, and is the official journal of The Society of Clinical Ophthalmology (SCO). The manuscript management system is completely online and includes a very quick and fair peer-review system, which is all easy to use. Visit <http://www.dovepress.com/testimonials.php> to read real quotes from published authors.