

Refractive Surprises After Cataract Surgery: Identification and Management in Optometric Practice- A Comprehensive Review

Bharat Gurnani ¹, Kirandeep Kaur²

¹Department of Cataract, Cornea and Refractive Surgery, Gomabai Netralaya and Research Centre, Neemuch, MP, 458441, India; ²Department of Cataract, Pediatric Ophthalmology and Strabismus, Gomabai Netralaya and Research Centre, Neemuch, MP, 458441, India

Correspondence: Bharat Gurnani, Department of Cataract, Cornea and Refractive Surgery, Gomabai Netralaya and Research Centre, Neemuch, MP, 458441, India, Tel +919080523059, Email drgurnanibharat25@gmail.com

Abstract: Refractive surprises remain one of the most challenging postoperative complications in modern cataract surgery, where precision and patient expectations for plano refractive outcomes continue to rise. Despite advances in optical biometry, intraocular lens (IOL) formula optimization, and surgical technology, postoperative refractive error still occurs in a subset of patients and may significantly affect visual satisfaction and quality of life. This review synthesizes contemporary evidence on the causes, detection, and optometric management of refractive surprises, with a practical focus on the evolving role of the optometrist in co-management. Residual refractive error most commonly results from biometric inaccuracies, keratometric misalignment, incorrect estimation of effective lens position, prior corneal refractive procedures, and anatomical extremes such as axial myopia or hyperopia. Early recognition through comprehensive postoperative assessment—including manifest refraction, keratometric stability, IOL position evaluation, corneal tomography, and retinal imaging—is critical to differentiating optical errors from pathology. Management options include spectacles and contact lenses for mild errors, while significant ametropia may require corneal refractive surgery, arcuate keratotomy, piggyback IOL implantation, or IOL exchange depending on patient factors, ocular anatomy, and refractive stability. The review further discusses algorithmic approaches to decision-making, counseling strategies for dissatisfied patients, and considerations when dealing with toric and multifocal IOLs. As optometrists increasingly serve as primary comanagers of cataract surgery patients, understanding the etiology and management of refractive surprises is essential. Improved diagnostic workflows, individualized IOL planning, and collaborative postoperative care pathways can greatly enhance refractive predictability and visual outcomes.

Keywords: refractive Surprise, cataract surgery, residual refractive error, IOL power calculation, optometry, biometry

Introduction

Cataract surgery has undergone a profound transformation from a procedure primarily aimed at restoring functional vision to one that is increasingly expected to deliver refractive precision.¹ In modern ophthalmic practice, cataract extraction is effectively refractive surgery. The introduction of high-performance intraocular lenses (IOLs), expanded availability of premium lens technologies, sophisticated optical biometers, and advanced surgical guidance systems has shifted the focus of cataract surgery toward spectacle independence and customized refractive outcomes.² As patient expectations rise accordingly, even small deviations between the intended and achieved postoperative refraction, the so-called “refractive surprises” have become clinically significant events.³ A refractive miss that might once have been considered acceptable can now result in patient dissatisfaction, functional limitation, and emotional distress, particularly in individuals who have invested in premium IOLs or were counselled toward spectacle-free outcomes.⁴ The uptake of advanced technology IOLs and the refractive mindset surrounding cataract surgery magnify the consequences of residual ametropia. Multifocal, trifocal, and extended-depth-of-focus (EDOF) lenses demand near-perfect preoperative measurements and precise postoperative alignment for optimal performance.⁵ Similarly, toric IOLs rely heavily on accurate keratometry and rotational stability. Even small inaccuracies, such as a few degrees of toric lens rotation or a 0.5 D residual spherical error can significantly affect

visual quality.⁶ Patients accustomed to high-quality vision with contact lenses or prior refractive surgery may be exceptionally sensitive to visual inconsistencies. The boundary of what constitutes an “acceptable” refractive outcome has narrowed dramatically, and optometrists are frequently the first clinicians to evaluate these results in the postoperative period.⁷ Optometrists play a central and expanding role in cataract surgery comanagement. They are responsible not only for preoperative screening, biometry optimization, and ocular surface management but also for the definitive postoperative refraction and determination of whether the achieved visual outcome meets the patient’s expectations and functional needs.⁸ Optometrists are often the first to identify subtle refractive errors, early IOL misalignment, irregular astigmatism, or ocular surface instability masquerading as a refractive miss. Their growing involvement in refractive cataract pathways places them at the forefront of detecting, diagnosing, and managing refractive surprises or coordinating timely referral when surgical intervention is required.⁹ A “refractive surprise” is generally defined as an unexpected postoperative refractive outcome that deviates meaningfully from the targeted refraction. It encompasses errors related to residual myopia, hyperopia, astigmatism, or anisometropia and can range from mild, correctable ametropia to severe deviations requiring surgical revision.¹⁰ Refractive surprises may be immediately apparent or may emerge over several weeks as the cornea stabilizes, the tear film improves, or the IOL settles within the capsular bag. Their incidence varies depending on patient population and surgical complexity, but even with modern biometry and 4th–5th generation IOL formulas, refractive accuracy within ± 0.50 D is not guaranteed for all eyes. Post-refractive surgery corneas, extremely short or long axial lengths, keratoconus, irregular astigmatism, zonular laxity, and dry eye disease remain fundamental challenges in achieving refractive precision.¹¹

Lundström et al analyzed 282,811 cataract cases in the EUREQUO registry and showed that, despite modern biometry and IOL calculation methods, refractive accuracy remains imperfect—only 72.7% of eyes achieved a postoperative spherical equivalent within ± 0.50 D and 93.0% within ± 1.00 D, underscoring the ongoing relevance of refractive outcome auditing and systematic error reduction.¹² Building on this quality-improvement perspective, Gale et al proposed practical NHS benchmark standards for routine cataract surgery ($\sim 55\%$ within ± 0.50 D and $\sim 85\%$ within ± 1.00 D) to support audit-driven optimization of constants, measurements, and surgical processes.¹³ In complex eyes, particularly those with prior corneal refractive surgery, Abulafia et al demonstrated that specialized post-refractive formulas such as Barrett True-K can improve IOL power prediction compared with several commonly used alternatives, highlighting formula choice as a key modifiable contributor to postoperative refractive surprise.¹⁴ The clinical impact of refractive surprises extends beyond dioptres. Patients may experience visual distortion, ghosting, monocular diplopia, glare, halos, reduced contrast sensitivity, and difficulty performing visually demanding tasks. These symptoms are amplified in premium IOL recipients whose visual systems depend on precise modulation of light.¹⁵ In addition, the psychological burden on patients, especially those who invested financially in advanced technology lenses can strain the doctor–patient relationship and prolong postoperative care.¹⁶ Addressing refractive surprises requires both technical expertise and compassionate patient communication. In this evolving landscape, the optometrist’s role is multidimensional. First, optometrists help prevent refractive surprises by optimizing ocular surface health before biometry, identifying high-risk eyes (such as those with forme fruste keratoconus or prior LASIK), and counseling patients realistically about refractive predictability.¹⁷ Second, optometrists are critical in early postoperative evaluation, when careful refraction, corneal tomography, and slit-lamp assessment can distinguish benign healing-related variability from true refractive error.⁸ Third, optometrists must guide management: prescribing spectacles or therapeutic contact lenses, stabilizing the ocular surface, or recommending procedural solutions such as laser vision correction, arcuate keratotomy, piggyback IOLs, or IOL exchange when appropriate.¹⁸ Timely identification of complications such as toric IOL rotation or capsular contracture allows corrective action before the window for safe surgical intervention closes.¹⁹ Despite significant advancements in biometric technology and intraocular lens (IOL) calculation formulas, several critical gaps persist in the prediction and management of refractive outcomes following cataract surgery. Current challenges include limited accuracy in eyes with prior corneal refractive surgery, variability in effective lens position prediction, and inconsistent integration of posterior corneal astigmatism into routine calculations.¹⁴ Furthermore, there is a lack of standardized diagnostic algorithms to differentiate true refractive error from ocular surface–related variability or subtle structural pathology in the early postoperative period. Emerging technologies such as intraoperative aberrometry, ray-tracing–based IOL calculation methods, and artificial intelligence–driven predictive models have shown promise in addressing these limitations, yet their integration into routine clinical practice remains heterogeneous. From an optometric perspective, the application of these advanced diagnostic tools in postoperative assessment and co-management pathways is not fully defined. Addressing these gaps is essential for improving

refractive predictability, optimizing patient satisfaction, and enhancing interdisciplinary collaboration in modern cataract care.¹⁹ The purpose of this review article is to equip optometrists with a comprehensive, evidence-based framework for identifying and managing refractive surprises after cataract surgery. This includes understanding the multifactorial etiology of refractive errors, the diagnostic workflow required to pinpoint their cause, and the full range of management strategies—from conservative correction to surgical revision. By synthesizing current literature and clinical experience, the review aims to enhance the optometrist's ability to anticipate refractive errors, counsel patients effectively, collaborate with surgeons, and implement tailored interventions that restore visual function and patient satisfaction. Ultimately, the growing complexity of refractive cataract surgery demands enhanced integration between ophthalmologists and optometrists. As comanagement models strengthen, optometrists will continue to be instrumental in improving refractive predictability, minimizing surprises, and ensuring the best possible postoperative outcomes for patients seeking high-precision cataract surgery.

Definitions and Epidemiology

Accurate terminology is fundamental when discussing refractive outcomes after cataract surgery, as imprecise or inconsistent language can lead to confusion among clinicians, researchers, and patients.²⁰ Modern refractive cataract surgery thrives on predictability; therefore, defining what constitutes success and what qualifies as a refractive “surprise”—requires conceptual clarity. Several terms are frequently used in clinical practice and scientific literature, sometimes interchangeably, yet they represent distinct concepts with different implications for evaluation and management.²¹ Prediction error refers to the difference between the intended refractive target and the postoperative refraction, typically expressed in spherical equivalent (SE). This metric quantifies how closely biometry, IOL formula selection, and surgical execution achieved the planned refractive outcome. A prediction error may be positive (hyperopic shift) or negative (myopic shift), and its magnitude is central to evaluating the accuracy of preoperative measurements.²² In contrast, residual refractive error refers to the *actual* postoperative refractive state, irrespective of the intended target. Residual ametropia may reflect an inherent limitation in surgical precision, anatomical variability, progressive corneal changes, wound healing effects, toric IOL rotation, or other postoperative factors. While prediction error evaluates the accuracy of planning, residual refractive error evaluates the functional refractive status that must be addressed through optical or surgical means.²³ A refractive surprise is best understood as a clinically meaningful deviation from the anticipated refractive outcome, large enough to impact visual performance or patient satisfaction. There is no universal threshold that defines a refractive surprise.²⁴ In standard monofocal IOL patients, many surgeons consider a deviation greater than ± 0.75 D from target as unexpected, whereas in premium IOL recipients, even a ± 0.50 D shift may result in substantial visual disturbances, glare, halos, or dissatisfaction. In toric IOLs, small misalignments produce significant cylindrical errors, such that >10 degrees of rotation is generally considered clinically important, while even 5 degrees can noticeably reduce cylinder-correcting efficacy.²⁵ Consistency in reporting is crucial, and spherical equivalent (SE) and astigmatic cylinder remain the preferred, comparable metrics for both clinical care and research audits. SE provides a single summary value for refractive status, while cylinder quantifies astigmatic error; both should be documented to properly characterize residual refractive patterns. Additionally, vector analysis (eg., Alpins method) has been increasingly adopted to evaluate astigmatic correction and surgically induced astigmatism with greater precision, especially relevant in toric and refractive cataract surgery.²⁶

Refractive outcomes are increasingly monitored through national and international registries, enabling the establishment of performance standards. These registries consistently demonstrate that, despite technological advances, a “tail” of postoperative refractive error persists in all datasets.²⁷ A commonly cited benchmark is that approximately 70–80% of patients should achieve postoperative outcomes within ± 0.50 D of target and 90–95% within ± 1.00 D when using modern optical biometry and updated IOL formulas. Nonetheless, outcomes are substantially poorer in populations with surgically complex eyes, including those with prior corneal refractive surgery, keratoconus, highly myopic or hyperopic axial lengths, or posterior segment abnormalities. Large cataract surgery audits from Europe, the United Kingdom, Australia, and the United States consistently confirm these findings.²⁸ For example, registry-based studies show that 10–20% of patients still fall outside the ± 0.75 D range despite optimal preoperative and intraoperative procedures. These persistent “outliers” reflect the multifactorial nature of refractive error, including unpredictable effective lens position, posterior corneal curvature variability, ocular surface instability affecting keratometry, and biometric measurement noise. Importantly, the incidence of refractive surprises is significantly higher in post-LASIK/PRK eyes—even when modern formulas such as Barrett True-K or Haigis-L are used. Similarly, toric IOLs are susceptible to postoperative misalignment, with each degree of rotation causing approximately 3.3% loss of astigmatic correction. Thus, eyes receiving

premium IOLs, by virtue of requiring higher refractive precision, exhibit higher functional sensitivity to error—effectively raising their refractive surprise rate even when absolute numerical errors are small.²⁹

Epidemiology Across Clinical Contexts

Epidemiological patterns vary by patient population, surgeon experience, and technology availability. With monofocal IOLs refractive surprises typically occur in <10–15% of cases but still represent the largest absolute number, as monofocal lenses dominate global cataract volume.³⁰ With toric IOLs approximately 5–10% of patients may experience clinically significant rotation requiring repositioning.³¹ Multifocal / EDOF IOLs lenses are more susceptible to refractive sensitivity, with even small degrees of error leading to decreased quality of vision.³² Dissatisfaction rates in premium IOL patients are significantly correlated with residual ametropia. In post-refractive surgery eyes refractive surprises occur in up to 20–30% of cases due to altered corneal geometry and increased unpredictability of effective lens position. Despite these variations, refractive surprises remain a universal challenge across surgical settings, underscoring the need for vigilance and systematic postoperative evaluation.³³ Optometrists are key contributors to refractive outcome audits because they conduct the majority of postoperative refractions, detect refractive misses, and evaluate symptom–sign mismatches. Clear and standardized definitions enable optometrists to accurately determine whether a refractive outcome represents a genuine planning error or falls within the expected range of postoperative healing variability.³⁴ These definitions also facilitate effective communication with surgeons by helping distinguish between anticipated and unexpected refractive results. Furthermore, they guide optometrists in determining the appropriate timing and type of intervention, whether optical correction, refractive enhancement, or surgical management. Importantly, the use of consistent terminology ensures clarity in medicolegal documentation and enhances the quality of patient counseling, thereby supporting coordinated and accountable postoperative care.³⁵ Furthermore, using standardized metrics (Spherical equivalent, cylinder, vector reporting) ensures uniformity in comanagement networks and contributes to more accurate benchmarking within a practice or regional cataract surgery ecosystem. Refractive surprises represent deviations from expected outcomes that may significantly affect patient satisfaction in modern refractive cataract surgery.³⁶ Differentiating prediction error from residual refractive error helps clarify etiology, guide diagnostic evaluation, and shape management decisions. Epidemiological data show that even with advanced biometry and IOL formulas, a persistent subset of patients experiences meaningful postoperative ametropia—especially in premium IOL and post-refractive surgery cohorts. Consistent definitions and metrics enable optometrists to accurately identify, quantify, and manage these refractive challenges within the comanagement pathway.³⁷

Large real-world datasets continue to demonstrate that refractive misses remain relatively common despite advances in biometry, intraocular lens (IOL) calculation formulas, and surgical techniques. In a large European Registry of Quality Outcomes for Cataract and Refractive Surgery (EUREQUO) analysis of 282,811 eyes, 72.7% achieved a postoperative spherical equivalent (SE) within ± 0.50 diopters (D) of the intended target, and 93.0% were within ± 1.00 D. Notably, a subset of 3,555 eyes (approximately 1.26%) had a prediction error exceeding ± 2.0 D, which has been operationally defined as a “refractive surprise.”³⁸ Even among so-called “best case” eyes—those without ocular comorbidity or intraoperative complications—outcomes were not universally optimal, with approximately 75% achieving ± 0.50 D and 95% achieving ± 1.00 D accuracy. Furthermore, substantial inter-clinic variability was observed, with the proportion of eyes within ± 0.50 D ranging from 44.2% to 89.4%, underscoring the influence of modifiable factors such as measurement techniques, formula selection, and surgical consistency.¹³ Historically, UK National Health Service (NHS) audit benchmarks have cited 55% of eyes within ± 0.50 D and 85% within ± 1.00 D as acceptable refractive outcome standards, and these thresholds continue to serve as reference points in contemporary audit and quality assurance literature. Collectively, these findings emphasize that while modern cataract surgery achieves high levels of refractive precision overall, refractive prediction error remains an important and clinically relevant outcome requiring ongoing audit, optimization, and system-level quality improvement. If ~7–8% of eyes fall outside ± 1.00 D, many services will see refractive surprises weekly. This is amplified in premium IOL populations where tolerance for residual error is lower and symptoms (glare/haloes, reduced contrast) may be exacerbated by small refractive errors.¹⁰

Etiology of Refractive Surprises

Refractive surprises arise from multifactorial breakdowns along the cataract surgery continuum—from preoperative measurements to postoperative healing. Although the consequences can appear dramatic, most refractive misses can be

traced to a small cluster of predictable failure points. Importantly, these factors rarely occur in isolation: subtle, seemingly insignificant errors accumulate into a meaningful deviation from the intended refractive target, forming what can be conceptualized as an “error budget.”¹⁸ When biometry is slightly off, the formula makes a borderline estimate, the capsular bag sits marginally forward, and the tear film fluctuates—all small deviations summate into a clinically significant refractive outcome (Figure 1).³⁴ Khoramnia et al reported that refractive surprise following cataract surgery most commonly arises from inaccuracies in preoperative biometry and intraocular lens (IOL) power calculation, particularly errors in axial length measurement, keratometry, and estimation of effective lens position (ELP). They emphasized that even small deviations in biometric parameters can significantly influence postoperative refractive outcomes, especially in eyes with atypical anatomy or prior refractive surgery.³⁹ Similarly, Moshirfar et al highlighted that residual refractive errors after cataract surgery frequently result from a combination of factors including measurement inaccuracies, inappropriate formula selection, surgically induced astigmatism, and postoperative IOL position changes such as tilt, decentration, or rotation.⁴⁰ Importantly, Mengistu et al demonstrated that unintended postoperative refractive error is often multifactorial and may arise from cumulative contributions of biometric error, wound-induced corneal changes, incorrect IOL selection, or postoperative healing effects. Collectively, these studies reinforce the concept that refractive surprises rarely stem from a single isolated cause but rather represent the additive effect of small deviations occurring at multiple stages of the surgical process—from preoperative measurement to postoperative healing.⁴¹ Recognizing this cumulative nature is essential for prevention and management (Table 1).

Preoperative Causes

Biometric Errors: Axial Length & Keratometry

Errors in axial length (AL) measurement remain one of the largest contributors to refractive surprises. Even a 100- μm AL error can produce ~ 0.25 D of refractive inaccuracy. Partial coherence interferometry and swept-source biometry have improved precision, but artifacts remain common in dense cataracts, staphylomas, or silicone-filled eyes.⁴² Keratometry (K) is equally influential, especially in toric IOL planning. Inconsistent tear film, meibomian gland dysfunction (MGD), and epithelial irregularity alter the anterior corneal curvature, while failure to account for posterior corneal astigmatism results in predictable residual cylinder. Small inaccuracies in K measurement disproportionately affect the cylinder axis, leading to unwanted postoperative astigmatism.⁴³ Olsen et al demonstrated that inaccuracies in axial length measurement remain one of the most significant determinants of refractive error after cataract surgery, emphasizing that even small deviations in biometry can substantially affect intraocular lens (IOL) power calculation and postoperative refractive outcomes. Their analysis highlighted that a 0.1-mm error in axial length measurement may result in approximately 0.25–0.30 D of refractive error, particularly in eyes with extreme axial lengths or abnormal posterior segment anatomy.⁴⁴ Similarly, Koch et al reported that keratometric inaccuracies—especially those arising from ocular surface instability or failure to account for posterior corneal astigmatism—can significantly influence refractive outcomes, particularly in toric IOL implantation. Their work demonstrated that neglecting posterior corneal curvature may lead to systematic overcorrection or undercorrection of astigmatism, thereby contributing to residual postoperative cylinder. Collectively, these studies underscore that precise biometric measurement and careful corneal assessment are critical for minimizing refractive surprises in modern cataract surgery.⁴⁵

Formula Limitations & Effective Lens Position (ELP) Prediction

Even with modern fourth- and fifth-generation intraocular lens (IOL) power calculation formulas such as Barrett Universal II, Kane, and EVO, accurate prediction of the postoperative IOL position, referred to as the effective lens position (ELP) remains an inherent challenge.⁴⁶ ELP estimation becomes less reliable in anatomically or biomechanically atypical eyes, including those with very short or very long axial lengths, post-refractive surgery corneas such as after LASIK or PRK, eyes with abnormal capsular bag dynamics, and corneas affected by keratoconus or other irregularities. In particular, formula selection is critically important in eyes with prior corneal refractive surgery, where the normal relationship between corneal power and axial length is altered. In such cases, the use of standard formulas may result in significant prediction errors, and failure to apply specialized post-refractive formulas, such as Barrett True-K, represents one of the most common causes of refractive surprise. These limitations highlight that, despite advances in biometry and formula sophistication, accurate ELP prediction

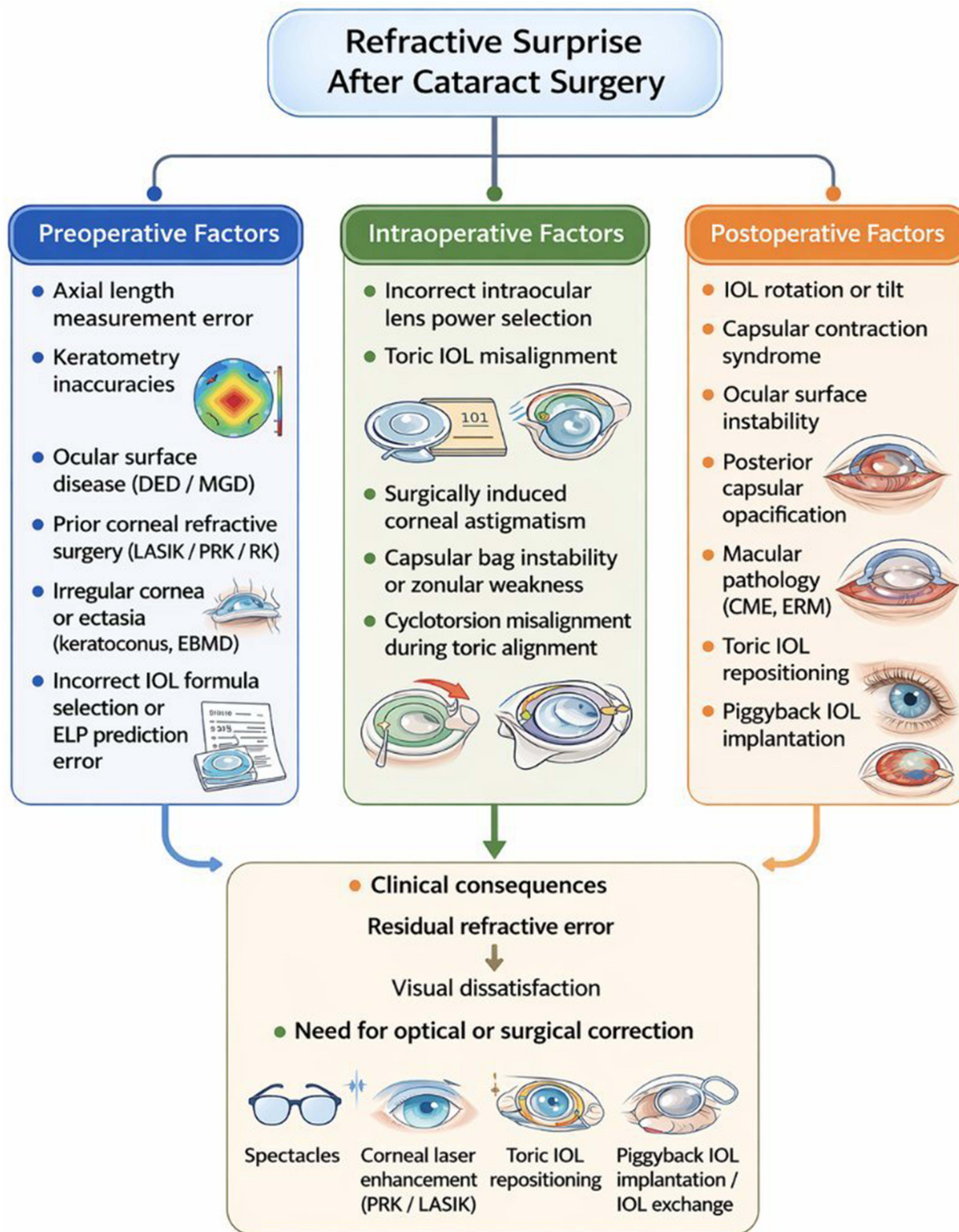


Figure 1 Etiological spectrum of refractive surprises after cataract surgery. The diagram categorizes causes into preoperative, intraoperative, and postoperative factors including biometric errors, toric IOL misalignment, capsular changes, and macular pathology.

Table 1 Depict the Etiology of Refractive Surprises-Causes, Mechanisms, and Clinical Clues

S. No	Category	Specific Cause	Mechanism	Clinical Clues
1	Preoperative	Axial length error	Incorrect AL → incorrect IOL power	Large deviations in both eyes; long/short eye outliers
		Keratometry error	Tear instability, EBMD, MGD	Variable astigmatism across devices
		Formula limitations	Incorrect ELP prediction	Outliers in long/short eyes, post-LASIK
		Prior LASIK/PRK	Altered anterior/posterior corneal ratio	Systematic hyperopic errors
		Irregular cornea	Invalid K values	Topography asymmetry
2	Intraoperative	Toric misalignment	Rotation reduces astigmatic correction	Oblique residual cylinder
		Incorrect IOL selection	Transcription/labeling error	Unexpected >1.0 D error
		Capsular instability	Variable ELP	Myopic or hyperopic shift
		Wound astigmatism	Incision-induced K change	Unexpected axis shift
3	Postoperative	IOL tilt/rotation	Altered power performance	Decreased vision despite correct refraction
		Capsular contraction	Late ELP shifts	Progressive refractive change
		Ocular surface disease	Fluctuating K, unstable refraction	Symptoms worsen during exam
		Macular pathology	Reduced vision despite clear optics	Abnormal OCT

remains a key determinant of refractive accuracy and an ongoing area for clinical refinement and technological improvement.⁴⁷ Kane et al evaluated the performance of contemporary intraocular lens (IOL) power calculation formulas and demonstrated that, despite significant improvements with modern fourth- and fifth-generation formulas, prediction of the effective lens position (ELP) remains a major determinant of refractive accuracy following cataract surgery. Their study showed that formulas incorporating multiple biometric variables—such as the Kane formula and Barrett Universal II—improve refractive predictability compared with earlier formulas; however, errors in ELP estimation continue to contribute to postoperative refractive deviation, particularly in eyes with extreme axial lengths or atypical ocular anatomy.⁴⁸

Ocular Surface Disease & Tear Film Instability

Dry eye disease profoundly alters keratometry readings. Even brief tear film breakup produces fluctuating K values and inconsistent astigmatism. Failure to optimize the ocular surface preoperatively can create false biometric inputs that directly translate into postoperative refractive error.⁴⁹ Yang et al demonstrated that dry eye disease significantly affects the reliability and reproducibility of keratometry measurements used for intraocular lens (IOL) power calculation in cataract surgery planning. In their clinical study, eyes with tear film instability showed greater variability in corneal curvature measurements compared with normal eyes, indicating that ocular surface disease can introduce substantial measurement error and potentially lead to postoperative refractive inaccuracies.⁵⁰ Similarly, Hiraoka et al reported that an unstable or irregular tear film can induce optical aberrations and reduce the repeatability of corneal power measurements, thereby compromising the accuracy of biometric inputs used for IOL calculations. These findings emphasize that the tear film forms the primary refractive interface of the eye, and even minor instability can alter keratometric values and astigmatic measurements. Consequently, failure to recognize and treat ocular surface disease before biometry may lead to inaccurate corneal measurements and ultimately translate into postoperative refractive surprise.⁵¹

Prior Refractive Surgery

LASIK and PRK modify anterior curvature without proportionally affecting posterior curvature, breaking the assumed anterior/posterior corneal relationship required by standard formulas. These eyes are among the highest risk for refractive surprises, particularly hyperopic shifts following myopic LASIK. Jaime Aramberri first highlighted that conventional intraocular lens (IOL) power calculation formulas become unreliable in eyes with previous corneal refractive surgery

because procedures such as LASIK and PRK alter the anterior corneal curvature without proportionally changing the posterior corneal surface. This disruption of the normal anterior–posterior corneal relationship leads to systematic errors in keratometric estimation of corneal power, often resulting in hyperopic refractive surprises following cataract surgery in post-myopic LASIK eyes.⁵² Similarly, Wang et al demonstrated that standard keratometry-based formulas frequently underestimate the true corneal power in post-refractive eyes, thereby producing inaccurate effective lens position assumptions and significant postoperative refractive error. Their work emphasized the importance of using specialized post-refractive IOL calculation methods to improve refractive predictability in these complex cases. Collectively, these studies confirm that eyes with prior corneal refractive surgery represent one of the highest-risk groups for refractive surprises after cataract surgery due to altered corneal biomechanics and disrupted biometric assumptions.⁵³

Unrecognized Irregular Astigmatism

Subclinical keratoconus, pellucid marginal degeneration, epithelial basement membrane dystrophy (EBMD), and other ectasias lead to irregular topography that invalidates both K readings and standard toric calculations. Rabinowitz et al demonstrated that early or subclinical keratoconus can significantly alter corneal curvature measurements and produce irregular astigmatism that is not always evident on routine examination but becomes detectable through corneal topography and tomography. Such irregular corneal patterns compromise the reliability of keratometric readings and may lead to inaccurate intraocular lens (IOL) power calculations or inappropriate toric IOL planning.⁵⁴ Similarly, Belin and Ambrósio emphasized that subtle or subclinical corneal ectasia may not be evident on routine keratometry but can be detected using advanced corneal tomography and elevation-based screening methods. Failure to identify these irregular corneal patterns before cataract surgery can lead to inaccurate corneal power estimation and unpredictable refractive outcomes. Collectively, these studies highlight the importance of careful preoperative screening for corneal ectasia and irregular astigmatism using modern imaging modalities to reduce the risk of postoperative refractive surprise.⁵⁵

Posterior Corneal Astigmatism and Total Corneal Power

Failure to account for posterior corneal astigmatism can lead to systematic over-/under-correction of astigmatism (particularly with toric IOL planning), motivating the use of tomography or formulas/calculators incorporating posterior corneal power. Koch et al demonstrated that posterior corneal astigmatism contributes significantly to total corneal astigmatism and that neglecting its effect during toric intraocular lens (IOL) planning can lead to systematic over-correction of with-the-rule astigmatism and undercorrection of against-the-rule astigmatism. Their findings highlighted the importance of incorporating posterior corneal curvature measurements through corneal tomography or using IOL calculation formulas that account for posterior corneal power to improve refractive accuracy in cataract surgery.⁴⁵

Intraoperative Causes

Incorrect IOL Selection or Labelling Errors

Although rare, transcription errors, wrong biometry entry, or IOL box mislabelling remain recognized contributors to refractive surprises. Automation and cross-checking workflows reduce such events but cannot eliminate them entirely. Gale et al reported that a proportion of postoperative refractive errors in cataract surgery arise from preventable system-related factors such as incorrect intraocular lens (IOL) selection, transcription mistakes in biometry data, or documentation errors during surgical planning. Although such events are relatively uncommon, they remain recognized causes of significant refractive surprise and highlight the importance of standardized verification protocols and audit systems in cataract surgery pathways.¹³ Similarly, Lundström et al demonstrated through the European Registry of Quality Outcomes for Cataract and Refractive Surgery (EUREQUO) that variations in surgical processes—including data entry errors or incorrect IOL choice—can contribute to unexpected postoperative refractive outcomes, reinforcing the need for automated checks and structured surgical workflows to minimize avoidable mistakes.³⁸

Toric IOL Misalignment and Early Rotation

Every degree of toric misalignment reduces astigmatic correction by $\sim 3.3\%$, and rotation $\geq 10^\circ$ becomes clinically significant. Common causes include inadequate marking, cyclotorsion uncorrected before insertion, loose capsular bags, and postoperative rotation due to delayed fibrosis. Koch et al demonstrated that the refractive effectiveness of toric intraocular lenses (IOLs) is highly dependent on precise rotational alignment within the capsular bag. Their analysis showed that each degree of toric IOL misalignment results in approximately 3.3% loss of cylindrical correction, meaning that rotation of 10° can reduce the astigmatic correction by nearly one-third, and larger rotations may negate the intended toric effect entirely.⁴⁵ Similarly, Chang et al reported that postoperative toric IOL rotation may occur due to factors such as inaccurate preoperative axis marking, uncorrected intraoperative cyclotorsion, large or unstable capsular bags, and delayed capsular fibrosis, all of which can contribute to residual postoperative astigmatism and refractive surprise. These findings emphasize the importance of accurate axis marking, intraoperative alignment verification, and early postoperative monitoring to ensure stable toric IOL positioning (Figure 2).⁵⁶

Capsular Instability & ELP Variability

Capsular weakness (pseudo exfoliation, trauma) or zonular compromise alters the predicted ELP. A more anterior ELP yields a myopic surprise; a posterior shift yields a hyperopic surprise. Small variances accumulate—another illustration of the error budget concept. Olsen et al demonstrated that accurate prediction of the effective lens position (ELP) is one of the most critical determinants of refractive accuracy following cataract surgery. Variations in capsular bag behavior, particularly in eyes with pseudoexfoliation syndrome, zonular weakness, or prior ocular trauma, can alter the final postoperative IOL position and lead to refractive deviations from the intended target. Because most IOL calculation

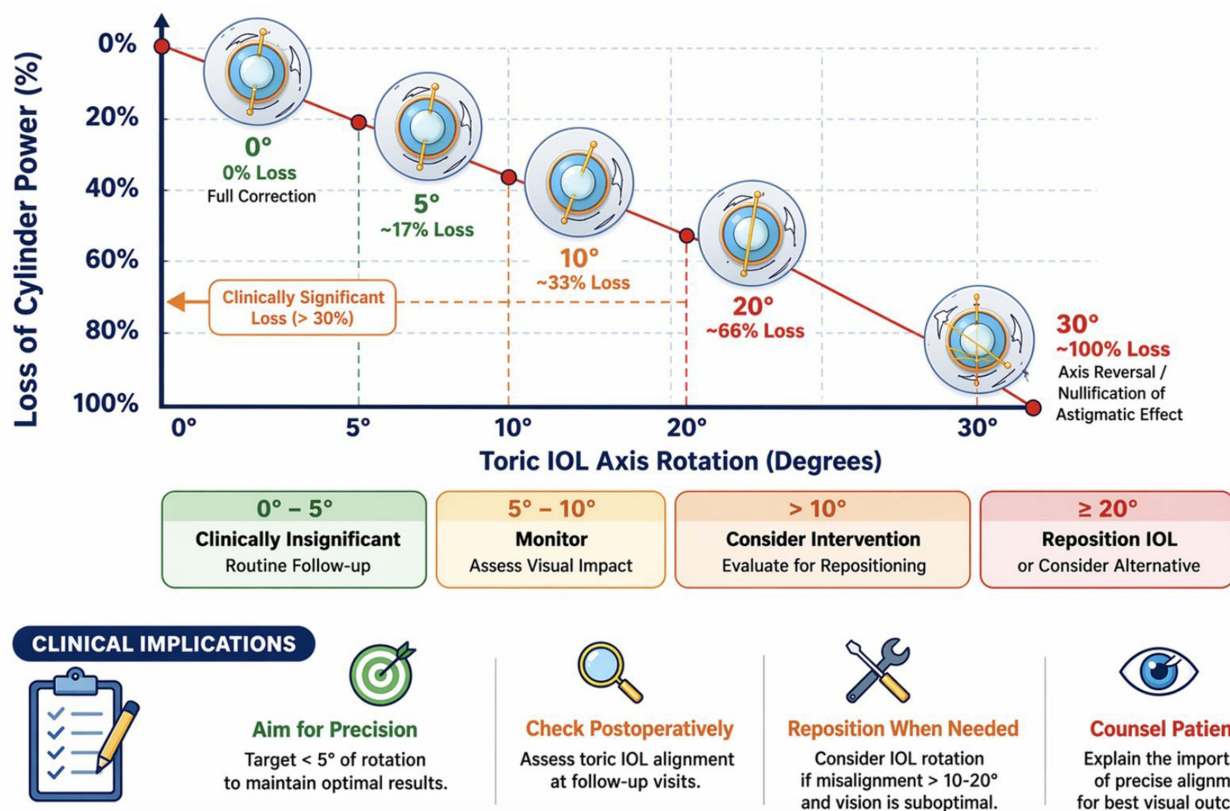


Figure 2 Impact of toric intraocular lens misalignment on astigmatic correction. The graph demonstrates progressive loss of astigmatic correction with increasing toric IOL rotation from its intended axis.

formulas estimate ELP based on preoperative biometric parameters rather than the true postoperative position, structural instability of the capsular bag may result in anterior or posterior displacement of the IOL optic.⁴⁴

Surgical Wound-Induced Astigmatism (SIA) and Axis Errors

Incision size, placement, architecture, and hydration can induce new astigmatism or modify pre-existing patterns. Even modern 2.2–2.4 mm wounds can subtly change postoperative K values. Masket et al reported that surgically induced astigmatism (SIA) remains an important contributor to postoperative refractive outcomes even with contemporary small-incision cataract surgery. Their studies demonstrated that factors such as incision location, size, architecture, and hydration can alter corneal biomechanics and induce measurable changes in corneal curvature.⁵⁷

Postoperative Causes

IOL Rotation or Tilt

Toric IOL rotation remains a leading cause of postoperative cylinder. Multifocal lenses are particularly sensitive to tilt or decentration, causing visual disturbances even when refractive metrics appear acceptable. Holladay et al emphasized that multifocal and other premium IOLs are particularly sensitive to tilt or decentration within the capsular bag. Optical modeling and clinical observations indicate that even small degrees of IOL tilt or decentration can induce higher-order aberrations, glare, and halos, leading to patient dissatisfaction despite apparently acceptable refractive measurements. These findings highlight the importance of maintaining stable IOL positioning and careful postoperative assessment to ensure optimal visual performance with both toric and multifocal IOL designs.⁵⁸

Late Effective Lens Position Shifts

Progressive capsular contraction syndrome may posteriorly displace or tilt the IOL. Conversely, early postoperative movement or lens instability in large bags may cause forward shifts, altering refractive power weeks after surgery. JA Davison first described capsular contraction syndrome as a postoperative phenomenon characterized by progressive fibrosis and shrinkage of the capsular bag, which can lead to intraocular lens (IOL) displacement, tilt, or decentration. Such capsular bag contraction may alter the effective lens position (ELP) and produce refractive shifts even months after otherwise uncomplicated cataract surgery.⁵⁹ Similarly, Hayashi et al reported that changes in capsular bag configuration and zonular tension can influence the stability and position of the implanted IOL, particularly in eyes with large capsular bags or weakened zonules. These positional changes may cause either anterior or posterior displacement of the IOL optic, leading to myopic or hyperopic refractive shifts respectively. Together, these findings demonstrate that postoperative capsular dynamics can significantly influence refractive stability and represent an important cause of delayed refractive surprise after cataract surgery.⁶⁰

Progressive Corneal or Macular Pathology

Unrecognized macular edema, epiretinal membrane, or initial keratoconus progression may mimic refractive error or degrade quality of vision, leading to misinterpretation as a “surprise.” Conceicao Lobo et al reported that pseudophakic cystoid macular edema (PCME) remains one of the most common causes of reduced visual quality following otherwise uncomplicated cataract surgery, and it may mimic residual refractive error by causing blurred vision and decreased contrast sensitivity despite apparently acceptable refractive outcomes.⁶¹ Similarly, Yonekawa and Kim emphasized that postoperative macular conditions such as cystoid macular edema or epiretinal membrane can significantly impair visual acuity and contrast perception, often leading clinicians to initially suspect refractive error when the underlying cause is retinal pathology. In addition, progressive corneal ectatic disorders such as keratoconus may alter corneal curvature over time, producing irregular astigmatism and visual distortion that can be misinterpreted as refractive surprise if careful corneal imaging is not performed. Collectively, these studies highlight the importance of thorough posterior segment evaluation and corneal assessment in patients with unexpected visual symptoms after cataract surgery to differentiate true refractive error from structural ocular disease.⁶²

Dry Eye & Ocular Surface Disturbance

Postoperative inflammation, preservatives, and drops frequently destabilize the tear film, creating fluctuating refractions or pseudo-astigmatism. Similarly, Kim et al demonstrated that tear-film instability following cataract surgery can significantly affect visual quality and refractive stability, emphasizing the importance of ocular surface optimization when evaluating unexpected visual outcomes.⁶³

Capsular Block Syndrome and Anterior Capsular Contraction

Late capsular block can shift the IOL forward, causing a myopic shift and often responds to Nd:YAG capsulotomy; anterior capsular contraction can induce IOL tilt, astigmatism and late refractive change. Miyake et al described capsular block syndrome, a condition in which fluid accumulation behind the intraocular lens (IOL) causes anterior displacement of the optic and results in a myopic refractive shift that often resolves after Nd:YAG laser posterior capsulotomy.⁶⁴ In addition, Davison et al reported that anterior capsular contraction syndrome may produce progressive capsular fibrosis and shrinkage, leading to IOL tilt or decentration with consequent astigmatism and delayed refractive changes. Together, these studies highlight that postoperative ocular surface instability and capsular bag dynamics are important contributors to fluctuating or delayed refractive outcomes following cataract surgery.⁵⁹

Posterior Capsular Opacification And Nd:YAG Effects

Posterior capsule opacification can reduce vision despite stable refraction; Nd:YAG capsulotomy may (in some cases) relate to changes in toric rotational stability, and should be considered in toric eyes with late change. Raj et al noted that posterior capsule opacification (PCO) is the most common late postoperative cause of reduced visual quality after cataract surgery and can significantly impair high- and low-contrast acuity even when the refractive state itself is relatively unchanged.⁶⁵ With respect to Nd:YAG capsulotomy, Cinar et al reported that in toric IOL eyes, capsulotomy may induce measurable toric IOL rotation, tilt, and decentration, with consequent change in cylindrical correction, although the average effect in their series was small. These findings support the view that PCO should be considered in patients with late visual decline despite apparently stable refraction, and that Nd:YAG capsulotomy in toric eyes should be undertaken with awareness of possible postoperative rotational change.⁶⁶

IOL Exchange as an Endpoint Marker of Severe Problems

IOL exchange is uncommon but clinically important; an 8-year cohort reported an incidence of approximately 2 per 1,000 surgeries, strongly associated with adverse surgical events and pre-existing ocular comorbidity. Greenberg et al reported that intraocular lens (IOL) exchange is an uncommon but clinically significant postoperative event that usually reflects severe refractive error, lens-related complications, or visual dissatisfaction following cataract surgery. In a large retrospective cohort study with long-term follow-up, the incidence of IOL exchange was approximately 2 per 1,000 cataract surgeries, highlighting its rarity but also its importance as a marker of complex postoperative problems. The study further demonstrated that IOL exchange was strongly associated with intraoperative complications, such as posterior capsular rupture, as well as pre-existing ocular comorbidities including pseudoexfoliation and prior ocular surgery. These findings emphasize that although most refractive surprises can be managed conservatively or with refractive enhancement procedures, a small subset of patients ultimately require IOL exchange to restore visual function.⁶⁷

Patient-Specific Anatomical and Systemic Contributors

Factors that increase refractive unpredictability include: extreme axial length, irregular cornea/ectasia, prior refractive surgery, pseudoexfoliation (capsular contraction/dislocation risk), thyroid eye disease, and post-vitrectomy eyes (where lens position and formula performance may differ). Olsen et al emphasized that patient-specific anatomical factors remain important determinants of refractive predictability in cataract surgery, particularly in eyes with extreme axial lengths where intraocular lens (IOL) power calculation formulas demonstrate reduced accuracy and increased prediction error.⁴⁴ Similarly, Wang and Koch et al reported that irregular corneal morphology, previous corneal refractive surgery, and ectatic disorders significantly disrupt the normal relationship between corneal power and axial length, thereby increasing

the risk of postoperative refractive surprise.⁵³ In addition, Hayashi et al demonstrated that pseudoexfoliation syndrome may compromise zonular stability and capsular bag behavior, increasing the likelihood of postoperative intraocular lens decentration or displacement. Other systemic or ocular conditions, such as thyroid eye disease and prior pars plana vitrectomy, have also been associated with altered ocular biomechanics and differences in effective lens position, which can affect formula performance and refractive outcomes.⁶⁰

Identification of Refractive Surprises in Optometric Practice

Stepwise Optometric Assessment

The accurate identification of refractive surprises following cataract surgery requires a deliberate, stepwise diagnostic framework that integrates clinical history, targeted examination techniques, and advanced imaging modalities. Optometrists frequently serve as the first point of postoperative evaluation; therefore, a meticulous and methodical approach is essential to differentiate between expected early fluctuations, modifiable optical factors, and true refractive errors requiring surgical or procedural intervention (Table 2).¹⁰ Charlesworth et al emphasized that postoperative refractive management after cataract surgery benefits from a structured optometric approach that begins with confirmation of the intended refractive target and proceeds through systematic assessment of refraction, ocular surface status, and the source of residual visual symptoms. Their Delphi-based recommendations highlighted the importance of consistent target-refraction discussions, careful postoperative refractive evaluation, and clear pathways for determining when optical correction is appropriate versus when further surgical review is required.⁶⁸ Similarly, Saigal et al noted that optometrists play an increasingly important role in cataract co-management, particularly during postoperative care, where careful refraction, slit-lamp biomicroscopy, and timely recognition of unexpected findings help distinguish benign postoperative variability from clinically meaningful refractive error or surgical complications.⁸ Complementing this, Aristodemou et al showed that robust evaluation of postoperative refractive outcomes is essential for detecting outliers and identifying cases that warrant further investigation, reinforcing the need for a deliberate, stepwise framework in routine practice. Collectively, these studies support the view that optometrists are often the first and most critical point of postoperative assessment, and that a methodical diagnostic strategy is central to identifying true refractive surprise and guiding appropriate management.⁶⁹

Table 2 Depicts the Common Refractive Surprise Patterns for Optometric Clues and Next Diagnostic Steps

S. No	Presentation	Likely Underlying Issue(s)	Key Optometric Clues	Priority Tests / Actions
1	Unexpected hyperopia (distance blur; poor near)	Post-myopic LASIK biometry error; ELP estimation error; wrong IOL power; posterior shift	History of LASIK/PRK; flat Ks; "hyperopic surprise" pattern	Topography/tomography; confirm target refraction; liaise with surgeon re formula / post-refractive calculator use
2	Unexpected myopia (distance blur; better near than expected)	Capsular block (forward IOL shift); wrong IOL power; early corneal oedema/wound effects	Myopic shift after initial good vision; shallow AC; early postop timing	Slit-lamp for capsular block; urgent referral if suspected; YAG may be indicated by surgeon
3	High residual cylinder / ghosting after toric IOL	Toric misalignment/rotation; posterior corneal astigmatism errors; irregular cornea	Toric marks off-axis; axis instability; symptoms within days–weeks	Check toric axis; topography; urgent referral if misalignment likely (>~10° or large cylinder)
4	Fluctuating refraction and variable VA	DED / tear film instability; MGD; epithelial irregularity	Variable acuity, "good and bad days", staining/MGD	Ocular surface work-up; treat and repeat refraction/keratometry after optimisation
5	Poor VA not explained by refraction ("BCVA limited")	CME, ERM, AMD, glaucoma, optic neuropathy; IOL issues	No meaningful improvement with refraction/pinhole; metamorphopsia	OCT macula; check IOP/optic nerve; refer appropriately
6	Good refraction but dissatisfaction (glare/haloes)	Multifocal/EDOF dysphotopsia; residual ametropia or astigmatism intolerance	Symptoms worse at night; reduced contrast	Confirm residual SE/cylinder; counsel neuroadaptation; communicate with surgeon about options

Comprehensive History and Target Verification

A detailed postoperative history forms the cornerstone for accurate interpretation of refractive outcomes following cataract or refractive lens surgery. Essential components include clarification of the preoperative refractive goal, such as whether the intended target was emmetropia, monovision, near bias, or a deliberately planned mild myopic offset. Careful review of biometric data is also critical, particularly the accuracy of axial length measurements, keratometry readings, and corneal symmetry, as errors in these parameters are among the most common causes of refractive deviation.³⁰ The type and characteristics of the implanted intraocular lens (IOL) must also be considered, including toric lens alignment, selection of multifocal or extended depth of focus (EDOF) lenses, and the use of specialized formulas or IOL designs for post-refractive surgery eyes. In addition, any history of prior ocular surgery—such as LASIK, PRK, radial keratotomy, corneal cross-linking, pterygium excision, or vitrectomy must be documented, as these procedures alter corneal biomechanics and affect the accuracy of biometric assumptions. Finally, intraoperative complications such as posterior capsular rupture, zonular instability, sulcus IOL placement, or the use of capsular tension rings can significantly influence postoperative refractive outcomes. Comprehensive documentation of these factors enables the optometrist to determine whether the observed refractive result aligns with the intended surgical target or represents an early deviation that warrants further evaluation or intervention.¹⁰ Hoffer et al emphasized that accurate interpretation of postoperative refractive outcomes requires careful review of preoperative biometric parameters and the intended refractive target. Errors in axial length measurement, keratometry, or inappropriate formula selection remain among the most common causes of postoperative refractive deviation after cataract surgery.⁷⁰

Postoperative Refraction Strategy

Optometrists should adopt a structured and systematic refraction methodology to accurately identify and characterize postoperative refractive outcomes. Manifest refraction serves as the initial step to detect early spherical or cylindrical discrepancies and provides a baseline assessment of the patient's functional refractive state.³⁹ Cycloplegic refraction is particularly valuable in distinguishing true refractive error from accommodative influences, as it helps unmask accommodative spasm or pseudomyopic shifts, especially in younger pseudophakic patients or in individuals with multifocal intraocular lenses experiencing dysphotopsia. Jackson Cross Cylinder (JCC) refinement is essential for accurately assessing astigmatic components, although clinicians should remain cautious in cases of irregular astigmatism, where endpoints may be unstable or inconsistent. Additionally, fogging techniques play an important role in confirming true hyperopic shifts and preventing over-minus prescriptions. This combined approach of manifest and cycloplegic refraction ensures accurate differentiation between genuine refractive error and variability related to accommodation, tear film instability, or measurement artifacts, thereby supporting appropriate clinical decision-making and optimal postoperative visual outcomes (Figure 3).⁷¹

Slit-Lamp Examination: Clues to Underlying Etiology

A careful anterior segment evaluation often reveals the structural basis of refractive deviation:

Corneal Findings

Careful assessment of corneal findings is essential when evaluating unexpected or suboptimal refractive outcomes. Ocular surface abnormalities such as dry eye disease or epithelial irregularity can lead to fluctuating vision and may result in inaccurate keratometry measurements, thereby contributing to refractive prediction errors. Surgical factors, including incisional astigmatism or poorly constructed or positioned corneal wounds, can induce unexpected cylindrical refractive changes that deviate from the intended outcome.⁷² Additionally, the presence of irregular astigmatism should prompt consideration of underlying causes such as corneal ectasia, prior refractive surgery, or active corneal surface disease. Identifying these corneal factors is critical, as they may represent modifiable contributors to refractive error and can guide appropriate management strategies, including ocular surface optimization, optical correction, or further diagnostic evaluation.⁷³ Nichols et al highlighted that ocular surface disease, particularly dry eye disease, can significantly alter corneal surface regularity and tear-film stability, leading to fluctuating visual acuity and variability in keratometric measurements used in cataract surgery planning

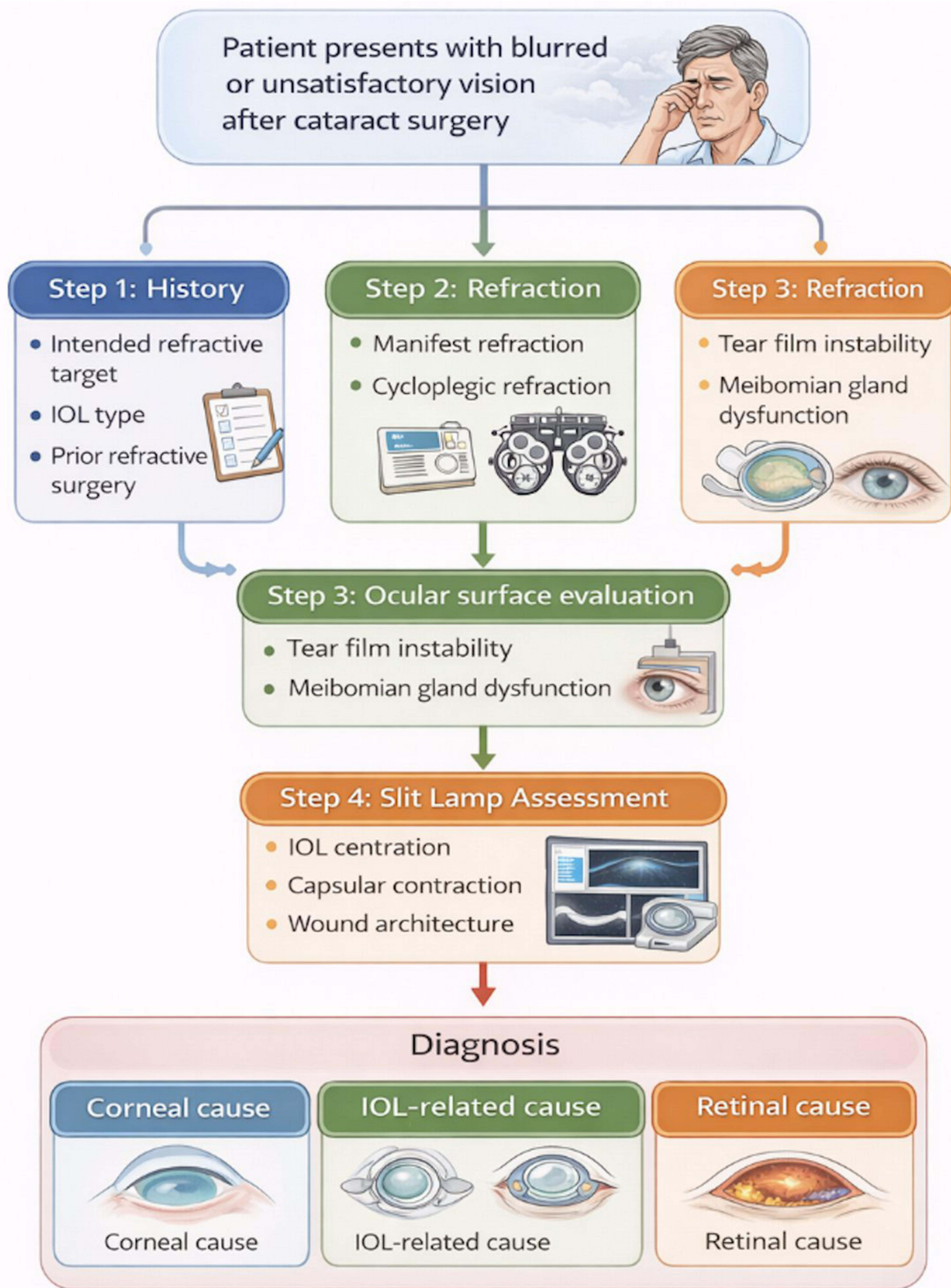


Figure 3 Optometric diagnostic framework for evaluation of refractive surprises. The schematic illustrates a systematic approach beginning with patient history and refraction, followed by ocular surface assessment, slit-lamp examination, and targeted imaging to differentiate corneal, IOL-related, and retinal causes.

and postoperative evaluation.⁷⁴ Similarly, Matossian et al reported that untreated ocular surface abnormalities may introduce measurement errors in corneal curvature and contribute to unexpected refractive outcomes after cataract surgery. In addition to ocular surface disturbances, surgical factors such as wound architecture and incision placement can influence postoperative corneal curvature (Figure 4).⁷⁵

Optical Quality and Surface Evaluation

Assess tear film stability and signs of DED/blepharitis/MGD. Treating visually significant ocular surface disease before repeat biometry is recommended by ASCRS and is supported by evidence that DED affects keratometry and refractive accuracy. Trattler et al reported that ocular surface disease, particularly dry eye disease (DED), is highly prevalent among patients presenting for cataract surgery and may significantly influence keratometric measurements and intraocular lens (IOL) power calculations. Their multicenter study demonstrated that a substantial proportion of patients with otherwise asymptomatic cataracts exhibit signs of tear-film instability that can compromise biometric accuracy.⁷⁶ Similarly, Epitropoulos et al showed that hyperosmolar dry eye can cause significant variability in keratometry measurements, potentially leading to clinically meaningful errors in IOL power selection and postoperative refractive outcomes. Based on such evidence, the American Society of Cataract and Refractive Surgery (ASCRS) clinical algorithm emphasizes the importance of identifying and treating visually significant ocular surface disease prior to performing definitive biometry or repeat measurements. Collectively, these findings support routine assessment of tear-film stability and management of conditions such as blepharitis, meibomian gland dysfunction, and dry eye disease before finalizing refractive calculations to improve postoperative refractive accuracy.⁷⁷

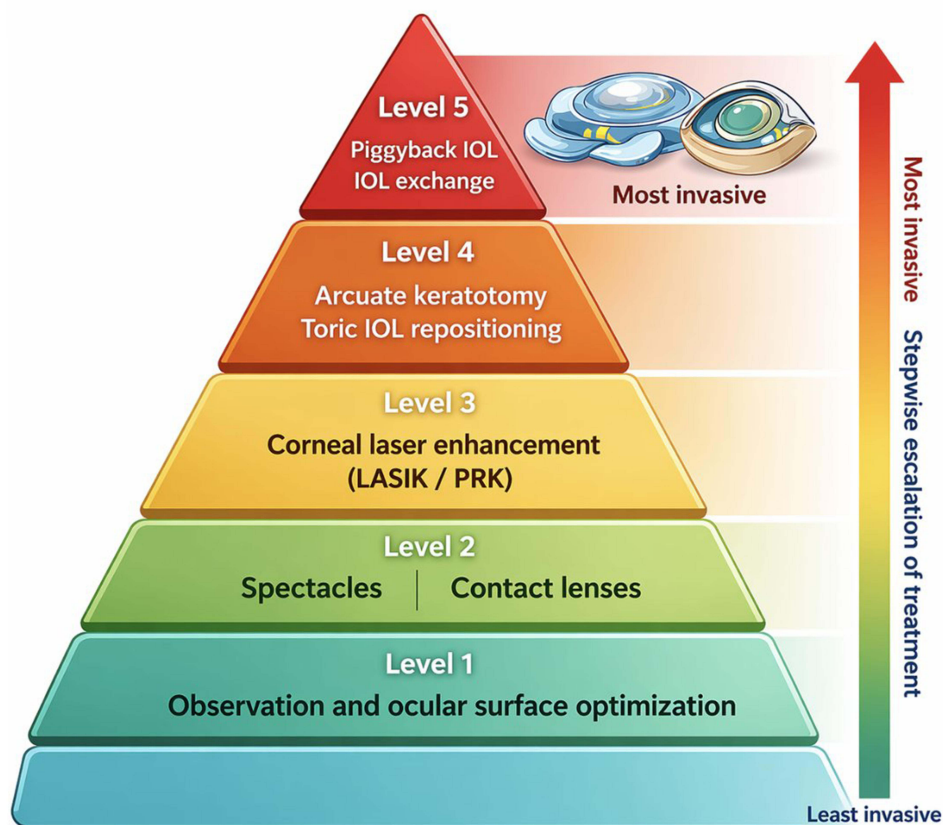


Figure 4 Management spectrum for refractive surprises after cataract surgery. The treatment pyramid illustrates stepwise escalation from observation and optical correction to corneal laser enhancement and intraocular procedures such as toric IOL repositioning, piggyback IOL implantation, or IOL exchange.

Intraocular Lens Clues

Careful evaluation of intraocular lens (IOL) position and stability can provide important clues when investigating unexpected refractive outcomes. Toric IOL misalignment is a well-recognized cause of residual astigmatism, with even 10 degrees of rotational deviation reducing the intended cylindrical correction by approximately 33%, thereby significantly compromising visual outcomes.⁷⁸ IOL tilt or decentration is another important consideration, particularly in eyes implanted with multifocal or aspheric lenses, where optical performance is highly sensitive to precise centration and alignment. Capsular phimosis, resulting from excessive contraction of a small capsulorhexis, may exert mechanical forces on the IOL optic, altering its effective lens position (ELP) and leading to refractive shifts.⁷⁹ Similarly, unintended sulcus placement of the IOL, whether due to intraoperative complications or surgical decision-making, can result in anterior or posterior displacement of the optic, producing hyperopic or myopic refractive surprises, respectively. Recognizing these anatomical and positional factors is essential for accurate diagnosis and guiding appropriate management, including observation, optical correction, or surgical repositioning where indicated (Table 3).⁸⁰

Posterior Segment Indicators

Evaluation of the posterior segment is an essential component in the assessment of unexpected visual symptoms following cataract or refractive lens surgery, as underlying retinal pathology may mimic or contribute to apparent refractive error. Macular abnormalities such as epiretinal membrane (ERM) or cystoid macular edema (CME) can reduce visual acuity and contrast sensitivity, creating the impression of residual refractive blur despite accurate refractive correction.⁸¹ Similarly, vitreous opacities may lead to symptoms such as monocular diplopia, ghosting, or visual distortion, which may be misinterpreted as refractive in origin. Identifying these posterior segment causes is critical, as they require retinal evaluation and management rather than refractive intervention, ensuring accurate diagnosis and appropriate treatment planning. These findings help categorize refractive surprises into corneal, lenticular (IOL), or retinal causes.⁸² Henderson et al reported that posterior segment pathology is an important cause of suboptimal visual outcomes following cataract surgery, even when refractive targets are accurately achieved. In particular, conditions such as cystoid macular edema (CME) remain among the most common causes of reduced postoperative visual acuity and contrast sensitivity. Similarly, epiretinal membrane (ERM) can produce metamorphopsia and blurred vision that may be mistaken for residual refractive error.⁸³

Imaging-Based Diagnostic Enhancement

Advanced imaging technologies have become indispensable for accurate characterization of refractive surprises.

Corneal Topography/Tomography

Corneal topography and tomography play a critical role in the evaluation of unexpected refractive outcomes by providing detailed analysis of corneal shape and optical quality. These imaging modalities are essential for detecting irregular astigmatism, keratoconic patterns, post-LASIK ectasia, and subtle corneal decentration that may not be evident on routine examination. In addition, tomography provides valuable information on posterior corneal curvature, which is particularly important for verifying the accuracy and performance of toric intraocular lenses (IOLs), as anterior keratometry alone may

Table 3 Depict the Impact of Toric IOL Rotation on Cylinder Correction

S. No	Rotation (Degrees)	Loss of Cylinder Correction (%)
1	5°	17%
2	10°	33%
3	20°	66%
4	30°	100%

underestimate total corneal astigmatism.⁸⁴ Corneal imaging can also reveal artefacts caused by tear-film instability, which may lead to unreliable biometric measurements and inaccurate IOL calculations. Identifying such ocular surface-related distortions allows clinicians to optimize the tear film and corneal surface before considering refractive enhancement or recalculation of IOL power, thereby improving the accuracy of subsequent refractive interventions.¹¹

Optical Coherence Tomography (OCT)

Optical coherence tomography (OCT) is an indispensable diagnostic tool in the evaluation of suboptimal visual outcomes following cataract or refractive lens surgery, as it enables high-resolution assessment of retinal and optic nerve structures. Macular OCT is particularly valuable for identifying subtle pathologies such as epiretinal membrane (ERM), cystoid macular edema (CME), subretinal fluid, or drusen, all of which can impair visual acuity and contrast sensitivity and may be mistakenly attributed to refractive error. In addition, retinal nerve fiber layer (RNFL) OCT allows detection of pre-existing or early optic neuropathy, such as glaucomatous damage or other optic nerve disorders, which may not be clinically evident during routine examination. Recognizing these structural abnormalities is essential for distinguishing true refractive error from retinal or optic nerve-related visual limitation, ensuring appropriate management and avoiding unnecessary refractive intervention.⁸⁵

Anterior Segment OCT

Anterior segment optical coherence tomography (AS-OCT) provides precise, cross-sectional imaging of intraocular lens (IOL) position and surrounding anterior segment structures, making it an invaluable tool in the evaluation of unexpected refractive outcomes. It allows objective confirmation of IOL tilt or decentration, capsular fibrosis, unintended sulcus placement, or the presence of a Soemmerring ring, all of which can alter the effective lens position (ELP) and contribute to refractive error. In addition, AS-OCT enables accurate measurement of the IOL's spatial relationship within the capsular bag, offering a more reliable and quantitative assessment of effective lens position compared with slit-lamp estimation alone. This enhanced visualization helps clinicians distinguish between biometric calculation error and postoperative positional shifts, thereby guiding appropriate management decisions such as observation, optical correction, or surgical intervention.⁸⁶

Scheimpflug Imaging

Scheimpflug imaging provides comprehensive analysis of corneal structure and biomechanics, offering valuable insights when evaluating unexpected refractive outcomes. This modality enables precise quantification of corneal thickness distribution (pachymetry), assessment of corneal curvature, and detection of subtle biomechanical abnormalities that may influence refractive stability. It is particularly useful in identifying postoperative wound-induced astigmatism, irregular corneal shape, or early ectatic changes that may contribute to refractive deviation.⁸⁷ By integrating Scheimpflug imaging with other diagnostic tools such as corneal topography, optical coherence tomography, and clinical refraction, clinicians can more accurately determine whether a refractive surprise originates from optical factors, structural abnormalities, or neural and retinal causes. This comprehensive assessment ensures accurate diagnosis and supports appropriate management strategies, including optical correction, ocular surface optimization, or surgical intervention where necessary. These tools help determine whether a refractive surprise is optical, structural, or neural in origin.⁸⁸

Integration into a Structured Diagnostic Workflow

A streamlined and systematic approach is essential for accurately identifying the cause of refractive deviation and minimizing unnecessary referrals for surgical enhancement. The evaluation should begin by verifying the intended refractive target, including whether the surgical goal was emmetropia, monovision, or a deliberate refractive offset. This should be followed by both manifest and cycloplegic refraction to differentiate true refractive error from accommodative or tear film-related variability.²⁰ Careful assessment of the ocular surface is crucial, as dry eye disease or epithelial irregularity may contribute to fluctuating vision and inaccurate measurements. A detailed slit-lamp examination should then be performed to evaluate wound integrity, intraocular lens (IOL) centration, capsular status, and other anterior segment findings. Advanced imaging modalities such as optical coherence tomography (OCT) and corneal tomography should be used as indicated to assess

macular integrity, IOL position, and corneal structure.⁸⁹ Based on these findings, the source of refractive error should be classified as corneal, IOL-related, or retinal in origin. Corneal causes may include surface irregularity or astigmatic shifts, IOL-related causes may involve lens rotation, tilt, or effective lens position error, and retinal causes may include macular pathology affecting visual clarity. Once the underlying cause is identified, the urgency of referral to the surgeon should be determined, and an appropriate management plan should be developed, whether through optometric correction, ocular surface optimization, or surgical enhancement. Optometrists who follow such structured pathways significantly reduce diagnostic ambiguity and enhance comanagement efficiency. A comprehensive, structured diagnostic workflow—integrating precise refraction techniques, slit-lamp analysis, and multimodal imaging—allows optometrists to accurately identify refractive surprises, minimize misdiagnosis, and expedite appropriate refractive rehabilitation or surgical enhancement.⁹⁰

Postoperative Assessment & Diagnosis

History and Symptom Review

A thorough postoperative history and symptom review is the foundation of diagnosing refractive surprises after cataract surgery. During this phase, the optometrist should explore the patient's subjective visual experience, including complaints such as blur, monocular diplopia, ghosting, glare, halos, and other dysphotopsias that may indicate residual ametropia, IOL misalignment, or early ocular surface compromise.²⁴ The temporal pattern of symptoms—whether constant, intermittent, or task-specific, provides additional diagnostic clues. Equally important is determining whether the patient's current visual function aligns with their preoperative expectations, especially in premium lens patients. Dissatisfaction in multifocal or EDOF IOL users may arise from normal neuroadaptation challenges rather than true refractive error, whereas toric IOL users with fluctuating clarity may be experiencing rotational misalignment.⁹¹ Reviewing preoperative biometry, the intended refractive target, surgical notes, and any history of corneal refractive surgery or ocular pathology further contextualizes the presenting symptoms. This historical framework helps differentiate between symptoms arising from residual refractive error, optical aberrations, ocular surface disease, or macular pathology, ensuring that subsequent diagnostic steps are accurately directed.⁹²

Clinical Examination

The clinical examination phase integrates objective and imaging-based assessments to identify the underlying cause of unexpected refractive outcomes. A precise manifest refraction is essential for quantifying spherical and cylindrical errors and should be complemented by cycloplegic refraction when accommodative factors or pseudomyopic shifts are suspected. Keratometry and corneal tomography provide valuable information about corneal curvature, incisional astigmatism, posterior corneal elevation, and irregular astigmatism findings that may point toward corneal surface disease, ectasia, or post-refractive surgery abnormalities.³⁹ Slit-lamp evaluation allows detailed observation of the anterior segment, including corneal clarity, ocular surface integrity, wound healing patterns, and the position and centration of the intraocular lens within the capsular bag. Signs such as toric IOL off-axis rotation, capsular phimosis, zonular laxity, or optic tilt may explain unexpected refractive shifts.⁹³ Anterior segment OCT enhances this assessment by providing high-resolution imaging of IOL tilt, decentration, capsular bag configuration, and sulcus placement features that cannot be fully appreciated clinically. Concurrently, macular OCT is indispensable for ruling out epiretinal membranes, cystoid macular edema, or other macular pathologies that may present as blurred or distorted vision rather than true refractive error. Together, these examination components establish whether the refractive surprise arises from corneal, lenticular, or retinal origins and direct appropriate management.⁹⁴

Determining Refractive Stability

Determining the stability of refractive measurements is critical before initiating any corrective intervention. Early postoperative refractive values may fluctuate due to ocular surface instability, corneal edema, residual inflammation, variable incision healing, or ongoing capsular bag dynamics affecting the effective lens position. In most uncomplicated pseudophakic cases, refractive measurements stabilize by 4–6 weeks, but this period may extend in multifocal, toric, or post-refractive surgery patients, where neuroadaptation or slow capsular contraction may influence clarity and comfort.⁹⁵

Repeat refractions and serial keratometry or tomography are essential to confirm whether residual error is stable, progressive, or fluctuating. Clinicians must also recognize circumstances in which intervention is inappropriate—for example, persistent dry eye, unaddressed meibomian gland dysfunction, unstable corneal topography, active inflammation, or unresolved macular edema. Premature enhancement, whether optical or surgical, may worsen visual outcomes if the underlying cause has not been stabilized. By carefully evaluating refractive stability, clinicians can determine the optimal timing for intervention, prevent unnecessary procedures, and ensure that any enhancement—spectacle-based, corneal-based, or intraocular is performed under the most favourable conditions.⁹⁶

Management Strategies

The management of refractive surprises after cataract surgery requires a tailored, etiology-driven approach that integrates optical, corneal, and intraocular solutions while balancing patient expectations and visual priorities. Non-surgical management remains the initial and often most practical strategy for low-magnitude or early postoperative refractive deviations.⁹⁷ Prescription eyeglasses can effectively correct small residual spherical or cylindrical errors, while specialty contact lenses—particularly rigid gas-permeable or scleral lenses—offer superior optical quality for patients with irregular astigmatism, ocular surface disease, or post-refractive corneas. Optimizing the tear film is essential because ocular surface instability can mimic refractive error and degrade visual quality; therefore, lubricants, lid hygiene, anti-inflammatory therapy, and punctal occlusion play important adjunctive roles.⁹⁸ Patient counseling is equally important, especially in premium IOL recipients, where even small deviations from target can result in disproportionate dissatisfaction. Clear communication regarding adaptation, timelines for refractive stabilization, and available enhancement options helps align expectations and strengthen comanagement plans. When optical correction is insufficient or when patients desire spectacle independence, corneal refractive surgery becomes a powerful enhancement tool.⁹⁹ PRK and LASIK can reliably correct residual ametropia once refraction has stabilized, typically after 6–12 weeks. These procedures are particularly effective in monofocal IOL recipients with stable corneal topography and adequate pachymetry. However, PRK is generally preferred in patients with multifocal or EDOF IOLs to minimize risks of flap-related complications and postoperative dry eye, both of which could worsen dysphotopsias. Contraindications such as epithelial basement membrane dystrophy, forme fruste keratoconus, or uncontrolled dry eye must be carefully ruled out preoperatively.¹⁰⁰ For premium IOL patients—especially those with multifocal optics—the threshold for refractive accuracy is tighter, and enhancement is often essential to achieving high-quality distance and near vision. In cases where the refractive surprise results from an intraocular lens–related issue, intraocular solutions provide targeted correction. Piggyback IOLs placed in the sulcus offer reversible and predictable correction of significant residual hyperopia or myopia, especially when capsular stability precludes safe IOL exchange. IOL exchange may be indicated when a substantial biometry-related power mismatch occurs, though it is generally reserved for early postoperative periods when capsular fibrosis is minimal.¹⁰¹ Toric IOL misalignment remains a common cause of residual astigmatism, and realignment procedures can restore the intended cylindrical effect if performed promptly; each degree of misalignment results in approximately 3.3% loss of toric correction, making early identification crucial. For residual regular astigmatism, arcuate keratotomy—either manual or femtosecond-assisted—can refine corneal cylinder with high accuracy, particularly in patients who are not ideal candidates for excimer laser enhancement. Light-adjustable lenses (LAL) offer an advanced solution where postoperative titration of refractive power is possible, providing unparalleled precision in complex or post-refractive cases (Table 3).¹⁰²

A structured management algorithm enables optometrists and surgeons to make consistent, evidence-based decisions. Low-magnitude errors and unstable refractions warrant conservative optical correction and ocular surface optimization, while stable moderate errors may benefit from corneal refractive surgery. Significant spherical deviations, IOL malposition, or toric rotation require intraocular solutions, with final selection guided by capsular bag status, IOL type, timing from surgery, and patient expectations.¹⁰³ Through this systematic process, clinicians can match the therapeutic intervention to the magnitude and origin of the refractive error, ensuring a safe, efficient, and patient-centered resolution of postoperative refractive surprises. Management of refractive deviation following cataract or refractive lens surgery is best approached in a structured, tiered manner that prioritizes reversible causes and minimizes unnecessary surgical intervention. The initial step involves identifying and optimizing missed reversible factors, such as ocular surface disease, posterior capsular opacification (PCO), or early intraocular lens (IOL) positional instability, all of which can contribute to transient or correctable refractive error. Once reversible causes have been addressed, the next step is to provide functional

visual correction through spectacles or contact lenses, which may offer effective and non-invasive visual rehabilitation, particularly in cases where surgical intervention is not immediately indicated or desired. Finally, enhancement procedures—such as laser refractive correction, IOL rotation, piggyback IOL implantation, or IOL exchange—should be considered only when the refractive error has stabilized and the underlying cause is clearly identified and amenable to surgical correction. This tiered approach ensures that management is both evidence-based and patient-centered, reducing unnecessary interventions while optimizing visual outcomes.³⁹

Non-Surgical Management in Optometric Practice

Spectacle Correction

For many monofocal IOL patients, spectacles provide rapid resolution and remain the most accessible option, particularly where surgical enhancement is not readily available. When a patient has a planned myopic target or monovision, “surprise” may reflect misunderstanding of intended outcome; reframing expectations and prescribing task-specific spectacles may be sufficient.³⁹ Lundström et al demonstrated that a proportion of postoperative patients continue to experience residual refractive error despite otherwise successful surgery, and optical correction remains an effective and practical solution in routine clinical practice. In many cases, spectacles provide rapid visual rehabilitation and are especially valuable in settings where surgical enhancement procedures such as laser vision correction or IOL exchange are not readily available.¹² In addition, when cataract surgery is intentionally planned with a myopic target or monovision strategy, postoperative visual dissatisfaction may arise from misunderstanding of the intended refractive goal rather than a true refractive error. Studies evaluating patient satisfaction after cataract surgery emphasize the importance of patient counseling and expectation management in such scenarios. Therefore, careful refraction, clarification of the original refractive target, and the prescription of task-specific spectacles for distance, near, or intermediate vision often represent an appropriate first-line management approach before considering further surgical intervention.¹⁰⁴

Contact Lenses

Contact lenses can be superior for: irregular corneal astigmatism (RGP/scleral), significant anisometropia, or where spectacle-induced aniseikonia is symptomatic. In post-refractive surgery corneas with irregularity, a diagnostic RGP over-refraction can help attribute visual degradation to corneal optics vs other causes (a point emphasised in post-refractive LAL outcome discussions).¹⁰⁵ Rabinowitz et al and subsequent corneal literature have shown that rigid gas permeable (RGP) lenses can neutralize irregular corneal astigmatism by masking anterior corneal surface irregularities, thereby improving visual quality in conditions such as keratoconus or post-refractive surgery corneas. Similarly, scleral lenses have been increasingly utilized for eyes with irregular corneal topography because the tear reservoir between the lens and cornea creates a smooth optical surface that enhances visual acuity.⁵⁴ Contact lenses are also advantageous in cases of postoperative anisometropia, where spectacles may induce symptomatic aniseikonia or image size disparity. In addition, performing a diagnostic RGP over-refraction can help differentiate corneal optical irregularity from other causes of reduced vision, such as intraocular lens (IOL) tilt, retinal pathology, or posterior capsule changes. This diagnostic strategy is particularly valuable in patients with previous corneal refractive surgery, where irregular corneal optics may contribute to degraded visual quality despite seemingly acceptable refractive metrics.¹⁰⁶

Ocular Surface Optimisation

Treating DED/MGD (lubricants, lid hygiene, anti-inflammatory therapy when indicated, demodex management, etc.) can reduce refraction fluctuation, improve quality of vision and reduce keratometry error when further surgical planning is considered. A systematic review concluded that DED treatment before repeating biometry reduces mean absolute error and improves refractive accuracy.¹⁰⁷ Trattler et al demonstrated that a significant proportion of patients presenting for cataract surgery have previously undiagnosed dry eye disease (DED), which can adversely affect corneal measurements and postoperative visual outcomes. Tear-film instability and meibomian gland dysfunction (MGD) can lead to fluctuating keratometry readings and variable refraction, thereby contributing to apparent refractive surprises. Consequently, treatment strategies such as preservative-free lubricants, lid hygiene, thermal therapies for MGD, anti-inflammatory agents

including topical cyclosporine or lifitegrast, and management of Demodex infestation may help restore tear-film stability and improve optical quality.⁷⁶

Referral for PCO or Capsular Block Syndrome Management

If PCO is the limiting factor, referral for Nd:YAG capsulotomy is appropriate. If capsular block syndrome is suspected with myopic shift, timely referral is important; Nd:YAG can be therapeutic in surgeon care.¹⁰⁸ Raj et al reviewed posterior capsule opacification (PCO) as the most common late complication of cataract surgery and noted that it can reduce visual quality even when the refractive state itself is relatively stable, making it an important non-refractive cause of postoperative visual dissatisfaction.⁶⁵ Elgohary and Dowler et al similarly showed that PCO can impair visual function in both monofocal and multifocal intraocular lens (IOL) eyes, so referral for Nd:YAG capsulotomy is appropriate when capsular opacity is the main limiting factor.¹⁰⁹ In contrast, Kanclerz and Wang et al described capsular block syndrome as a distinct postoperative entity that may present with deterioration in vision and an unexpected myopic shift, and concluded that Nd:YAG posterior capsulotomy is generally the standard and effective treatment in appropriately selected cases. Collectively, these studies support prompt referral when PCO or capsular block syndrome is suspected, as management is typically procedural and surgeon-led rather than optometric.¹¹⁰

Surgical Enhancement Pathways

Optometrists generally do not perform intraocular enhancements, but they are essential in identifying candidates, providing objective measurements (stable refraction/topography/OCT), and ensuring timely referral when early repositioning or exchange is time-sensitive.¹¹¹ Abdelghany et al reviewed the management of residual refractive error after cataract surgery and emphasized that successful surgical enhancement depends on first identifying the underlying cause of the refractive error and selecting the appropriate corrective approach, such as corneal refractive surgery, piggyback IOL implantation, or IOL exchange.¹⁸ Similarly, Sáles et al noted that careful postoperative assessment is essential before enhancement, because stable refraction and accurate characterization of the error determine whether corneal or intraocular correction is most appropriate. These studies support the clinical role of optometrists in documenting stable refraction and identifying patients who require timely surgical referral rather than continued conservative management.¹¹² While most contemporary literature on refractive outcomes after cataract surgery focuses on phacoemulsification, it is important to acknowledge that alternative surgical techniques such as manual small-incision cataract surgery (SICS) and extracapsular cataract extraction (ECCE) continue to be widely practiced, particularly in resource-limited settings.⁷³ These techniques are associated with distinct refractive challenges. In SICS, surgically induced astigmatism (SIA) is often higher and less predictable due to larger, self-sealing scleral incisions, which may lead to greater variability in postoperative refractive outcomes. Similarly, ECCE is associated with even larger incisions, delayed wound healing, and higher degrees of postoperative astigmatism, all of which contribute to increased refractive unpredictability when compared to phacoemulsification. In addition to surgical factors, socioeconomic constraints play a critical role in determining refractive outcomes.⁷⁶ In many settings, patients may not opt for premium intraocular lenses (IOLs), such as toric or multifocal lenses, due to financial limitations. The inability to implant toric IOLs in patients with significant pre-existing corneal astigmatism may result in residual refractive error, even when appropriate indications are present. This highlights that refractive surprise is not solely a consequence of biometric or surgical inaccuracies but may also arise from limitations in access to advanced technologies. Therefore, an unbiased and comprehensive evaluation of refractive surprises must incorporate variability related to surgical technique as well as patient-specific economic considerations. Recognizing these factors is particularly important in developing countries, where a significant proportion of cataract surgeries are performed using non-phacoemulsification techniques and cost constraints influence IOL selection.⁷⁸

Toric Intraocular Lens Repositioning

Large series report repositioning surgery incidence around 0.65% and suggest that timing matters; one ophthalmology cohort concluded repositioning should be performed about 1 week after implantation for best outcomes.¹¹³ A practical optometric indicator for referral is the presence of significant residual astigmatism in eyes implanted with a toric

intraocular lens, particularly when clinical examination suggests meaningful axis misalignment commonly greater than 10° or when the resulting refractive impact exceeds approximately 0.50 diopters. In such cases, early referral to the operating surgeon is advisable. Timely intervention, often within the first few postoperative weeks before capsular fibrosis stabilizes the lens position, may allow effective toric IOL realignment and improved refractive outcomes, as emphasized in studies evaluating toric IOL rotational stability.¹¹⁴

Intraocular Lens Exchange

IOL exchange can correct large spherical surprises or address intolerable presbyopia-correcting IOL dysphotopsia, but risk increases with time as capsular scarring progresses. Exchange is uncommon overall ($\approx 2/1,000$ surgeries in one 8-year cohort) and is strongly associated with surgical adverse events and ocular comorbidity.¹¹⁵

Supplementary Sulcus-Fixated “Add-On” IOLs (Polypseudophakia / DUET)

Contemporary designs (eg Sulcoflex, AddOn, Reverso) were developed to reduce risks seen with older piggyback techniques. A 2025 review summarised that specially designed sulcus-fixated supplementary IOLs reduce complications associated with early “two-in-the-bag” approaches and expand options for correcting residual refractive error and even reversible multifocality. However, optometrists should be aware of potential complications (pigment dispersion, dysphotopsia, IOP rise, decentration/rotation, and—less commonly with modern designs—UGH syndrome/iris chafing).¹¹⁶

Laser Vision Correction (LASIK/PRK)

ASCRS guidance frames corneal laser enhancement as a common approach for residual error because it avoids entering the eye, but it may exacerbate ocular surface disease, has age-related healing considerations, and may be less predictable in post-refractive corneas. The ASCRS report also summarises comparative studies suggesting LASIK may achieve higher predictability for achieving SE within ± 0.50 D than lens-based approaches in some series (while acknowledging evidence limitations).¹¹⁷

Light-Adjustable Lens (LAL) and Emerging Adjustable Platforms

Adjustable IOL technology is increasingly relevant to refractive surprise prevention and management. In eyes with prior corneal refractive surgery, a group at high risk of surprise—second-generation LAL studies report excellent refractive accuracy. A large series of post-refractive eyes reported $\sim 67\%$ within ± 0.25 D and $\sim 87\%$ within ± 0.50 D after adjustment, highlighting the advantage of postoperative adjustability where formula accuracy rarely exceeds $\sim 70\%$ within ± 0.50 D. A separate post-LASIK/PRK series with second-generation LAL reported 97.1% within ± 0.50 D of plano target and illustrates “co-managed” care models where postoperative light treatments occur at separate facilities.¹¹⁸

Counselling and Follow-Up

Effective counselling and structured follow-up are central to the successful management of refractive surprises, as they directly influence patient satisfaction, treatment adherence, and long-term outcomes. Optometrists, who often serve as the primary point of postoperative contact, play a pivotal role in setting realistic expectations and guiding patients through the decision-making process. Early discussions should clarify the nature of refractive variability after cataract surgery, emphasizing that vision may fluctuate during the healing phase and that additional interventions—optical, corneal, or intraocular—may be required to achieve the desired refractive target.¹¹⁹ Patients must be informed about the range of available management options, their associated risks, expected recovery timelines, and the likelihood of achieving spectacle independence, particularly in the context of premium IOL technologies where visual demands are high and tolerance for error is low. Equally important is the documentation of patient concerns, dissatisfaction, or unexpected visual disturbances. A transparent record of subjective symptoms and objective findings creates continuity in comanagement with the surgeon and helps ensure medicolegal robustness should expectations not be immediately met.¹²⁰ Longitudinal follow-up enables the optometrist to monitor refractive stability, ocular surface optimization, and the progression or resolution of dysphotopsias or binocular imbalance. Follow-up visits also provide opportunities for reinforcing education, revisiting expectations as the clinical picture evolves, and reassessing the need for enhancement procedures once refraction stabilizes. Ultimately, thoughtful counselling

combined with structured, empathetic follow-up fosters shared decision-making, enhances patient trust, reduces unnecessary anxiety, and significantly improves postoperative satisfaction, solidifying the optometrist's role as a key partner in the surgical care continuum (Table 4 and Figure 5).¹²¹

Guidelines, Implementation and Interdisciplinary Considerations

Guidance Relevant to Optometric Co-Management

UK Post-Operative Care and Refraction Timing

UK-based practice resources commonly advise a structured post-operative review and sight test at approximately 4 weeks after surgery, with refraction and visual function assessment, and clear pathways for re-referral if outcomes are not as expected.¹²²

ESCRS Guideline for Cataract Surgery

The ESCRS guideline provides explicit definitions of target refraction (including emmetropia and monovision ranges), recommends shared decision-making for target selection, suggests toric IOLs be considered for corneal astigmatism ≥ 1.0

Table 4 Management Options for Refractive Surprises: Indications, Advantages and Limitations

S. No	Option	Typical Indications	Advantages	Limitations/Risks	Optometrist's Practical Role
1	Observation + temporary Rx	Early postop; refraction still shifting; mild error	Avoids premature intervention	Delays spectacle independence; may frustrate "premium IOL" patients	Explain stabilisation timeline; schedule repeat refraction; document stability
2	Spectacles	Most residual SE/cylinder, especially monofocal	Fast, accessible, safe	Aniseikonia with anisometropia; may not meet expectations	Prescribe; counsel adaptation and task-specific options
3	Contact lenses (soft toric/RGP/scleral)	Irregular astigmatism; anisometropia; high cylinder	Better optics; reduces aniseikonia	Handling tolerance; dry eye; cost	Fit and monitor; use diagnostic RGP over-refraction to localise aberration source
4	Ocular surface treatment	Fluctuating refraction; DED/MGD; pre-enhancement optimisation	Improves measurement reliability and vision quality	May require weeks; persistent symptoms possible	Treat; repeat K/refraction; coordinate re-biometry if needed
5	Nd:YAG capsulotomy (surgeon)	PCO limiting VA; capsular block-related myopic shift	Rapid VA improvement	IOP spikes; potential toric rotation risk; retinal risk in predisposed	Identify and refer; post-YAG refraction update and monitoring
6	Toric IOL repositioning (surgeon)	Large residual cylinder with toric misalignment	Directly addresses cause; fast visual gain	Time-sensitive; surgical risk	Detect axis error; urgent referral when clinically meaningful misalignment suspected
7	IOL exchange (surgeon)	Wrong IOL power; intolerable premium IOL optics; large SE error	Addresses fundamental cause	Higher risk with capsular fibrosis; uncommon overall	Confirm stable refraction; provide measurements and counselling; coordinate referrals
8	Supplementary sulcus-fixated add-on IOL (surgeon)	Residual SE/cylinder; desire for reversible multifocality; avoid exchange	Reversible; modern designs reduce historic risks	Pigment dispersion/dysphotopsia/IOP issues possible	Identify candidates; monitor post-op IOP/inflammation; educate about symptoms
9	Corneal laser enhancement (LASIK/PRK)	Stable residual error; suitable cornea	Avoids intraocular surgery; high predictability in many	Dry eye risk; corneal limits; challenges in prior LASIK flaps	Ensure surface is optimised and refraction stable; provide pre-enhancement refraction/topography data
10	Light adjustable lens (technology pathway)	High-risk predictability cases (post-refractive); desire for precision	Postoperative adjustability; high % within ± 0.50 D in studies	Requires UV light treatment visits; protocol adherence	Support co-managed follow-up; verify "final stable" refraction; counsel on regimen

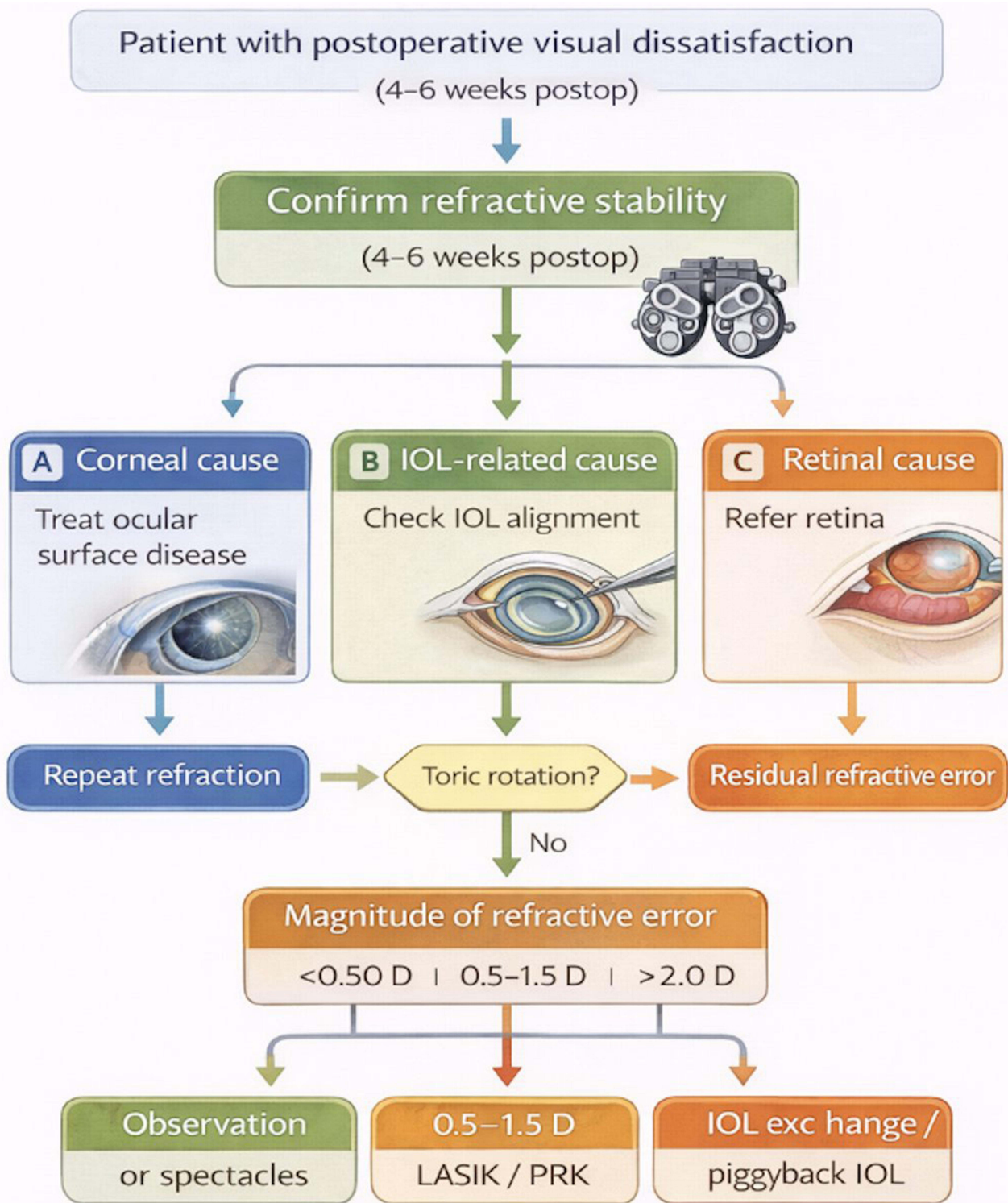


Figure 5 Flowchart of clinical management algorithm for refractive surprises following cataract surgery. After confirming refractive stability, patients are evaluated for corneal, IOL-related, or retinal causes. Management decisions are guided by the magnitude of residual refractive error and may include observation, laser enhancement, or intraocular surgical correction.

D (with strongest benefit at higher astigmatism), and supports OCT when VA is worse than expected. It also highlights that pre-operative DED affects measurements and outcomes and that prior refractive surgery requires additional assessment and counselling regarding refractive predictability and potential need for further correction.³⁸

ASCRS Clinical Committee Guidance

The ASCRS report provides a prevention-to-management continuum: repeat and cross-validate measurements in unusual eyes; perform topography/tomography before drops; treat ocular surface disease; recognise rare iatrogenic mistakes; and select enhancement modality based on error magnitude, corneal suitability, IOL type and tolerance. It also emphasises that multifocal IOLs are less tolerant of residual sphere/cylinder (typically around 0.50 D).

Structured Communication for Refractive Surprise Referral

Practical Communication Template

Effective communication between optometrists and surgeons is essential when referring a patient with a suspected refractive surprise after cataract surgery. Providing a structured and concise clinical summary helps minimize delays in management and allows the surgeon to quickly identify potential causes and determine the most appropriate corrective strategy. A comprehensive referral should include the date of surgery, the implanted intraocular lens (IOL) model and intended refractive target if known, the operated eye, and any reported intraoperative complications. Current refractive findings should be clearly documented, including sphere, cylinder, axis, best-corrected visual acuity (BCVA), uncorrected distance visual acuity (UDVA), and evidence of refractive stability across visits. Corneal information is equally important; therefore, a brief summary of keratometry or corneal topography findings—particularly whether astigmatism appears regular or irregular and whether the axis corresponds with the refractive cylinder—should be included. In eyes with toric IOLs, assessment of the lens axis alignment relative to corneal markings can provide valuable information regarding potential rotational misalignment. Additional details such as ocular surface status and ongoing treatment, macular OCT findings when visual acuity is worse than expected, and the patient's visual goals or tolerance for spectacles or contact lenses further assist the surgeon in planning appropriate management. A standardized communication approach ensures that referrals are clinically informative, facilitates efficient decision-making, and ultimately improves patient outcomes following cataract surgery.¹²³

Challenges in Optometric Settings

Key constraints include limited access to enhancement procedures (especially in publicly funded pathways), variation in how quickly surgical services can review toric misalignment, and incomplete transfer of surgical data (IOL model/target refraction) into community records. Co-management models (including separate LAL “open-access” light treatment clinics) illustrate potential solutions but also add coordination complexity.¹²

High-Risk Eyes for Refractive Surprise

Certain patient populations present unique biometric and optical challenges that substantially increase the risk of refractive surprises following cataract surgery. Post-refractive surgery eyes—particularly those with a history of LASIK, PRK, or RK—have altered anterior and posterior corneal curvature profiles that compromise the accuracy of standard keratometry and IOL power prediction formulas.⁵³ These patients often demonstrate unpredictable effective lens position (ELP), making both the identification and correction of refractive errors more complex; therefore, optometrists must rely on advanced corneal tomography, historical refractive data, and modern post-refractive IOL formulas to interpret postoperative refractive outcomes. Similarly, eyes with extreme axial lengths, whether exceptionally short (nanophthalmic) or very long (highly myopic), exhibit heightened sensitivity to small biometric deviations. In long eyes, even minor IOL power miscalculations may yield large refractive errors, while short eyes are prone to shallow anterior chamber depth and unpredictable IOL positioning, complicating both diagnosis and management of postoperative ametropia.¹²⁴ Patients with irregular corneas or underlying ectatic disease, including keratoconus or post-crosslinking morphology, are at particularly high risk for postoperative optical instability. These corneas frequently produce irregular astigmatism and large discrepancies between anterior and posterior curvature readings, leading to inaccurate keratometric inputs. Postoperative evaluation in these individuals requires careful topographic and tomographic assessment, and residual refractive error may necessitate specialty contact lenses rather than surgical enhancement.¹²⁵ Lastly, individuals implanted with multifocal or extended-depth-of-focus (EDOF) intraocular lenses constitute a distinct subgroup in which refractive accuracy is critical. Even small residual errors—especially uncorrected astigmatism or subtle IOL tilt—can

significantly degrade contrast sensitivity and generate dysphotopsias. These patients often present with heightened visual expectations, making precise identification of optical, neural, or IOL-related causes of dissatisfaction essential. Optometrists must therefore apply an elevated level of diagnostic scrutiny in these special populations, integrating imaging, refraction strategy, and symptom analysis to guide appropriate enhancement or referral decisions.¹²⁶

Optometric Role in Prevention & Co-Management

Optometrists play an indispensable role in preventing refractive surprises and ensuring optimal outcomes in cataract surgery through comprehensive preoperative assessment, meticulous ocular surface optimisation, and coordinated co-management with the surgical team.^{8,76} Prevention begins long before the day of surgery, with optometrists serving as the primary clinicians responsible for identifying factors that increase the likelihood of postoperative refractive error. During preoperative screening, optometrists evaluate refractive stability, assess the integrity and biomechanics of the cornea, and conduct detailed anterior and posterior segment examinations to identify conditions such as epithelial basement membrane dystrophy, subtle keratoconus, early macular degeneration, epiretinal membranes, or glaucomatous optic neuropathy all of which can influence the accuracy of biometry, IOL selection, and postoperative visual expectations. By systematically documenting a patient's refractive history, contact lens wear patterns, dry eye severity, ocular surgeries, and systemic comorbidities, optometrists create a precise risk profile that guides IOL planning and patient counseling.^{8,35,81,84} A major preventive responsibility lies in optimizing the ocular surface prior to biometry, as tear film instability, epithelial irregularity, meibomian gland dysfunction, and subclinical inflammation are among the most common—and most correctable—contributors to inaccurate keratometry and axial length measurements. Optometrists are uniquely positioned to diagnose and treat these issues using therapeutic warm compresses, lid hygiene, preservative-free lubricants, punctal occlusion, anti-inflammatory therapy, and strategies to reverse contact-lens-induced corneal warpage.^{76,77} Objective improvements in topography regularity and tear-film stability following surface optimization directly translate into more accurate IOL calculations, thereby reducing postoperative refractive surprises. This phase is also critical for flagging high-risk eyes, including post-LASIK/PRK/RK corneas, extremely short or long axial lengths, irregular corneas, pellucid/keratoconus patterns, corneal scars, and prior vitrectomy patients. Optometrists' ability to detect such conditions early enables surgeons to apply appropriate IOL formulas, avoid unsuitable IOL designs, or counsel patients toward realistic expectations regarding premium IOL performance.^{72,76,77}

Effective prevention also hinges on strong shared-care communication pathways between optometrists and surgeons. Clear, structured reporting that includes preoperative findings, biometric limitations, astigmatism analysis, macular status, and risk stratification greatly enhances surgical planning. This shared-care model continues into the postoperative period, where optometrists typically perform day-1, week-1, and month-1 assessments. Their ability to detect early warning signs—such as unexpected refractive drift, toric IOL rotation, capsular phimosis, cystoid macular edema, or ocular surface regression—provides the surgeon with timely information that may prevent chronic refractive error or visual dissatisfaction.^{8,34,56,61} Effective communication also ensures that decisions regarding enhancement—whether corneal refractive surgery, IOL rotation, piggyback IOL, or IOL exchange—are made collaboratively and at the appropriate postoperative interval. Finally, optometrists play a critical role in patient education and expectation management, which is one of the strongest predictors of postoperative satisfaction. Counseling begins preoperatively, with detailed discussions on achievable outcomes based on ocular status, limitations of multifocal/EDOF IOLs, the possibility of postoperative glare or halos, and the potential need for enhancements.^{10,18,33} Postoperatively, optometrists reinforce realistic timelines for visual stabilization, explain the management of temporary fluctuations, and address anxiety associated with early dysphotopsias or residual refractive error. This longitudinal relationship provides continuity of care and greatly reduces dissatisfaction by allowing patients to feel informed, supported, and included in shared decision-making. In essence, the optometrist's preventive and co-management role spans the entire surgical continuum—preoperative screening, ocular surface preparation, risk stratification, perioperative communication, postoperative monitoring, and long-term patient education. By integrating clinical precision with coordinated care pathways, optometrists significantly minimize refractive surprises, enhance visual outcomes, and elevate the overall patient experience following cataract surgery.^{8,91,95}

Challenges and Limitations in Optometric Settings

Despite the pivotal role of optometrists in the detection and management of refractive surprises following cataract surgery, several practical challenges limit the effectiveness of optometric involvement in certain healthcare settings. One major limitation relates to access to enhancement procedures. Surgical interventions such as corneal laser enhancement, piggyback or supplementary intraocular lens implantation, and intraocular lens exchange are not uniformly available across all regions. Availability often depends on local surgical infrastructure, reimbursement models, and healthcare system policies, including insurance coverage or publicly funded programs. Even when these procedures are clinically appropriate, logistical barriers such as cost, limited refractive surgery facilities, or referral delays may reduce their uptake despite evidence demonstrating favourable predictability and outcomes for correcting postoperative refractive error. Consequently, optometrists must frequently rely on conservative strategies such as spectacle or contact lens correction while coordinating referral to surgical services when enhancement becomes necessary.^{10,18,112} Another important challenge is the timing disconnect within shared-care pathways. In many co-management models, optometrists conduct routine postoperative reviews approximately four to six weeks after cataract surgery, by which time certain corrective interventions—such as toric intraocular lens repositioning or early IOL exchange—may be technically more difficult due to capsular fibrosis and lens stabilization. Earlier recognition of significant residual refractive error, particularly large cylindrical error suggestive of toric IOL misalignment, is therefore critical. Establishing clear “fast-track” referral criteria for early surgical reassessment can help preserve a wider range of corrective options and improve visual outcomes.^{31,113} A further limitation involves heterogeneity in diagnostic equipment across optometric practices. Advanced imaging technologies such as corneal tomography, anterior segment optical coherence tomography, and macular OCT are increasingly recommended for evaluating patients with postoperative dissatisfaction, as they help identify subtle corneal irregularities, IOL tilt or decentration, and retinal pathology that may masquerade as refractive error. However, not all community practices have access to such equipment, which can limit the depth of diagnostic evaluation and necessitate additional referrals for comprehensive assessment.^{84,85} Finally, effective interdisciplinary communication between optometrists and cataract surgeons remains essential yet sometimes suboptimal. For enhancement planning to be accurate and efficient, postoperative findings must be communicated in a surgeon-actionable format, including precise refractive measurements, astigmatism axis and vector information, stability of refraction across visits, and relevant ocular surface or retinal findings. Structured reporting systems and standardized documentation of refractive outcomes have been recommended to improve coordination of care and minimize delays in decision-making. Strengthening these collaborative communication pathways ultimately supports more timely interventions and better patient outcomes in the management of postoperative refractive surprises (Table 5 and Table 6).^{36,68}

Table 5 Depict the Diagnostic Imaging Modalities in Refractive Surprise Evaluation

S. No	Imaging Modality	Key Parameter Assessed	Diagnostic Role	Typical Findings in Refractive Surprise	Clinical Interpretation
1	Corneal Topography	Anterior corneal curvature	Detect irregular astigmatism and ectasia	Asymmetric bow-tie pattern, inferior steepening	Suggests keratoconus or irregular cornea
2	Scheimpflug Tomography	Total corneal power, posterior curvature	Evaluate posterior corneal astigmatism	Posterior corneal steepening, abnormal elevation maps	Helps explain unexpected residual astigmatism
3	Optical Biometry	Axial length, anterior chamber depth	Reconfirm biometric accuracy	Significant deviation from fellow eye measurements	Possible axial length measurement error
4	Anterior Segment OCT	IOL tilt, decentration, capsular bag anatomy	Detect IOL position abnormalities	Tilted or decentred IOL optic	Explains refractive error despite normal refraction
5	Macular OCT	Retinal structure and macular integrity	Identify retinal causes of reduced vision	CME, ERM, subretinal fluid	Visual symptoms not primarily refractive

(Continued)

Table 5 (Continued).

S. No	Imaging Modality	Key Parameter Assessed	Diagnostic Role	Typical Findings in Refractive Surprise	Clinical Interpretation
6	Keratometry (automated/manual)	Corneal curvature	Identify corneal measurement variability	Large variability between devices	Suggests tear film instability or measurement error
7	Wavefront Aberrometry	Higher-order aberrations	Evaluate optical quality of the eye	Elevated coma, spherical aberration	May indicate irregular cornea or IOL tilt
8	Slit-lamp biomicroscopy	IOL centration, capsular status	First-line structural assessment	Capsular contraction, toric misalignment	Guides need for surgical referral

Table 6 Depict the Refractive Error Magnitude Based Management Strategy

S. No	Magnitude of Refractive Error	Typical Clinical Scenario	Preferred Management	Alternative Options	Key Clinical Considerations
1	≤0.50 D	Mild residual refractive error	Observation or spectacles	Contact lenses	Often well tolerated, especially in monofocal IOLs
2	0.50–1.00 D	Small refractive miss	Spectacles or soft toric lenses	Laser enhancement (selected cases)	Important in premium IOL patients
3	1.00–2.00 D	Moderate ametropia	Laser refractive surgery (PRK/LASIK)	Piggyback IOL	Requires stable refraction and healthy cornea
4	>2.00 D	Large spherical error	IOL exchange or piggyback IOL	Corneal laser enhancement (limited)	Prefer early intervention before capsular fibrosis
5	Residual cylinder >1.50 D	Toric IOL rotation	Toric IOL repositioning	Arcuate keratotomy	Time sensitive—best early postop
6	Irregular astigmatism	Keratoconus, corneal scar	RGP or scleral lenses	Corneal procedures	Optical correction preferred initially
7	Fluctuating refractive error	Dry eye or tear instability	Ocular surface treatment	Repeat biometry	Treat surface before planning enhancement
8	Dissatisfaction despite good refraction	Dysphotopsia with multifocal IOL	Counseling / neuroadaptation	IOL exchange (rare)	Rule out residual refractive error first

Future Directions

The future of cataract surgery is increasingly shaped by technological advances aimed at reducing postoperative refractive surprises and improving visual outcomes. Innovations in artificial intelligence, machine learning, and next-generation biometry are enhancing refractive prediction accuracy and enabling greater personalization of surgical planning. These tools integrate biometric measurements, corneal imaging, and large clinical datasets to improve intraocular lens (IOL) selection and postoperative refractive predictability, strengthening both surgical planning and optometric co-management.^{28,34} Artificial intelligence-based IOL prediction models are transforming refractive planning by identifying complex nonlinear relationships between biometric variables such as axial length, corneal curvature, anterior chamber depth, and effective lens position. Algorithms including the Hill-RBF, Kane formula, and other machine-learning systems demonstrate improved prediction accuracy, particularly in challenging eyes such as those with extreme axial lengths or previous refractive surgery. These approaches move toward personalized IOL selection based on individual ocular anatomy rather than population averages.^{28,46} Advances in optical biometry further support refractive precision. Modern swept-source OCT

biometers provide high-resolution imaging of ocular structures and improved measurement repeatability for axial length, lens thickness, and corneal parameters. Integration of tomography, aberrometry, and tear-film assessment also helps reduce measurement variability caused by ocular surface disease.^{34,84} Machine learning tools are also improving detection of toric IOL misalignment and postoperative lens position. Automated imaging analysis can identify subtle rotational shifts that significantly affect refractive outcomes and guide timely surgical correction.^{31,114} Future strategies are also focusing on improved prediction of effective lens position and personalized IOL calculation models. Integration of additional biometric parameters and AI-based prediction systems may further reduce refractive outliers. Adjustable and modular lens technologies—such as light-adjustable lenses and supplementary sulcus-fixated IOLs—offer postoperative refractive modification and flexible management of residual error.^{116–118} Optimization of corneal metrics and ocular surface health is another critical component of improving refractive accuracy. Technologies such as total keratometry and posterior corneal measurement improve corneal power estimation, while evidence shows that dry eye disease significantly affects keratometric reliability and should be treated prior to biometry.^{11,72,77} Despite these advances, important evidence gaps remain. Standardized definitions of refractive surprise that include astigmatism and visual quality symptoms are still lacking, and further research is needed to evaluate optometrist-led diagnostic pathways and real-world outcomes of enhancement strategies across different IOL types and ocular surface conditions.^{68,112}

Conclusion

Refractive surprises after cataract surgery remain a significant source of patient dissatisfaction and clinical complexity, but they are largely preventable through meticulous preoperative planning, structured postoperative evaluation, and timely optometric intervention. This review highlights the essential role of optometrists in early identification, diagnostic stratification, and collaborative management of residual refractive errors. A systematic approach—beginning with accurate history gathering, careful refraction, detailed slit-lamp assessment, and targeted use of imaging—enables clinicians to distinguish between optical, corneal, lenticular, and retinal contributors to suboptimal outcomes. Likewise, familiarity with both nonsurgical and surgical management pathways ensures appropriate escalation and patient counselling.

Funding

No external support, either public or private, was received for the conduct of this study.

Disclosure

The authors declare no conflicts of interest in this work.

References

- Okoye GS, Bonabe D, Obasi CU, et al. Visual outcomes and complications after phacoemulsification and small incision manual cataract surgery in two eye hospitals. *J Fr Ophthalmol*. 2025;48(1):104353. PMID: 39561679. doi:10.1016/j.jfo.2024.104353
- Lapp T, Wacker K, Heinz C, Maier P, Eberwein P, Reinhard T. Cataract surgery-indications, techniques, and intraocular lens selection. *Dtsch Arztebl Int*. 2023;120(21):377–386. PMID: 36794457; PMCID: PMC10413970. doi:10.3238/arztebl.m2023.0028
- Antwi-Adjei EK, Owusu E, Kobia-Acquah E, Dadzie EE, Anarfi E, Wanye S. Evaluation of postoperative refractive error correction after cataract surgery. *PLoS One*. 2021;16(6):e0252787. PMID: 34138900; PMCID: PMC8211256. doi:10.1371/journal.pone.0252787
- Alió JL, Martínez-Abad A, Ruiz-Mesa R, et al. Visual and patient reported outcomes provided by a refractive multifocal intraocular lens based on continuous transitional focus. *Eye Vis*. 2024;11(1):41. PMID: 39402644; PMCID: PMC11479541. doi:10.1186/s40662-024-00408-y
- Tavassoli S, Ziaei H, Yadegarfar ME, et al. Trifocal versus extended depth of focus (EDOF) intraocular lenses after cataract extraction. *Cochrane Database Syst Rev*. 2024;7(7):CD014891. PMID: 38984608; PMCID: PMC11234495. doi:10.1002/14651858.CD014891.pub2
- Singh A, Kapoor G, Baranwal VK, Kalra N. Rotational stability of Toric intraocular lenses. *Med J Armed Forces India*. 2022;78(1):68–73. Epub 2020 Jul 9. PMID: 35035046; PMCID: PMC8737107. doi:10.1016/j.mjafi.2020.03.014
- Ottonelli G, De Rosa G, Celada Ballanti J, Gaeta A, Vinciguerra P, Di Maria A. Does DeepSeek Provide Clinically Acceptable Intraocular Lens (IOL) power predictions in cataract surgery? A proof-of-concept study. *J Clin Med*. 2025;14(24):8870. PMID: 41464772; PMCID: PMC12733728. doi:10.3390/jcm14248870
- Saigal K, Shah S, Ansari Z. Optometry co-management of preoperative and postoperative cataract surgery patients. *Curr Opin Ophthalmol*. 2025;36(5):401–406. Epub 2025 Jun 5. PMID: 40471754. doi:10.1097/ICU.0000000000001153
- Ayanniyi AA, Folorunso FN, Adepoju FG. Refractive ocular conditions and reasons for spectacles renewal in a resource-limited economy. *BMC Ophthalmol*. 2010;10:12. PMID: 20459676; PMCID: PMC2885324. doi:10.1186/1471-2415-10-12
- Kanclerz P, Bazylczyk N, Hecht I, Tuuminen R. Surgical options for correcting refractive surprise after cataract and lens surgery: review and meta-analysis. *J Cataract Refract Surg*. 2025;51(12):1139–1147. PMID: 40929562. doi:10.1097/j.jcrs.0000000000001750

11. Jiang Y, Chen X, Gao Y, et al. Impact of tear film stability on corneal refractive power measurement and surgical planning for cataract. *Adv Ophthalmol Pract Res.* 2025;5(2):100–106. PMID: 40207192; PMCID: PMC11979470. doi:10.1016/j.aopr.2025.02.001
12. Lundström M, Dickman M, Henry Y, et al. Risk factors for refractive error after cataract surgery: analysis of 282 811 cataract extractions reported to the European Registry of Quality Outcomes for cataract and refractive surgery. *J Cataract Refract Surg.* 2018;44(4):447–452. Epub 2018 Apr 22. PMID: 29685779. doi:10.1016/j.jcrs.2018.01.031
13. Gale RP, Saldana M, Johnston RL, Zuberhuhler B, McKibbin M. Benchmark standards for refractive outcomes after NHS cataract surgery. *Eye.* 2009;23(1):149–152. PMID: 17721503. doi:10.1038/sj.eye.6702954
14. Abulafia A, Hill WE, Koch DD, Wang L, Barrett GD. Accuracy of the Barrett True-K formula for intraocular lens power prediction after laser in situ keratomileusis or photorefractive keratectomy for myopia. *J Cataract Refract Surg.* 2016;42(3):363–369. PMID: 27006324. doi:10.1016/j.jcrs.2015.11.039
15. Lee T, Leung M, van Boxtel JJA, Boon MY. The effects of refractive imbalance on binocular vision status, reading performance, and vision-related reading difficulty symptoms in expert readers. *Invest Ophthalmol Vis Sci.* 2025;66(9):15. PMID: 40622213; PMCID: PMC12240207. doi:10.1167/iov.66.9.15
16. Marino F, Alby F, Zuccheromaglio C, Fatigante M. Digital technology in medical visits: a critical review of its impact on doctor-patient communication. *Front Psychiatry.* 2023;14:1226225. PMID: 37575567; PMCID: PMC10412815. doi:10.3389/fpsy.2023.1226225
17. Oam BA, Resnikoff S. The role of optometry in vision 2020. *Community Eye Health.* 2002;15(43):33–36. PMID: 17491876; PMCID: PMC1705887.
18. Abdelghany AA, Alio JL. Surgical options for correction of refractive error following cataract surgery. *Eye Vis.* 2014;1:2. PMID: 26605349; PMCID: PMC4604120. doi:10.1186/s40662-014-0002-2
19. Lin X, Ma D, Yang J. Insights into the rotational stability of toric intraocular lens implantation: diagnostic approaches, influencing factors and intervention strategies. *Front Med Lausanne.* 2024;11:1349496. PMID: 38414624; PMCID: PMC10896894. doi:10.3389/fmed.2024.1349496
20. Gurnani B, Kaur K. Recent advances in refractive surgery: an overview. *Clin Ophthalmol.* 2024;18:2467–2472. PMID: 39246558; PMCID: PMC11380141. doi:10.2147/OPHT.S481421
21. Alió JL, Vega-Estrada A, Plaza-Puche AB. Clinical outcomes with a new microincisional diffractive multifocal IOL. *Eye Vis.* 2015;2:2. PMID: 26605358; PMCID: PMC4657369. doi:10.1186/s40662-015-0012-8
22. Karabela Y, Eliacik M, Kocabora MS, Erdur SK, Baybora H. Predicting the refractive outcome and accuracy of IOL power calculation after phacoemulsification using the SRK/T formula with ultrasound biometry in medium axial lengths. *Clin Ophthalmol.* 2017;11:1143–1149. PMID: 28670106; PMCID: PMC5479261. doi:10.2147/OPHT.S136882
23. Hashemi H, Jamali A, Rezavn F, Hashemi A, Khabazkhoob M. Residual refractive errors in pseudophakic eyes and related factors: a population-based study. *Int J Ophthalmol.* 2023;16(5):778–786. PMID: 37206186; PMCID: PMC10172090. doi:10.18240/ijo.2023.05.16
24. Shokooi Rad S, Ansari Astaneh MR, Kiarudi MY, Ghavami Shahri SH, Heidarzadeh HR. Post cataract surgery refractive surprise due to intraocular lens mislabeling. *Clin Case Rep.* 2024;12(7):e9104. PMID: 38911921; PMCID: PMC11192593. doi:10.1002/ccr3.9104
25. Sandoval HP, Potvin R, Solomon KD. Comparing visual performance and subjective outcomes with an enhanced monofocal intraocular lens when targeted for emmetropia or monovision. *Clin Ophthalmol.* 2023;17:3693–3702. PMID: 38058694; PMCID: PMC10697088. doi:10.2147/OPHT.S442752
26. Saffarizadeh M, Rahmani S, Akbarzadeh Baghban A, Ghassemi-Broumand M. Effect of astigmatism and spherical equivalent correction on contrast sensitivity. *Int J Ophthalmol.* 2024;17(12):2243–2247. PMID: 39697875; PMCID: PMC11589434. doi:10.18240/ijo.2024.12.12
27. Gurnani B, Kaur K, Lalgudi VG, et al. Role of artificial intelligence, machine learning and deep learning models in corneal disorders - A narrative review. *J Fr Ophtalmol.* 2024;47(7):104242. PMID: 39013268. doi:10.1016/j.jfo.2024.104242
28. Stopyra W, Cooke DL, Grzybowski A. A review of intraocular lens power calculation formulas based on artificial intelligence. *J Clin Med.* 2024;13(2):498. PMID: 38256632; PMCID: PMC10816994. doi:10.3390/jcm13020498
29. Schnider C, Yuen L, Rampat R, et al. BCLA CLEAR presbyopia: management with intraocular lenses. *Cont Lens Anterior Eye.* 2024;47(4):102253. PMID: 39068141. doi:10.1016/j.clae.2024.102253
30. Shoshi F, Shoshi F, Xhafa A, Nagy ZZ. Refractive outcomes after cataract surgery-the impact of preoperative visual acuity, the intraocular lens model, and the surgeon's experience: an empirical analysis of hungarian and kosovan patients. *J Clin Med.* 2024;13(23):7013. PMID: 39685470; PMCID: PMC11642209. doi:10.3390/jcm13237013
31. Hu EH. Repositioning rates of toric IOLs implanted in cataract surgery patients: a retrospective chart review. *Clin Ophthalmol.* 2023;17:4001–4007. PMID: 38152615; PMCID: PMC10752012. doi:10.2147/OPHT.S441524
32. Kanclerz P, Toto F, Grzybowski A, Alio JL. Extended depth-of-field intraocular lenses: an update. *Asia Pac J Ophthalmol.* 2020;9(3):194–202. PMID: 32511121; PMCID: PMC7299221. doi:10.1097/APO.0000000000000296
33. Woodward MA, Randleman JB, Stulting RD. Dissatisfaction after multifocal intraocular lens implantation. *J Cataract Refract Surg.* 2009;35(6):992–997. PMID: 19465282; PMCID: PMC5125020. doi:10.1016/j.jcrs.2009.01.031
34. Pathak M, Sahu V, Kumar A, Kaur K, Gurnani B. Current concepts and recent updates of optical biometry- a comprehensive review. *Clin Ophthalmol.* 2024;18:1191–1206. PMID: 38711575; PMCID: PMC11073143. doi:10.2147/OPHT.S464538
35. Lee DJ, Seto S, Banghart M, et al. Risk factors associated with unexpected refractive outcomes in uveitic cataract surgery. *Ocul Immunol Inflamm.* 2024;32(5):642–647. PMID: 36931285; PMCID: PMC10505240. doi:10.1080/09273948.2023.2187847
36. Kaye SB, Rubin A, Evans T, Aristodemou P, Khawaja A, Sparrow J. Standardised approach to the reporting and presentation of refractive data: electronic patient record. *BMJ Open Ophthalmol.* 2022;7(1):e001015. PMID: 35452209; PMCID: PMC8977760. doi:10.1136/bmjophth-2022-001015
37. Tran KV, Nguyen THM. Evaluation of residual refractive prediction accuracy after phacoemulsification using the SRK/T formula. *Saudi J Ophthalmol.* 2023;37(3):237–240. PMID: 38074294; PMCID: PMC10701144. doi:10.4103/sjopt.sjopt_19_23
38. Lundström M, Barry P, Henry Y, Rosen P, Stenevi U. Evidence-based guidelines for cataract surgery: guidelines based on data in the European registry of quality outcomes for cataract and refractive surgery database. *J Cataract Refract Surg.* 2012;38(6):1086–1093. PMID: 22541829. doi:10.1016/j.jcrs.2012.03.006
39. Khoramnia R, Auffarth G, Labuz G, Pettit G, Suryakumar R. Refractive outcomes after cataract surgery. *Diagnostics.* 2022;12(2):243. PMID: 35204334; PMCID: PMC8870878. doi:10.3390/diagnostics12020243

40. Moshirfar M, McCaughey MV, Santiago-Caban L. Corrective techniques and future directions for treatment of residual refractive error following cataract surgery. *Expert Rev Ophthalmol.* 2014;9(6):529–537. PMID: 25663845; PMCID: PMC4317710. doi:10.1586/17469899.2014.966817
41. Mengistu M, Admassu F, Wondale T, Tsegaw A. Refractive outcome of cataract surgery done at university of gondar tertiary eye care and training center, North West Ethiopia. *Patient Relat Outcome Meas.* 2021;12:173–179. PMID: 34140819; PMCID: PMC8203275. doi:10.2147/PROM.S308816
42. Eleftheriadis H. IOLMaster biometry: refractive results of 100 consecutive cases. *Br J Ophthalmol.* 2003;87(8):960–963. PMID: 12881334; PMCID: PMC1771781. doi:10.1136/bjo.87.8.960
43. Ifrah R, Darwish T. Prevalence of meibomian gland dysfunction in patients with keratoconus in an optometry clinic in the palestinian authority. *Biomedicine.* 2026;14(1):134. PMID: 41595668; PMCID: PMC12838816. doi:10.3390/biomedicine14010134
44. Olsen T. Calculation of intraocular lens power: a review. *Acta Ophthalmol Scand.* 2007;85(5):472–485. PMID: 17403024. doi:10.1111/j.1600-0420.2007.00879.x
45. Koch DD, Ali SF, Weikert MP, Shirayama M, Jenkins R, Wang L. Contribution of posterior corneal astigmatism to total corneal astigmatism. *J Cataract Refract Surg.* 2012;38(12):2080–2087. PMID: 23069271. doi:10.1016/j.jcrs.2012.08.036
46. Yasar II, Yasar S, Al BL, et al. Comparative analysis of intraocular lens power calculation formulas (Kane, barrett universal II, hill-radial basis function, and ladas super formula): which one is more accurate? *J Clin Med.* 2025;14(7):2443. PMID: 40217893; PMCID: PMC11989757. doi:10.3390/jcm14072443
47. Pniakowska Z, Jurowski P, Wierzbowska J. Clinical evaluation of corneal biomechanics following laser refractive surgery in myopic eyes: a review of the literature. *J Clin Med.* 2022;12(1):243. PMID: 36615041; PMCID: PMC9821300. doi:10.3390/jcm12010243
48. Kane JX, Van Heerden A, Atik A, Petsoglou C. Accuracy of 3 new methods for intraocular lens power selection. *J Cataract Refract Surg.* 2017;43(3):333–339. PMID: 28410714. doi:10.1016/j.jcrs.2016.12.021
49. Kaur RP, Gurnani B, Kaur K. Intricate insights into immune response in dry eye disease. *Indian J Ophthalmol.* 2023;71(4):1248–1255. PMID: 37026255; PMCID: PMC10276682. doi:10.4103/IJO.IJO_481_23
50. Yang F, Yang L, Ning X, Liu J, Wang J. Effect of dry eye on the reliability of keratometry for cataract surgery planning. *J Fr Ophthalmol.* 2024;47(2):103999. PMID: 37919153. doi:10.1016/j.jfo.2023.04.016
51. Hiraoka T, Asano H, Ogami T, et al. Influence of Dry eye disease on the measurement repeatability of corneal curvature radius and axial length in patients with cataract. *J Clin Med.* 2022;11(3):710. PMID: 35160160; PMCID: PMC8837034. doi:10.3390/jcm11030710
52. Aramberri J. Intraocular lens power calculation after corneal refractive surgery: double-K method. *J Cataract Refract Surg.* 2003;29(11):2063–2068. PMID: 14670413. doi:10.1016/s0886-3350(03)00957-x
53. Wang L, Hill WE, Koch DD. Evaluation of intraocular lens power prediction methods using the American society of cataract and refractive surgeons post-keratorefractive intraocular lens power calculator. *J Cataract Refract Surg.* 2010;36(9):1466–1473. PMID: 20692556. doi:10.1016/j.jcrs.2010.03.044
54. Rabinowitz YS. Keratoconus. *Surv Ophthalmol.* 1998;42(4):297–319. PMID: 9493273. doi:10.1016/S0039-6257(97)00119-7
55. Belin MW, Ambrósio R. Scheimpflug imaging for keratoconus and ectatic disease. *Indian J Ophthalmol.* 2013;61(8):401–406. PMID: 23925323; PMCID: PMC3775073. doi:10.4103/0301-4738.116059
56. Koch DD, Jenkins RB, Weikert MP, Yeu E, Wang L. Correcting astigmatism with toric intraocular lenses: effect of posterior corneal astigmatism. *J Cataract Refract Surg.* 2013;39(12):1803–1809. PMID: 24169231. doi:10.1016/j.jcrs.2013.06.027
57. Masket S, Wang L, Belani S. Induced astigmatism with 2.2- and 3.0-mm coaxial phacoemulsification incisions. *J Refract Surg.* 2009;25(1):21–24. PMID: 19244949. doi:10.3928/1081597X-20090101-04
58. Holladay JT, Piers PA, Koranyi G, van der Mooren M, Norrby NE. A new intraocular lens design to reduce spherical aberration of pseudophakic eyes. *J Refract Surg.* 2002;18(6):683–691. PMID: 12458861. doi:10.3928/1081-597X-20021101-04
59. Davison JA. Capsule contraction syndrome. *J Cataract Refract Surg.* 1993;19(5):582–589. PMID: 8229711. doi:10.1016/s0886-3350(13)80004-1
60. Hayashi K, Hayashi H, Nakao F, Hayashi F. Anterior capsule contraction and intraocular lens decentration and tilt after hydrogel lens implantation. *Br J Ophthalmol.* 2001;85(11):1294–1297. PMID: 11673291; PMCID: PMC1723752. doi:10.1136/bjo.85.11.1294
61. Lobo C. Pseudophakic cystoid macular edema. *Ophthalmologica.* 2012;227(2):61–67. PMID: 21921587. doi:10.1159/000331277
62. Yonekawa Y, Kim IK. Pseudophakic cystoid macular edema. *Curr Opin Ophthalmol.* 2012;23(1):26–32. PMID: 22134362. doi:10.1097/ICU.0b013e32834cd5f8
63. Kim SJ, Flach AJ, Jampol LM. Nonsteroidal anti-inflammatory drugs in ophthalmology. *Surv Ophthalmol.* 2010;55(2):108–133. PMID: 20159228. doi:10.1016/j.survophthal.2009.07.005
64. Miyake K, Ota I, Ichihashi S, Miyake S, Tanaka Y, Terasaki H. New classification of capsular block syndrome. *J Cataract Refract Surg.* 1998;24(9):1230–1234. PMID: 9768398. doi:10.1016/s0886-3350(98)80017-5
65. Raj SM, Vasavada AR, Johar SR, Vasavada VA, Vasavada VA. Post-operative capsular opacification: a review. *Int J Biomed Sci.* 2007;3(4):237–250. PMID: 23675049; PMCID: PMC3614664.
66. Cinar E, Yuce B, Aslan F, Erbakan G. Influence of Nd:YAG laser capsulotomy on toric intraocular lens rotation and change in cylinder power. *J Cataract Refract Surg.* 2024;50(1):43–50. PMID: 37702513. doi:10.1097/j.jcrs.0000000000001306
67. Greenberg PB, Tseng VL, Wu WC, et al. Prevalence and predictors of ocular complications associated with cataract surgery in United States veterans. *Ophthalmology.* 2011;118(3):507–514. PMID: 21035868. doi:10.1016/j.ophtha.2010.07.023
68. Charlesworth E, Ursell P, Ho KC, Keay L, Elliott DB. Developing refractive management recommendations for patients undergoing cataract surgery: a Delphi study. *Ophthalmic Physiol Opt.* 2023;43(1):150–159. PMID: 36385383; PMCID: PMC10100233. doi:10.1111/opo.13069
69. Aristodemou P, Sparrow JM, Kaye S. Evaluating refractive outcomes after cataract surgery. *Ophthalmology.* 2019;126(1):13–18. PMID: 30153943. doi:10.1016/j.ophtha.2018.07.009
70. Hoffer KJ. The Hoffer Q formula: a comparison of theoretic and regression formulas. *J Cataract Refract Surg.* 1993;19(6):700–712. PMID: 8271165. doi:10.1016/s0886-3350(13)80338-0
71. Kaur K, Gurnani B. Cycloplegic and noncycloplegic refraction. In: *StatPearls*. Treasure Island (FL): StatPearls Publishing; 2026. PMID: 35593830.

72. Biela K, Winiarczyk M, Borowicz D, Mackiewicz J. Dry eye disease as a cause of refractive errors after cataract surgery - a systematic review. *Clin Ophthalmol.* 2023;17:1629–1638. PMID: 37304333; PMCID: PMC10257420. doi:10.2147/OPTH.S406530
73. Chen L, Chen X, Li F, Liu Z. Refractive Surprise of irregular astigmatism following cataract surgery in two patients with neglected subclinical corneal ectasia: two case reports. *BMC Ophthalmol.* 2023;23(1):239. PMID: 37248492; PMCID: PMC10226246. doi:10.1186/s12886-023-02984-4
74. Nichols KK, Foulks GN, Bron AJ, et al. The international workshop on meibomian gland dysfunction: executive summary. *Invest Ophthalmol Vis Sci.* 2011;52(4):1922–1929. PMID: 21450913; PMCID: PMC3072157. doi:10.1167/iovs.10-6997a
75. Matossian C, McDonald M, Donaldson KE, Nichols KK, MacIver S, Gupta PK. Dry eye disease: consideration for women's health. *J Womens Health.* 2019;28(4):502–514. PMID: 30694724; PMCID: PMC6482917. doi:10.1089/jwh.2018.7041
76. Trattler WB, Majmudar PA, Donnenfeld ED, McDonald MB, Stonecipher KG, Goldberg DF. The Prospective Health Assessment of Cataract Patients' Ocular Surface (PHACO) study: the effect of dry eye. *Clin Ophthalmol.* 2017;11:1423–1430. PMID: 28848324; PMCID: PMC5557104. doi:10.2147/OPTH.S120159
77. Epiropoulos AT, Matossian C, Berdy GJ, Malhotra RP, Potvin R. Effect of tear osmolarity on repeatability of keratometry for cataract surgery planning. *J Cataract Refract Surg.* 2015;41(8):1672–1677. PMID: 26432124. doi:10.1016/j.jcrs.2015.01.016
78. Potvin R, Kramer BA, Hardten DR, Berdahl JP. Toric intraocular lens orientation and residual refractive astigmatism: an analysis. *Clin Ophthalmol.* 2016;10:1829–1836. PMID: 27703323; PMCID: PMC5036610. doi:10.2147/OPTH.S114118
79. Chen XY, Wang YC, Zhao TY, Wang ZZ, Wang W. Tilt and decentration with various intraocular lenses: a narrative review. *World J Clin Cases.* 2022;10(12):3639–3646. PMID: 35647149; PMCID: PMC9100733. doi:10.12998/wjcc.v10.i12.3639
80. Mehta R, Aref AA. Intraocular lens implantation in the ciliary sulcus: challenges and risks. *Clin Ophthalmol.* 2019;13:2317–2323. PMID: 31819356; PMCID: PMC6885568. doi:10.2147/OPTH.S205148
81. Jammal HM, Khader Y, Shawer R, Al Bdour M. Posterior segment causes of reduced visual acuity after phacoemulsification in eyes with cataract and obscured fundus view. *Clin Ophthalmol.* 2012;6:1843–1848. Epub 2012 Nov 7. PMID: 23152664; PMCID: PMC3497462. doi:10.2147/OPTH.S38303
82. Bamonte G, Iodice CM, Mastropasqua R, et al. Symptomatic vitreous opacities: exploring the mismatch between clinical observation of vitreous alterations and self-reported symptoms. *J Clin Med.* 2024;13(20):6052. PMID: 39458005; PMCID: PMC11509205. doi:10.3390/jcm13206052
83. Henderson BA, Kim JY, Ament CS, Ferrufino-Ponce ZK, Grabowska A, Cremers SL. Clinical pseudophakic cystoid macular edema. Risk factors for development and duration after treatment. *J Cataract Refract Surg.* 2007;33(9):1550–1558. PMID: 17720069. doi:10.1016/j.jcrs.2007.05.013
84. Kanclerz P, Khoramnia R, Wang X. Current developments in corneal topography and tomography. *Diagnostics.* 2021;11(8):1466. PMID: 34441401; PMCID: PMC8392046. doi:10.3390/diagnostics11081466
85. Goldhardt R, Rosen BS. Optical coherence tomography: critical tool to manage expectations after cataract extraction. *Curr Ophthalmol Rep.* 2020;8(3):129–135. PMID: 33094032; PMCID: PMC7574664. doi:10.1007/s40135-020-00243-z
86. Shan J, DeBoer C, Xu BY. Anterior segment optical coherence tomography: applications for clinical care and scientific research. *Asia Pac J Ophthalmol.* 2019;8(2):146–157. PMID: 31020820; PMCID: PMC7903991. doi:10.22608/APO.201910
87. López-Muñoz A, López-Castaño I, Torres-Parejo Ú, García-Romera MC. A corneal biomechanical study measured with a scheimpflug dynamic analyser in soft contact lens wearers. *Life.* 2023;13(12):2313. PMID: 38137914; PMCID: PMC10744429. doi:10.3390/life13122313
88. R A Jr, Lopes BT, Faria-Correia F, et al. Integration of scheimpflug-based corneal tomography and biomechanical assessments for enhancing ectasia detection. *J Refract Surg.* 2017;33(7):434–443. PMID: 28681902. doi:10.3928/1081597X-20170426-02
89. Szczesna-Iskander DH, Muzyka-Wozniak M, Llorens Quintana C. The efficacy of ocular surface assessment approaches in evaluating dry eye treatment with artificial tears. *Sci Rep.* 2022;12(1):21835. PMID: 36528723; PMCID: PMC9759550. doi:10.1038/s41598-022-26327-3
90. Harb EN, Wildsoet CF. Origins of refractive errors: environmental and genetic factors. *Annu Rev Vis Sci.* 2019;5:47–72. PMID: 31525141; PMCID: PMC11827892. doi:10.1146/annurev-vision-091718-015027
91. Ison M, Scott J, Apel J, Expectation AAP. Satisfaction and clinical outcomes with a new multifocal intraocular lens. *Clin Ophthalmol.* 2021;15:4131–4140. PMID: 34675480; PMCID: PMC8520966. doi:10.2147/OPTH.S327424
92. Hernández-López I, Estradé-Fernández S, Cárdenas-Díaz T, Biometry B-LAJ. Refractive errors, and the results of cataract surgery: a large sample study. *J Ophthalmol.* 2021;2021:9918763. PMID: 34007484; PMCID: PMC8099509. doi:10.1155/2021/9918763
93. Fernández-Vigo JI, De-Pablo-Gómez-de-Liaño L, Almorín-Fernández-Vigo I, et al. The clinical usefulness of evaluating the lens and intraocular lenses using optical coherence tomography: an updated literature review. *J Clin Med.* 2024;13(23):7070. PMID: 39685529; PMCID: PMC11642259. doi:10.3390/jcm13237070
94. Werner L, Michelson J, Ollerton A, Leishman L, Bodnar Z. Anterior segment optical coherence tomography in the assessment of postoperative intraocular lens optic changes. *J Cataract Refract Surg.* 2012;38(6):1077–1085. PMID: 22624909. doi:10.1016/j.jcrs.2012.01.027
95. Nanda AK, Panda BB, Swain A, Balakrishnan L. Determination of the time of refractive stability after uneventful phacoemulsification in Indian eyes. *World J Exp Med.* 2024;14(2):95016. PMID: 38948423; PMCID: PMC11212749. doi:10.5493/wjem.v14.i2.95016
96. Gustafsson I, Bergström A, Myers AC, Ivarsen A, Hjortdal J. Association between keratoconus disease severity and repeatability in measurements of parameters for the assessment of progressive disease. *PLoS One.* 2020;15(2):e0228992. PMID: 32059036; PMCID: PMC7021304. doi:10.1371/journal.pone.0228992
97. Kaur K, Gurnani B. Subjective Refraction Techniques. In: *StatPearls*. Treasure Island (FL): StatPearls Publishing; 2026. PMID: 35593807.
98. Barone V, Petrini D, Nunziata S, et al. Impact of scleral lenses on visual acuity and ocular aberrations in corneal ectasia: a comprehensive review. *J Pers Med.* 2024;14(10):1051. PMID: 39452558; PMCID: PMC11509004. doi:10.3390/jpm14101051
99. Al-Shymali O, Cantó-Cerdán M, Alió Del Barrio JL, McAlinden C, Yebana P, Alió JL. Managing dissatisfaction after multifocal intraocular lens implantation through lens exchange using monofocal or alternative multifocal IOLs. *Acta Ophthalmol.* 2024;102(7):e1040–e1049. Epub 2024 May 23. PMID: 38780148. doi:10.1111/aos.16720
100. Frings A, Richard G, Steinberg J, Druchkiv V, Linke SJ, Katz T. LASIK and PRK in hyperopic astigmatic eyes: is early retreatment advisable? *Clin Ophthalmol.* 2016;10:565–570. PMID: 27099463; PMCID: PMC4820209. doi:10.2147/OPTH.S99098

101. Salerno LC, Tiveron MC, Alió JL. Multifocal intraocular lenses: types, outcomes, complications and how to solve them. *Taiwan J Ophthalmol.* 2017;7(4):179–184. PMID: 29296549; PMCID: PMC5747227. doi:10.4103/tjo.tjo_19_17
102. Ito M, Watabe M, Obikane K, Yamamoto T, Yukawa S. Precision refraction methodology for LASIK enhancement after trifocal intraocular lens implantation: clinical outcomes and technique. *J Cataract Refract Surg.* 2026;52(1):52–60. PMID: 40827888; PMCID: PMC12777586. doi:10.1097/j.jcrs.0000000000001765
103. Wongsakhuang J. Optimization of the ocular surface prior to cataract surgery using cryopreserved amniotic membrane. *Clin Ophthalmol.* 2025;19:1975–1983. PMID: 40589536; PMCID: PMC12206894. doi:10.2147/OPHTH.S525438
104. Nijkamp MD, Nuijts RM, Borne B, Webers CA, Van Der Horst F, Hendrikse F. Determinants of patient satisfaction after cataract surgery in 3 settings. *J Cataract Refract Surg.* 2000;26(9):1379–1388. PMID: 11020624. doi:10.1016/s0886-3350(00)00501-0
105. Alió JL, Belda JI, Artola A, García-Lledó M, Osman A. Contact lens fitting to correct irregular astigmatism after corneal refractive surgery. *J Cataract Refract Surg.* 2002;28(10):1750–1757. PMID: 12388023. doi:10.1016/s0886-3350(02)01489-x
106. Winn B, Ackerley RG, Brown CA, Murray FK, Prais J, St John MF. Reduced aniseikonia in axial anisometropia with contact lens correction. *Ophthalmic Physiol Opt.* 1988;8(3):341–344. PMID: 3077649.
107. Qiao J, Yan X. Emerging treatment options for meibomian gland dysfunction. *Clin Ophthalmol.* 2013;7:1797–1803. PMID: 24043929; PMCID: PMC3772773. doi:10.2147/OPHTH.S33182
108. Karahan E, Er D, Kaynak S. An overview of Nd:YAG laser capsulotomy. *Med Hypothesis Discov Innov Ophthalmol.* 2014;3(2):45–50. PMID: 25738159; PMCID: PMC4346677.
109. Elgohary MA, Beckingsale AB. Effect of posterior capsular opacification on visual function in patients with monofocal and multifocal intraocular lenses. *Eye.* 2008;22(5):613–619. PMID: 17187030. doi:10.1038/sj.eye.6702661
110. Kanclerz P, Wang X. Postoperative capsular bag distension syndrome - risk factors and treatment. *Semin Ophthalmol.* 2019;34(6):409–419. Epub 2019 Jul 12. PMID: 31298075. doi:10.1080/08820538.2019.1640750
111. Zeppieri M, Marsili S, Enaholo ES, et al. Optical Coherence Tomography (OCT): a brief look at the uses and technological evolution of ophthalmology. *Medicina.* 2023;59(12):2114. PMID: 38138217; PMCID: PMC10744394. doi:10.3390/medicina59122114
112. Sáles CS, Manche EE. Managing residual refractive error after cataract surgery. *J Cataract Refract Surg.* 2015;41(6):1289–1299. PMID: 26096522. doi:10.1016/j.jcrs.2015.05.001
113. Oshika T, Inamura M, Inoue Y, et al. Incidence and outcomes of repositioning surgery to correct misalignment of toric intraocular lenses. *Ophthalmology.* 2018;125(1):31–35. Epub 2017 Aug 18. PMID: 28827044. doi:10.1016/j.ophtha.2017.07.004
114. Kawahara A. Predicting residual astigmatism in cataract surgery. *Vision.* 2022;6(4):70. PMID: 36548932; PMCID: PMC9785719. doi:10.3390/vision6040070
115. Stern B, Gatinel D. Presbyopia correction in lens replacement surgery: a review. *Clin Exp Ophthalmol.* 2025;53(6):668–681. PMID: 40295166; PMCID: PMC12326228. doi:10.1111/ceo.14535
116. Verdonck T, Werner L, Ni Dhubhghaill S, Tassignon MJ. Clinical and surgical outcome of a supplementary multifocal intraocular lens implanted with a bag-in-the-lens intraocular lens: 5-year follow-up. *Ophthalmic Res.* 2021;64(3):503–511. PMID: 33326968. doi:10.1159/000513790
117. Yahalomi T, Achiron A, Arnon R, Stanescu N, Pikkil J. Dry Eye Disease following LASIK, PRK, and LASEK: an observational cross-sectional study. *J Clin Med.* 2023;12(11):3761. PMID: 37297956; PMCID: PMC10253504. doi:10.3390/jcm12113761
118. Jones M, Terveen DC, Berdahl JP, Thompson V, Kramer BA, Ferguson TJ. Clinical outcomes of the light-adjustable lens in eyes with a history of prior corneal refractive surgery. *J Cataract Refract Surg.* 2024;50(9):936–941. PMID: 38736178; PMCID: PMC11338023. doi:10.1097/j.jcrs.0000000000001481
119. Wei H, Zhou L, Huang Y, Liu Y, Sun L. Knowledge, attitudes, and practices of adult patients with myopia toward refractive surgery and postoperative medications: a cross-sectional study. *Front Med Lausanne.* 2026;13:1759008. PMCID: PMC12967940. doi:10.3389/fmed.2026.1759008
120. Park CY. Factors affecting postoperative satisfaction after presbyopia-correcting intraocular lens. *J Clin Med.* 2026;15(1):336. PMID: 41517585; PMCID: PMC12786824. doi:10.3390/jcm15010336
121. Casemore RK, Wolffsohn JS, Utheim TP, Reppe S, Aass HCD, Dutta D. A prospective, longitudinal study to assess progression of ocular surface signs, tear cytokines and protein profiles in young adults. *Ocul Surf.* 2025;37:57–67. PMID: 40015455. doi:10.1016/j.jtos.2025.02.011
122. Parajuli S, Dhakhwa P, Adhikary R. Deferring postoperative follow-up visits up to 4 weeks after uneventful cataract surgery in a tertiary level eye hospital: protocol for a prospective, quantitative, experimental control study. *JMIR Res Protoc.* 2023;12:e48616. PMID: 37651180; PMCID: PMC10502588. doi:10.2196/48616
123. Starr CE, Gupta PK, Farid M, et al. ASCRS Cornea Clinical Committee. An algorithm for the preoperative diagnosis and treatment of ocular surface disorders. *J Cataract Refract Surg.* 2019;45(5):669–684. PMID: 31030780. doi:10.1016/j.jcrs.2019.03.023
124. Gatinel D, Debellemanière G, Saad A, Rampat R. Theoretical relationship among effective lens position, predicted refraction, and corneal and intraocular lens power in a pseudophakic eye model. *Transl Vis Sci Technol.* 2022;11(9):5. PMID: 36069859; PMCID: PMC9465937. doi:10.1167/tvst.11.9.5
125. Gurnani B, Kaur K. Corneal cross-linking for keratoconus: a global economic and clinical perspective. *J Med Econ.* 2025;28(1):2119–2124. PMID: 41320236. doi:10.1080/13696998.2025.2587416
126. Álvarez-García MT, Fuente-García C, Muñoz-Puyol C, Piñero DP. Clinical outcomes with extended depth of focus intraocular lenses in cases in which multifocal lenses are not primarily recommended. *J Ophthalmol.* 2023;2023:8814627. PMID: 37362313; PMCID: PMC10289873. doi:10.1155/2023/8814627

Clinical Optometry

Publish your work in this journal

Clinical Optometry is an international, peer-reviewed, open access journal publishing original research, basic science, clinical and epidemiological studies, reviews and evaluations on clinical optometry. All aspects of patient care are addressed within the journal as well as the practice of optometry including economic and business analyses. Basic and clinical research papers are published that cover all aspects of optics, refraction and its application to the theory and practice of optometry. The manuscript management system is completely online and includes a very quick and fair peer-review system, which is all easy to use. Visit <http://www.dovepress.com/testimonials.php> to read real quotes from published authors.

Submit your manuscript here: <https://www.dovepress.com/clinical-optometry-journal>

Dovepress

Taylor & Francis Group