

# Hunting Firearm Induced Optic Nerve Transection

Valerio Calabresi\*, Alberto Cuccu , Claudia Corda, Giuseppe Giannaccare 

Eye Clinic, Department of Surgical Sciences, University of Cagliari, Cagliari, Italy

\*These authors contributed equally to this work

Correspondence: Giuseppe Giannaccare, Eye Clinic, Department of Surgical Sciences, University of Cagliari, Via Università 40, Cagliari, CA, 09124, Italy, Email giuseppe.giannaccare@unica.it

**Abstract:** Penetrating ocular trauma caused by firearms represents a severe ophthalmic emergency and is frequently associated with poor visual outcomes. We report the case of a 41-year-old man who presented with complete loss of visual acuity (no light perception) after a penetrating injury to the right eye sustained during a hunting accident involving a low-velocity firearm. Initial ophthalmic examination showed a full-thickness nasal scleral perforation with vitreous prolapse, mild corneal oedema, and limited fundus visualization due to dense vitreous haemorrhage. A relative afferent pupillary defect of the right eye was present. Urgent orbital computed tomography demonstrated vitreous hemorrhage with intravitreal and peri-optic nerve air, as well as a 5-mm metallic pellet lodged within the intraconal fat near the orbital apex, without associated orbital fractures. The patient underwent urgent primary surgical repair within 6 hours of trauma, followed by intravitreal broad-spectrum antibiotic prophylaxis. Given the deep intraconal location of the pellet and the absence of compressive or infectious complications, the foreign body was left in situ to avoid the risks related to a surgical procedure in this area. Postoperatively, vision remained null and a traumatic inferior retinal detachment was diagnosed one week postoperatively. Observation was preferred to vitreoretinal surgical repair and the retinal picture remained stable at 1-month follow-up visit. This case highlights the role of computed tomography in penetrating ocular trauma. Integrating radiological and clinical findings is crucial to support diagnosis and prognosis as well as to avoid unnecessary surgical interventions.

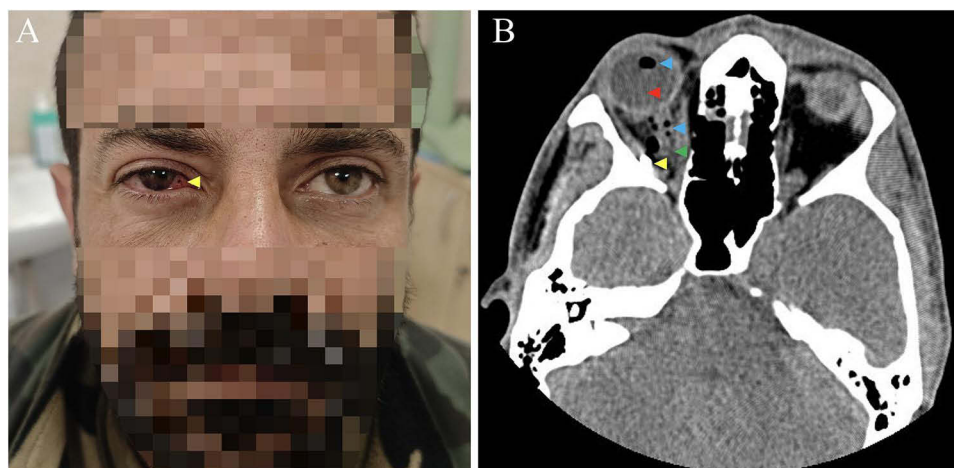
**Keywords:** computed tomography, firearm-related injury, penetrating ocular trauma, optic nerve injury, trauma

## Introduction

Penetrating ocular trauma represents a severe ophthalmic emergency and remains a leading cause of irreversible visual loss worldwide, particularly in young and working-age adults. Open globe injuries caused by firearms are associated with extensive ocular and orbital damage and poor visual outcomes, even when low-velocity projectiles such as hunting pellets are involved.<sup>1</sup> The severity of injury depends on multiple factors, including the mechanism of trauma, the trajectory of the projectile, and associated posterior segment or optic nerve involvement.<sup>2</sup> Computed tomography (CT) is the imaging modality of choice in acute settings, allowing rapid assessment, detection of retained intraorbital foreign bodies, and evaluation of orbital and optic nerve involvement. In particular, indirect CT signs such as peri-optic nerve air, foreign bodies located near the orbital apex, and disruption of the normal optic nerve contour may indicate severe or complete optic nerve injury, a condition associated with an extremely poor visual prognosis.<sup>3</sup> In such cases, imaging plays a crucial role not only in diagnosis but also in guiding management decisions, avoiding unnecessary interventions aimed at visual recovery.

## Case Presentation

A 41-year-old man presented to the emergency department with a penetrating injury to the right eye sustained during a hunting accident involving a low-velocity firearm. On initial examination, the right eye showed marked conjunctival hyperaemia and a full-thickness nasal scleral perforation with vitreous prolapse. The cornea was mildly oedematous, the iris appeared stretched at the 5 o'clock position, and the crystalline lens was in situ (Figure 1A). Visual acuity was



**Figure 1** Smartphone picture and orbital computed tomography of hunting firearm eye injury. **(A)** Smartphone picture of ocular injury with low-velocity gunshot penetrating the sclera (yellow arrow). **(B)** Orbital computed tomography showing posterior vitreous hemorrhage (red arrow), intravitreal and peri-optic nerve air (blue arrow), metallic intraconal foreign body (yellow arrow), suggestive of optic nerve transection (green arrow).

completely abolished (no light perception), and intraocular pressure measured 12 mmHg. A relative afferent pupillary defect of the right eye was present. Fundus examination was difficult due to dense vitreous haemorrhage. Ocular motility was preserved, with normal ductions and versions. Examination of the left eye was unremarkable, with a full best-corrected visual acuity, normal intraocular pressure, and lack of abnormalities at fundus examination.

Urgent orbital CT was performed, revealing posterior vitreous haemorrhage with intravitreal air, multiple air bubbles tracking along the optic nerve sheath, and heterogeneous stranding of the intraconal fat. A 5-mm metallic foreign body, consistent with a hunting pellet, was identified within the intraconal fat adjacent to the lateral orbital apex, without associated orbital fractures or signs of globe collapse (Figure 1B). These findings were highly suggestive of severe optic nerve injury.<sup>3,4</sup> Based on the clinical and radiological findings, a diagnosis of open globe injury with suspected optic nerve transection was reached. The patient underwent urgent surgical repair within 6 hours of trauma, consisting of conjunctival peritomy, removal of prolapsed vitreous from the scleral wound, and primary closure of the sclera and conjunctiva. Intravitreal vancomycin and ceftazidime were administered for endophthalmitis prophylaxis. Systemic antibiotic therapy with intravenous ceftriaxone was continued for the next 48 hours. The intraorbital pellet was left in situ due to its deep intraconal location near the orbital apex and the absence of compressive, infectious, or inflammatory complications, as surgical removal carries a high risk of further optic nerve damage of iatrogenic nature.<sup>5</sup>

One week later, postoperative examination showed well-positioned sutures and a clear cornea. Visual acuity remained lost (no light perception), and intraocular pressure measured 9 mmHg. Fundus examination revealed a traumatic inferior retinal detachment with a full-thickness retinal break, associated with persistent vitreous haemorrhage and intravitreal air. Given the irreversible visual loss and poor prognosis, a conservative approach was adopted, and no vitreoretinal surgery was pursued. At 1-month follow-up, the ocular findings remained unchanged, with stable intraocular pressure and no signs of infection or other complications.

## Discussion

Firearm-related penetrating ocular injuries are associated with high rates of globe rupture, retinal detachment, endophthalmitis, and optic nerve damage.<sup>6</sup> Although hunting pellets are low-velocity projectiles, they may still cause devastating open-globe and posterior orbital injury, particularly when the trajectory involves the posterior segment or orbital apex. Traumatic optic neuropathy may result from direct optic nerve transection, compression, or indirect concussive mechanisms. Complete optic nerve transection is rare but carries an invariably poor visual prognosis.<sup>7,8</sup>

In the acute setting, CT imaging is essential for identifying indirect signs of optic nerve injury, such as peri-optic nerve air and metallic foreign bodies near the orbital apex.<sup>3,4</sup> In the case presented herein, the presence of air tracking

along the optic nerve sheath, combined with the early loss of light perception, strongly supported optic nerve injury and raised suspicion for optic nerve transection, allowing early prognostication and appropriate patient counselling.

Management of retained intraorbital foreign bodies remains controversial and must be individualized. In fact, there is the need to balance the potential benefits of foreign body removal against the risk of further iatrogenic damage, particularly when the foreign body is deeply lodged within the intraconal space or at the orbital apex. Generally, organic foreign bodies and cases complicated by infection, compression, or progressive inflammation warrant surgical removal. By contrast, inert metallic foreign bodies lodged deep within the intraconal space or at the orbital apex may be observed when asymptomatic, because surgical extraction carries substantial risk of further neuro-ophthalmic injury. The decision to leave the pellet in situ in our patient was therefore based on an individualized risk-benefit assessment and was consistent with the general principles reported in the literature.

In eyes presenting with no light perception and strongly suspected severe optic nerve injury, aggressive vitreoretinal surgery is unlikely to provide visual benefit and may expose the patient to unnecessary surgical risks.<sup>5,9</sup> In the present case, a conservative approach focused on preserving ocular integrity and ensuring patient comfort was therefore considered the most appropriate individualized management strategy.

## Conclusion

This case highlights the pivotal role of CT in the evaluation of penetrating ocular trauma, not only for detecting retained intraorbital foreign bodies but also for identifying imaging features suggestive of severe optic nerve injury, with possible transection. Integration of clinical and radiological findings is essential to establish prognosis, guide management decisions, and avoid unnecessary surgical interventions when meaningful visual recovery appears extremely unlikely. In the present case, the decision to manage conservatively both the retained intraorbital foreign body and the associated retinal detachment was reached not only due to the challenging location of the pellet carrying high intraoperative risks, but also due to the complete vision loss strongly suggestive of severe optic nerve injury, as supported by radiological findings, which made meaningful visual recovery extremely unlikely.

## Ethical Approval and Consent for Publication

Institutional approval was not required for publication of this single case report. Written informed consent for publication of the case details and accompanying images was obtained from the patient.

## Funding

This research did not receive any specific grant from funding agencies in the public, commercial, or not-for-profit sectors.

## Disclosure

The authors declare that they have no conflicts of interest in this work.

## References

1. Shah FQ, Qureshi TS, Nawaz S, Kaushik M. Clinical spectrum and functional outcome of firearm pellet-related eye injuries: a prospective follow-up study. *Injury*. 2022;53(9):2998–3004. doi:10.1016/j.injury.2022.05.051
2. Agrawal R, Wei HS, Teoh S. Prognostic factors for open globe injuries and correlation of ocular trauma score at a tertiary referral eye care centre in Singapore. *Indian J Ophthalmol*. 2013;61(9):502–506. doi:10.4103/0301-4738.119436
3. Cellina M, Cè M, Marziali S, et al. Computed tomography in traumatic orbital emergencies: a pictorial essay-imaging findings, tips, and report flowchart. *Insights Imaging*. 2022;13(1):4. doi:10.1186/s13244-021-01142-y
4. Mehta A, Jain C, Anjum N, Virk RS. Metallic foreign body on the optic nerve head. *BMJ Case Rep*. 2020;13(10):e238443. doi:10.1136/bcr-2020-238443
5. Fulcher TP, McNab AA, Sullivan TJ. Clinical features and management of intraorbital foreign bodies. *Ophthalmology*. 2002;109(3):494–500. doi:10.1016/s0161-6420(01)00982-4
6. Sobaci G, Mutlu FM, Bayer A, Karagül S, Yildirim E. Deadly weapon-related open-globe injuries: outcome assessment by the ocular trauma classification system. *Am J Ophthalmol*. 2000;129(1):47–53. doi:10.1016/s0002-9394(99)00254-8
7. Chen B, Zhang H, Zhai Q, Li H, Wang C, Wang Y. Traumatic optic neuropathy: a review of current studies. *Neurosurg Rev*. 2022;45(3):1895–1913. doi:10.1007/s10143-021-01717-9
8. Kumaran AM, Sundar G, Chye LT. Traumatic optic neuropathy: a review. *Craniofac Trauma Reconstr*. 2015;8(1):31–41. doi:10.1055/s-0034-1393734
9. Kim AH, Kim J, Nayer ZH, Plum W, Glass LRD. Management of traumatic globe subluxation with optic nerve and extraocular muscle transection. *Orbit*. 2024;43(6):801–806. doi:10.1080/01676830.2023.2283185

### International Medical Case Reports Journal

### Publish your work in this journal

The International Medical Case Reports Journal is an international, peer-reviewed open-access journal publishing original case reports from all medical specialties. Previously unpublished medical posters are also accepted relating to any area of clinical or preclinical science. Submissions should not normally exceed 2,000 words or 4 published pages including figures, diagrams and references. The manuscript management system is completely online and includes a very quick and fair peer-review system, which is all easy to use. Visit <http://www.dovepress.com/testimonials.php> to read real quotes from published authors.

Submit your manuscript here: <https://www.dovepress.com/international-medical-case-reports-journal-journal>

**Dovepress**

Taylor & Francis Group