

Visual, Refractive, Functional, and Patient Satisfaction Outcomes After Implantation of a New Trifocal Diffractive Intraocular Lens [Corrigendum]

Mendicutte J, Lauzirika G, Illarramendi I, Martínez-Soroya I. *Clin Ophthalmol.* 2024;18:2785–2795. <https://doi.org/10.2147/OPTH.S480311>

After publication, the authors have identified two technical/representation errors in Figures 1 and 2 on page 2788 of the published article.

The graphs originally published in Figure 2 did not correspond to the descriptions provided in the figure legend. Specifically, Figure 2 represented monocular graphs (A–C) and binocular graphs (D–F) of cumulative visual acuity measurements at 6 months, respectively. However, the study intended to present a comparison between monocular 1-month and 6-month cumulative visual acuity outcomes. To maintain consistency with the legend the authors have replaced the incorrect graphs with the intended data sets in Figure 2.

A second discrepancy was then identified between Figure 1A and E and the corrected Figure 2A and D, which should have been identical as they represent the same cumulative eye data for monocular CDVA/UCDVA at 1 month and 6 months. Consequently, Figure 1 has been updated to reflect this correction, ensuring both graphs of Figure 1A/E and Figure 2A/D are now mathematically, visually and conceptually consistent.

The authors advise Figure 2 was always generated with original LogMAR values (without any conversion). This is the reason why Figure 1 and the corrected Figure 2 did not initially match. Furthermore, all visual acuities conversions were reviewed, and no more mismatches were found.

The correct Figures 1 and 2 are shown below.

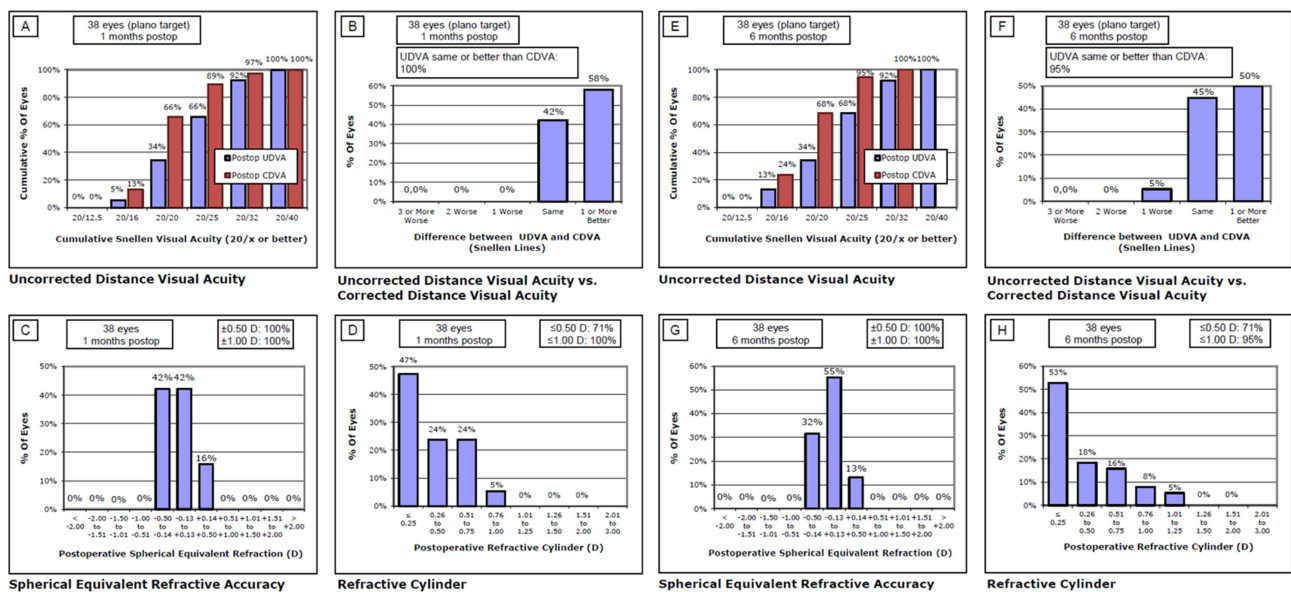


Figure 1 Monocular refractive outcomes at 1- and 6-month post-op. (A–D) correspond with 1-month outcomes, and (E–H) correspond with 6-month outcomes.

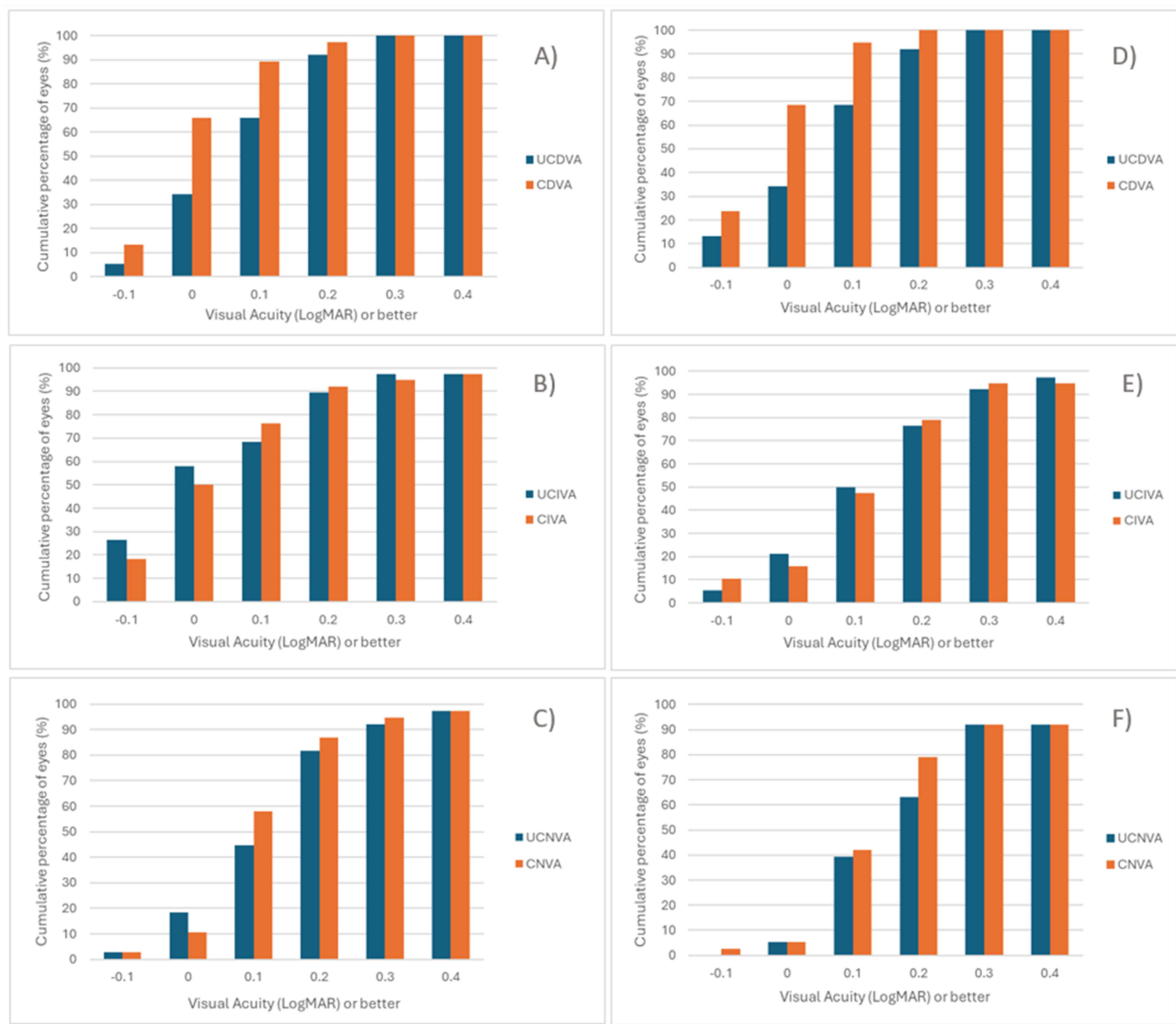


Figure 2 Cumulative distribution of visual acuity at 1 month and 6 months post-op at all distances. (A–C) correspond to monocular visual acuity at 1 month post-op; and (D–F) correspond to monocular visual acuity at 6 months post-op.

The authors confirm that these changes were due to unintentional errors during the data processing for image assembly stages. These corrections are strictly for the accuracy of visual presentation and do not alter the study's original experimental data, findings, or clinical conclusions.

The authors sincerely apologize to the Journal and the readers for any inconvenience this error may have caused.

Clinical Ophthalmology

Publish your work in this journal

Clinical Ophthalmology is an international, peer-reviewed journal covering all subspecialties within ophthalmology. Key topics include: Optometry; Visual science; Pharmacology and drug therapy in eye diseases; Basic Sciences; Primary and Secondary eye care; Patient Safety and Quality of Care Improvements. This journal is indexed on PubMed Central and CAS, and is the official journal of The Society of Clinical Ophthalmology (SCO). The manuscript management system is completely online and includes a very quick and fair peer-review system, which is all easy to use. Visit <http://www.dovepress.com/testimonials.php> to read real quotes from published authors.

Submit your manuscript here: <https://www.dovepress.com/clinical-ophthalmology-journal>

Dovepress
Taylor & Francis Group