




Combined PRP and Contact Lens for Corneal Ulcer Perforation: A Case Report

Mukhammadbektosh Khaydarov ^{1,2}, Javokhir Ibatov ^{1,3}, Temur Tillakhujaev^{1,4},
Jamshid Mamatov ^{1,3}

¹School of Medicine, Central Asian University, Tashkent, Uzbekistan; ²Department of Surgery, AKFA Medline University Hospital, Tashkent, Uzbekistan; ³Department of Ophthalmology, AKFA Medline University Hospital, Tashkent, Uzbekistan; ⁴Department of Head and Neck, AKFA Medline University Hospital, Tashkent, Uzbekistan

Correspondence: Jamshid Mamatov, Email j.mamatov@akfamedline.uz

Introduction: Corneal ulcerations leading to perforations are severe ophthalmologic conditions posing significant risks to vision, especially in resource-limited settings where advanced surgical interventions are inaccessible. This report describes a novel, minimally invasive approach using platelet-rich plasma (PRP) therapy combined with therapeutic contact lens application to manage a corneal ulcer with perforation.

Case Presentation: A 56-year-old female agricultural worker presented with a progressive, severe corneal ulcer with perforation that was unresponsive to conventional antiviral, antibiotic, and steroid treatments. Given the patient's refusal of invasive procedures and logistical constraints in Uzbekistan, treatment involved subconjunctival PRP injections administered on days 2, 4, and 6, along with PRP eye drops four times daily for one month. A therapeutic silicone-hydrogel contact lens was applied to protect and stabilize the ocular surface. Rapid clinical improvement was observed, with a 43% reduction in ulcer size within 24 hours and significant pain relief by day 3. Near-complete epithelialization was achieved by the one-month follow-up, with sustained visual acuity improvement from 0.1 to 0.4 maintained at two years.

Conclusion: Combining PRP therapy with therapeutic contact lens application is an effective, minimally invasive treatment for severe corneal ulcers with perforation, particularly advantageous in settings lacking advanced surgical options. This case highlights the potential for broader application of accessible and cost-effective therapies, warranting further clinical research to confirm efficacy and safety in larger patient populations.

Keywords: PRP, contact lens, corneal ulceration, perforation

Introduction

Corneal ulcers are a significant cause of ocular morbidity worldwide, with an estimated 1.5 to 2 million new cases occurring annually.¹ In developing countries, corneal ulcers leading to perforation contribute substantially to unilateral blindness, particularly in rural areas where access to prompt and adequate medical care is limited.² Corneal perforations represent a severe complication of corneal ulcers, posing an immediate threat to ocular integrity and vision. They can result from various etiologies, including infectious agents such as bacteria, fungi, viruses, and protozoa, or from non-infectious causes like autoimmune disorders and trauma.^{3,4}

Management of corneal perforations is challenging and often requires surgical interventions to restore structural integrity and prevent further complications. Conventional treatments include the use of tissue adhesives, amniotic membrane transplantation, and corneal transplantation (keratoplasty), which aim to re-establish corneal integrity and preserve visual function.⁵ However, these advanced treatments may not be readily available in resource-limited settings due to lack of infrastructure, surgical expertise, or donor tissue availability.⁶ Consequently, there is a critical need for accessible, minimally invasive therapies that can effectively promote corneal healing and preserve vision in these contexts.

Platelet-rich plasma (PRP) therapy has emerged as a promising regenerative treatment in ophthalmology. PRP is an autologous blood product enriched with platelets, which release a high concentration of growth factors and cytokines that enhance tissue repair and regeneration.^{7,8} It has been successfully applied in various ocular surface disorders, including persistent epithelial defects and neurotrophic keratitis, demonstrating its potential to accelerate epithelialization and reduce inflammation.⁹ Additionally, therapeutic contact lenses are utilized to protect the corneal surface, promote healing, and provide symptomatic relief in corneal ulcers.¹⁰

Several studies have explored the combined use of PRP therapy and therapeutic contact lenses in managing corneal ulcers and perforations. Use of an autologous fibrin membrane combined with an eye platelet-rich plasma (E-PRP) clot to seal corneal perforations, reportedly demonstrating safety and efficacy in 11 patients. The technique involved placing an E-PRP clot over the perforation, covering it with a fibrin membrane, and securing it with sutures, resulting in successful closure and healing of the perforations without complications during a 3-month follow-up period.¹¹

Alvarado-Villacorta et al described a novel approach combining solid-activated PRP with silicone-hydrogel soft contact lenses for treating non-healing corneal ulcers. In their case series of three patients, a PRP clot was applied directly onto the corneal ulcer and covered with a soft contact lens. All patients achieved complete re-epithelialization within two weeks, with no recurrences or signs of infection throughout the follow-up period, highlighting the potential efficacy of this combined therapy.¹²

Despite promising outcomes, the use of platelet-rich plasma (PRP) for corneal ulcers is limited by significant gaps in standardization—especially regarding preparation protocols, dosage, delivery forms, and quality control.^{7,13} Current studies vary in centrifugation parameters, anticoagulants, application frequency, and growth factor concentrations, making comparisons and reproducibility difficult.^{7,13–15} This case report addresses these gaps by presenting a standardized, multimodal approach combining subconjunctival PRP injections, topical PRP eye drops, and a therapeutic contact lens—particularly valuable in resource-limited settings.^{15,16} The protocol includes detailed preparation and administration steps, demonstrating a feasible, replicable alternative to surgical interventions.^{14,16} It also contributes early safety and efficacy data for this specific combination therapy in corneal perforation management.¹⁶

Case Report/Case Presentation

Patient Information

A 56-year-old female agricultural worker from a rural area in Uzbekistan presented to AKFA Medline University Hospital with a two-month history of progressive pain, redness, burning, itching, and decreased vision in her left eye (OS). She reported a remote history of ocular trauma several years prior but could not recall the specifics. Her occupation involved frequent exposure to dust, debris, and environmental pollutants. The patient had previously consulted multiple local physicians and was prescribed antiviral therapy, followed by antibiotics and steroids, without improvement. Her condition worsened, leading to a corneal ulcer with perforation.

Her past medical history was unremarkable, with no known systemic illnesses such as diabetes mellitus, autoimmune disorders, or immunodeficiency. She denied any history of herpetic infections or prior ocular surgeries. Family history was non-contributory. She was not on any systemic medications and had no known drug allergies.

Clinical Findings

On presentation, the patient's uncorrected visual acuity was 0.6 (decimal scale) in the right eye (OD) and 0.3 in the left eye (OS). Slit-lamp examination of OS revealed a paracentral corneal infiltrate measuring 0.2×0.2 mm with blurred borders and significant stromal thinning. A perforation was observed in the region of the infiltrate, with the absence of an anterior chamber in the affected area. The pupil was irregularly shaped, with posterior synechiae at the 10 o'clock position, and appeared pulled toward the perforation site as shown in [Figure 1](#). The iris showed extensive neovascularization. The lens showed early opacification. The posterior segment was unremarkable. The intraocular pressure (IOP) in OD was 12 mmHg, but IOP could not be measured in OS due to the perforation.

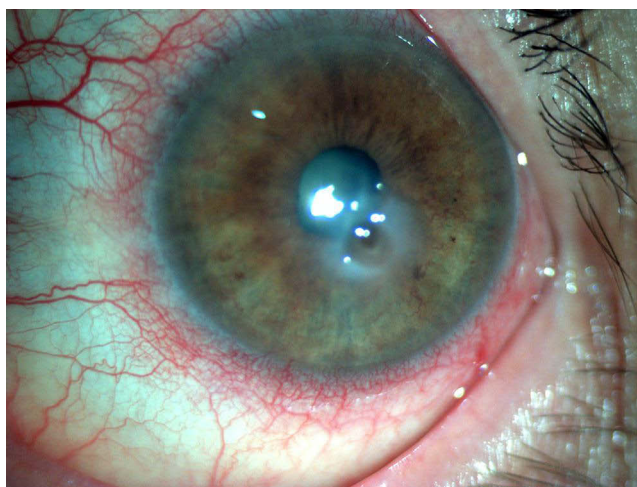


Figure 1 Slit-lamp photograph of the left eye showing a corneal ulcer with perforation, central corneal opacity, irregular pupil due to iris prolapse, and surrounding conjunctival injection indicative of significant inflammation and disruption of corneal integrity.

Diagnostic Assessment

Given the acute presentation and inadequate response to previous therapies, the differential diagnosis encompassed several conditions. Bacterial keratitis was considered unlikely due to the patient's poor response to prior antibiotic treatment and the absence of purulent discharge. Fungal keratitis was also contemplated; however, the patient lacked a history of agricultural injuries involving organic material, reducing the likelihood of this etiology. Herpetic keratitis emerged as a plausible diagnosis given the presence of corneal ulceration and iris involvement; nonetheless, the patient's lack of response to antiviral therapy cast doubt on this possibility. An autoimmune-associated corneal melt was evaluated due to the severity of the condition and its progression despite previous interventions.

Corneal scraping and cultures were deferred to avoid exacerbating the perforation, and the patient was reluctant to undergo invasive procedures. Additionally, the extensive prior use of antibiotics likely diminished the reliability of culture results. Systemic workup for autoimmune conditions was not performed due to resource limitations.

Therapeutic Intervention

Given the limited availability of advanced surgical options, including emergent keratoplasty and amniotic membrane transplantation, and the patient's refusal of invasive procedures, a combination therapy involving platelet-rich plasma (PRP) and a therapeutic contact lens was selected.

- Type of centrifuge used: A standard swing-out rotor centrifuge such as the Eppendorf 5702 was employed, which allows gentle and consistent separation of blood components.
- Tubing or collection kit utilized: Blood was drawn into sterile vacuum tubes containing 3.2% sodium citrate as an anticoagulant. No commercial PRP kit was used to reduce costs and ensure local replicability.
- Total volume of blood drawn: Approximately 20 mL of venous blood was collected from each patient.
- Centrifugation steps:
 - First spin (soft spin): Blood was centrifuged at 1,100 rpm for 10 minutes to separate the red blood cells from the plasma.
 - Second spin (hard spin): The plasma supernatant (containing the buffy coat) was transferred to a new sterile tube and centrifuged at 1,500 rpm for another 10 minutes to concentrate the platelets at the bottom.
- Number of vials produced: After the second spin, the upper two-thirds of the platelet-poor plasma (PPP) was removed. The remaining lower one-third (~3–4 mL), containing concentrated platelets, was gently resuspended to form PRP. The final product was divided into:

- Two sterile droppers for topical use (administered four times daily),
 - And 0.2–0.3 mL aliquots for subconjunctival injections (administered on days 2, 4, and 6).
- Sterility and application method: All procedures were performed under sterile conditions. The eye was disinfected with 10% povidone-iodine (Betadine) for 3 minutes and rinsed with sterile saline prior to subconjunctival injection, which was performed under topical anesthesia. This preparation method ensured a reproducible, cost-effective, and resource-conscious approach, suitable for use in rural or under-equipped clinical environments.
 - Therapeutic Contact Lens: A silicone-hydrogel therapeutic contact lens was placed on day 1 to protect the corneal surface, reduce friction, and promote epithelialization.
 - Adjunctive Treatment: Preservative-free lubricating eye drops and a combination ophthalmic solution containing 0.8% tropicamide and 5% phenylephrine were administered to manage the prolapsed iris and prevent synechiae formation. The patient was hospitalized for eight days and monitored daily for signs of healing and complications.

Follow-Up and Outcomes

By the fourth day, a significant reduction in ulcer size and depth was noted, with a 43% decrease in the area of the ulcer and visible improvements in epithelialization as shown in [Figure 2](#). The therapeutic contact lens remained in place during the hospital stay and was removed on the eighth day. The patient reported significant pain relief by day 3 and no adverse effects.

OCT imaging confirmed restoration of the corneal surface. Notably, at presentation the iris was prolapsed through the corneal perforation ([Figure 1](#)), whereas on follow-up anterior segment OCT images no iris tissue was seen in the corneal defect. This indicates that as healing occurred, the small iris prolapse retracted or became sealed behind the repaired cornea, resulting in a normalized anterior chamber anatomy on later imaging.

The patient was discharged with instructions to continue using PRP eye drops twice daily for one month. At the one-month follow-up, the corneal ulcer was nearly completely epithelialized, with no residual stromal thinning or inflammation as shown in [Figure 3](#). Visual acuity in OS improved to 0.2 (20/200) one month following treatment, 0.3 (20/70) by 6 months, and 0.4 (20/50) on one-year follow-up and 0.4 (20/50) on two-year follow-up.

At the six-month follow-up, the therapeutic outcome remained stable, with no evidence of recurrence or complications as shown in [Figure 4](#). The ocular surface was clear, and the patient was satisfied with the improvement in vision and comfort. At the two-year follow-up, OCT imaging demonstrated sustained corneal integrity with no evidence of pathological changes as shown in [Figure 5](#)

Treatment Rationale

The combination of PRP therapy with a therapeutic contact lens was chosen as a minimally invasive and practical alternative suited for a resource-limited setting. PRP delivers concentrated growth factors that promote corneal healing, while the contact lens provides a protective barrier that supports epithelialization. In this case, advanced surgical interventions such as keratoplasty and amniotic membrane transplantation were not feasible due to the lack of donor tissue, surgical infrastructure, and appropriate storage facilities. Additionally, the patient declined invasive procedures. These constraints necessitated a non-surgical, yet effective solution. PRP was prepared using basic centrifugation equipment, making it feasible even in low-resource environments. As an autologous product, it eliminated concerns related to donor availability or immune reactions. The therapeutic contact lens, being readily accessible and affordable, further enhanced the treatment by stabilizing the ocular surface. This case underscores how limitations in resources and patient preference can catalyze innovative, accessible care strategies. The favorable outcome supports the use of combined PRP and contact lens therapy as a viable approach for corneal ulcers with perforation, especially in underserved regions.

Discussion

This case report highlights the successful management of a severe corneal ulcer with perforation using a combination of platelet-rich plasma (PRP) therapy and a therapeutic contact lens. The treatment approach resulted in rapid

High Definition Images: Anterior Segment 5 Line Raster

OD ○ | ● OS

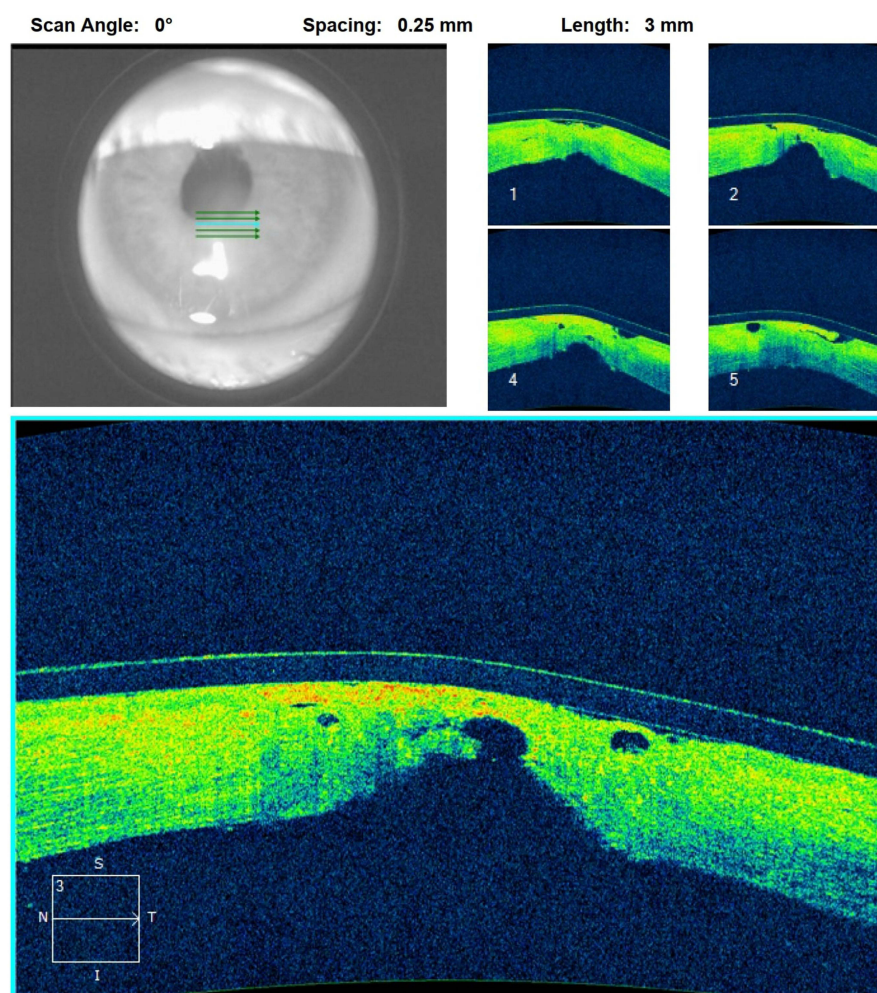


Figure 2 High-definition AS-OCT images of the left eye on Day 4 post-PRP treatment, demonstrating decreased corneal thinning, reduced epithelial defects, and initial stromal healing.

epithelialization, reduced inflammation, and sustained healing, demonstrating its potential as a minimally invasive alternative to conventional surgical interventions, especially in resource-limited settings.

One notable clinical observation was the development of iris neovascularization in the affected eye. Although neovascularization of the iris (rubeosis iridis) is most commonly associated with chronic retinal ischemia in conditions like diabetic retinopathy, it can also occur due to prolonged anterior segment inflammation or ischemia in severe corneal disease. Chronic corneal ulcers and inflammation upregulate angiogenic factors such as vascular endothelial growth factor (VEGF), which induce abnormal blood vessel growth on the iris.¹⁷ In our patient, fine iris vessels were observed, likely reflecting the chronicity and severity of the corneal ulcer. The presence of iris neovascularization underscores the compromised state of the ocular environment and can herald further complications (eg, peripheral anterior synechiae or neovascular glaucoma) if the underlying condition remains unmitigated. Its resolution with successful healing of the cornea suggests that improving corneal integrity and reducing inflammation can regress these anterior segment changes.¹⁷

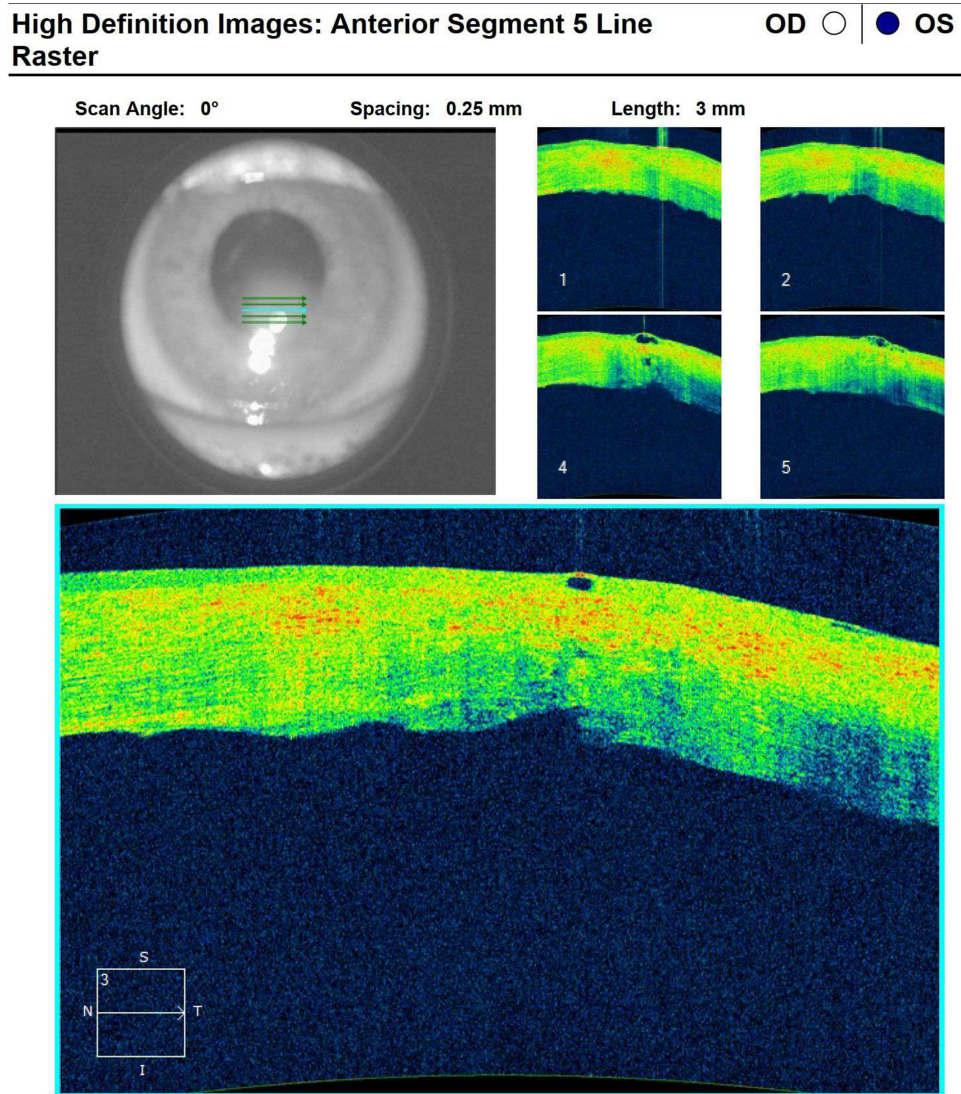


Figure 3 High-definition AS-OCT images of the left eye at one-month post-PRP treatment, illustrating complete epithelial healing and normalized corneal architecture.

Comparison with Conventional Treatments

Conventional treatment options for corneal perforations include tissue adhesives, amniotic membrane transplantation (AMT), and corneal transplantation (keratoplasty). Tissue adhesives like cyanoacrylate glue provide temporary closure for small perforations but often require additional interventions due to their transient nature and potential for complications, such as corneal toxicity and foreign body sensation.^{5,18} AMT has been widely used for promoting epithelialization and reducing inflammation; however, its availability is limited in many regions due to logistical challenges and costs associated with donor tissue.¹⁹ Corneal transplantation, while effective for larger perforations, carries risks such as graft rejection, infection, and delayed healing, which can be exacerbated in resource-limited settings where postoperative care may be inadequate.^{20,21}

Temporary Tarsorrhaphy

Temporary tarsorrhaphy is another conservative treatment option for small corneal perforations. In cases of tiny perforations or impending perforations, partially sewing the eyelids closed can protect the cornea and promote re-epithelialization. This simple procedure can be performed with minimal resources and is often combined with a bandage contact lens and intensive lubrication or topical antibiotics.^{22,23} By reducing eyelid-induced trauma and exposure,

High Definition Images: Anterior Segment 5 Line Raster

OD ○ | ● OS

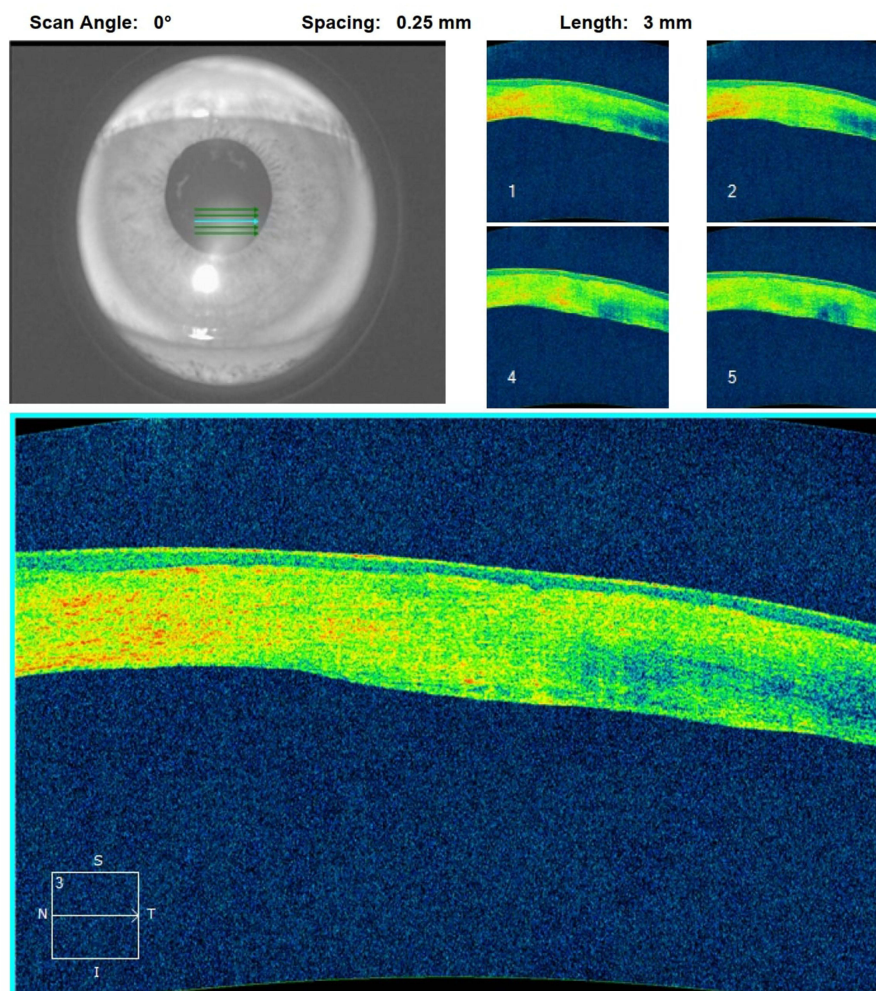


Figure 4 High-definition AS-OCT images of the left eye at six months post-PRP treatment, confirming sustained corneal integrity and absence of pathological changes.

a temporary tarsorrhaphy creates a stable environment that encourages the perforation to seal. This approach has been reported as an accessible alternative when other therapies are not available; however, it has drawbacks. The closed eyelids make it difficult to examine the cornea frequently, and premature opening of the tarsorrhaphy (whether accidental or due to patient non-compliance) can lead to recurrence of the perforation.²³ Despite these limitations, tarsorrhaphy remains a valuable option in resource-poor settings to stabilize the eye until definitive healing occurs or more advanced care can be obtained.²²

Cyanoacrylate Tissue Glue

Cyanoacrylate tissue glue was considered as an alternative for sealing the corneal perforation in this case. Tissue adhesive is a well-established temporizing measure that can rapidly seal perforations up to approximately 3 mm in size, often avoiding the need for immediate surgical intervention.^{22,24} Cyanoacrylate glue has shown initial success rates as high as 86% for small corneal perforations and is relatively accessible in many ophthalmic centers.²² However, we opted not to use cyanoacrylate in our patient due to several reasons. First, there were concerns about exacerbating the inflammation or trapping infectious material under the glue, as cyanoacrylate can sometimes worsen keratitis and cause notable irritation or even pressure spikes.²² Second, in our rural setting, procuring medical-grade corneal adhesive

High Definition Images: Anterior Segment 5 Line Raster

OD ○ | ● OS

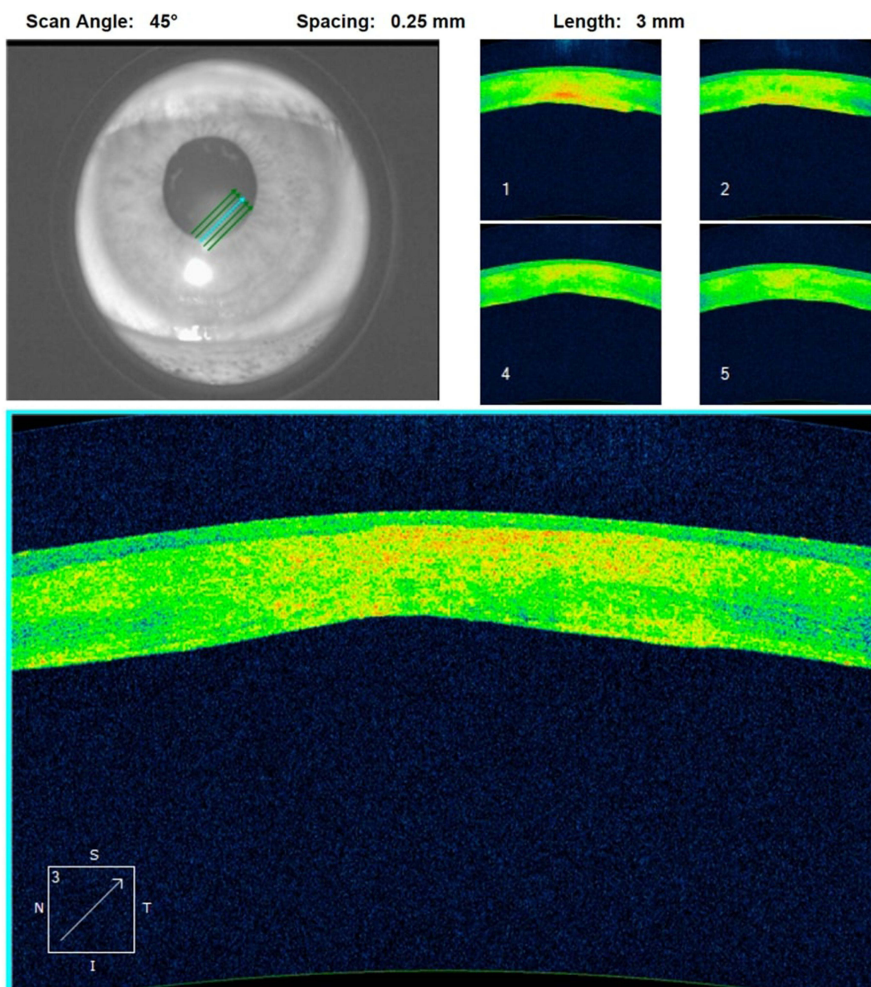


Figure 5 High-definition AS-OCT images of the left eye at 2 years post-PRP treatment, confirming sustained corneal integrity and absence of pathological changes.

promptly was challenging, which made the PRP approach more immediately feasible. Third, the patient preferred to avoid any additional foreign material or procedures after having declined more invasive interventions. Given these considerations, we chose to proceed with PRP therapy in conjunction with a bandage contact lens, aiming to biologically seal the defect and stimulate healing without the potential toxic or inflammatory side effects of cyanoacrylate glue.

In contrast, combining PRP and a therapeutic contact lens offers several advantages. PRP, an autologous product, is readily available and cost-effective, reducing the need for donor materials or advanced surgical facilities. The therapeutic contact lens acts as a protective barrier, stabilizing the ocular surface and enhancing the effects of PRP by maintaining a conducive healing environment. This approach is particularly advantageous in rural or under-resourced settings, where access to advanced surgical care is limited. Advanced surgical interventions, such as emergent keratoplasty, were not feasible due to the unavailability of donor corneal tissue, lack of surgical infrastructure, and the associated financial burden. In Uzbekistan, keratoplasty costs approximately \$5,000, which includes the cost of surgery, donor tissue procurement, and post-operative care. In addition to the high cost, patients often face lengthy waiting times and logistical hurdles in accessing these advanced treatments, further complicating timely care for urgent cases.

In contrast, the cost of three subconjunctival PRP injections combined with one month of PRP eye drops is approximately \$150, representing a fraction of the expense of keratoplasty. PRP preparation requires basic centrifugation

equipment and utilizes the patient's own blood, eliminating the need for donor tissue and reducing associated costs. Furthermore, PRP therapy can be administered promptly, bypassing the delays associated with surgical interventions.

The therapeutic contact lens, which is widely available and affordable, further enhanced the practicality of this approach by providing a protective barrier to support healing without adding significant financial strain.

The marked cost difference between keratoplasty and the PRP-based approach highlights the accessibility and affordability of this novel treatment. By addressing both the financial and logistical barriers to care, the combined use of PRP therapy and therapeutic contact lenses emerges as a viable alternative for managing corneal perforations in resource-limited settings. This case underscores the importance of developing cost-effective and readily deployable therapies to ensure equitable access to care for patients in underserved regions. Future studies should further explore the cost-effectiveness and scalability of this approach to inform healthcare policies and improve treatment accessibility. Although many centres use PRP within 4–6 h, laboratory work shows its key trophic mediators stay stable for at least a few days in the fridge and for months when frozen, making weekly batch preparation practical even in remote clinics.^{25,26}

Mechanisms of Action

PRP's regenerative properties stem from its high concentrations of growth factors, including platelet-derived growth factor (PDGF), transforming growth factor-beta (TGF- β), vascular endothelial growth factor (VEGF), and epidermal growth factor (EGF). These molecules play a pivotal role in promoting cellular proliferation, angiogenesis, and tissue remodeling, which are critical for corneal repair.⁸ Subconjunctival injections deliver PRP directly to the affected area, providing a targeted therapeutic effect that enhances epithelialization and stromal healing. PRP eye drops complement this by offering sustained exposure to growth factors, facilitating continuous ocular surface repair.

Therapeutic contact lenses contribute by creating a stable environment that minimizes mechanical irritation, shields the cornea from environmental insults, and maintains a moist ocular surface. This synergistic effect likely accelerated healing in this case, as evidenced by the rapid reduction in ulcer size and resolution of inflammation.

Comparison with Similar Studies

Previous studies have documented the efficacy of PRP in ocular surface disorders, including persistent epithelial defects, neurotrophic keratitis, and dormant corneal ulcers. For instance, Alio et al demonstrated successful closure of corneal perforations using autologous fibrin membrane combined with an E-PRP clot, achieving favorable outcomes in 11 patients.¹¹ Alvarado-Villacorta et al reported complete re-epithelialization in non-healing corneal ulcers using solid PRP with silicone-hydrogel contact lenses. While these studies highlight the promise of PRP in corneal healing, the literature lacks reports on the combined use of liquid PRP (subconjunctival injections and eye drops) with therapeutic contact lenses for treating corneal perforations.¹² This case represents a novel application of these therapies, demonstrating their feasibility and effectiveness in a resource-limited setting.

Clinical Implications and Future Directions

This case underscores the importance of developing accessible and minimally invasive therapies for managing corneal perforations, particularly in regions where advanced surgical options are unavailable. The combination of PRP and therapeutic contact lenses offers a practical solution that aligns with personalized medicine principles, tailoring treatment to the patient's needs and resource constraints.

Despite the promising outcomes, this report has several limitations. First, the lack of microbial cultures and sensitivity testing limits the ability to confirm the specific etiology of the ulcer. While herpetic keratitis was the presumed cause, this diagnosis remains clinical. Second, as a single case report, these findings are not generalizable. Future studies involving larger cohorts and randomized controlled trials are necessary to validate the efficacy and safety of this combined approach. Standardized PRP preparation and application protocols should also be established to ensure reproducibility and consistency across clinical settings.

Unanswered Questions and Research Opportunities

Numerous inquiries persist concerning the concurrent application of PRP and therapeutic contact lenses: What are the ideal dosing regimens and concentrations for PRP in managing corneal perforations? Is it feasible to integrate this method with additional adjunctive therapies, such as collagen cross-linking or anti-inflammatory agents, to improve results? How does this treatment measure against established surgical procedures regarding long-term efficacy, safety, and cost-effectiveness? Furthermore, the assumption that PRP retains its therapeutic potential for extended periods, such as one month, is problematic. Its biological stability is highly time- and storage-dependent, with platelet functionality beginning to decline within hours, and growth factor concentrations fluctuating unpredictably over time. Without post-preparation analysis—such as platelet counts, growth factor profiling, and bioactivity testing—there remains a significant quality control gap that can compromise treatment consistency and outcomes. Future research should address these issues, while also exploring the potential of this therapy in other challenging ocular surface conditions, such as chemical burns or autoimmune-related corneal melts.

In conclusion, this case highlights the potential of combining PRP therapy with therapeutic contact lenses as an effective, minimally invasive treatment for corneal ulcers with perforation. The approach offers a viable alternative to conventional surgical interventions, particularly in resource-limited settings. This method can potentially transform the management of complex corneal conditions by accelerating epithelialization, reducing inflammation, and preserving corneal integrity. Further studies are warranted to establish its role in clinical practice and refine treatment protocols.

Data Sharing Statement

All data generated or analyzed during this study are included in this article. Further inquiries can be directed to the corresponding author.

Statement of Ethics

We confirm that institutional approval was not required for the publication of this case report, in accordance with the local policies of AKFA Medline University Hospital. The patient provided the case report, in accordance with the local policies of written informed consent for the publication of their case details and associated images.

Author Contributions

All authors made a significant contribution to the work reported, whether that is in the conception, study design, execution, acquisition of data, analysis and interpretation, or in all these areas; took part in drafting, revising or critically reviewing the article; gave final approval of the version to be published; have agreed on the journal to which the article has been submitted; and agree to be accountable for all aspects of the work.

Funding

This study was not supported by any sponsor or funder.

Disclosure

The authors have no conflicts of interest to declare in this work.

References

1. Whitcher JP, Srinivasan M, Upadhyay MP. Corneal blindness: a global perspective. *Bull World Health Organ.* 2001;79(3):214–221.
2. Upadhyay MP, Karmacharya PC, Koirala S, et al. The Bhaktapur eye study: ocular trauma and antibiotic prophylaxis for the prevention of corneal ulceration in Nepal. *Br J Ophthalmol.* 2001;85(4):388–392. doi:10.1136/bjo.85.4.388
3. Schaefer F. Bacterial keratitis: a prospective clinical and microbiological study. *Br J Ophthalmol.* 2001;85(7):842–847. doi:10.1136/bjo.85.7.842
4. O'Brien TP. Management of bacterial keratitis: beyond exorcism towards consideration of organism and host factors. *Eye.* 2003;17(8):957–974. doi:10.1038/sj.eye.6700635
5. Deshmukh R, Stevenson LJ, Vajpayee R. Management of corneal perforations: an update. *Indian J Ophthalmol.* 2020;68(1):7–14. doi:10.4103/ijo.IJO_1151_19
6. Kate A, Basu S. Corneal blindness in the developing world: the role of prevention strategies. *F1000Research.* 2023;12:1309. doi:10.12688/f1000research.141037.1

7. Amable PR, Carias RBV, Teixeira MVT, et al. Platelet-rich plasma preparation for regenerative medicine: optimization and quantification of cytokines and growth factors. *Stem Cell Res Ther.* 2013;4(3):67. doi:10.1186/scrt218
8. Alio JL, Rodriguez AE, WróbelDudzińska D. Eye platelet-rich plasma in the treatment of ocular surface disorders. *Curr Opin Ophthalmol.* 2015;26(4):325–332. doi:10.1097/ico.0000000000000169
9. Hassan A, Telandro A, Barguigua A, Baba M, Körber N. Evaluation of the use of highly concentrated autologous platelet-rich plasma and platelet-rich fibrin membrane to improve the outcome in the management of severe dry eye disease, corneal neurotrophic ulcer and corneal burn. *Cureus.* 2024;16(1):e51794. doi:10.7759/cureus.51794
10. Lim L, Lim EWL. Therapeutic contact lenses in the treatment of corneal and ocular surface diseases—a review. *Asia Pac J Ophthalmol.* 2020;9(6):524–532. doi:10.1097/apo.0000000000000331
11. Alio JL, Rodriguez AE, Martinez LM, Rio AL. Autologous fibrin membrane combined with solid platelet-rich plasma in the management of perforated corneal ulcers: a pilot study. *JAMA Ophthalmol.* 2013;131(6):745–751. doi:10.1001/jamaophthalmol.2013.2474
12. Alvarado-Villacorta R, Davila-Alquisiras JH, Hernández-Quintela E, Ramos-Betancourt N. Solid platelet rich plasma combined with silicone-hydrogel soft contact lens for non-healing corneal ulcers: a case series. *Ocul Immunol Inflamm.* 2022;30(5):1123–1128. doi:10.1080/09273948.2020.1871492
13. Fadadu PP, Mazzola AJ, Hunter CW, Davis TT. Review of concentration yields in commercially available platelet-rich plasma (PRP) systems: a call for PRP standardization. *Reg Anesth Pain Med.* 2019;44(6):652–659. doi:10.1136/rapm-2018-100356
14. Muthu S, Krishnan A, Ramanathan KR. Standardization and validation of a conventional high yield platelet-rich plasma preparation protocol. *Ann Med Surg.* 2022;82:104593. doi:10.1016/j.amsu.2022.104593
15. Mohammed MA, Allam IY, Shaheen MS, Lazreg S, Doheim MF. Lacrimal gland injection of platelet rich plasma for treatment of severe dry eye: a comparative clinical study. *BMC Ophthalmol.* 2022;22(1):343. doi:10.1186/s12886-022-02554-0
16. Fitriana PO, Pawiroranu S, Widayanti TW, Wirohadidjojo YW, Mahayana IT. Autologous platelet-rich plasma eye drop for moderate-to-severe bacterial corneal ulcers: changes in interleukin-6 tear concentration and clinical outcomes. *Taiwan J Ophthalmol.* 2022;12(4):457–461. doi:10.4103/tjo.tjo_42_21
17. Drzyzga Ł, Śpiwak D, Dorecka M, Wyględowska-Promieńska D. Available therapeutic options for corneal neovascularization: a review. *Int J Mol Sci.* 2024;25(10):5479. doi:10.3390/ijms25105479
18. Stamate A-C, Tătaru CP, Zemba M. Update on surgical management of corneal ulceration and perforation. *Romanian J Ophthalmol.* 2019;63(2):166–173. doi:10.22336/rjo.2019.25
19. Kruse FE, Rohrschneider K, Völcker HE. Multilayer amniotic membrane transplantation for reconstruction of deep corneal ulcers. *Ophthalmology.* 1999;106(8):1504–1511. doi:10.1016/s0161-6420(99)90444-x
20. Di Zazzo A, Kheirkhah A, Abud TB, Goyal S, Dana R. Management of high-risk corneal transplantation. *Surv Ophthalmol.* 2017;62(6):816–827. doi:10.1016/j.survophthal.2016.12.010
21. Liu S, Wong YL, Walkden A. Current Perspectives on Corneal Transplantation. *Clin Ophthalmol.* 2022;16:631–646. doi:10.2147/opth.S289359
22. Sharma A, Sharma N, Basu S, et al. Tissue adhesives for the management of corneal perforations and challenging corneal conditions. *Clin Ophthalmol.* 2023;17:209–223. doi:10.2147/opth.S394454
23. Acharya M, Gour A, Dave A. Commentary: tarsorrhaphy: a stitch in time. *Indian J Ophthalmol.* 2020;68(1):33–34. doi:10.4103/ijo.IJO_1824_19
24. Kitchens J. The drawstring temporary tarsorrhaphy technique. *Arch Ophthalmol.* 2002;120(2):187–190. doi:10.1001/archophth.120.2.187
25. Anitua E, Muruzabal F, Pino A, Merayo-Llodes J, Orive G. Biological stability of plasma rich in growth factors eye drops after storage of 3 months. *Cornea.* 2013;32(10):1380–1386. doi:10.1097/ICO.0b013e31829f7088
26. Anitua E, de la Fuente M, Riestra A, Merayo-Llodes J, Muruzábal F, Orive G. Preservation of biological activity of plasma and platelet-derived eye drops after their different time and temperature conditions of storage. *Cornea.* 2015;34(9):1144–1148. doi:10.1097/ico.0000000000000489

International Medical Case Reports Journal

Publish your work in this journal

The International Medical Case Reports Journal is an international, peer-reviewed open-access journal publishing original case reports from all medical specialties. Previously unpublished medical posters are also accepted relating to any area of clinical or preclinical science. Submissions should not normally exceed 2,000 words or 4 published pages including figures, diagrams and references. The manuscript management system is completely online and includes a very quick and fair peer-review system, which is all easy to use. Visit <http://www.dovepress.com/testimonials.php> to read real quotes from published authors.

Submit your manuscript here: <https://www.dovepress.com/international-medical-case-reports-journal-journal>

Dovepress
Taylor & Francis Group