

Percutaneous dermal drug delivery for local pain control

Sujatha Tadicherla
Brian Berman

Department of Dermatology and
Cutaneous Surgery, University of
Miami, Miami, FL, USA

Abstract: Topical anesthetics have evolved from a simple solution of cocaine to creams, ointments, gels, liposomal preparations, and to the latest sophisticated patches and peels. Topical anesthetics are essential for performing diagnostic, therapeutic, and cosmetic dermatology procedures. These anesthetics noninvasively deliver anesthesia in locally required areas. In this review, we present an overview on the mechanism of percutaneous absorption of skin and address the composition, duration of onset of anesthetic effect, uses, and side effects that are applicable for the products. Also discussed are the novel advances of using heat to enhance penetration of the anesthetic as seen in Synera™ patch and delivery of anesthesia using a peel method as seen in the yet to be US Food and Drug Administration-approved S-Caine peel.

Keywords: Topical anesthetics, dermal anesthetics, EMLA, iontophoresis, S-Caine Patch, dentipatch

Introduction

For centuries, topical application of medications has mostly been utilized for the treatment of localized skin diseases. Topical treatment was meant to treat the disease state locally with little or no systemic effects (Cleary 1984). This review focuses on the products available for producing the local anesthetic effects necessary for performing diagnostic, therapeutic, and cosmetic dermatologic procedures.

The first topical anesthetic discovered was cocaine. It was extracted from the leaves of *Erythroxylon coca*, a plant originally found in South America (Ritchie and Greene 1980). For centuries the natives had chewed the leaves for their euphoric effects (Dyke and Byck 1982). Nieman first isolated cocaine alkaloid in its pure form in 1859 (Fink 1985) and noted its ability to numb the tongue (Faulconor and Keys 1965), and Koller was the first to use it as a topical anesthetic for eye surgery (Berger 2000). An ideal topical anesthetic produces effective anesthesia within minutes when applied to intact skin, has prolonged duration of action, and has minimal side effects. Another potential benefit of using topical anesthetics is avoiding disruption of anatomical landmarks. Over the past 150 years, topical anesthetics have evolved from a simple solution of cocaine to creams, ointments, gels, liposomal preparations, and to the latest sophisticated patches and peels. Iontophoresis and sonophoresis have also been utilized to enhance the anesthetic delivery.

Anatomy of skin and percutaneous absorption

Delivery of a drug through the skin is a complex process, and this can be better appreciated by briefly reviewing the anatomy of the skin. Skin is an effective barrier and its vital role is to prevent the ingress or egress of compounds across it. When this

Correspondence: Brian Berman
Department of Dermatology and
Cutaneous Surgery, University of Miami,
Miller School of Medicine, 2023A
Rosenstiel Medical Science Building
(RMSB), 1600 N.W. 10th Avenue, Miami,
FL 33136, USA
Tel +1 305-243-5620
Fax +1 305-243-6468
Email bberman@med.miami.edu

barrier function is compromised for any reason, it results in loss of body fluids and also becomes a port of entry for microorganisms into the body as seen in burns patients and various dermatological conditions. Therefore, skin plays a key role in protecting the body from various environmental insults, both biological and chemical (Bucks and Maibach 2002). The skin is composed of the outermost epidermis, which is avascular, and the dermis, which is vascular, and which contains the free nerve endings that are responsible for pain sensation. Hence, the target area for the anesthetic action is the dermis. The pilosebaceous, apocrine, and eccrine glands originate in the dermis. These glands penetrate through the epidermis to reach the surface of the skin. The dermis is further supported by subcutaneous fat and muscle beneath. The superficial layer of epidermis is the stratum corneum. Stratum corneum is almost impermeable and responsible for the barrier function of the skin. It plays a vital role in the absorption of drugs. Stratum corneum therefore provides the rate-limiting step in the penetration process (Barry et al 1987).

When a drug is applied to intact skin, it first has to traverse through the stratum corneum, and to do this, the drug has to partition from the vehicle into the stratum corneum. As stratum corneum is lipophilic, usually a drug in its base form is ideal. The viable part of epidermis and the dermis are hydrophilic, and the drug has to be in an ionized state for optimal permeation. When the drug arrives at the interface of stratum corneum and the viable epidermis, it has to partition into the hydrophilic tissue. On further penetration, the drug has to partition into the dermis that is again hydrophilic. Enroute through the layers of the skin, the drug undergoes metabolism by enzymes present in the skin to more active or inactive compounds. Some of the drug interacts with binding sites forming a depot. The drug on further penetration reaches subcutaneous tissue and muscle. These tissues may also act as a depot leading to sustained release (Schuplein 1978; Flynn 1979; Chien 1982; Schaefer et al 1982; Guy and Hadgraft 1984; Bronaugh and Maibach 1985; Marty et al 1985; Bucks et al 2002).

The penetration of drugs through the skin involves diffusion via transcellular and intercellular pathways, and via hair follicles and sweat glands. The permeation through the appendages allows diffusional leakage into the epidermis and penetration directly into the dermis. This is supposedly the fastest route for hydrophilic molecules. However, the major transport pathway is through the intercellular lipid domains. (Katz and Poulsen 1971; Katz 1973; Poulsen 1973; Idson 1976; Higuchi 1977).

Transport of an anesthetic depends on its time-scale of permeation that is either steady state or transient diffusion, the pKa of the drug, molecular size, stability, binding affinity, solubility, partition co-efficient, integrity and thickness of stratum corneum, density of sweat glands and hair follicles, skin hydration, metabolism, and the vehicle effects (Ranade and Hollinger 2003). The pKa of an anesthetic is the pH at which a drug exists both in non-ionic (base) and ionic (salt) states in equal proportions (Covino 1986). As mentioned earlier, base is the active form that permeates through the stratum corneum. The closer the pKa of the drug to the pH of the vehicle and the skin, the more of the drug is in its active base form and hence its penetration is higher (Schaefer et al 1982).

For optimizing the percutaneous absorption of topically applied drugs, two strategies are utilized in formulations. The first strategy is using a vehicle or device which maximizes drug delivery into the skin without affecting the physiochemical properties of stratum corneum and the second is using penetration enhancers. These enhancers enter into the skin and alter it reversibly to promote the drug absorption. An ideal enhancer should be pharmacologically inert, non-toxic, non-irritating or non-allergenic, and a suitable solvent for the drug (Woodford and Barry 1986; Barry et al 1987).

Occlusion is a physical method utilized to enhance the permeation of the anesthetic through the skin. It impairs the passive transepidermal loss of water at the site of application, and increases water content of intercellular areas. This is responsible for increase in the hydrophilic character of the stratum corneum, reducing the stratum corneum–viable epidermis partition coefficient of the penetrant (Bucks and Maibach 2002).

Mechanism of cutaneous analgesia

The mechanism by which an anesthetic works is by inhibiting the initiation and propagation of nerve impulses. This is achieved by the base form of the drug by penetrating through the axolemma, the outer nerve sheet, and blocking the influx of sodium ions into the nerve cell, thereby dampening the generation of action potential.

Product review EMLA

Eutectic mixture of local anesthetics (EMLA) is based on an eutectic mixture of two well known local anesthetics lidocaine and prilocaine. EMLA is an oil-in-water emulsion

mixture. The oil phase consists of the eutectic mixture lidocaine and prilocaine. A eutectic mixture is one in which its constituents melt at room temperature and are present in liquid phase. Broberg when working with emulsion mixtures had first discovered this property serendipitously. He found that when lidocaine and prilocaine bases in crystalline form were mixed together, they became fluid at room temperature. This is secondary to lowering of the melting points of both the constituents in the mixture. This effect is best produced when the drugs were mixed in 1:1 ratio (Juhlin and Evers 1990). With the discovery of eutectic mixture, an oil-in-water emulsion can be prepared with highest concentration of the active ingredients (Lycka 1992). In EMLA, the concentration of lidocaine and prilocaine achieved in the oil droplet is 80% though the overall concentration of both the active drugs is kept as low as 5% in the mixture. This is secondary to the emulsifiers present in the mixture. This reduction in concentration is responsible for decreased systemic toxicity (Watson 1986).

Each gram of EMLA is composed of lidocaine 25 mg/ml and prilocaine 25 mg/ml, polyoxyethylene fatty acid esters that are emulsifiers, carboxypolymethylene that is a thickening agent, distilled water with pH adjusted approximately to 9, and without any preservative (AstraZeneca 2004). It was released in the US in 1993 and is Food and Drug Administration (FDA)-approved for use only on procedures involving intact skin.

EMLA has to be applied under occlusive dressings like Tegaderm™, Saran-wrap™, or Band-aid™, which aids diffusion into the skin (Lycka 1992). The onset of anesthesia depends on anatomic location and duration of application. On face and thighs, for needle stick purposes, the onset is less than 25 minutes (Holmes 1994). For procedures on mucous membranes involving oral and genitalia, the onset is in 5–15 minutes without occlusion (Rylander et al 1990). EMLA does not provide effective anesthesia on thick glabrous skin like palms and soles and is not recommended for procedures in these areas (Huang and Vidimos 2000).

The recommended application time for adequate analgesia is at least 1 hour. For painful procedures like split skin grafting, the recommended application time is 2 hours (Lahteenmaki et al 1988). Maximum effect is reached at 2–3 hours of application time and lasts for at least 1–2 hours after removal (AstraZeneca 2004). In several clinical trials, EMLA was found to produce adequate dermal analgesia when applied under occlusive dressing for 60 minutes, and inadequate analgesia when applied for 30 minutes only (Evers et al 1985; McCafferty and Woolfson 1993;

Greenbaum and Bernstein 1994). EMLA forms as a depot in the stratum corneum during occlusion (Evers et al 1985; Arendt-Nielsen and Bjerring 1988), which results in continued and even increase in analgesia 15–60 minutes after removal of the medication (Evers et al 1985; Arendt-Nielsen and Bjerring 1988; Friedman et al 1999). The onset of analgesia can be enhanced by pretreatment with low frequency ultrasound (55 KHz) before application of EMLA and it was found to be as early as 5 minutes (Katz et al 2004). Rapid onset was also found when EMLA was applied for 20 minutes with heat (Liu et al 2003).

The duration of analgesia is influenced by the vascularity of the local area; the more vascular, the more clearance, and hence the wearing off effect happens sooner. For example, on the face, the duration of anesthetic effect is shortened (Arendt-Nielsen et al 1990; Larsson et al 1996). The depth of an anesthetic effect depends mainly on the duration of application. When applied for 60 minutes, the depth of anesthetic effect was found to be 3 mm, and for 120 minutes of application time, the depth of anesthetic effect was found to be 5 mm (Bjerring and Arendt-Nielsen 1990). In a study evaluating anesthesia for punch biopsies, EMLA was found to provide effective anesthesia to a depth of 1–2 mm when applied for 60 minutes, 2–3 mm when applied for 120 minutes, and 6 mm when applied for 3–4 hours (Wahlgren and Quiding 2000). When EMLA was applied on intact skin under occlusive dressing and left for 3 hours and 24 hours, the plasma levels of both lidocaine and prilocaine were found to be well below systemic toxic level. The peak lidocaine levels were 1/20 and prilocaine levels were 1/36 of the systemic toxic levels (AstraZeneca 2004). In a study involving 10 patients, when 5–10 g of EMLA was applied to chronic leg ulcers for a period of 24 hours, plasma concentrations of lidocaine and prilocaine were found to be less than 1/5th of those associated with toxic reactions (Stymne and Lillieborg 2001).

In dermatologic procedures, EMLA was found to be effective in relieving pain associated with shave (Shelley 1975) and punch biopsies (Juhlin et al 1980), curettage of molluscum (Rosdahl et al 1988), split thickness skin grafting (Goodacre et al 1988), chemical peels (Lycka 1991), epilation (Hjorth et al 1991), vascular laser treatments (Ashinoff and Geronemus 1990; Tan and Stafford 1992; Sherwood 1993), facial laser resurfacing (Ramos-Zabala et al 2004), laser hair removal (Guardiano and Norwood 2005), excisional biopsy or curettage, and electro-surgery (Gupta and Sibbald 1996). EMLA has also been found to be useful prior to procedures like venepuncture in neonates (Hallen

et al 1984; Kurien et al 1985; Moller 1985), venous cannulation (Russell and Doyle 1997), lumbar puncture (Kapelushnik et al 1990), sharp wound debrediment, leg ulcers (Holm et al 1990; Holst and Kristofferson 1998; Lok et al 1999; Rosenthal et al 2001), decubitus ulcers, abscess revisions, post-op wounds, diabetic ulcers, burns (Blanke and Hallern 2003), and post-burn pruritus in children when applied to newly healing intact skin (Kopecky et al 2001). EMLA did not provide effective anesthesia for procedures on external ear (Sarifakioglu et al 2004) As for those on oral mucosa, EMLA provided anesthesia only for superficial layers and for short term procedures only (Bernardi et al 1999). EMLA provided comparable anesthesia as LMX for hair removal with Nd: YAG 1064 nm laser (Guardiano and Norwood 2005).

Local effects are initial transient blanching followed by erythema. This is secondary to the bi-phasic effect on cutaneous blood vessels at the application site. Blanching is seen in 1.5 hours of application secondary to vasoconstrictive effect (this effect does not favor emergency venous cannulations), and this is followed by erythema in 2–3 hours of application resulting from vasodilatory effect (Bjerring et al 1989). Itching and edema can occur. With repeated applications, local reactions are exacerbated but resolve after stopping the medication (Evers et al 1985; Wehle et al 1989). Contact urticaria (Waton et al 2004) and dermatitis (Ismail and Goldsmith 2005) have also been reported. Any contact with eye should be avoided as EMLA irritates the cornea and its high pH 9 may produce lesions similar to corneal abrasions and ulcerations (Brahma and Inkster 1995; Eaglstein 1999; McKinlay et al 1999).

Plasma levels where toxic reactions seen are 6 µg/ml. In studies done in children older than 3 months of age, when EMLA was applied for 4 hours to intact skin, plasma levels of lidocaine were shown to be 0.155 µg/ml, and prilocaine were 0.131 µg/ml, which were well below the toxic levels (Engberg et al 1987). A well documented major systemic side effect of using EMLA is methemoglobinemia produced secondary to prilocaine. This is due to the oxidation of iron in hemoglobin from ferrous to ferric state, decreasing the oxygen carrying capacity of hemoglobin. This results in cyanosis when levels reach around 5%–15% (Russell and Doyle 1997). EMLA is not recommended in infants younger than 12 months of age who are on methemoglobinemia-inducing drugs, patients with glucose-6-phosphate dehydrogenase (G6PD) deficiency and with congenital or idiopathic methemoglobinemia (AstraZeneca 2004). It should be used with caution in infants less than 3 months of

age because of the incomplete maturation of nicotinamide adenine dinucleotide (NADH)-methemoglobinemia reductase system (Brisman et al 1998). A maximum of 1 g for an hour of application is safe on intact skin of term neonates younger than 3 months (Rincon et al 2000). Central nervous system (CNS) toxicity was also reported in a toddler when excessive EMLA was applied over an extensive area prior to molluscum treatment (Juhlin et al 1989).

Usage of EMLA is contraindicated in the presence of history of amide sensitivity, liver disease, and skin diseases like atopic dermatitis, or psoriasis (Juhlin and Rollman 1984). In the later it is secondary to higher rates of absorption from inflamed areas.

TAC solution

Tetracaine, adrenaline (epinephrine), and cocaine (TAC) solution is a dermal anesthetic. They are used for open wounds, such as lacerations and abrasions, to provide anesthetic effect prior to wound repair. The original formulation of TAC solution consisted of tetracaine 0.5%, 0.05% epinephrine 1:2000, and 11.8% cocaine in normal solution. At this concentration, each ml of TAC solution contains 5 mg tetracaine, 0.5 mg epinephrine, and 118 mg cocaine. Since 1980, TAC solution has been used as an alternative to infiltrative anesthesia with lidocaine for repair of minor superficial lacerations (Pryor et al 1980; Anderson et al 1990, Huang and Vidimos 2000). It was found to work better for scalp and facial lacerations than on extremities (Hegenbarth et al 1990). The same was found when different formulations of TAC solution were compared (Bonadio and Wagner 1988b; Smith and Barry 1990; Vinci and Fish 1996). TAC solution was 95% effective in providing anesthesia prior to repair of lacerations on face and neck in children, with no adverse events even on application to an area with a length of 5 cm and a depth of 5 mm (Bonadio and Wagner 1988a). TAC solution is applied to the laceration with a cotton ball or gauze pad soaked in the solution (Grant and Hoffman 1992).

For a laceration up to 5 cm in length, the recommended dosing of TAC solution is from 2–5 ml. One dosing regimen is as per weight, 0.09 ml/kg of TAC solution that contains approximately 10 mg/kg of cocaine (Hegenbarth et al 1990). Another regimen suggests 1 ml of TAC solution per cm of laceration (Cannon et al 1989). Application for at least 20 minutes prior to suturing produced effective anesthesia in children (Ordog and Ordog 1994).

Effectiveness can be determined clinically by visible blanching (Nichols et al 1987; Hegenbarth et al 1990; Anderson et al 1990). The epinephrine and cocaine in the

preparation produce vasoconstriction leading to a prolonged presence of the drug at the site of application, inhibiting the absorption of the drugs into systemic circulation, resulting in fewer systemic effects (Russell and Doyle 1997).

TAC solution is not recommended for usage on mucous membranes, burn areas, or large abrasions due to the risk of rapid absorption leading to systemic toxicity. It is also not recommended for areas supplied by terminal arterioles (McCafferty et al 1989; Russell and Doyle 1997).

Very low plasma levels of cocaine were detected on application of 3 ml of TAC solution for 15 minutes in 75% of children. Tetracaine levels were not detected (Terndrup et al 1992). Urine drug screen was found to be positive for cocaine for up to 36–48 hours after usage of TAC solution (Altieri et al 1990).

Local adverse effects of TAC solution were thought to be due to the combined vasoconstrictive effects of epinephrine and cocaine. As a result of this, blood circulation is decreased at the application site, which leads to a decrease in tissue defenses. There is a possibility for an increased risk of wound infection and thereby decreased healing capacity of the wound (Barker et al 1982; Grant and Hoffman 1992). This could eventually lead to wound dehiscence in extreme cases (Galvin and De Simone 1976; Gosnold 1977; Rutherford and Spence 1980; Alkan et al 1984). It is also contraindicated for usages anywhere near the eye area as it was found to produce corneal abrasions (Bonadio and Wagner 1990).

Systemic reactions were reported when TAC solution was applied at or near the mucous membranes. This is secondary to the rapid and uninhibited absorption of cocaine and tetracaine from the mucosa. As the individual components are toxic by themselves, in combination their toxicities are much more potentiated. Severe adverse events including respiratory distress, seizures (Wehner and Hamilton 1984; Tipton et al 1989) and death (Jacobsen 1987; Dailey 1988) have been reported.

Because of the potential for systemic absorption of cocaine and resulting side effects, and because cocaine is a regulated drug, TAC solution is not FDA-approved. New formulations without cocaine have been tried to compare their efficacy against TAC solution. At the same concentrations, TAC without cocaine was found to be less effective than the original TAC solution (Schaffer 1985). The same result was found when TAC solution was compared with tetracaine alone (White et al 1986).

The formulations that were found to be equally effective as TAC solution are: LAT containing 4% lidocaine,

adrenaline 1:2000, and 1% tetracaine in both children (Ernst et al 1995a; Schilling et al 1995) and adults (Ernst et al 1995b); lidocaine 5%–epinephrine 1:2000-containing solution (Blackburn et al 1995); tetracaine containing 1% tetracaine with 5% phenylephrine (Smith et al 1997); and bupivacaine containing bupivacaine and norepinephrine (Smith et al 1996). EMLA was found to be superior to TAC, though EMLA is recommended only for intact surfaces (Anderson et al 1990).

Amethocaine

Amethocaine is a 4% tetracaine gel and was first synthesized in 1928 by Eisleb. It has to be applied under occlusive dressing. Tetracaine is a lipophilic compound and it easily diffuses through the stratum corneum because of this property (Covino 1986). This intrinsic property is responsible for rapid onset of anesthetic effect within 40 minutes (Lawson et al 1995). Due to the same property, it is held as a reservoir in the skin, which is responsible for sustained release resulting in a prolonged duration of action of approximately 4 hours (McCafferty et al 1989). In dermatology, for pulsed dye laser treatment of port-wine stains, amethocaine was found to be significantly better in reducing pain when compared with EMLA (McCafferty et al 1997). This was a randomized, double-blind and placebo-controlled study involving 29 patients. The amethocaine preparation was found significantly better than EMLA, $p < 0.05$ by visual analog scale (VAS) pain scoring system and $p < 0.005$ by verbal rating score (VRS) pain scoring system. The results from this study seem to be reliable based on the p values. It was not found to be effective when compared with placebo either during or after photodynamic therapy for small lesions of superficial basal cell carcinoma, Bowen's disease or actinic keratosis (Holmes et al 2004).

When compared with placebo, amethocaine gel was found to provide good analgesic action for skin puncturing procedural pain in neonates (Moore 2001). When used prior to minor surgical procedures like venous cannulation in both adults (Molodecka et al 1994) and children (Lawson et al 1995), amethocaine was found to be as effective as EMLA. Amethocaine was efficacious for relieving pain prior to venepuncture in children when compared with placebo (Jain and Rutter 2000). However, in procedures like heel prick blood sampling (newborns) (Jain et al 2001), arterial puncture (Tran et al 2002), it was not effective in reducing pain. For radial artery cannulation in adults, topical amethocaine provided comparable anesthetic effect as with lidocaine infiltration (Olday et al 2002).

The most common local effect was erythema. Other effects were itching and edema, although not commonly seen (O'Connor and Tomlinson 1995). Secondary to absent or very low systemic levels upon topical application; systemic adverse effects are rarely seen. In a study involving 10 subjects on topical application of amethocaine, three subjects had plasma concentrations of $0.20 \text{ mg liter}^{-1}$ without any significant side effects. The absence of side effects was concluded to be secondary to slow absorption and tissue hydrolysis of amethocaine after topical dermal application (Mazumdar et al 1991).

A new micro emulsion formulation of amethocaine in preclinical studies done in rats was found to be promising in providing rapid and effective anesthetic effect against heat and mechanical stimulus when compared with amethocaine gel, EMLA, lidocaine infiltration, or nothing (Arevalo et al 2004). A novel patch, made of hydroxypropylcellulose discs containing tetracaine ($1 \text{ mg} \times \text{cm}^2$) and surrounded by a low tack pressure-sensitive adhesive backing layer was found to be effective in reducing pain prior to venepuncture in both term and pre-term infants (Long et al 2004).

LMX (ELA-Max)

LMX is a topical liposomal formulation containing 4% or 5% lidocaine. Liposomes have similar structure as cell membrane, made up of lipid bi-layers. This structure enhances the penetration of the drug, leading to rapid onset of action (Finkel et al 2002) and prevents metabolic degradation at the application site, which leads to a prolonged duration of action (Bucalo et al 1998), and also helps in sustained release of the drug (Yun et al 2002).

LMX 4% is available over the counter and is FDA-approved for temporary relief of pain and itching associated with minor cuts, minor burns, sunburn, and insect bites. The 5% preparation needs prescription and has been approved for anorectal pain. Both the preparations can be used without occlusion unlike EMLA, but if cooperation is an issue as faced in pediatrics, LMX can be used under occlusion with tegaderm and is supplied as 5 g tubes for this purpose. Each gram of LMX contains lidocaine 40 mg, vitamin E acetate, propylene glycol, benzyl alcohol, lecithin, cholesterol, carbomer 940, triethanolamine, polysorbate 80, and purified water (Huang and Vidimos 2000).

LMX provides effective anesthesia prior to various procedures when applied for 30 minutes without occlusion unlike EMLA which needs 60 minutes with occlusion to get the same effect (Altman and Gildenberg 1999; Eremia and Newman 2000; Kleiber et al 2002; Eichenfield et al 2002;

Smith and Gjellum 2004; Koh et al 2004). Onset of LMX has been found to be further enhanced by pretreatment with erbium: yttrium-aluminum-garnet laser (Yun et al 2002).

In dermatologic procedures, LMX has been tested and found to be effective as topical anesthetic prior to hair removal procedures using laser (Eremia and Newman 2000) and high-energy pulsed light source devices (Altman and Gildenberg 1999). However, both studies lacked good sample size and blinding. The latter study also did not involve randomization. In a recent double-blind and randomized study which evaluated the hair removal using Nd: YAG 1064 nm laser, both LMX and EMLA showed similar efficacy in reducing pain when applied for the same time period of 30 minutes (Guardiano and Norwood 2005). In a comparative clinical trial with EMLA and placebo groups for medium-depth chemical peeling involving 10 patients, both LMX and EMLA showed equal efficacy in reducing the pain when applied for the same period of time without any clinical or histopathological difference between the treatment and control group (Koppel et al 2000).

In randomized clinical studies in children comparing LMX and EMLA, the former was found to be safe and provided effective anesthesia in 30 minutes prior to intravenous (IV) insertions (Kleiber et al 2002; Koh et al 2004) and venipuncture (Eichenfield et al 2002). In another study involving children, LMX provided similar pain and anxiety reduction during peripheral intravenous (PIV) insertion in children when compared with injected buffered lidocaine (Luhmann et al 2004).

LMX has been found to be safe with very minor and few side effects. The local effects were transient blanching and erythema. The amount of lidocaine absorbed systemically depends on the duration and surface area of application. The recommendation in children is that the area of application should not be larger than 100 cm^2 in a child weighing less than 10 kg or between 10–20 kg for a single application of LMX. Systemic effects are seen when plasma levels of lidocaine are over $5 \mu\text{g/ml}$. The serum levels of lidocaine are in the range of $0.05\text{--}0.16 \mu\text{g/ml}$ when 60 g of LMX has been applied topically for 3 hours over an area of 400 cm^2 of skin (Huang and Vidimos 2000). These levels are very low when compared with the toxic levels and hence very low profiles of any serious adverse events were noticed.

As of now, LMX has the advantage of faster onset of anesthetic effect, no occlusion required, low profile of side effects, and no risk of methemoglobinemia when compared with EMLA. More studies are required to establish its efficacy prior to other dermatologic procedures.

Betacaine–LA

Betacaine LA contains lidocaine, prilocaine, dibucaine, and phenylephrine (a vasoconstrictor) in petrolatum base. The exact concentration of the ingredients is not revealed as it is a proprietary anesthetic. Concentration of lidocaine and prilocaine are four times that found in EMLA and therefore should be used cautiously (Friedman, Mafong, et al 2001a).

In adults, betacaine–LA is not recommended to be used for areas more than 300 cm² and is also not recommended for children (Friedman, Mafong, et al 2001a). It can be applied without occlusion for 30–45 minutes to get adequate analgesia. The only comparative study with betacaine–LA was done under occlusion for 60 minutes, along with EMLA, LMX, and tetracaine. Anesthetic effect was assessed with Q-switched Nd: YAG laser at 1064 nm after 60 minutes of application time and 30 minutes after removal. Its efficacy was found to be superior to control at the end of 60 minutes, and 30 minutes after removal of the medication. Both EMLA and LMX were found to be more efficacious than betacaine–LA (Friedman et al 1999). However, this is a weak study as it involves a small sample size (n = 12), lacks randomization, and involves subjective reporting of pain sensations.

Topicaine

Topicaine contains 4% or 5% lidocaine in a hydro-ethanolic gel micro emulsion delivery system. It is made up of lidocaine base 4% or 5% in a gel composed of water, ethanol, glycerin, jojoba oil, aloe vera oil, glyceryl monolaureate, benzyl alcohol, carbomer 940, and ethylenediamine tetraacetic acid (EDTA). Both formulations can be obtained without prescription.

Four percent topicalaine is recommended for usage only on intact skin under occlusion. Five percent can be used with or without occlusion. As per manufacturer, topicalaine produces effective analgesic effect when applied for 30–60 minutes prior to a procedure. The recommended maximum area of application in adults is less than 600 cm² and in children it is less than 100 cm².

Topicaine is being used extensively in the field of cosmetic dermatology. It is indicated for pain relief prior to procedures like electrolysis, waxing, laser hair removal, permanent make up, tattoos, collagen injections, botox injections, hair transplants, laser treatment of telengectiasis, and acid peels. The 5% formulation can also be used for anorectal pain relief.

Topicaine's efficacy was tested in a randomized, double-blind, controlled trial with EMLA and LMX 5 after application for 30 minutes with laser-induced pain stimuli

using Q-switched Nd: YAG laser at 1064 nm. Topicaine and LMX 5 produced effective anesthesia after a 30 minute application time. However, topicalaine and EMLA seemed to produce the highest anesthetic effect 30 minutes after removal.

Local effects are mild, which include erythema, edema, and blanching. Topicaine's usage is contraindicated in patients with amide sensitivity. More studies are needed to establish the efficacy, tolerability and safety profile of topicalaine (Friedman, Mafong, et al 2001b; ESBA 2005).

Iontophoresis

Iontophoresis is a method of enhancing the transport of topically applied drugs using a mild electric current to increase the permeability of charged drugs through the skin. This process is utilized for delivery of drugs like lidocaine, epinephrine, methylprednisolone succinate, dexamethasone phosphate, antivirals, and antibiotics (Gangarosa et al 1995). The drug to be delivered is placed at an electrode of the same polarity at or near the surface of the treatment area. The positively charged drug is placed at the anode and the negatively charged drug is placed at the cathode. A mild direct current is passed, which travels through the skin, through the interstitial fluids, and back to the skin, which is collected by a return electrode. The ions of the drug traverse through the same path as the current (Gangarosa et al 1995; Zimmer and Ashburn 2001). Iontophoresis was found to enhance the penetration of the drug by 20–60-fold when compared with topical application (Gangarosa et al 1995).

Lidocaine iontophoresis has been found to be 80% to 100% effective in providing anesthetic action prior to procedures like injections, abrasions, laser surgery, and cautery. This procedure was not found to be efficacious in providing enough anesthesia for dermal excisions, for procedures that involve more than 1 cm, and for procedures done on hands and feet (Maloney et al 1992).

With lidocaine iontophoresis, the onset of action is within 10 minutes. The onset of anesthetic effect was not decreased by increasing the concentration of lidocaine (Oshima et al 1994), and the anesthetic effect lasted for 15 minutes (Kundu and Achar 2002). The depth of anesthesia was found to be 1–2 cm (Lener et al 1997). The plasma levels of lidocaine were <1.0–1 µg/ml after 10 minutes of iontophoresis application. This did not change even when higher concentrations of lidocaine were used (Oshima et al 1994).

In dermatologic procedures, iontophoresis has been found to be a safe and an effective technique for topical anesthesia in both children and adults. It was found to be

useful for performing procedures in children like shave biopsy, curettage, injection, punch biopsy (Zempsky and Parkinson 2003a). This was a multicenter, randomized, placebo-controlled, double-blind study in 60 children evaluating the efficacy and safety of lidocaine iontophoresis. Ninety-four percent in treatment reported no pain when compared with 7% of patients in the placebo group ($p < 0.001$). This is a good quality study and the results seem to be reliable. It was used in adults prior to performing shave biopsy (Zempsky and Parkinson 2003b). In this study, 41 patients were evaluated in a single center, randomized, double-blind, and placebo-controlled fashion. This is a very good study and the results seem to be reliable as 90% of patients in the treatment group reported no pain when compared with 10% of the patients in the placebo group ($p < 0.001$). In a comparative clinical study with EMLA, both provided effective and complete anesthesia, however the onset of anesthetic effect with iontophoresis had been much more rapid (within 30 minutes) (Greenbaum and Bernstein 1994). It has also been shown to provide effective anesthesia prior to pulsed dye laser application of port wine stains (Nunez et al 1997).

Iontophoresis has also been found to provide rapid and effective anesthesia in various procedures. It has been found useful prior to lumbar puncture performed in emergency department (Strout et al 2004). When compared with placebo both in children and adults prior to venous cannulation was found to provide safe and effective anesthesia (Miller et al 2001; Zempsky et al 2004). This was again confirmed in another study when done in children alone (Rose et al 2002). In a comparative study with EMLA, iontophoresis was found to be inferior in efficacy but onset was much faster with iontophoresis (Squire et al 2000; Moppett et al 2004). Iontophoresis was also found efficacious for IV placement (Ashburn et al 1997; Zempsky et al 1998; Galinkin et al 2002), radial artery cannulation (Sherwin et al 2003), and PIV in both children and adults.

The local effects upon using iontophoresis were transient erythema and edema, blanching, itching (Zempsky and Parkinson 2003b; Strout et al 2004), burning, and tingling sensation. There has been no reported systemic toxicity so far. The blood levels of lidocaine were found to be below 10 ng/mL without any systemic reactions in a study which evaluated the tolerability and systemic bioavailability in pediatric population (Kearns et al 2003). In another independent study the plasma levels of lidocaine in children after an average of 20 minutes of iontophoresis with lidocaine was found to be $> 1.0 \mu\text{g/ml}$. Less than $1.5 \mu\text{g/ml}$

was supposed to be within the normal range (Schultz et al 2002).

Synera™ (S-Caine Patch)

Synera™ is a novel patch system intended to deliver local anesthesia. This was originally developed under the name of S-Caine Patch by ZARS Pharma (Salt Lake City, UT, US), and was recently approved by FDA. It is now licenced to Endo Pharmaceuticals Inc (Chadds Ford, PA, USA). This is a lidocaine and tetracaine patch (L/T patch) built in with a heating element called CHADD (Controlled Heat-Assisted Drug Delivery), which is a disposable oxygen-activated system. The L/T patch without the CHADD system has been found to provide effective anesthetic effect for minor dermatology procedures in geriatric population (Schechter 2005). The formulation is an emulsion in which the active ingredients are in oil phase as a eutectic mixture containing 70 mg of lidocaine and 70 mg of tetracaine in a ratio of 1:1 by weight. The inactive ingredients are polyvinyl alcohol, sorbitan monopalmitate, water, methylparaben, and propylparaben (Endo Pharmaceuticals Inc. Packet insert for Synera™). This system does not use any permeation enhancers. The total surface area of Synera patch is 50 cm^2 out of which the active area is 10 cm^2 . Synera is indicated to be used on intact skin for providing local dermal anesthesia prior to superficial dermatological procedures and superficial venous access. It is not recommended for usage on mucous membranes (Endo Pharmaceuticals Inc. Packet insert for Synera™).

The CHADD patch uses a new technology that releases controlled heat to enhance the delivery of the drug. Heat is generated using a mixture of iron powder, activated carbon, sodium chloride, wood flour, and water (Endo Pharmaceuticals Inc. Packet insert for Synera™). This mixture is placed in a pouch made of filter paper. This is again sealed between 2 polymer films. One of the films has holes of precalculated size. Another membrane with tiny holes covers the heat generating chemical components. When this package is exposed to atmosphere, air flows through the holes present in the cover membrane at a controlled rate, into the heating mixture and initiates a chemical reaction that generates heat. The amount of heat generated and the duration of reaction depend on the number and size of the holes in the membrane, and the composition and amount of the chemicals in the pouch (See URL: <http://www.zars.com/scainepatch.html>).

The local anesthetics are packed in a shallow chamber below the CHADD patch and sealed in an airtight packet. When applied to the skin, the CHADD patch gets heated

spontaneously and increases the temperature of the skin, thereby enhancing the permeation of the drugs through the epidermis (See URL: <http://www.zars.com/scainepatch.html>). This reduces the duration of onset of action of the local anesthetics. The heating element produces a temperature of 39°C to 41°C for 2 hours (Friedman et al 2001a).

A picture of Synera patch is provided by ZARS on their website at <http://www.zars.com/scainepatch.html> (Figure 1).

In a randomized, double-blind study, when Synera was compared with placebo, prior to minor dermatology procedures such as skin tag removal, superficial excision, electrodesiccation, keloid injection, and shave biopsies performed in adults, the patch proved to provide safe and effective anesthesia when applied for 30 minutes (Berman et al 2005). In a similarly designed study conducted on 74 patients over the age of 65 years, Synera patch-treated patients had less pain than patients who received placebo (Endo Pharmaceuticals Inc. Packet insert for Synera™). The depth of anesthesia was found to be 6.8 mm with Synera and 4.7 mm with placebo. The anesthetic effect of the patch lasted for more than 120 minutes as opposed to 10 minutes with placebo. This was determined in a randomized, double-blind, placebo-controlled, two-period crossover trial involving 12 healthy adult volunteers between the ages of 18 and 50 years. (Shomaker et al 2000). It has also been found to be beneficial prior to venipuncture in children, adults, and the geriatric population. In an independent study among the pediatric population involving 64 children, in a randomized, double-blind, and placebo-controlled fashion, Synera was found to be safe and effective when applied for 20 minutes. The child's pain was rated with the Oucher pain scale. Seventy-six percent of patients with this medication had less pain when compared with 20% of patients in the placebo group ($p=0.001$) (Sethna et al 2005). This is a well balanced study with good sample size and results seem to be valid.

A 20 minute application of Synera patch showed less pain in three randomized, double-blind, placebo-controlled studies that were conducted among adults and the geriatric population to evaluate the degree of dermal analgesia prior to venipuncture. Pain was measured using 100 mm visual analog scale in all three studies. The first study ($n=21$) showed median VAS scores of 1 and 9 for Synera and placebo treatments, respectively. The second study ($n=40$) showed median VAS scores of 5 and 28 for Synera and placebo treatments, respectively. The third study ($n=21$) showed median VAS scores of 1 and 9 for Synera and placebo treatments, respectively. The third study involved

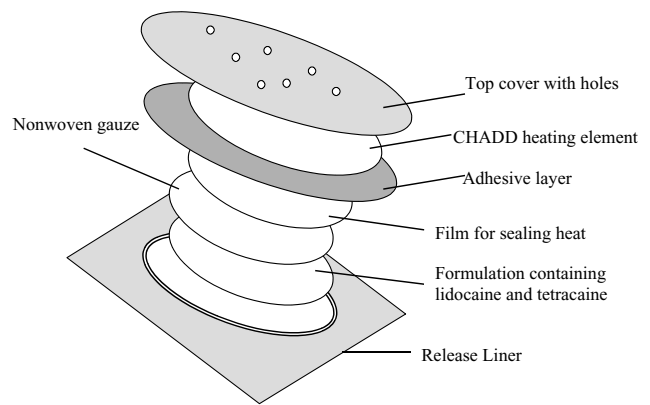


Figure 1 Illustration of Synera patch.

40 subjects over the age of 65 years, and the median VAS scores for Synera and placebo treatments were 8 and 14, respectively. In another double-blind study conducted in 250 adult subjects, comparing Synera patch intact with heating element and without heating element, the median VAS scores with heating and without heating element were 17 and 22, respectively (Endo Pharmaceuticals Inc. Packet insert for Synera™).

The local effects reported were transient mild erythema, edema (Sethna et al 2005), blanching (Endo Pharmaceuticals Inc. Packet insert for Synera™), and burning sensation (Berman et al 2005) resolving spontaneously soon after treatment. Contact with the eyes should be avoided as it may result in severe eye irritation based on animal studies (Endo Pharmaceuticals Inc. Packet insert for Synera™). There have been no reported systemic effects so far. In several studies conducted in both adults and children, either with a single or multiple Synera patches, the plasma levels of lidocaine and tetracaine were well below the toxic levels. Central nervous system toxicity may usually be seen at levels around 5000 ng/ml, though few patients may show signs of toxicity like excitation and or depression at plasma lidocaine levels of approximately 1000 ng/ml. In a study involving adults, the peak plasma levels of lidocaine were found to be less than 5 ng/ml, while levels of tetracaine were less than 0.9 ng/ml in all patients on application of one Synera patch for 30 minutes. When the duration of application was doubled to 60 minutes, there was no significant increase in plasma levels of both the agents. In children aged 4 months to 12 years, on application of one Synera patch for 30 min, the plasma levels of lidocaine and tetracaine were found to be 63 ng/ml and 65 ng/ml, respectively. Studies were also done to determine the plasma levels of lidocaine and tetracaine on simultaneous and sequential usage of multiple Synera patches in adults and children. Although these studies did

not show the levels of either lidocaine or tetracaine to reach toxic levels, application of multiple Synera patches is not recommended. In a clinical pharmacology study, when two or four Synera patches were applied simultaneously for 60 minutes, the peak plasma concentration of lidocaine were less than 9 ng/ml, while that of tetracaine were undetectable. On sequential 30 minute application of four Synera patches at 60 minute intervals, the peak plasma concentrations of lidocaine were less than 12 ng/ml and that of tetracaine were less than the quantitation limit. When two Synera patches were applied for up to 30 minutes in children of ages 4 months and 12 years, the peak levels of lidocaine and tetracaine were 331 ng/ml and less than 5 ng/ml, respectively (Endo Pharmaceuticals Inc. Packet insert for Synera™). Based on the results of the above mentioned studies, the usage of Synera patch seems to be safe and without major side effects. The usage of this patch is not recommended during magnetic resonance imaging as the heating element contains iron powder (Endo Pharmaceuticals Inc. Packet insert for Synera™). The advantages of using Synera over other topical products are ease of application, heat induced enhancement of solubility of drugs and their permeation, no reactions with the vehicle components, and no necessity for occlusive dressings. (see URL: <http://www.zars.com/scainepatch.html>). Most of all, from the data in the above mentioned studies, Synera patch, when used as recommended by the manufacturer, seems to be very safe and efficacious in delivering dermal anesthesia. The technique of using thermal energy for enhancement of drug penetration may be applied for producing local anesthesia with other agents as well.

Dentipatch

Dentipatch is an oral transmucosal delivery system containing lidocaine. This was the first bioadhesive patch developed for delivering local anesthesia to oral mucosa. It was introduced in the US in 1996 and is FDA-approved for providing mild topical anesthesia of accessible mucous membranes of the mouth prior to superficial dental procedures (Mantele et al 2005). This patch can also find its use in dermatology prior to procedures involving oral mucosa.

The dentipatch contains a viscous mixture of lidocaine, lecithin, propylene glycol, dipropylene glycol, glycerin, karaya gum, aspartame, and spearmint flavor. This mixture is coated onto a backing containing a polyester/ethylene vinyl acetate (EVA) film laminated to a polyester/rayon nonwoven fabric at a predetermined thickness. This is then dried in ovens to accelerate gelling process. Once the gelling is

completed, this is again laminated to the release liner. The current available product contains 46.1 mg of lidocaine which is 20 weight percent concentration in a bioadhesive matrix. It provides site-specific anesthetic effect where needed, when directly applied to the mucosa (Mantele et al 2005).

On application of the dentipatch for 15 minutes, anesthetic effect was found to be produced in 2.5 minutes, and the action lasted for 40 minutes after the removal of the patch. Two studies done to evaluate the efficacy of 10 and 20 weight percent lidocaine patches against placebo showed to provide effective anesthetic effect when tested with 25 gauge needle inserted unto bone. The plasma levels of lidocaine with 20 weight percent active patch at intervals of 15 and 45 minutes were found to be 9 times lesser than those achieved with injection of 2% lidocaine. Plasma levels of lidocaine with application of 5% lidocaine ointment were found to be at least double than those achieved with application of 20 weight percent of dentipatch for the same time period of 15 minutes. The most common local effect found was unpleasant taste. The other was minimal irritation (Hersh et al 1996; Mantele et al 2005).

Other patches

Other patches are also used for their systemic effects in the management of chronic pain states. One such patch is duragesic patch containing the opioid, fentanyl. This provides sustained analgesia around the clock. It finds application in the treatment of cancer and noncancer pain states. The lidoderm patch containing lidocaine 5% has been found to be useful in chronic pain states. It has been extensively studied and used for pain control in post-herpetic neuralgia. It has also been studied for pain control in osteoarthritis, myofascial pain, peripheral pain syndromes, chronic leg ulcers, allodynia, and erythromelalgia (Katz et al 2002; Davis 2003; Meier et al 2003; Gammaitoni et al 2003, 2004; Dalpiaz et al 2004).

S-Caine peel

This is a novel and innovative method of delivering topical anesthesia, mostly is being tested in the field of cosmetic dermatology. This is a cream-based preparation, made up of eutectic mixture of lidocaine 7% and tetracaine 7%. The inactive ingredients in the formulation are polyvinyl alcohol, lecithin, corn starch, and water (Chen et al 2003). When applied to the skin, it dries on exposure to air, forming a flexible membrane that can be easily peeled off. The advantage is that anesthesia is easily delivered to contours of the body without needing any occlusion (see URL:

<http://www.zars.com/scainepeel.html>). Its efficacy had been mostly tested for anesthesia that is necessary for laser procedures used in dermatology. A picture of S-Caine peel is provided by ZARS on their website at <http://www.zars.com/scainepeel.html>.

In comparative clinical studies with placebo, it has shown to provide effective anesthesia, and the time of onset was between 30 to 60 minutes. The level of anesthetic action needed depended on the specific type of lasers, such as pulsed dye laser, nonablative laser, and long-pulsed Nd: YAG laser, used for specific procedures (Bryan and Alster 2002; Doshi et al 2003; Jih et al 2004). The more the numbing effect is needed, the more time the peel should be left behind.

In a randomized, double-blind, placebo-controlled study involving 60 patients in three centers, S-Caine peel was found to provide safe and effective anesthesia in 20 to 30 minutes of application prior to treatment of portwine stains and facial telengectiasis using pulsed dye laser. Fifty-two percent of patients had VAS scores for pain as 10 mm and 72.2% of patients had VAS scores as 20 mm being on the active drug. The investigators and independent observer rated no pain in 75% and 72% of patients on the active drug, respectively. The high level of efficacy found in this study should be confirmed by further clinical evaluation (Bryan and Alster 2002). For treatment of leg veins using long-pulsed Nd: YAG laser treatment, S-Caine peel provided safe and highly effective anesthesia when applied for 60 minutes (Jih et al 2004). This was evaluated in a study involving 60 patients which was a randomized, double-blind, placebo-controlled study conducted at 2 centers ($p < 0.001$). In a multicentered, randomized, double-blind, placebo-controlled study conducted in 30 adult patients, who underwent laser-assisted tattoo removal, 70% of patients, S-Caine peel was found to have pain reduction when applied for 60 minutes (Chen et al 2005).

Local side effects thus far reported included transient mild erythema (Bryan and Alster 2002; Doshi et al 2003; Chen et al 2005). This interesting new invention seems to have advantages over classical topical anesthetics, in that it can be easily applied and removed, and the anesthetic effect generated depends on the duration of the peel left behind. More information pertaining to plasma levels of the active agents attained and potential side effects, if any, would be expected to be available once S-Caine peel is approved by the FDA.

Summary

Table 1 summarizes the various modes of penetration enhancements of the drugs discussed in this review.

Conclusion

Among the current available products, EMLA and LMX have been widely tested and are popular in clinical practice. With the invention of smaller and portable instruments, iontophoresis has considerable potential to regain its popularity. Synera patch, which was recently FDA-approved, would likely find more application because of its ease of usage, especially in the pediatric population. In the immediate future, S-Caine peel has potential to become popular in cosmetic dermatology procedures.

There has been significant research over the past decade in understanding the skin permeation mechanisms. The outcome of research in this area so far is reflected on the advances we are now seeing in the development of formulations and devices that optimize drug delivery, either by passive or active means, necessary for local and or systemic effects. More products in the form of patches with novel polymers for constructing the backing membranes and

Table 1 Modes of penetration enhancement

Medication	Concentration	Mode of penetration enhancement
EMLA	2.5% lidocaine and 2.5% prilocaine	<ul style="list-style-type: none"> • Occlusion • Eutectic mixture • Emulsion mixture • pH 9.4
LMX	4% or 5% lidocaine	<ul style="list-style-type: none"> • Liposomal carriage
Amethocaine gel	4% tetracaine	<ul style="list-style-type: none"> • Occlusion • Intrinsic lipophilic property
Betacaine-LA	Lidocaine, prilocaine, dibucaine, and phenylephrine	<ul style="list-style-type: none"> • Emulsion system
Topicaine 4%	4% lidocaine	<ul style="list-style-type: none"> • Occlusion
Topicaine 5%	5% lidocaine	<ul style="list-style-type: none"> • With/without occlusion • Micro-emulsion delivery system
Synera™ patch	Lidocaine 70 mg and tetracaine 70 mg	<ul style="list-style-type: none"> • Occlusive effect of patch • Self heating element
S-Caine peel	7% lidocaine and 7% tetracaine	<ul style="list-style-type: none"> • Occlusive effect resulting from the formation of tight flexible film over site of application.
TAC solution or gel	0.5% tetracaine, 0.05% epinephrine 1:2000, and cocaine 1:1.8%	<ul style="list-style-type: none"> • Passive diffusion
Iontophoresis	Charged drugs like lidocaine.	<ul style="list-style-type: none"> • Driven by electric current gradient

Abbreviations: EMLA, Eutectic mixture of local anesthetics; TAC, tetracaine, adrenaline, and cocaine.

adhesives, peels, and vesicles as drug carriers are likely to be the mode of drug delivery through the skin in future.

References

- Alkan M, Gefen Z, Golcman L. 1984. Wound infection after simple suture at the emergency ward. *Infection Control*, 5:562–4.
- Altieri M, Bogema S, Schwartz RH. 1990. TAC topical anesthesia produces positive urine tests for cocaine. *Ann Emerg Med*, 19:577–9.
- Altman DA, Gildenberg SR. 1999. High-energy pulsed light source hair removal device used to evaluate the onset of action of a new topical anesthetic. *Dermatol Surg*, 25:816–18.
- Anderson AB, Colecchi C, Baronoski R, et al. 1990. Local anesthesia in pediatric patients: topical TAC versus lidocaine. *Ann Emerg Med*, 19:519–22.
- Arendt-Neilsen L, Bjerring P, Nielsen J. 1990. Regional variations in analgesic efficacy of EMLA cream. Quantitatively evaluated by argon laser stimulation. *Acta Derm Venereol*, 70:314–18.
- Arendt-Nielsen L, Bjerring P. 1988. Laser-induced pain for evaluation of local analgesia. *Anesth Analg*, 67:115–23.
- Arevalo MI, Escribano E, Calpena A, et al. 2004. Rapid skin anesthesia using a new topical amethocaine formulation: a preclinical study. *Anesth Analg*, 98:1407–12.
- Ashburn MA, Gauthier M, Love G, et al. 1997. Iontophoretic administration of 2% lidocaine HCl and 1:100,000 epinephrine in humans. *Clin J Pain*, 13:22–6.
- Ashinoff R, Geronemus RG. 1990. Effect of the topical anesthetic EMLA on the efficacy of pulsed dye laser treatment of port-wine stains. *J Dermatol Surg Oncol*, 16:1008–11.
- AstraZeneca Pharmaceuticals, USA. 2004. Rev 05/05. EMLA full prescription information [online]. Accessed on 20 Aug 2005. URL: <http://www.astrazeneca-us.com/pi/EMLA.pdf>.
- Barker W, Rodeheaver GT, Edgerton MT, et al. 1982. Damage to tissue defenses by a topical anesthetic agent. *Ann Emerg Med*, 11:307–10.
- Barry B.W, Johnson P, Lloyd-Jones J.G. 1987. Transdermal drug delivery systems fundamentals and techniques. Chichester, UK: Ellis Horwood Publishers. p 200–223.
- Berger L. 2000. Freud: Darkness in the Midst of Vision. New York, NY: John Wiley & Sons, Inc. p 63–9.
- Berman B, Flores J, Pariser D, et al. 2005. Self-warming lidocaine/tetracaine patch effectively and safely induces local anesthesia during minor dermatologic procedures. *Dermatol Surg*, 31:135–8.
- Bernardi M, Secco F, Benec A. 1999. Anesthetic efficacy of an eutectic mixture of lidocaine and prilocaine (EMLA) on the oral mucosa: prospective double-blind study with a placebo. *Minerva Stomatol*, 48:39–43.
- Bjerring P, Andersen PH, Arendt-Nielsen L. 1989. Vascular response of human skin after analgesia with EMLA cream. *Br J Anaesth*, 63:655–60.
- Bjerring P, Arendt-Nielsen L. 1990. Depth and duration of skin analgesia to needle insertion after topical application of EMLA cream. *Br J Anaesth*, 64:173–7.
- Blackburn PA, Butler KH, Hughes MJ, et al. 1995. Comparison of tetracaine-adrenaline-cocaine (TAC) with topical lidocaine-epinephrine (TLE): efficacy and cost. *Am J Emerg Med*, 13:315–17.
- Blanke W, Hallern BV. 2003. Sharp wound debridement in local anaesthesia using EMLA cream: 6 years' experience in 1084 patients. *Eur J Emerg Med*, 10:229–31.
- Bonadio WA, Wagner V. 1988a. Efficacy of TAC topical anesthetic for repair of pediatric lacerations. *Am J Dis Child*, 142:203–5.
- Bonadio WA, Wagner V. 1988b. Half-strength TAC topical anesthetic. For selected dermal lacerations. *Clin Pediatr (Phila)*, 27:495–8.
- Bonadio WA, Wagner V. 1990. When TAC drips into the eye. *Am J Emerg Med*, 8:371.
- Brahma AK, Inkster C. 1995. Alkaline chemical ocular injury from EMLA cream. *Eye*, 9:658–9.
- Brisman M, Ljung BM, Otterbom I, et al. 1998. Methaemoglobin formation after the use of EMLA cream in term neonates. *Acta Paediatr*, 87:1191–4.
- Bronaugh RL, Miabach HI. 1985. Percutaneous absorption. New York, NY: Marcel Dekker.
- Bryan HA, Alster TS. 2002. The S-Caine peel: a novel topical anesthetic for cutaneous laser surgery. *Dermatol Surg*, 28:999–1003.
- Bucalo BD, Mirikitani EJ, Moy RL. 1998. Comparison of skin anesthetic effect of liposomal lidocaine, nonliposomal lidocaine, and EMLA using 30-minute application time. *Dermatol Surg*, 24:537–41.
- Bucks Daniel AW, Maibach HI. 2002. Occlusion does not uniformly enhance penetration in vivo. In: Bronaugh RL, Maibach HI, (ed). Topical absorption of dermatological products. New York, NY: Dekker, p 9–32.
- Cannon CR, Chouteau S, Hutchinson K. 1989. Topically applied tetracaine, adrenalin, and cocaine in the repair of traumatic wounds of the head and neck. *Otolaryngol Head Neck Surg*, 100:78–9.
- Chen JZ, Alexiades-Armenakas MR, Bernstein LJ, et al. 2003. Two randomized, double-blind, placebo-controlled studies evaluating the S-Caine Peel for the induction of local anesthesia before long-pulsed Nd: YAG laser therapy for leg veins. *Dermatol Surg*, 29:1012–18.
- Chen JZ, Jacobson LG, Bakus AD, et al. 2005. Evaluation of the S-Caine Peel for induction of local anesthesia for laser-assisted tattoo removal: randomized, double-blind, placebo-controlled, multicenter study. *Dermatol Surg*, 31:281–6.
- Chien YW. 1982. Novel drug systems. New York, NY: Dekker, p 149.
- Cleary GW. 1984. Transdermal controlled-release systems. In: Langer RS, Wise DL (ed). Medical applications of controlled release. Boca Raton: CRC Press, Inc. p 203–251.
- Covino BG. 1986. Pharmacology of local anaesthetic agents. *Br J Anaesth*, 58:701–16.
- Dailey RH. 1988. Fatality secondary to misuse of TAC solution. *Ann Emerg Med*, 2:159–160.
- Dalpia AS, Lordon SP, Lipman AG. 2004. Topical lidocaine patch therapy for myofascial pain. *J Pain Palliat Care Pharmacother*, 18:15–34.
- Davis MD. 2003. Lidocaine patch helpful in managing the chronic pain of leg ulceration. *J Am Acad Dermatol*, 49:964.
- Doshi SN, Friedman PM, Marquez DK, et al. 2003. Thirty-minute application of the S-Caine peel prior to nonablative laser treatment. *Dermatol Surg*, 29:1008–11.
- Dyke VC, Byck R. 1982. Cocaine. *Sci Am*, 246:128–41.
- Eaglstain FN. 1999. Chemical injury to the eye from EMLA cream during erbium laser resurfacing. *Dermatol Surg*, 25:590–1.
- Eichenfield LF, Funk A, Fallon-Friedlander S, et al. 2002. A clinical study to evaluate the efficacy of ELA-Max (4% liposomal lidocaine) as compared with eutectic mixture of local anesthetics cream for pain reduction of venipuncture in children. *Pediatrics*, 109:1093–9.
- Engberg G, Danielson K, Henneberg S, et al. 1987. Plasma concentrations of prilocaine and lidocaine and methaemoglobin formation in infants after epicutaneous application of a 5% lidocaine-prilocaine (EMLA). *Acta Anaesthesiol Scand*, 31:624–8.
- Eremia S, Newman N. 2000. Topical anesthesia for laser hair removal: comparison of spot sizes and 755 nm versus 800 nm wavelengths. *Dermatol Surg*, 26:667–9.
- Ernst AA, Marvez E, Nick TG, et al. 1995a. Lidocaine adrenaline tetracaine gel versus tetracaine adrenaline cocaine gel for topical anesthesia in linear scalp and facial lacerations in children aged 5 to 17 years. *Pediatrics*, 95:255–8.
- Ernst AA, Marvez E, Nick TG, et al. 1995b. Lidocaine adrenaline tetracaine gel versus tetracaine adrenaline cocaine gel for topical anesthesia in linear scalp and facial lacerations in children aged 5 to 17 years. *Am J Emerg Med*, 13:151–4.

- [ESBA] ESBA Laboratories. 2005. Information on Topical gel [online]. Accessed on 15 Aug 2005. URL: <http://www.topicalgel.com/>. ESBA Laboratories, Jupiter, FL, USA.
- Evers H, Von Dardel O, Juhlin L, et al. 1985. Dermal effects of compositions based on the eutectic mixture of lignocaine and prilocaine (EMLA). *Br J Anaesth*, 57:997–1005.
- Faulconer A Jr, Keys TE. 1965. Foundations of anesthesiology. Springfield, IL: CC Thomas, p 771.
- Fink BR. 1985. Leaves and needles: the introduction of surgical local anesthesia. *Anesthesiology*, 63:77–83.
- Finkel JC, Yang CI, Yarovitz JL, et al. 2002. Neuroselective sensory electrodiagnostic evaluation of 4% liposomal topical lidocaine. *Anesth Analg*, 94:1259–62.
- Flynn GL. 1979. Topical drug absorption and topical pharmaceutical systems. In: Banker GS, Rhodes CT (ed). Modern pharmaceuticals. New York, NY: Dekker, p 263.
- Friedman PM, Mafong EA, Friedman ES, et al. 2001a. Topical Anesthetics Update: EMLA and Beyond. *Dermatologic Surgery*, 27:1019–26.
- Friedman PM, Fogelman J, Levine V, et al. 2001. Comparative study of three topical anesthetics after 30 minutes application time, *Cosmetic Surgery Times*.
- Friedman PM, Fogelman JP, Nouri K, et al. 1999. Comparative study of the efficacy of four topical anesthetics. *Dermatol Surg*, 25:950–4.
- Friedman PM, Mafong EA, Friedman ES, et al. 2001b. Topical anesthetics update: EMLA and beyond. *Dermatol Surg*, 27:1019–26.
- Galinkin JL, Rose JB, Harris K, et al. 2002. Lidocaine iontophoresis versus eutectic mixture of local anesthetics (EMLA) for IV placement in children. *Anesth Analg*, 94:1484–8.
- Galvin JR, De Simone D. 1976. Infection rate of simple suturing. *J Am Coll Emerg Physicians*, 5:332–333.
- Gammaitoni AR, Alvarez NA, Galer BS. 2003. Safety and tolerability of the lidocaine patch 5%, a targeted peripheral analgesic: a review of the literature. *J Clin Pharmacol*, 43:111–17.
- Gammaitoni AR, Galer BS, Onawola R, et al. 2004. Lidocaine patch 5% and its positive impact on pain qualities in osteoarthritis: results of a pilot 2-week, open-label study using the Neuropathic Pain Scale. *Curr Med Res Opin*, 20(Suppl 2):S13–19.
- Gangarosa LP Sr, Ozawa A, Ohkido M, et al. 1995. Iontophoresis for enhancing penetration of dermatologic and antiviral drugs. *J Dermatol*, 22:865–75.
- Goodacre TE, Sanders R, Watts DA, et al. 1988. Split skin grafting using topical local anaesthesia (EMLA): a comparison with infiltrated anaesthesia. *Br J Plast Surg*, 41:533–8.
- Gosnold JK. 1977. Infection rate of sutured wounds. *Practitioner*, 218: 584–5.
- Grant SA, Hoffman RS. 1992. Use of tetracaine, epinephrine, and cocaine as a topical anesthetic in the emergency department. *Ann Emerg Med*, 21:987–97.
- Greenbaum SS, Bernstein EF. 1994. Comparison of iontophoresis of lidocaine with a eutectic mixture of lidocaine and prilocaine (EMLA) for topically administered local anesthesia. *J Dermatol Surg Oncol*, 20:579–83.
- Guardiano RA, Norwood CW. 2005. Direct comparison of EMLA versus lidocaine for pain control in Nd:YAG 1,064 nm laser hair removal. *Dermatol Surg*, 31:396–8.
- Gupta AK, Sibbald RG. 1996. Eutectic lidocaine/prilocaine 5% cream and patch may provide satisfactory analgesia for excisional biopsy or curettage with electrosurgery of cutaneous lesions. A randomized, controlled, parallel group study. *J Am Acad Dermatol*, 35:419–23.
- Guy RH, Hadgraft J. 1984. Pharmacokinetics of percutaneous absorption and concurrent metabolism. *Int J Pharm*, 20:43.
- Hallen B, Olsson GL, Uppfeldt A. 1984. Pain-free venepuncture. Effect of timing of application of local anaesthetic cream. *Anaesthesia*, 39:969–72.
- Hegenbarth MA, Altieri MF, Hawk WH, et al. 1990. Comparison of topical tetracaine, adrenaline, and cocaine anesthesia with lidocaine infiltration for repair of lacerations in children. *Ann Emerg Med*, 19:63–7.
- Hersh EV, Houpt MI, Cooper SA, Feldman RS, et al. 1996. Analgesic efficacy and safety of an intraoral lidocaine patch. *J Am Dent Assoc*, 127:1626–34.
- Higuchi T. 1977. Pro-drug, molecular structure and percutaneous delivery. In: Roche B (ed). Design of biopharmaceutical properties through pro-drugs and analogs. Washington, DC: APA. p 409–121.
- Hjorth N, Harring M, Hahn A. 1991. Epilation of upper lip hirsutism with a eutectic mixture of lidocaine and prilocaine used as a topical anesthetic. *J Am Acad Dermatol*, 25:809–11.
- Holm J, Andren B, Grafford K. 1990. Pain control in the surgical debridement of leg ulcers by the use of a topical lidocaine—prilocaine cream, EMLA. *Acta Derm Venereol*, 70:132–6.
- Holmes HS. 1994. Choosing a local anesthetic. *Dermatol Clin*, 12:817–2.
- Holmes MV, Dawe RS, Ferguson J, et al. 2004. A randomized, double-blind, placebo-controlled study of the efficacy of tetracaine gel (Ametop) for pain relief during topical photodynamic therapy. *Br J Dermatol*, 150:337–40.
- Holst RG, Kristofferson A. 1998. Lidocaine-prilocaine cream (EMLA Cream) as a topical anaesthetic for the cleansing of leg ulcers. The effect of length of application time. *Eur J Dermatol*, 8:245–7.
- Huang W, Vidimos A. 2000. Topical anesthetics in dermatology. *J Am Acad Dermatol*, 43:286–98.
- Idson B. 1976. Percutaneous absorption in topics in medicinal chemistry. In: Rabinowitz Myerson RM. (ed). Absorption phenomena. 4th ed. New York, NY: Wiley-Interscience. p 181.
- Ismail F, Goldsmith PC. 2005. Emla cream-induced allergic contact dermatitis in a child with thalassaemia major. *Contact Dermatitis*, 52:111.
- Jacobsen S. 1987. Errors in emergency practice. *Emerg Med*, 19:109.
- Jain A, Rutter N, Ratnayaka M. 2001. Topical amethocaine gel for pain relief of heel prick blood sampling: a randomised double-blind controlled trial. *Arch Dis Child Fetal Neonatal Ed*, 84:F56–9.
- Jain A, Rutter N. 2000. Does topical amethocaine gel reduce the pain of venepuncture in newborn infants? A randomised double-blind controlled trial. *Arch Dis Child Fetal Neonatal Ed*, 83:F207–10.
- Jih MH, Friedman PM, Sadick N, et al. 2004. 60-minute application of S-Caine Peel prior to 1,064 nm long-pulsed Nd:YAG laser treatment of leg veins. *Lasers Surg Med*, 34:446–50.
- Juhlin L, Evers H. 1990. EMLA: A New Topical Anesthetic. *Adv Dermatol*, 5:75–91.
- Juhlin L, Evers H, Broberg FA. 1980. lidocaine-prilocaine cream for superficial skin surgery and painful lesions. *Acta Derm Venereo*, 60:544–6.
- Juhlin L, Hagglund G, Evers H. 1989. Absorption of lidocaine and prilocaine after application of a eutectic mixture of local anesthetics (EMLA) on normal and diseased skin. *Acta Derm Venereol*, 69: 18–22.
- Juhlin L, Rollman O. 1984. Vascular effects of a local anesthetic mixture in atopic dermatitis. *Acta Derm Venereol*, 64:439–40.
- Kapelushnik J, Koren G, Solh H, et al. 1990. Evaluating the efficacy of EMLA in alleviating pain associated with lumbar puncture; comparison of open and double-blinded protocols in children. *Pain*, 42:31–4.
- Katz M. 1973. Design of topical drug product: pharmaceuticals. In: Ariens EJ (ed). Drug design. 4th ed. New York, NY: Acad Pr. p 93–148.
- Katz M, Poulsen BJ. 1971. Absorption of drugs through the skin. In: Brodie BB, Gillette J (ed). Handbook of experimental pharmacology. New York, NY: Springer-Verlag. p 28, 103.
- Katz NP, Gammaitoni AR, Davis MW, et al. 2002. Lidoderm Patch Study Group. Lidocaine patch 5% reduces pain intensity and interference with quality of life in patients with postherpetic neuralgia: an effectiveness trial. *Pain Med*, 3:324–32.

- Katz NP, Shapiro DE, Herrmann TE, et al. 2004. Rapid onset of cutaneous anesthesia with EMLA cream after pretreatment with a new ultrasound-emitting device. *Anesth Analg*, 98:371–6.
- Kearns GL, Heacock J, Daly SJ, et al. 2003. Percutaneous lidocaine administration via a new iontophoresis system in children: tolerability and absence of systemic bioavailability. *Pediatrics*, 112:578–82.
- Kleiber C, Sorenson M, Whiteside K, et al. 2002. Topical anesthetics for intravenous insertion in children: a randomized equivalency study. *Pediatrics*, 110:758–61.
- Koh JL, Harrison D, Myers R, et al. 2004. A randomized, double-blind comparison study of EMLA and ELA-Max for topical anesthesia in children undergoing intravenous insertion. *Paediatr Anaesth*, 14: 977–82.
- Kopecky EA, Jacobson S, Bch MB, et al. 2001. Safety and pharmacokinetics of EMLA in the treatment of postburn pruritus in pediatric patients: a pilot study. *J Burn Care Rehabil*, 22:235–42.
- Koppel RA, Coleman KM, Coleman WP. 2000. The efficacy of EMLA versus ELA-Max for pain relief in medium-depth chemical peeling: a clinical and histopathologic evaluation. *Dermatol Surg*, 26:61–4.
- Kundu S, Achar S. 2002. Principles of office anesthesia: part II. Topical anesthesia. *Am Fam Physician*, 66:99–102.
- Kurien L, Kollberg H, Uppfeldt A. 1985. Venepuncture pain can be reduced. *J Trop Med Hyg*, 88:397–9.
- Lahteenmaki T, Lillieborg S, Ohlson L, et al. 1988. Topical analgesia for the cutting of split-skin grafts: a multicenter comparison of two doses of a lidocaine/prilocaine cream. *Plast Reconstr Surg*, 82:458–62.
- Larsson BA, Norman M, Bjerring P, et al. 1996. Regional variations in skin perfusion and skin thickness may contribute to varying efficacy of topical, local anaesthetics in neonates. *Paediatr Anaesth*, 6: 107–10.
- Lawson RA, Smart NG, Gudgeon AC, et al. 1995. Evaluation of an amethocaine gel preparation for percutaneous analgesia before venous cannulation in children. *Br J Anaesth*, 75:282–5.
- Lener EV, Bucalo BD, Kist DA, et al. 1997. Topical anesthetic agents in dermatologic surgery. *Dermatol Surg*, 23:673–83.
- Liu DR, Kirchner HL, Petrack EM. 2003. Does using heat with eutectic mixture of local anesthetic cream shorten analgesic onset time? A randomized, placebo-controlled trial. *Ann Emerg Med*, 42:27–33.
- Lok C, Paul C, Amblard P, et al. 1999. EMLA cream as a topical anesthetic for the repeated mechanical debridement of venous leg ulcers: a double-blind, placebo-controlled study. *J Am Acad Dermatol*, 40: 208–13.
- Long CP, McCafferty DF, Sittlington NM, et al. 2004. Randomized trial of novel tetracaine patch to provide local anaesthesia in neonates undergoing venepuncture. *Br J Anaesth*, 92:450–1.
- Luhmann J, Hurt S, Shootman M, et al. 2004. A comparison of buffered lidocaine versus ELA-Max before peripheral intravenous catheter insertions in children. *Pediatrics*, 113:e217–20.
- Lycka BA. 1991. Medical indications for using a topical anesthetic. *Perspect Pain Manage*, 1:9–12.
- Lycka BA. 1992. EMLA. A new and effective topical anesthetic. *J Dermatol Surg Oncol*, 18:859–62.
- Maloney JM, Bezzant JL, Stephen RL, et al. 1992. Iontophoretic administration of lidocaine anesthesia in office practice: An appraisal. *J Dermatol Surg Oncol*, 1992 18:937–40.
- Mantele JA, Lucking D, Kanios DP, et al. 2005. Oral transmucosal systems for Local anesthetics: dental and oral surgical premedication In: Gosh TK, Pfister WR, (ed). Drug delivery to the oral cavity molecules to market. Boca Raton, FL: CRC Pr. p 233–259.
- Marty JP, Guy RH, Maibach HI. 1985. Percutaneous penetration as a method of delivery to muscle and other tissues. In: Bronaugh RL, Maibach HI (ed). Percutaneous absorption. New York, NY: Marcel Dekker.
- Mazumdar B, Tomlinson AA, Faulder GC. 1991. Preliminary study to assay plasma amethocaine concentrations after topical application of a new local anaesthetic cream containing amethocaine. *Br J Anaesth*, 67: 432–6.
- McCafferty DF, Woolfson AD. 1993. New patch delivery system for percutaneous local anesthesia. *Br J Anaesth*, 71:370–4.
- McCafferty DF, Woolfson AD, Boston V. 1989. In vivo assessment of percutaneous local anaesthetic preparations. *Br J Anaesth*, 62:17–21.
- McCafferty DF, Woolfson AD, Handley J, et al. 1997. Effect of percutaneous local anaesthetics on pain reduction during pulse dye laser treatment of portwine stains. *Br J Anaesth*, 78:286–9.
- McKinlay JR, Hofmeister E, Ross EV, et al. 1999. EMLA cream-induced eye injury. *Arch Dermatol*, 135:855–6.
- Meier T, Wasner G, Faust M, et al. 2003. Efficacy of lidocaine patch 5% in the treatment of focal peripheral neuropathic pain syndromes: a randomized, double-blind, placebo-controlled study. *Pain*, 106: 151–8.
- Miller KA, Balakrishnan G, Eichbauer G, et al. 2001. 1% lidocaine injection, EMLA cream, or “numby stuff” for topical analgesia associated with peripheral intravenous cannulation. *AANA J*, 69: 185–7.
- Moller C. 1985. A lignocaine-prilocaine cream reduces venipuncture pain. *Ups J Med Sci*, 90:293–8.
- Molodecka J, Stenhouse C, Jones JM, et al. 1994. Comparison of percutaneous anaesthesia for venous cannulation after topical application of either amethocaine or EMLA cream. *Br J Anaesth*, 72:174–6.
- Moore J. 2001. No more tears: a randomized controlled double-blind trial of Amethocaine gel vs. placebo in the management of procedural pain in neonates. *J Adv Nurs*, 34:475–82.
- Moppett IK, Szypula K, Yeoman PM. 2004. Comparison of EMLA and lidocaine iontophoresis for cannulation analgesia. *Eur J Anaesthesiol*, 21:210–3.
- Nichols FC III, Mucha P Jr, Farnell MB. 1987. TAC topical anesthetic and minor skin lacerations. *Resident and Staff Physician*, 33:59–66.
- Nunez M, Miralles ES, Boixeda P, et al. 1997. Iontophoresis for anesthesia during pulsed dye laser treatment of port-wine stains. *Pediatr Dermatol*, 14:397–400.
- O'Connor B, Tomlinson AA. 1995. Evaluation of the efficacy and safety of amethocaine gel applied topically before venous cannulation in adults. *Br J Anaesth*, 74:706–8.
- Olday SJ, Walpole R, Wang JY. 2002. Radial artery cannulation: topical amethocaine gel versus lidocaine infiltration. *Br J Anaesth*, 88: 580–2.
- Ordog GJ, Ordog C. 1994. The efficacy of TAC (tetracaine, adrenaline, and cocaine) with various wound-application durations. *Acad Emerg Med*, 1:360–3.
- Oshima T, Kashiki K, Toyooka H, et al. 1994. Cutaneous iontophoretic application of condensed lidocaine. *Can J Anaesth*, 41:677–9.
- Poulsen BJ. 1973. Design of topical drug products: biopharmaceutics. In: Ariens EJ (ed). Drug design. 4th ed. New York, NY: Acad Pr. p 149–192.
- Pryor GJ, Kilpatrick WR, Opp DR. 1980. Local anesthesia in minor lacerations: topical TAC vs lidocaine infiltration. *Ann Emerg Med*, 9:568–71.
- Ramos-Zabala A, Perez-Mencia MT, Fernandez-Garcia R, et al. 2004. Anesthesia technique for outpatient facial laser resurfacing. *Lasers Surg Med*, 34:269–72.
- Ranade VV, Hollinger Manfred A. 2003. Transdermal drug delivery. In: Drug delivery systems. 2nd ed. Boca Raton, FL: CRC Pr. p 207–40.
- Rincon E, Baker RL, Iglesias AJ, et al. 2000. CNS toxicity after topical application of EMLA cream on a toddler with molluscum contagiosum. *Pediatr Emerg Care*, 16:252–4.
- Ritchie JM, Greene NM. 1980. Local anesthetics. In: Goodman AG, Rall TW, Nies AS, et al (ed). The pharmacologic basis of therapeutics. 8th ed. New York, NY: Pergamon Pr. p 311–29.
- Rosdahl I, Edmar B, Gisslen H, et al. 1988. Curettage of molluscum contagiosum in children: analgesia by topical application of a lidocaine/prilocaine cream (EMLA). *Acta Derm Venereol*, 68: 149–53.
- Rose JB, Galinkin JL, Jantzen EC, et al. 2002. A study of lidocaine iontophoresis for pediatric venipuncture. *Anesth Analg*, 94:867–71.

- Rosenthal D, Murphy F, Gottschalk R, et al. 2001. Using a topical anaesthetic cream to reduce pain during sharp debridement of chronic leg ulcers. *J Wound Care*, 10:503–5.
- Russell SC, Doyle E. 1997. A risk-benefit assessment of topical percutaneous local anaesthetics in children. *Drug Saf*, 16:279–87.
- Rutherford WH, Spence RAJ. 1980. Infection in wounds sutured in the accident and emergency department. *Ann Emerg Med*, 9:350–2.
- Rylander E, Sjoberg I, Lillieborg S, et al. 1990. Local anesthesia of the genital mucosa with a lidocaine/prilocaine cream (EMLA) for laser treatment of condylomata acuminata: a placebo-controlled study. *Obstet Gynecol*, 75:302–6.
- Sarifakioglu N, Terzioglu A, Cigsar B, et al. 2004. EMLA and ear surgery: is it possible to achieve full-thickness anesthesia with EMLA? *Dermatol Surg*, 30:395–8.
- Schaefer H, Zesch A, Stutgen G. 1982. Skin permeability. Heidelberg: Springer-Verlag. p 604–7.
- Schaffer DJ. 1985. Clinical comparison of TAC anesthetic solutions with and without cocaine. *Ann Emerg Med*, 14:1077–80.
- Schecter AK. 2005. Randomized, double-blind, placebo-controlled study evaluating the lidocaine/tetracaine patch for induction of local anesthesia prior to minor dermatologic procedures in geriatric patients. *Dermatol Surg*, 31:287–9.
- Schilling CG, Bank DE, Borchert BA, et al. 1995. Tetracaine, epinephrine (adrenalin), and cocaine (TAC) versus lidocaine, epinephrine, and tetracaine (LET) for anesthesia of lacerations in children. *Ann Emerg Med*, 25:203–8.
- Schultz AA, Strout TD, Jordan P, et al. 2002. Safety, tolerability, and efficacy of iontophoresis with lidocaine for dermal anesthesia in ED pediatric patients. *J Emerg Nurs*, 28:289–96.
- Schuplein RJ. 1978. The skin as a barrier, skin permeation, site variation in diffusion and permeability. In: Jarret A, (ed). Physiology and pathophysiology of the skin. New York, NY: Acad Pr. p 1693–731.
- Sethna NF, Verghese ST, Hannallah RS, et al. 2005. A randomized controlled trial to evaluate S-Caine Patch for reducing pain associated with vascular access in children. *Anesthesiology*, 102:403–8.
- Shelley WB. 1975. The razor blade in dermatologic practice. *Cutis*, 16: 843–4.
- Sherwin J, Awad IT, Sadler PJ, et al. 2003. Analgesia during radial artery cannulation: comparison of the effects of lidocaine applied by local injection or iontophoresis. *Anaesthesia*, 58:474–6.
- Sherwood KA. 1993. The use of topical anesthesia in removal of port-wine stains in children. *J Pediatr*, 122:S36 40.
- Shomaker TS, Zhang J, Love G, et al. 2000. Evaluating skin anesthesia after administration of a local anesthetic system consisting of an S-Caine Patch and a controlled heat-aided drug delivery (CHADD) patch in volunteers. *Clin J Pain*, 16:200–4.
- Smith DP, Gjellum M. 2004. The efficacy of LMX versus EMLA for pain relief in boys undergoing office meatotomy. *J Urol*, 172:1760–1.
- Smith GA, Strausbaugh SD, Harbeck-Weber C, et al. 1996. Comparison of topical anesthetics without cocaine to tetracaine-adrenaline-cocaine and lidocaine infiltration during repair of lacerations: bupivacaine-norepinephrine is an effective new topical anesthetic agent. *Pediatrics*, 97:301–7.
- Smith GA, Strausbaugh SD, Harbeck-Weber C, et al. 1997. New non-cocaine-containing topical anesthetics compared with tetracaine-adrenaline-cocaine during repair of lacerations. *Pediatrics*, 100: 825–30.
- Smith SM, Barry RC. 1990. A comparison of three formulations of TAC (tetracaine, adrenalin, cocaine) for anesthesia of minor lacerations in children. *Pediatr Emerg Care*, 6:266–70.
- Squire SJ, Kirchoff KT, Hissong K. 2000. Comparing two methods of topical anesthesia used before intravenous cannulation in pediatric patients. *Pediatr Health Care*, 14:68–72.
- Strout TD, Schultz AA, Baumann MR, et al. 2004. Reducing pain in ED patients during lumbar puncture: the efficacy and feasibility of iontophoresis, collaborative approach. *J Emerg Nurs*, 30:423–30.
- Stymne B, Lillieborg S. 2001. Plasma concentrations of lignocaine and prilocaine after a 24-h application of analgesic cream (EMLA) to leg ulcers. *Br J Dermatol*, 145:530–4.
- Tan OT, Stafford TJ. 1992. EMLA for laser treatment of portwine stains in children. *Laser Surg Med*, 12:543–8.
- Terndrup TE, Walls HC, Mariani PJ, et al. 1992. Plasma cocaine and tetracaine levels following application of topical anesthesia in children. *Ann Emerg Med*, 21:162–6.
- Tipton GA, DeWitt GW, Eisenstein SJ. 1989. Topical TAC (tetracaine, adrenaline, cocaine) solution for local anesthesia in children: prescribing inconsistency and acute toxicity. *South Med J*, 82:1344–6.
- Tran NQ, Pretto JJ, Worsnop CJ. 2002. A randomized controlled trial of the effectiveness of topical amethocaine in reducing pain during arterial puncture. *Chest*, 122:1357–60.
- Vinci RJ, Fish SS. 1996. Efficacy of topical anesthesia in children. *Arch Pediatr Adolesc Med*, 150:466–9.
- Wahlgren CF, Quiding H. 2000. Depth of cutaneous analgesia after application of a eutectic mixture of the local anesthetics lidocaine and prilocaine (EMLA cream). *J Am Acad Dermatol*, 42:584–8.
- Watson J, Boulanger A, Trechot PH, et al. 2004. Contact urticaria from Emla cream. *Contact Dermatitis*, 51:284–7.
- Watson K. 1986. Astra markets cream to remove pain of injections. *Pharm J*, 236:262.
- Wehle B, Bjornstrom M, Cedgard M, et al. 1989. Repeated application of EMLA cream 5% for the alleviation of cannulation pain in haemodialysis. *Scand J Urol Nephrol*, 23:299–302.
- Wehner D, Hamilton GC. 1984. Seizures following topical application of local anesthetics to burn patients. *Ann Emerg Med*, 13:456–8.
- White WB, Iserson KV, Criss E. 1986. Topical anesthesia for laceration repair: tetracaine versus TAC (tetracaine, adrenaline, and cocaine). *Am J Emerg Med*, 4:319–22.
- Woodford R, Barry BW. 1986. Penetration enhancers and the percutaneous absorption of drugs: an update. *J Toxicol Cut Ocular Toxicol*, 5: 167–77.
- Yun PL, Tachihara R, Anderson RR. 2002. Efficacy of erbium:yttrium-aluminum-garnet laser-assisted delivery of topical anesthetic. *J Am Acad Dermatol*, 47:542–7.
- ZARS. 2005. Information on S-Caine Peel [online]. Accessed on 20 Jul 2005. URL: <http://www.zars.com/scainepeel.html>. ZARS, UT, USA.
- ZARS. 2005. Information on Synera [online]. Accessed on 20 Jul 2005. URL: <http://www.zars.com/scainepatch.html>. ZARS, UT, USA.
- Zempsky WT, Anand KJ, Sullivan KM, et al. 1998. Lidocaine iontophoresis for topical anesthesia before intravenous line placement in children. *J Pediatr*, 132:1061–3.
- Zempsky WT, Parkinson TM. 2003a. Lidocaine iontophoresis for topical anesthesia before dermatologic procedures in children: a randomized controlled trial. *Pediatr Dermatol*, 20:364–8.
- Zempsky WT, Parkinson TM. 2003b. Lidocaine iontophoresis for local anesthesia before shave biopsy. *Dermatol Surg*, 29:627–30.
- Zempsky WT, Sullivan J, Paulson DM, et al. 2004. Evaluation of a low-dose lidocaine iontophoresis system for topical anesthesia in adults and children: a randomized, controlled trial. *Clin Ther*, 26:1110–19.
- Zimmer R, Ashburn MA. 2001. Noninvasive drug delivery. *Compr Ther*, 27:293–301.

