

Fetoscopic Laser Photocoagulation for Stage II TTTS in a Resource-Limited Setting: A Case Report on the Persisting Challenge of Extreme Prematurity

Moch Erwin Jaya Sanjaya , Dennis Fachmi Ardiansyah ,
Bahar Sangkur Gusasih , Dani Setiawan , Adhi Pribadi 

Division of Maternal-Fetal Medicine, Department of Obstetrics and Gynecology, Faculty of Medicine, Padjadjaran University/Dr. Hasan Sadikin General Hospital, Bandung, Indonesia

Correspondence: Bahar Sangkur Gusasih, Division of Maternal-Fetal Medicine, Department of Obstetrics and Gynecology, Faculty of Medicine, Padjadjaran University/Dr. Hasan Sadikin General Hospital, Bandung, Indonesia, Tel +62 813-8885-7906, Email bahar21001@mail.unpad.ac.id



Background: Twin-to-Twin Transfusion Syndrome (TTTS) is a severe complication in monochorionic pregnancies. Fetoscopic laser photocoagulation (FLPC) is the standard of care for advanced stages. However, data regarding neonatal outcomes following FLPC in resource-limited settings, where neonatal intensive care capabilities may be constrained, remain scarce.

Case Presentation: We report the case of a 33-year-old woman (G4P2A1) diagnosed with TTTS Quintero stage II at 21 weeks of gestation. She presented with significant pre-existing uterine contractions. Following a decompressive amnioreduction, she underwent selective FLPC which successfully resolved the “stuck twin” phenomenon in the donor twin. Despite the technical success of the fetal intervention, the patient experienced worsening preterm labor resulting in delivery at 24 weeks and 4 days. Both infants were born alive but succumbed to complications of extreme prematurity given the limited availability of advanced neonatal life support.

Conclusion: This case highlights the critical need for strategies to mitigate iatrogenic prematurity following successful fetal therapy in resource-limited settings. While FLPC effectively corrects fetal pathophysiology, the ultimate survival is heavily dependent on the capacity of the healthcare system to manage the subsequent extreme prematurity.

Keywords: twin-to-twin transfusion syndrome, fetoscopic laser photocoagulation, neonatal outcome, fetal therapy, resource-limited setting

Introduction

Twin-to-Twin Transfusion Syndrome (TTTS) is one of the most serious complications in monochorionic twin pregnancies. The diagnosis is established via ultrasonography based on the presence of a polyhydramnios-oligohydramnios sequence and is classified using the Quintero staging system. Without intervention, TTTS carries a poor prognosis. Currently, fetoscopic laser photocoagulation (FLPC) is the standard treatment for advanced-stage TTTS (Quintero stage II and above) due to its effectiveness in interrupting abnormal vascular connections between twins.^{1,2} However, despite its success, FLPC is associated with significant procedural risks. The intervention can trigger iatrogenic preterm premature rupture of membranes (iPPROM) and preterm labor, mechanisms potentially driven by trocar-induced inflammation or chorioamniotic separation, which critically influence neonatal outcomes.² Furthermore, while outcomes in high-resource centers are well-documented, there is a paucity of literature describing the challenges of this advanced intervention in resource-limited settings, where neonatal survival is often compromised by structural constraints. This report aims to present a case of Quintero stage II twin-to-twin transfusion syndrome managed with selective fetoscopic laser photocoagulation in a resource-limited setting, emphasizing the procedural success and the persisting challenge of neonatal survival due to extreme prematurity.

Case Presentation

A 33-year-old woman, Gravida 4, Para 2, Abortus 1, was referred to our institution, a national tertiary referral hospital, at 21 weeks of gestation. She presented with a history of rapidly increasing fundal height since 16 weeks and progressively frequent uterine contractions. Ultrasonographic examination confirmed a live monochorionic diamniotic twin pregnancy with a classic polyhydramnios-oligohydramnios sequence.

Twin A, the recipient, had an estimated fetal weight (EFW) of 392 grams (consistent with 20 6/7 weeks), polyhydramnios, a visible and filled urinary bladder, and normal Doppler studies. In contrast, Twin B, the donor, had an EFW of 364 grams (consistent with 20 3/7 weeks) and severe oligohydramnios. The donor twin appeared immobile and “stuck” to the posterior uterine wall, with a non-visible urinary bladder, confirming a “stuck twin” phenomenon (Figure 1). Based on these findings, a diagnosis of TTTS Quintero stage II was established.

Prior to the laser procedure, a decompressive amnioreduction of 1000 cc was performed. This maneuver was technically necessary to improve fetoscopic visualization, which was otherwise obscured by massive polyhydramnios, and to reduce severe uterine overdistension to facilitate safer trocar entry. Following this stabilization, selective FLPC was performed, during which four distinct arteriovenous anastomoses on the placental vascular equator were identified and coagulated (Figure 2). Immediate post-procedural evaluation revealed a marked improvement in the donor twin’s condition, evidenced by an increase in its amniotic fluid volume and the reappearance of its urinary bladder, indicating resolution of the “stuck twin” status.

The patient was subsequently monitored on an outpatient basis. At 24 weeks’ gestation, she presented again with worsening uterine contractions. An ultrasound evaluation at this time showed appropriate interval growth for both fetuses, with adequate amniotic fluid and reassuringly normal doppler studies. She was hospitalized for intensive tocolysis and administration of antenatal corticosteroids.

Despite these measures, at 24 weeks and 4 days of gestation, she progressed into active preterm labor, resulting in the delivery of both infants. Both male infants were delivered alive, with birth weights of 613 grams and 600 grams, respectively. Unfortunately, both neonates died within 24 hours of delivery due to complications of extreme prematurity. The mother’s postoperative course was uneventful, and she was discharged two days later in stable condition. The postnatal placental examination confirmed the coagulated anastomoses (Figure 3).

Ethical approval was not required for this single-patient case report according to the institutional policy of the Faculty of Medicine, Padjadjaran University / Dr. Hasan Sadikin General Hospital Bandung, and written informed consent for publication was obtained.

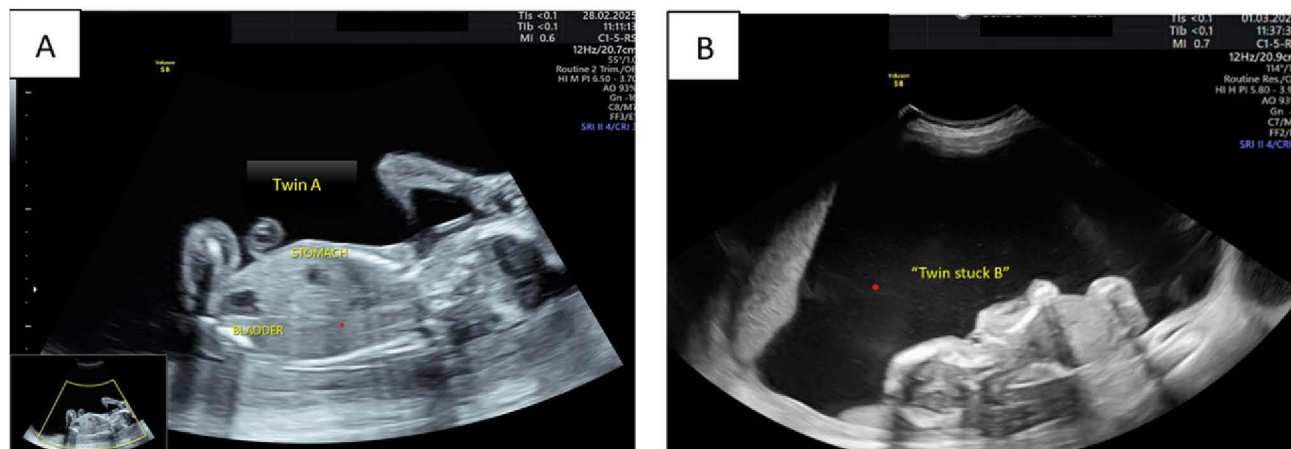


Figure 1 Ultrasound examination prior to intervention. (A) Twin A (recipient) shows polyhydramnios with a visible urinary bladder. (B) Twin B (donor) presents with severe oligohydramnios, positioned against the posterior uterine wall (“stuck twin”) with an unvisualized urinary bladder. These findings confirm the classic polyhydramnios-oligohydramnios sequence characteristic of Quintero Stage II TTTS.

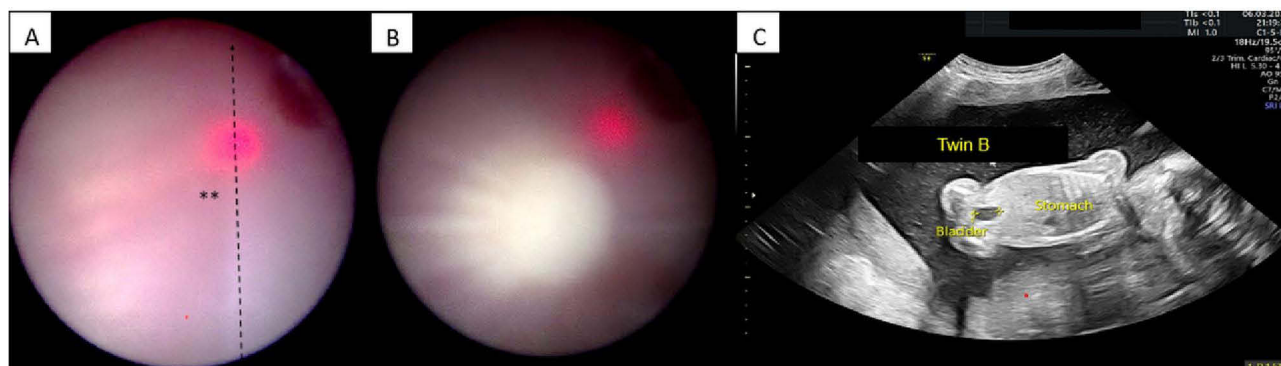


Figure 2 Fetoscopic Laser Photocoagulation procedure. (A) The dashed black line indicates the vascular equator on the placenta. (B) White spots represent the sites of laser coagulation targeting the arteriovenous anastomoses. (C) Twenty-four hours post-procedure ultrasound showing increased amniotic fluid volume and a visible urinary bladder in Twin B. This reappearance of the donor bladder and fluid normalization indicates the successful interruption of the inter-twin vascular shunts and resolution of the “stuck twin” phenomenon.

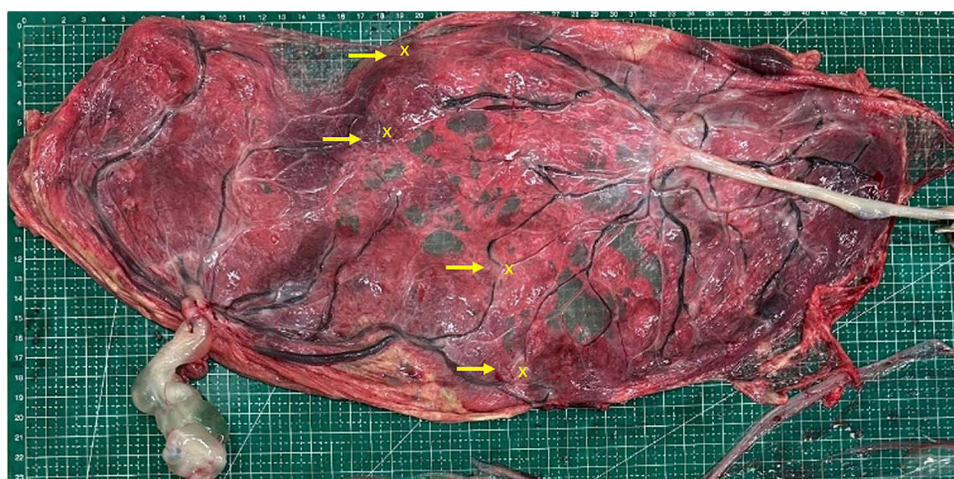


Figure 3 Postnatal placental examination. The yellow arrows indicate the sites of the arteriovenous anastomoses (AVA), and the “x” marks the coagulated areas. Macroscopic inspection confirmed that all identified communicating vessels were successfully ablated, with no residual patent anastomoses observed.

Discussion

This case report illustrates a critical dichotomy in the management of advanced TTTS: the technical success of FLPC in reversing fetal pathophysiology, which is subsequently challenged by the devastating consequence of extreme preterm delivery. Our patient, diagnosed with Quintero stage II TTTS, experienced a complete resolution of the “stuck twin” phenomenon post-FLPC, only to deliver at 24 weeks’ gestation with subsequent neonatal loss.

The patient’s presentation aligns with the classic pathophysiology of TTTS, driven by unbalanced unidirectional arteriovenous (AVA) anastomoses on the monochorionic placenta.^{1,2} Management of TTTS is strictly guided by the Quintero staging system, which stratifies the disease’s severity (Table 1).^{3,4} Given the diagnosis of Quintero stage II in our patient—defined by a non-visible donor bladder—and the associated mortality rate exceeding 90% for untreated cases, intervention was mandatory.⁴ Our decision to perform FLPC is therefore consistent with current international guidelines, which recommend it as the standard of care over other options like serial amnioreduction.^{5,6} The immediate improvement in the donor twin’s amniotic fluid and bladder visibility post-procedure directly demonstrates the procedure’s effectiveness in correcting the underlying hemodynamic imbalance.

Despite this initial success, the clinical course highlights the most significant complication of FLPC: iatrogenic prematurity. The progression to preterm labor in our patient at 24 weeks is a stark reminder of this risk. The mechanisms driving this outcome are multifactorial. Procedural trauma can lead to trocar-induced chorioamniotic separation and stimulate a local

Table 1 Quintero Classification of Twin-to-Twin Transfusion Syndrome^{3,4}

Stage	Classification
I	Poly-Oligohydramnios sequence, MVP (maximum vertical pocket) > 8 cm in the recipient twin, and MVP < 2 cm in the donor twin.
II	The bladder of the donor twin is not visible on ultrasound
III	Absent and reverse diastolic flow in the umbilical artery, Reversed a-wave flow in the ductus venosus, or pulsatile umbilical venous flow in either twin.
IV	Hydrops in one or both twins.
V	Death of one or both twins.

inflammatory cascade, resulting in microstructural changes to the amniotic membrane that weaken its integrity and trigger uterine contractility.^{7,8} This risk is particularly pronounced in procedures performed at early gestational ages, as in our case at 21 weeks.

Furthermore, it is critical to highlight that our patient presented with progressively frequent uterine contractions even prior to the intervention. This pre-existing uterine irritability constituted a significant independent risk factor for preterm delivery, placing the patient in a high-risk category regardless of the procedural insult. Consequently, the FLPC procedure likely acted as a precipitating event on a uterus that was already primed for labor, rather than being the sole cause of the adverse neonatal outcome.^{9,10}

Crucially, this case underscores the distinct challenges of managing TTTS in a resource-limited setting, which differs significantly from high-income environments. First, the delay between symptom onset (16 weeks) and referral (21 weeks) highlights unique socio-cultural barriers; in our context, medical decision-making is often communal, requiring extended time to reach a “family consensus” before consent for novel interventions like FLPC can be obtained. Second, neonatal survival is heavily compromised by structural and economic constraints. Our tertiary center faces extremely high demand with limited NICU capacity. Furthermore, access to essential therapeutics for extreme prematurity, such as surfactant, remains a challenge as these are often not fully covered by the national social health insurance scheme. Consequently, pre-procedural counseling in our setting is distinct; it necessitates a transparent discussion not only about surgical risks but also about the financial and logistical implications of neonatal intensive care, which remain critical determinants of the final outcome.

We acknowledge the limitations inherent in a single case report. We cannot establish a definitive causal link between a specific procedural aspect and the onset of preterm labor. Furthermore, while factors like cervical length are known predictors, a full analysis of all contributing factors for this specific patient is not possible.

Nevertheless, this case provides a valuable clinical lesson. While survival rates for at least one twin following FLPC in high-resource centers now exceed 80–90%,⁷ outcomes in developing nations remain constrained by limited neonatal infrastructure. Recent data from resource-limited settings suggest that despite successful laser ablation, neonatal mortality remains disproportionately high due to the complications of prematurity.¹¹ The management of the subsequent high risk of extreme prematurity is an integral, and perhaps more challenging, part of the patient’s care. This underscores the need for comprehensive pre-procedural counseling regarding the dual nature of hope and risk, and the critical importance of intensive post-procedural monitoring for early signs of preterm labor.

Conclusion

This case demonstrates that while FLPC is highly effective in correcting the underlying pathophysiology of TTTS, its clinical success in a resource-limited setting is critically dependent on the subsequent neonatal intensive care capabilities. The ultimate survival was precluded by extreme prematurity, compounded by structural and economic barriers typical of developing nations. Therefore, in such settings, “success” cannot be defined by surgical endpoints alone. Clinical management must integrate comprehensive pre-procedural counseling that transparently addresses these logistical and financial realities. Future efforts should focus not only on expanding surgical expertise but also on health policy advocacy to improve financial coverage for essential neonatal therapeutics, ensuring that fetal salvage can translate into intact neonatal survival.

Disclosure

The authors report no conflicts of interest in this work.

References

1. Dashe JS, Levine D, Simpson LL. *Fetology: Diagnosis and Management of the Fetal Patient*. 2nd ed. New York: McGraw-Hill Education; 2017.
2. Deprest J, Flake AW, Gratacós E, et al. *Fetal Therapy: Scientific Basis and Critical Appraisal of Clinical Benefits*. 2nd ed. Boca Raton: CRC Press; 2021.
3. Khalil A, Rodgers M, Baschat A, et al. ISUOG Practice Guidelines: role of ultrasound in twin pregnancy. *Ultrasound Obstet Gynecol*. 2016;47(2):247–263. doi:10.1002/uog.15821
4. Quintero RA, Morales WJ, Allen MH, et al. Staging of twin–twin transfusion syndrome. *J Perinatol*. 1999;19(8):550–555. doi:10.1038/sj.jp.7200292
5. Society for Maternal-Fetal Medicine (SMFM). Clinical guideline for the diagnosis and management of twin-to-twin transfusion syndrome. *Am J Obstet Gynecol*. 2020;222(2):B2–B15.
6. Van Mieghem T, Baschat AA, Klaritsch P, et al. Fetal interventions in twin pregnancies. *Best Pract Res Clin Obstet Gynaecol*. 2014;28(2):305–317. doi:10.1016/j.bpobgyn.2013.11.004
7. Seaman RD, Salmanian B, Amini A, et al. Pregnancy outcomes following early fetoscopic laser photocoagulation for twin-to-twin transfusion syndrome at 16 weeks' gestation. *Am J Obstet Gynecol MFM*. 2023;5(1):100762. doi:10.1016/j.ajogmf.2022.100771
8. Hecher K, Diehl W, Ziklunig L, et al. Endoscopic laser surgery for twin-to-twin transfusion syndrome: comparative outcome in 200 consecutive cases. *Am J Obstet Gynecol*. 2000;182(5):1176–1184. doi:10.1067/mob.2000.105157
9. Malshe A, Snowise S, Mann LK, et al. Preterm delivery after fetoscopic laser surgery for twin-twin transfusion syndrome: etiology and risk factors. *Ultrasound Obstet Gynecol*. 2017;49(5):612–616. doi:10.1002/uog.15972
10. Rüegg L, Hüsler M, Krähenmann F, et al. Outcome after fetoscopic laser coagulation in twin-twin transfusion syndrome - is the survival rate of at least one child at 6 months of age dependent on preoperative cervical length and preterm prelabour rupture of fetal membranes? *J Matern Fetal Neonatal Med*. 2018;31(15):1961–1967. doi:10.1080/14767058.2017.1334812
11. Bhatia V, Chawla D, Naganur S, et al. Fetoscopic laser for twin-twin transfusion syndrome: a single center experience from North India. *J Obstet Gynaecol India*. 2019;69(4):329–334. doi:10.1007/s13224-019-01216-9

International Medical Case Reports Journal

Publish your work in this journal

The International Medical Case Reports Journal is an international, peer-reviewed open-access journal publishing original case reports from all medical specialties. Previously unpublished medical posters are also accepted relating to any area of clinical or preclinical science. Submissions should not normally exceed 2,000 words or 4 published pages including figures, diagrams and references. The manuscript management system is completely online and includes a very quick and fair peer-review system, which is all easy to use. Visit <http://www.dovepress.com/testimonials.php> to read real quotes from published authors.

Submit your manuscript here: <https://www.dovepress.com/international-medical-case-reports-journal-journal>

Dovepress
Taylor & Francis Group