

Minimizing Post-Operative Scars in External Dacryocystorhinostomy: A Literature Review

Lars Christian Boberg-Ans^{1,2}, Sophie Boberg-Ans^{3,4}, Ayyad Zartasht Khan^{5,6}, Richard Cutler Allen⁷, Kim Alexander Tønseth⁸, Elin Bohman⁹, Tor Paaske Utheim^{5,6,10–25}, Fredrik Andreas Fineide^{5,14,16,23,24}

¹Department of Ophthalmology, University Hospital of Southern Denmark, Vejle, Denmark; ²Department of Ophthalmology, Innlandet Hospital Trust, Elverum, Norway; ³Nordic House of Advanced Dentistry and Oral Surgery, Specialist Referral Practice, Lyngby, Denmark; ⁴Department of Oral and Maxillofacial Surgery, Odense University Hospital, Odense, Denmark; ⁵Department of Ophthalmology, Østfold Hospital Trust, Moss, Norway; ⁶Department of Ophthalmology, Sorlandet Hospital Trust, Arendal, Norway; ⁷Department of Ophthalmology, Baylor College of Medicine, Houston, TX, USA; ⁸Department of Plastic and Reconstructive Surgery, Oslo University Hospital & Institute of Clinical Medicine, University of Oslo, Oslo, Norway; ⁹Department of Clinical Neuroscience, Division of Eye and Vision, Karolinska Institutet & St. Erik Eye Hospital, Stockholm, Sweden; ¹⁰Department of Ophthalmology, Oslo University Hospital, Oslo, Norway; ¹¹Department of Ophthalmology, Stavanger University Hospital, Oslo, Norway; ¹²Department of Ophthalmology, Vestre Viken Hospital Trust, Drammen, Norway; ¹³Department of Ophthalmology, Vestfold Hospital, Tønsberg, Norway; ¹⁴Department of Medical Biochemistry, Oslo University Hospital, Oslo, Norway; ¹⁵Department of Life Sciences and Health, Oslo Metropolitan University, Oslo, Norway; ¹⁶Department of Plastic and Reconstructive Surgery, Oslo University Hospital, Oslo, Norway; ¹⁷Institute of Clinical Medicine, Faculty of Medicine, University of Oslo, Oslo, Norway; ¹⁸Department of Quality and Health Technology, The Faculty of Health Sciences, University of Stavanger, Stavanger, Norway; ¹⁹Department of Oral Biology, Faculty of Dentistry, University of Oslo, Oslo, Norway; ²⁰National Centre for Optics, Vision and Eye Care, Department of Optometry, Radiography and Lighting Design, Faculty of Health Sciences, University of South-Eastern Norway, Kongsberg, Norway; ²¹Department of Health and Nursing Science, The Faculty of Health and Sport Sciences, University of Agder, Grimstad, Norway; ²²Department of Ophthalmology, Faculty of Life Course Sciences and Medicine, King's College London, London, UK; ²³The Norwegian Dry Eye Clinic, Oslo, Norway; ²⁴Department of Computer Science, Oslo Metropolitan University, Oslo, Norway; ²⁵Department of Product Design, Oslo Metropolitan University, Oslo, Norway

Correspondence: Lars Christian Boberg-Ans, Department of Ophthalmology, University Hospital of Southern Denmark, Beriderbakken 4, DK-7100, Vejle, Denmark, Email boberg-ans@hotmail.com

Purpose: This literature review examines the literature on surgical modifications and post-operative strategies designed to minimize visible scarring following external dacryocystorhinostomy (Ext-DCR).

Methods: A comprehensive search of PubMed, Medline, Embase, Cochrane Central, and CINAHL databases was performed on July 25th 2024, to identify studies evaluating scar formation after Ext-DCR. Studies were included if they assessed incision techniques, closure methods, or post-operative care protocols and reported aesthetic outcomes related to scar visibility.

Results: Forty studies comprising 3750 Ext-DCR procedures with scar reports from 3715 individuals met the inclusion criteria. The prevalence of visible scarring varied widely (0–50%), though most studies reported rates below 10%. Techniques associated with improved aesthetic outcomes included alternative incision designs, minimal incision approaches, and sutureless skin closures.

Conclusion: Various surgical modifications have demonstrated potential in reducing visible scarring after Ext-DCR; however, no single technique has achieved universal acceptance. Tailoring incision design and closure techniques based on patient-specific factors, including skin type and aesthetic concerns, has been reported to improve outcomes. Future studies should incorporate standardized scar assessment scales to facilitate direct comparisons and optimize best practices in Ext-DCR surgery.

Keywords: dacryocystorhinostomy, cicatrix, surgical incisions, esthetics, patient satisfaction, suture techniques

Introduction

External dacryocystorhinostomy (Ext-DCR) remains the gold standard for treating nasolacrimal duct obstruction due to its high success rate and cost-effectiveness. However, visible post-operative scarring represents a significant drawback. Despite the availability of endonasal techniques that avoid cutaneous scars, Ext-DCR remains widely used because of its consistently high functional success rate, straightforward technique, and accessibility in low-resource settings.^{1–4}

However, visible scarring following Ext-DCR is a concern for many patients and surgeons. According to Huang et al, scarring after Ext-DCR was described as cosmetically unacceptable in 11% of cases.⁵

To minimize scarring, various alterations to the original Ext-DCR technique described in 1904 by Toti et al have been proposed.⁶ In the present review, we synthesize the existing scientific literature on strategies to reduce or minimize post-operative scarring in Ext-DCR. To the best of our knowledge, such a literature review has not been published during the last decade.

Methods

This systematic review analyzed the scientific literature focusing on surgical tools and techniques, postoperative care methods, and patient-related factors such as skin complexion, with the aim of reducing scar formation after external dacryocystorhinostomy (Ext-DCR). All surgical techniques and postoperative protocols were eligible for inclusion.

Eligibility Criteria

Outcomes of interest included the appearance and severity of postoperative scars, patient satisfaction with scar outcomes, and the incidence of complications such as hypertrophic scars or keloids. No restrictions were imposed on the definitions of scar assessment or the methods used to evaluate outcomes; each study's definitions and methods were reported. Only studies published in English were eligible.

Search Strategy

A literature search was performed on July 25, 2024, using the databases PubMed, MEDLINE, Embase, Cochrane Central, and Cumulative Index to Nursing and Allied Health Literature (CINAHL). The search terms were “external dacryocystorhinostomy” AND “scar”.

Study Selection

One author (L.C.B.A.) screened titles and abstracts of all identified records and removed duplicates and irrelevant articles. Full texts were retrieved for potentially eligible studies. Two authors (L.C.B.A. and A.Z.K.) independently assessed the full texts, as well as additional relevant publications identified from reference lists. Disagreements were resolved by consensus.

Data Extraction

Two authors (L.C.B.A. and S.B.A.) extracted data independently using a predesigned form (Table 1). Extracted data included study characteristics, surgical technique, incision type, postoperative care, scar assessment method, patient satisfaction, and complications.

Results

Study Selection and Characteristics

The initial search identified 270 records. After removal of duplicates (n=141) and exclusion of irrelevant articles, 73 studies underwent full-text screening. Following independent review, 40 studies met the eligibility criteria and were included in the final analysis (Figure 1). Together, these studies reported outcomes from 3750 Ext-DCR procedures, with scar assessments available for 3715 individuals.

Main Findings

Across the included studies, reported rates of visible scarring ranged from 0% to 50%, though in most series cosmetically significant scars were observed in less than 10% of patients (Table 1).

Conjunctival approaches (retrocaruncular and transconjunctival) consistently avoided cutaneous scars and achieved high patient satisfaction. However, these techniques were technically more demanding and occasionally required conversion to a conventional Ext-DCR. Reported complications included conjunctival granuloma formation and minor eyelid lacerations.

Table 1 Characteristics and Main Findings of Studies Evaluating Cosmetic Outcomes After External Dacryocystorhinostomy (Ext-DCR). Data Presented Include Study Design, Number of Cases, Surgical Technique (Incision Site, Design, and Length), Postoperative Care, Scar Grading Method, and Results (Including Scar Prevalence, Closure Method, and Patient-Related Factors)

Reference	Study Design	Cases ex-DCR (n)	Surgical Technique	Postoperative Care	Scar Grading	Results
Adenis et al, 2003 ⁷	Retrospective non comparative case series	11	Retrocaruncular approach	NS	NS	No scarring
Ajalloueyan et al, 2007 ¹	Prospective randomized trial	122	NS	Topical antibiotics and steroid drops for one week	NS	Reports 10 cases of keloid
Akaishi et al, 2011 ⁸	Prospective interventional case series	26	10-15mm incision in lower eye lid crease, 3-4 interrupted 6-0 nylon suture	NS	3 observers (an ophthalmologist, a general plastic surgeon and a head and neck specialist) grading photographs 1, 3 and 6 months after surgery with a 4-level scale: 1- invisible, 2- minimally visible, 3- moderately visible, and 4- very visible.	Mean score: 1 month= 2.19 3months= 1.65 6months= 1.44
Amin et al, 2022 ⁹	Prospective observational study	100	Modified ex-DCR DCR with anterior flap anastomosis and excision of posterior flaps. Skin closure with 6-0 black silk	Sutures removed 5-7 days after surgery	NS	2 cases had disfigured scars in the shape of epicanthus fold.
Besharati et al, 2005 ¹⁰	Retrospective study	187	Site of incision was 4mm medial to the medial canthal angle. The subcutaneous tissue and skin were sutured by 6-0 Vicryl and 6-0 silk sutures.	Chloramphenicol eye drops for one week. Skin suture removal after 5-7 days.	NS	8, 6% (n=16) had scar formation
Bharanikana et al, 2022 ¹¹	Randomized prospective interventional study	20	Conventional ex-DCR with intraoperative mitomycin C and silicone tube	NS	NS	No patients (n=20) complained about scarring.
Caesar et al, 2005 ¹²	Retrospective study with postal questionnaire	155	18mm straight incision, silicone tube intubation. Skin closure with interrupted 6-0 nylon	Silicone tubes removed after 6 weeks	Questionnaire mailed. Grading visible/ invisible. If visible further graded excellent/ good/ok/poor/very poor	33% of patients had visible scars, but only 3% rated them as poor or worse. Majority of patients were satisfied with the cosmetic outcome with 67% reporting invisible scars. Younger patients were more likely to notice visible scars.
Ciftci et al, 2010 ¹³	Retrospective case control	366	Skin excision was performed vertically (10-14mm), 1-2mm above the medial canthal tendon. It was placed 10mm from the medial canthal angle. Use of silicone tube. Lacrimal diaphragm was sutured in study group and left unsutured in control group. Skin closure with 6-0 Vicryl suture; Steri-Strips were placed over the skin incision.	Topical and systemic antibiotics for 1 week. Removal of sutures and Steri-Strips after one week. Corticoid ointment used for 1 month. Silicone tube removed after 2-4 months.	Grading performed by two ophthalmologists 6-month postoperatively. Grade 0: Invisible incision scar, Grade 1: Minimally visible incision scar, Grade 2: Moderately visible incision scar, Grade 3: Extremely visible incision scar (hypertrophic scar)	Study Group (with saturation) grading 0/1/2/3: 41.5% / 51.1% / 6.3% / 1.1% Control Group (without saturation) grading 0/1/2/3: 31.3% / 45.8% / 14.6% / 8.3% Significant hypertrophic scars were more frequent in the control group (8.3% vs 1.1%)

(Continued)

Table I (Continued).

Reference	Study Design	Cases ex-DCR (n)	Surgical Technique	Postoperative Care	Scar Grading	Results
Dave et al, 2012 ¹⁴	Prospective interventional study	17	10-15mm subillary incision (1–2 mm below lashline) for accessing the lacrimal sac and performing ex-DCR with standard procedures, including flap anastomosis and creating a bony ostium. Skin closure with 6–0 polyglactin suture.	Routine wound care with follow-up examinations at 1 day, 1 week, 6 weeks, 3 months and every 3–6 months thereafter.	Grade 0: invisible incision. Grade 1: Minimal visible. Grade 2: Moderately visible. Grade 3: Very visible. The evaluator graded the scars twice on two different days.	Physician grading: 0/1/2/3: 47% / 41.2% / 11.7% / 0%. Patient grading 0/1/2/3: 88% / 12% / 0% / 0%
Davies et al, 2015 ¹⁵	Multicenter, prospective, noncomparative interventional study.	72	Incision site was placed below the medial canthal ligament extended inferiorly and laterally in the tear trough (10–15mm). Skin closure with running or interrupted absorbable suture based upon surgeons' preferences.	NS	Grading scale: 0: Invisible incision 1: Minimally visible incision 2: Moderately visible incision 3: Very visible incision.	Patient grading 0/1/2/3: 83.3% / 12.5% / 4.2% / 0% Surgeon grading 0/1/2/3: 25.5% / 53.7% / 17.1% / 3.7%
Devoto et al, 2004 ²	Prospective, interventional, noncomparative case series.	34	10-12mm ex-DCR incision. Skin closure with 6–0 mild-chronic gut sutures followed by Steri-Strip	Sutures and Steri-Strip removed after a week	Photographs were taken pre-surgery and were graded by the patients and three ophthalmologists at 6 weeks and 6 months post-surgery. Grading scale: 0: Invisible incision 1: Minimally visible incision 2: Moderately visible incision 3: Very visible incision.	Patient grading 0/1/2/3 at 6 weeks: 26% / 38% / 26% / 9%, Patient grading 0/1/2/3 at 6 months: 44% / 47% / 9% / 0%, Average Scores by Three Observers at 6 weeks: 1.12, 1.18, and 1.24, Average Scores by Three Observers at 6 months: 0.56, 0.74, and 0.79
Dirim et al, 2015 ¹⁶	Retrospective case series	88	Group A: Anterior and posterior flap anastomosis (H-flap) with curvilinear skin incision. Group B: Only anterior flap anastomosis (U-flap) with W-shaped skin incision. Skin closure with 6–0 polypropylene monofilament non-absorbant	Corticosteroid and antibiotic eye drops 4 times daily for 10 days. Oral antibiotics for 1 week. Skin sutures removed after 10 days.	Grade 1: Invisible Grade 2: Minimally visible Grade 3: Moderately visible Grade 4: Highly visible	Group A (Curvilinear) grading 1/2/3/4: 60.0% / 16.0% / 10.0% / 14.0% Group B (W-shaped) grading 1/2/3/4: 50.0% / 36.8% / 5.3% / 7.9%
Ekinci et al, 2013 ¹⁷	Prospective non-randomized study	76	LS incision(vertical) was applied to one side and WS incision to the other side of each patient. 12mm length. 8mm to the medial canthus. Skin closure: Subcutaneous 6–0 Vicryl. Skin: vertical group: 4 separate 6–0 Prolene sutures WS: 5 separate 6–0 Prolene sutures.	Topical antibiotic drops and ointment for two weeks, vasoconstrictor nasal spray for five days. Sutures were removed on the 10th postoperative day.	Scar visibility was graded by patients and ophthalmologist from a distance of 100 cm under the same light. 1: Invisible incision, 2: Minimally visible incision, 3: Moderately visible incision, 4: Very visible incision	Patient grading (Vertical Incision) 1/2/3/4: 23% / 35.8% / 30.7% / 10.2% Patient grading (W Incision) 1/2/3/4: 45.9% / 43.2% / 8.1% / 2.7% Observer grading (Vertical Incision) 1/2/3/4: 30.7% / 38.4% / 20.5% / 10.2% Observer grading (W Incision) 1/2/3/4: 51.3% / 43.2% / 2.7% / 2.7%
Ekinci et al, 2014 ¹⁸	Prospective, interventional, comparative study	16	LS incision was 12 mm in length and 8 mm medial to the medial canthus, with one third of the incision (4 mm) lying above the medial canthal angle. The WS skin incision was 12 mm in linear length. The subcutaneous tissues were sutured with 6/0 Vicryl sutures, and the skin incisions were sutured with 6/0 Prolene.	Postoperatively, all patients received the same topical antibiotic drops and ointment for 2 weeks and the same vasoconstrictor nasal spray for 5 days. The sutures were removed on postoperative day 10 in both groups	Graded by two ophthalmologists and patient self-assessment from 100 cm in the same light. Grading scale: 0: Invisible incision 1: Minimally visible incision 2: Moderately visible incision 3: Very visible incision.	First Ophthalmologist: LS Incision 2.50 ± 0.82: / WS Incision 1.25 ± 0.45. Second Ophthalmologist: LS Incision 2.25 ± 0.86 / WS Incision 1.25 ± 0.45. Patient Self-Assessment: LS Incision 2.44 ± 1.03/ WS Incision 1.56 ± 0.73

Ganguly et al, 2016 ¹⁹	Prospective noncomparative case series	18	Transconjunctival dacryocystorhinostomy, conjunctival closure the 6–0 polyglactin suture	Topical antibiotics and steroids for one week postoperatively	Graded by independent grader using photographs, which were taken one month or later after surgery. Evaluated 3 places; conjunctival, lateral canthal and medial fat pad disturbance. Grading scale: 0: Invisible incision 1: Minimally visible incision 2: Moderately visible incision 3: Disfigured scar.	Conjunctival scar: Grade 1 (visible only on eyelid eversion) in all patients. Lateral canthal scar: Grade 0 (invisible) in all patients except one. Medial fat pad disturbance: Grade 0 (no disturbance) in all patients
González-López et al, 2014 ²⁰	Cross-sectional noninferiority comparative study	35	Cold blade or Colorado microcautery needle for skin incisions, followed by polyglycolic acid sutures removed after 7–10 days.	NS	Patients completed the Patient Scar Assessment Scale (PSAS). Macro photographs was taken and the esthetic result was blindly assessed by 2 of the authors using Patient and Observer Scar Assessment Scale (POSAS), Vancouver Scar Scale (VSS), and Observer Scar Assessment Scale (OSAS) at 6–12 months postoperatively.	No statistically significant differences in esthetic outcomes between techniques. DCR scars had significantly better esthetic results (lower pigmentation and relief scores) compared to other surgeries.
Idris et al, 2015 ²¹	Prospective interventional study	100	Skin incision 10mm vertically, 8mm from the medial canthus. Skin closure with interrupted sutures 6–0 Vicryl	Systemic antibiotics, analgesia and tranexamic acid.	Patient satisfaction (yes/no)	97% were satisfied
Islam et al 2018 ²²	Prospective interventional study	31	Vertical incision, 10mm away from the medial canthus, wound closure layer by layer	Systemic and topical antibiotics eyedrops	NS	5 cases of ugly looking scars
Jain et al, 2016 ²³	Retrospective study	23	A standard technique was used with a curvicular skin incision over lying the anterior lamina crest. Skin closure with single-layer interrupted 6–0 Vicryl sutures	Oral antibiotics and regular cleaning of the wound	NS	4 cases of self-reporting disfiguring scars and one developing punctal ectropion due to scarring.
Jha et al, 2009 ²⁴	Retrospective study	51	NS	Amoxicillin 500mgx4 for 5 days	NS	No cases of serious scarring or keloid formation.
Kashkoui et al, 2014 ²⁵	Retrospective interventional case series	85	Stab knife 15 degrees and an angled 2, 8mm keratome to avoid injuring the margins of skin incision (lacrimal sac and nasal flap incision). Skin closure with no sutures in subcutis or skin, only Steri-Strips.	Topical antibiotic and steroid ointment 2x a day for one week (at the incision site), strips removed after 1–2days, tube removal after 6 weeks.	Visual Analogue Score (VAS). Patient self-assessment by looking in mirror.	Mean VAS for the appearance of incision was 99.2 (SD=1.2; range, 95–100). Anatomical and overall functional success was 98.8% and 95.3%, respectively. No visible scarring observed.
Kaynak-Hekimhan et al, 2011 ²⁶	Prospective interventional case series	25	Transconjunctival DCR without endoscope/ laser assistance. No sutures in conjunctiva	Antibiotic and corticosteroid eye drops, nasal and ocular steroids, nasal saline spray for 3 weeks, restricted nose blowing first week.	NS	No visible scars. Complications included granuloma formation at the conjunctival incision site in 2 eyes (10.6%) and a minor eyelid margin laceration in one eye (5.3%). No facial scars were reported.

(Continued)

Table 1 (Continued).

Reference	Study Design	Cases ex-DCR (n)	Surgical Technique	Postoperative Care	Scar Grading	Results
Kumar et al, 2013 ²⁷	Prospective interventional case series	15	Conventional ex-DCR. Silicone intubation and application of mitomycin C. Skin closure: 6–0 silk	Patients received a course of antibiotics and anti-inflammatory drugs, local antibiotic drops, and ointment application on the wound area for 1 week, along with nasal decongestant drops. Skin suture removal on the seventh day. The silicone tube removal 2 months post-surgery.	NS	1 case of noticeable incisional scar
Mekonnen et al 2009 ²⁸	Prospective study	128	Conventional ex-DCR. Skin closure: Suture of muscle layer, skin suture 6–0 Vicryl subcuticular interrupted sutures	7 days with broad antibiotics and 2 weeks topical antibiotics	Bad, good and excellent	Scar rated excellent 107 eyes, good in 19 eyes, bad 2 eyes, all patients would recommend the operation
McKinley & Yen, 2004 ²⁹	Retrospective Review	21	10mm linear skin incision in the medial canthal region. Skin closure with octyl-2-cyanoacrylate which was painted on the incision.	Corticosteroid nasal spray started after 1 week for 1 month	NS	1 case of hypertrophic scar formation, which resolved within 8 weeks with daily massage.
Nemet et al, 2008 ³⁰	Retrospective review	104	NS	Systemic antibiotics in cases of mucocoele or infection, ocular antibiotic ointment and drops for up to 14 days. Silicone stenting in some cases.	Scar visibility rated on a scale of 1 (least) to 5 (greatest) during postoperative telephone interviews.	Scar visibility average was 1.79 out of 5, with a high satisfaction rate averaging 4.53 out of 5. Silicone intubation associated with lower revision surgery rates.
Ng et al, 2015 ⁴	Chart review	61	Conventional group: 10mm incision midpoint between the medial canthus and the nasal bridge. V-shape incision of upper and lower eyelids as well as the medial canthus. Both techniques with silicone tube. 8–0 Vicryl was used for closure.	Topical antibiotics and corticosteroid ointment 2–3 times a day in 2–4 weeks. Bicanalicular tube removal scheduled 4–8 weeks post-surgery.	Visual analogue scale (VAS) for patient satisfaction. Stony Brook scar evaluation scale (SBSES) for independent physician grading.	VDCR group: Mean VAS score of 95.5 ± 16.8 Conventional DCR group: Mean VAS score of 82.9 ± 25.1. The VDCR group rated significantly higher on aesthetic outcomes (p=0.03). SBSES: Observer 1 ratings: VDCR group: 4.6 ± 1.1. Conventional DCR group: 3.1 ± 2.8. Observer 2 ratings: VDCR group: 4.7 ± 1.2. Conventional DCR group: 2.8 ± 2.1. Both observers rated the VDCR group significantly higher on aesthetic outcomes (p<0.01).
Su, 2018 ³¹	Retrospective, comparative, nonrandomized clinical study	71	Curved skin incision length 15–20mm, medially to the angular vein at the level of the anterior lacrimal crest. Silicone tube used. Skin closure: subcutaneous sutured with interrupted 5–0 vicryl. Skin closed with interrupted 6–0 nylon suture	Antibiotics eyedrops(topical) 4x a day in 1month. Skin sutures removed after 1 week. Silicone tube removed after 6 months.	NS	Wound dehiscence (2 cases) and keloid formation (3 cases).

Quaranta-Leoni et al, 2019 ³²	Retrospective interventional study	48	Through a 6–7 mm paranasal incision, an appropriate osteotomy was created and a mucosal anastomosis was fashioned by suturing with 6/0 polyglactin sutures both the posterior and anterior mucosal flaps. All patients had silicone intubation, and skin closure was performed with 7/0 polyglactin interrupted sutures. Steri-Strip was applied to the wound.	Intraoperative systemic antibiotics were given to all patients. Combined steroid-antibiotic eye drops were prescribed twice daily for 2 weeks after surgery	Standardized pictures were taken post-operatively at 12 months in order to evaluate the scar, and the parents of the young patients were asked to evaluate the appearance of the scar 12 months after surgery in a scale from poor, fair, satisfactory to very satisfactory	Hypertrophic Scar: poor/fair=4.3%, satisfactory= 28.3%, very satisfactory = 67.4%
Rajabi et al, 2022 ³³	Retrospective nonrandomized study	618	10-12 mm straight incision, silicone tube placement depending on the case.	Post cold compression for 48 hours, chloramphenicol 0.5% + betamethasone 0.1% every 6 hour for 1 week, 500mg cephalexin 4x for 5 days	Grading not specified but mentioned as: invisible, a fine line at the operation site, visible line with mild elevation, visible hypertrophic scar and were unhappy about the cosmetic result	Invisible 39.5% (242), a fine line at the operation site 42.24% (261), visible line with mild elevation 15.54% (96), visible hypertrophic scar and were unhappy about the cosmetic result 3.07% (19).
Resti et al 2022 ³⁴	Retrospective observational study	245	15 mm long skin incision vertical. Silicone tube. Subcutaneous absorbable interrupted sutures and a cutaneous non absorbable continuous sutures were placed	Steroid og antibiotics 4x daily for 7 days	Grading 0 invisible, 1 slightly visible, 2 visible	Invisible 91.8%, slightly visible 8.2%, none reported visible
Rizvi et al, 2016 ³⁵	Prospective clinical interventional study	50	A short 10-mm straight incision, positioned at half the distance between the medial canthus and midpoint of the nasal bridge and not extending above the level of the medial canthus. After completion of surgery, orbicularis was closed with 6–0 Vicryl (polyglactin) suture and the skin closed with fine 6–0 Prolene (polypropylene) subcuticular	Sutures were removed after 1 week.	Photograph of each patient were taken at 2, 6 and 12week post operatively. Graded by patient self-assessment and two independent observers of same expertise and specialty. Grading scale: 0: Invisible incision, 1: Minimally visible incision, 2: Moderately visible incision, 3: Very visible incision.	Patient grading 0/1/2/3 at 6 weeks: 6% / 18% / 62% / 14% Patient grading 0/1/2/3 at 12 weeks: 38% / 52% / 8% / 2% Observers grading 0/1/2/3 at 2 weeks: 0% / 2% / 20–26% / 74–78% Observers grading 0/1/2/3 at 6 weeks: 2–4% / 20–22% / 52–58% / 18–24% Observers grading 0/1/2/3 at 12 weeks: 30–38% / 44–46% / 12–16% / 6–8%
Rizvi et al 2019 ³⁶	Prospective interventional randomized control study	50	A straight 10mm incision around 10mm medial to medial canthus. The control group underwent ex-DCR with closure in two layers, subcutaneous with 6-0-Vicryl interrupted three sutures, and skin with 6-0-Prolene continuous subcuticular sutures. The case group underwent DCR with interrupted three 6-0-Vicryl subcutaneous sutures with Steri Strip for skin apposition.	The patient were given systemic antibiotics and nasal decongestant for one week. Antibiotic and corticosteroid eye drops were given topically for two weeks and an antibiotic eye ointment locally at incision site were also prescribed for 15 days. The Steri Strip as well as 6-0-Prolene subcuticular continuous suture was removed the fifth day of follow-up.	Graded by two observers who were unaware of the surgical technique using photographs at 2, 6, and 12 weeks following surgery. Grading scale: Grade 0: Scar not visible. Grade 1: Scar minimally visible. Grade 2: Scar moderately visible. Grade 3: Scar maximally visible.	Mean scar grade of control group by the 2 observers at 2, 6 and 12 weeks was 2.6 +-0.57 (95% CI (2.44–2.76), 2.04 +- 0.64 (95% CI 1.86–2.22) and 1.16 +- 0.89 (95% CI 0.90–1.42), respectively. Mean scar grade of case group by the two observers at 2, 6 and 12 weeks was 2.02 +- 0.65 (95% CI 1.83–2.21), 1.44+- 0.70 (95% CI 1.24–1.64) and 0.44 +- 0.61 (95% CI 0.27–0.61). 8% had visible scars after 12 weeks in the subcuticular group, no scars were visible in the sutureless group after 12 weeks

(Continued)

Table I (Continued).

Reference	Study Design	Cases ex-DCR (n)	Surgical Technique	Postoperative Care	Scar Grading	Results
Sharma et al, 2005 ³⁷	Cross-sectional questionnaire-based study	297	A straight incision (10 mm) near the medial canthus, with skin closure using 6–0 Vicryl sutures, subcuticular continuous or interrupted suturing. Most patients underwent silicone intubation.	Antibiotic eyedrops 1 week, antibiotic ointment on wound 1–2 week, most sutures removed 1 week after operation	Questionnaire sent. Scars were assessed by patients on a scale 0 to 5, 0 (not visible) / 1 (least significant) 5 (highest significance)	Patients rating 0/1/2/3/4/5: 45.3% / 44.3% / 6.4% / 1.7% / 1.3% / 1%. Patients who rated their scars as cosmetically significant (higher than 1) had an average age of 51.6 years. 12.8% of female patients reported cosmetically significant scars compared to 3.8% of male patients. This difference was statistically significant.
Sharma et al, 2015 ³⁸	Prospective interventional study	56	Straight 12–14 mm skin incision at the level at the medial canthal tendon, 10mm nasally from medial canthus Orbicularis oculi was sutured with interrupted 6–0 Vicryl, skin sutured with 6–0 silk	Systemic antibiotics and anti-inflammatory drugs for 7 days, topical antibiotic-steroid drops x 4 for 4 weeks, and nasal decongestants for 7 days. Steroids ointment x1 for 4 weeks. Skin sutures removed after 8 days.	NS	Hypertrophic scar formation in 3.6% of cases.
Tarbet et al, 1995 ³	Retrospective study	153	Straight 2cm incision over the anterior lacrimal crest. Silicone tubes were used for intubation in 90% of case. Orbicularis oculi was sutured with 6–0 polyglactin, skin sutured with running 6–0 Prolene	Topical and oral antibiotics. Skin sutures were removed within 4–7 days. Silicone tube removed 3 weeks after	Telephone responses. Grading: excellent, good, fair, poor, or very poor.	75 patients reported the scar invisible. Rating of appearance as excellent (84cases), good (6cases), fair (2cases), poor (1case), very poor (none). How pleased they were (extremely pleased 70%, pleased 25%, somewhat pleased 3%, not pleased 2%). All patients would recommend the surgery
Torabi et al, 2023 ³⁹	Retrospective study	34	NS. Silicone tubes were placed	Silicone tubes removed after 3 months	Questionnaire letter (yes/no)	Four patients (12%) in the ex-DCR group were bothered by the scar on the side of the nose, 2 considered the scar ugly, and 1 one reported problems with wearing of glasses

<p>Wadwekar et al, 2019⁴⁰</p>	<p>Prospective trial</p>	<p>64</p>	<p>In group A a 12 mm curvilinear incision was given in tear trough along the direction of orbicularis muscle. The W-shaped incision was given 12 mm in vertical length, forming three consecutive equilateral triangles with 4 mm side length, with two triangle tip points and one base showing the medial canthus. Sutured with 6–0 Vicryl.</p>	<p>Postoperatively, tablet ciprofloxacin 500 mg and serratiopeptidase (10 mg), and diclofenac (50 mg) tablet were given twice daily for five to seven days to all patients. Nasal decongestant oxymetazoline (0.5 mg/mL) was administered as one drop four times daily on the side of surgery for one week. Ciprofloxacin ointment 0.3% was given for application over the wound twice a day for seven days. Ciprofloxacin (0.03 mg/10 mL) and dexamethasone (0.01 mg/10 mL) eye-drops were instilled four times daily for the first week post-operatively on the side of surgery, which was tapered and stopped over one month. The nasal pack was removed and syringing was done for all patients on the 1st postoperative day. All patients were discharged on the second postoperative day. The patients were examined on postoperative day 1, day 10, after one month, 3 months and 6 months</p>	<p>Cosmetic outcome was assessed by scar visibility at the first, third and sixth month postoperatively by two ophthalmologists independently. They were unaware of the incision types and the side of surgery. First, the examiners were told to predict the side (right or left) of surgery by looking for a scar. If examiners were unable to tell the side of surgery it was taken as no scar grade 1. If they could recognize the side by scar they were asked to grade the scar. Minimally visible scar tissue was assessed as grade 2, moderately visible scar tissue as grade 3, and easily visible scar tissue as grade 4.</p>	<p>First Month: Curvilinear Incision (CLI): 100% had minimally visible scars (Grade 2). W-Shaped Incision (WSI): 65.6% had minimally visible scars (Grade 2), and 34.4% had moderately visible scars (Grade 3). Third Month: CLI: 100% had no visible scars (Grade 1). WSI: 65.6% had no visible scars (Grade 1), while 34.4% still had minimally visible scars (Grade 2). Sixth Month: CLI: 100% had no visible scars (Grade 1), while 34.4% continued to have minimally visible scars (Grade 2).</p>
<p>Waly et al, 2016⁴¹</p>	<p>Prospective randomized interventional study</p>	<p>40</p>	<p>Group A: Standard ex-DCR procedure. Group B: A subciliary incision along the medial half of the lower eyelid. In both groups, the incision extended 10–15 mm. Either Prolene 6–0 or vicryl 6–0) were randomly used in 10 patients of each group.</p>	<p>The postoperative care included topical administration of combined antibiotic steroids drops for 1–2 weeks. The skin sutures were removed 1 week postoperative.</p>	<p>Graded by patient self-assessment, an oculoplastic surgeon and the operating surgeon. Grading scale: 0: invisible scar, 1: minimally visible scar, 2: moderately visible scar, 3: very visible scar.</p>	<p>Subciliary incision patient grading 0/1/2/3: 65% / 30% / 5% / 0%, Vertical incision patient grading 0/1/2/3: 15% / 35% / 30% / 20%. Prolene 6–0 sutures patient grading 0/1/2/3: 45% / 40% / 10% / 5%, Vicryl 6–0 sutures patient grading 0/1/2/3: 35% / 25% / 25% / 15%, Fair-skinned patient grading 0/1/2/3: 43.8% / 34.4% / 15.6% / 6.3%, Dark-skinned patient grading 0/1/2/3: 25% / 25% / 25% / 25%, Fair-skinned observer grading 0/1/2/3: 28.1% / 34.4% / 28.1% / 9.4%, Dark-skinned observer grading 0/1/2/3: 12.5% / 25% / 37.5% / 25%</p>

Abbreviation: NS, not stated.

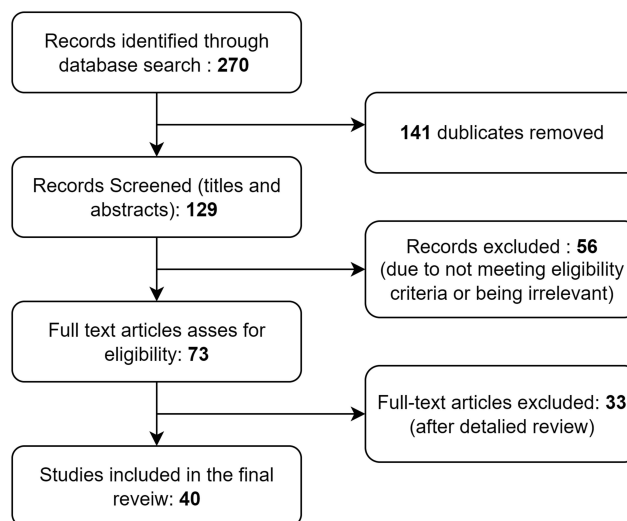


Figure 1 Flow diagram of study identification, inclusion, and exclusion.

For cutaneous approaches, the location of the incision played a central role in cosmetic outcomes. Incisions placed in natural creases such as the lower eyelid crease, subciliary margin, or periciliary line produced superior results compared with traditional vertical skin incisions.

Incision design also influenced scar outcomes. W-shaped and curvilinear incisions were generally associated with less visible scarring compared with straight vertical incisions. Curvilinear incisions along the tear trough line achieved particularly favorable results at follow-up.

Incision length was another factor, smaller skin incisions (5–10 mm) were associated with lower scar visibility and higher cosmetic satisfaction compared with traditional longer approaches.

Regarding closure techniques, sutureless methods using tissue adhesive or Steri-Strips frequently resulted in superior cosmetic outcomes and in some series completely avoided visible scarring. Suturing of the periosteum and lacrimal diaphragm reduced the incidence of hypertrophic scarring compared with unsutured wounds.

Patient-related factors influenced results. Darker skin types (Fitzpatrick IV–VI) were more prone to hypertrophic or pigmented scars, while younger patients were more likely to report cosmetic dissatisfaction compared with older individuals.

Discussion

Prevalence of Scarring

Conventional Ext-DCR is not a scarless procedure; scar assessment varies based on the grading scheme used, the patient's subjective opinion, and the surgeon's professional evaluation. Patient satisfaction is ultimately the most important outcome and is dependent on multiple factors, including the presence of complications and scar formation.

The prevalence of visible scarring varied greatly across the reviewed studies, ranging from 0–50%. However, in most reports, the prevalence was under 10%, meaning most cases resulted in no or minimal visible scarring after Ext-DCR.^{2,3,10,13,21–25,27–34,36–40,42,43} Some study designs evaluated scarring at different post-surgery intervals, highlighting scar reduction over time.^{2,8,36,40} For instance, Rizvi et al showed an initial assessment of 68% highly visible scars at post-operative week two, which decreased to 2% at 12 weeks after surgery.³⁶ Granuloma formation, keloids, and hypertrophic scarring ranged from 0–11%,^{10,26} 0–8%,^{1,31} and 0–8%,^{13,29,32,33,38} respectively. McKinley et al found one case of hypertrophic scarring, which resolved after eight weeks of daily massage of the scar.²⁹ Another study found that hypertrophic scarring could be resolved by steroid injection.³

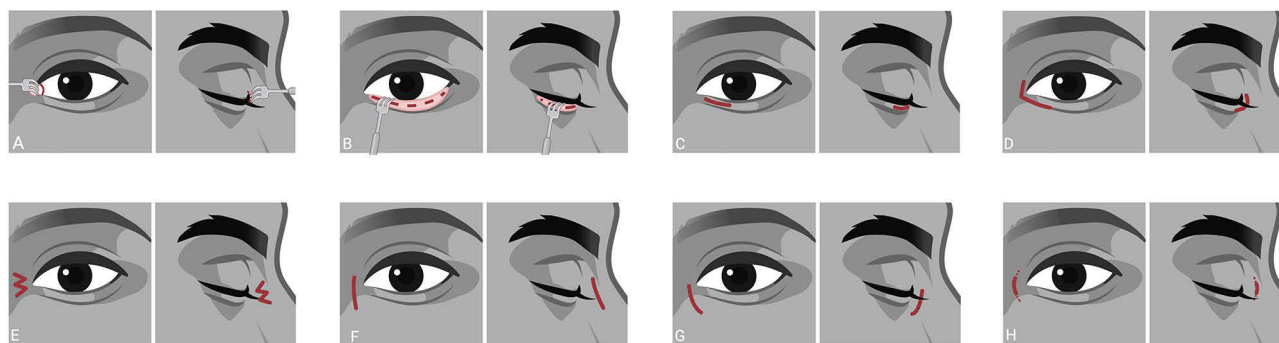


Figure 2 Incisional designs and locations. (A) Retrocaruncular. (B) Transconjunctival. (C) Subciliary. (D) Periciliary V-incision. (E) W-shaped. (F) Traditional linear straight. (G) Curved linear/tear trough. (H) Minimal incision.

Incision Site

The choice of incision site is a major determinant of postoperative cosmetic outcome in Ext-DCR. Different approaches have been described to either avoid visible skin scars or to conceal them within natural folds.

Conjunctival Approaches

To completely avoid cutaneous scarring, retrocaruncular and transconjunctival techniques have been proposed (Figure 2A and B).^{7,19,26} These approaches place the incision through the conjunctiva, leaving no external scar. Most studies reported good functional results and high patient satisfaction, with only one case of lateral canthal scarring described.²⁶ Kaynak-Hekimhan et al highlighted the technical challenges: in 6 of 25 cases, conversion to a standard Ext-DCR was required. Reported complications included granuloma formation at the conjunctival incision site (10.6%) and minor eyelid margin laceration (5.3%).²⁶ Despite high patient satisfaction with the postoperative aesthetic outcome, the limited surgical field and relative unfamiliarity of these approaches among surgeons have restricted their widespread adoption.

Alternative Cutaneous Incision Sites

Other modifications seek to hide the scar within natural skin creases or hair-bearing areas. Akaishi et al placed the incision in the medial relaxed skin tension line at the lower eyelid crease and reported significantly improved scar outcomes (Figure 2C).⁸

A subciliary incision has also been associated with good cosmetic results, with one study reporting no visible scarring based on patient self-assessment.¹⁴ Waly et al found only 5% of patients reported visible scarring in the subciliary group, compared with 50% in those receiving a traditional vertical incision.⁴¹

The periciliary “V-incision” (Figure 2D), involving incisions at both the upper and lower eyelid margins, was likewise associated with favorable cosmetic outcomes.⁴

Collectively, these approaches suggest that scar visibility can be reduced by strategic incision placement. However, moving further from the lacrimal sac increases technical difficulty, and subciliary/periciliary approaches may pose a risk of canalicular injury.

Cutting Instruments

The role of the incision instrument has also been studied. González-López et al conducted a comparative study analyzing periocular scars resulting from incisions made with a cold blade versus a microdissection needle.²⁰ The study found no significant differences in aesthetic outcomes between the two techniques, assessed by multiple validated scar assessment scales (Patient and Observer Scar Assessment Scale (POSAS), Vancouver Scar Scale (VSS), and Observer Scar Assessment Scale (OSAS)). Interestingly, the results indicated that DCR scars generally exhibited better cosmetic outcomes compared to other periocular surgical procedures, suggesting that incision instrument may play less of a role in post-operative scarring in Ext-DCR.

Incision Design

Alongside location, the design of skin incisions and modifications of techniques have also been investigated.

Ekinci et al conducted two studies in Turkey evaluating the impact of W-shaped (WS) versus traditional linear (LS) incisions on scar visibility after Ext-DCR (Figure 2E and F).^{17,18} Results indicated that the WS incision significantly reduced visible scarring, particularly among younger patients. A similar study applied the WS incision to one side and the LS incision to the other during bilateral Ext-DCR. Postoperative scar assessments at six months showed that the WS incision had significantly lower scar visibility.¹⁸ The scars were assessed by both ophthalmologists and patients, with both reporting lower scores for the WS incision ($p < 0.001$). These findings collectively highlight the effectiveness of the WS incision in achieving better cosmetic outcomes and reducing visible scarring compared to the LS incision.

Two studies compared the scarring outcomes of different incision techniques.^{16,40} One evaluated a curvilinear incision versus a W-shaped incision.¹⁶ Similar success rates were reported in lacrimal patency and comparable scar visibility scores, though the W-shaped incision group showed a modest reduction in visible scarring.¹⁶ The other altered both the location and the design of the traditional incision in Ext-DCR.⁴⁰ They compared a curvilinear incision (CLI) (Figure 2G), following the tear trough along the orbicularis muscle, to a W-shaped incision. The CLI group achieved superior cosmetic outcomes over time, suggesting that while both techniques are effective, the CLI along the natural tear trough line may offer an advantage in minimizing long-term scar visibility. A third study confirmed the tear trough to be among the best incisional methods.¹⁵ The authors reported that most patients (83%) rated their scars as invisible after three months. Surgeons also rated the scarring outcome favorably. A different study using CLI but not following the tear trough reported two cases of dehiscence and three cases of keloid scar formations from the total of 71 Ext-DCR cases.³¹

Incision Length

The length of skin incisions can also have an impact on the visibility of the scar. Two comparable studies support the efficacy of minimal incision techniques in Ext-DCR for enhancing cosmetic outcomes. One reported high patient satisfaction (97%) with reduced scarring using a small incision (10mm), while the other reported an even higher satisfaction rate with no visible scarring utilizing a modified 5mm incision without sutures (Figure 2H).^{21,25} Both studies confirm that smaller incisions can minimize scar visibility, although the unsutured approach may offer superior aesthetic results while maintaining functional outcomes.^{21,25}

Sutureless Closure

The study by Kashkouli et al demonstrated that using a sutureless skin closure technique with Steri-Strips after Ext-DCR, which used the modified 5 mm incision, resulted in no visible scars after 6 months.²⁵ Similarly, a different study, which used a 10mm straight incision, compared subcuticular suturing to the sutureless skin closure technique and showed the cosmetic advantages of using Steri-Strips instead of sutures, with no visible scars observed after 12 weeks; compared to an 8% scar visibility rate in the subcuticular group.³⁶

Evaluating whether the skin incision should be left sutureless, the effects of suturing the lacrimal diaphragm and periosteum were evaluated.¹³ The results indicated that preservation of these structures contributed to a concave contour in the lacrimal region, effectively preventing webbing and thereby resulting in fewer visible scars and a significantly lower incidence of hypertrophic scarring compared to the unsutured control group.¹³ This approach also yielded better functional outcomes, as indicated by a higher success rate in the dye disappearance test. The results of these studies collectively underscore the importance of tailored incision and closure techniques in minimizing visible scarring, with both the preservation of underlying structures and sutureless closure showing promising results for optimal aesthetic outcomes after Ext-DCR.^{13,25,35,36}

Skin Complexion

Waly et al found that skin complexion influenced scar visibility and grading in Ext-DCR. While 50% of dark-skinned patients rated their scars as cosmetically significant, only 22% of fair-skinned patients reported the same.⁴¹ The mean scar grades also tended to be higher among dark-skinned patients compared to fair-skinned patients, but this difference did not reach statistical significance, possibly due to the small proportion of dark-skinned patients in the study.

Nevertheless, this trend highlights the potential for increased scar hypertrophy and pigmentary changes in darker skin tones.

Individuals with darker skin types (Fitzpatrick IV–VI) are more prone to pathological scarring, such as keloids and hypertrophic scars, due to factors including increased fibroblast activity, excessive collagen deposition, and prolonged inflammatory phases during healing. Keloids and hypertrophic scars are significantly more common in individuals of African and Asian descent, potentially due to genetic predispositions relating to the regulation of collagen synthesis and growth factors. Moreover, the increased melanin content in darker skin contributes to hyperpigmentation, making scars more noticeable.⁴⁴

Limitations

A significant limitation of this systematic review is the lack of standardized scar assessment tools across studies. While some studies utilized validated grading scales, others relied on self-reported outcomes or non-validated scales, limiting the comparability of results.^{4,20,25} Additionally, many studies did not describe their methodology for scar assessment in detail, further complicating comparisons. To minimize these limitations and allow for more successful comparisons of outcomes, future studies should aim for a more standardized means of assessment by using validated scales like the Visual Analogue Scale (VAS) or the Stony Brook Scar Evaluation Scale (SBSSES).⁴³

Furthermore, greater heterogeneity in surgical techniques and patient populations would give a better understanding of which procedural initiatives make a clear difference in minimizing scarring. Several studies identified patient-related factors influencing scar visibility.^{12,37,41} Moreover, studies have shown that children and younger females were more attentive and critical when rating the postoperative scar. This underscores the importance of considering patient demographics when planning surgical interventions and setting realistic expectations for postoperative outcomes. The use of professional and blinded graders could therefore optimize the accurate measurement of both scar occurrence and assessment, ensuring a consistent foundation for determining optimal surgical approaches for minimizing scarring after Ext-DCR. Additionally, this review highlights the lack of studies evaluating the impact on alternating post-operative care protocols, such as the use of antibiotics and steroid ointments. This could potentially have a significant effect on reducing scar formation.

Conclusion

Our review suggests that scar outcomes following Ext-DCR may be improved through careful selection of incision site and closure technique. However, current evidence is heterogeneous, and no single modification has achieved universal acceptance. Standardized scar assessment tools are needed to allow meaningful comparisons across studies.

Future research should aim to refine these approaches, with a focus on minimizing visible scarring while maintaining high rates of functional success.

Disclosure

TPU, FAF and AZK have ownership interests in the Eye Health Clinic and the Norwegian Dry Eye Clinic, which offer oculoplastic surgery, and gave lectures for and/or receives financial support from Abigo, Alcon, Allergan, AMWO, Bausch & Lomb, Bayer, European School for Advanced Studies in Ophthalmology, Innz Medical, Medilens Nordic, Medistim, Novartis, Santen, Specsavers, Shire Pharmaceuticals and Théa Laboratories. The author(s) report no other conflicts of interest in this work. The abstract for this article was included in the official abstract list of the 43rd ESORPS Meeting in Prague, September 11th-13th 2025.

References

1. Ajalloueyan M, Fartookzadeh M, Parhizgar H. Use of laser for dacryocystorhinostomy. *Arch Otolaryngol Head Neck Surg.* 2007;133(4):340-343. doi:10.1001/archotol.133.4.340
2. Devoto MH, Zaffaroni MC, Bernardini FP, De Conciliis C. Postoperative evaluation of skin incision in external dacryocystorhinostomy. *Ophthalmic Plast Reconstr Surg.* 2004;20(5):358–361. doi:10.1097/01.IOP.0000134274.46764.FC
3. Tarbet KJ, Custer PL. External dacryocystorhinostomy: surgical success, patient satisfaction, and economic cost. *Ophthalmology.* 1995;102(7):1065–1070. doi:10.1016/S0161-6420(95)30910-4

4. Ng DSC, Chan E, Yu DKH, Ko STC. Aesthetic assessment in periciliary “v-incision” versus conventional external dacryocystorhinostomy in Asians. *Graefes Arch Clin Exp Ophthalmol*. 2015;253(10):1783–1790. doi:10.1007/s00417-015-3098-8
5. Huang J, Malek J, Chin D, et al. Systematic review and meta-analysis on outcomes for endoscopic versus external dacryocystorhinostomy. *Orbit*. 2014;33(2):81–90. doi:10.3109/01676830.2013.842253
6. Toti A. Nuovo metodo conservatore dicura radicale delle soppurazioni croniche del sacco lacrimale (dacriocistorinostomia). *Clin Moderna*. 1904;10:385–387.
7. Adenis JP, Robert PY. Retrocaruncular approach to the medial orbit for dacryocystorhinostomy. *Graefes Arch Clin Exp Ophthalmol*. 2003;241(9):725–729. doi:10.1007/s00417-003-0720-y
8. Akaishi PMS, Mano JB, Pereira IC, Cruz AA. Functional and cosmetic results of a lower eyelid crease approach for external dacryocystorhinostomy. *Arq Bras Oftalmol*. 2011;74(4):283–285. doi:10.1590/S0004-27492011000400011
9. Amin N, Makwana K, Gupta A. A prospective study on modified approach to classical dacryocystorhinostomy. *Asian J Pharm Clin Res*. 2022;15(12):58–60. doi:10.22159/ajpcr.2022.v15i12.46176
10. Besharati MR, Rastegar A. Results and complications of external dacryocystorhinostomy surgery at a teaching hospital in Iran. *Saudi Med J*. 2005;26(12):1940–1944.
11. Bharanikana M, Malladi RR, Ratnakumari BVS, Reddi A. A comparative study on surgical outcome of external dacryocystorhinostomy and endonasal dacryocystorhinostomy with nasolacrimal duct intubation and mitomycin-C application. *J Cardiovasc Dis Res*. 2022;13(8):1693–1702. doi:10.31838/jc9r.2022.13.08.211
12. Caesar RH, Fernando G, Scott K, McNab AA. Scarring in external dacryocystorhinostomy: fact or fiction? *Orbit*. 2005;24(2):83–86. doi:10.1080/01676830590926567
13. Ciftci F, Asli Dinc U, Ozturk V. The importance of lacrimal diaphragm and periosteum suturation in external dacryocystorhinostomy. *Ophthalmic Plast Reconstr Surg*. 2010;26(4):254–258. doi:10.1097/IOP.0b013e3181bb5942
14. Dave TV, Ali MJ, Sravani P, Naik MN. Subciliary incision for external dacryocystorhinostomy. *Ophthalmic Plast Reconstr Surg*. 2012;28(5):341–345. doi:10.1097/IOP.0b013e31825e697c
15. Davies BW, McCracken MS, Hawes MJ, Hink EM, Durairaj VD, Pelton RW. Tear trough incision for external dacryocystorhinostomy. *Ophthalmic Plast Reconstr Surg*. 2015;31(4):278–281. doi:10.1097/IOP.0000000000000302
16. Dirim B, Sendul SY, Demir M, et al. Comparison of modifications in flap anastomosis patterns and skin incision types for external dacryocystorhinostomy: anterior-only flap anastomosis with W skin incision versus anterior and posterior flap anastomosis with linear skin incision. *Sci World J*. 2015;2015(1). doi:10.1155/2015/170841
17. Ekinci M, Çağatay HH, Oba ME, et al. The long-term follow-up results of external dacryocystorhinostomy skin incision scar with W Incision. *Orbit*. 2013;32(6):349–355. doi:10.3109/01676830.2013.822898
18. Ekinci M, Çağatay HH, Gokce G, et al. Comparison of the effect of w-shaped and linear skin incisions on scar visibility in bilateral external dacryocystorhinostomy. *Clin Ophthalmol*. 2014;8:415–419. doi:10.2147/OPHTH.S57382
19. Ganguly A, Ramarao K, Mohapatra S, Rath S. Transconjunctival dacryocystorhinostomy: an aesthetic approach. *Indian J Ophthalmol*. 2016;64(12):893–897. doi:10.4103/0301-4738.198855
20. González-López JJ, González-García FJ, Sales-Sanz M, Alonso N, Albandea A, Mateos E. Long-term cicatrization analysis in periocular incisions for oculoplastic surgery performed with cold blade and Colorado needle. *Ophthalmic Plast Reconstr Surg*. 2014;30(3):225–228. doi:10.1097/IOP.0000000000000054
21. Idris M, Ayaz S, Iqbal A, Ahmad N, Shah MA. Effectiveness of external dacryocystorhinostomy with small skin incision. *Rawal Med J*. 2015;40(1):62–64.
22. Islam MR, Wadud SA, Akhanda AH, et al. Outcome of transcanalicular endolaser and external dacryocystorhinostomy in chronic dacryocystitis. *Mymensingh Med J*. 2018;27(4):673–678.
23. Jain S, Ganguly A, Singh S, Mohapatra S, Tripathy D, Rath S. Primary nonendoscopic endonasal versus delayed external dacryocystorhinostomy in acute dacryocystitis. *Ophthalmic Plast Reconstr Surg*. 2017;33(4):285–288. doi:10.1097/IOP.0000000000000759
24. Jha KN, Ramalingam WV. External versus endoscopic dacryocystorhinostomy: a retrospective study. *Med J Armed Forces India*. 2009;65(1):23–25. doi:10.1016/S0377-1237(09)80048-8
25. Kashkouli MB, Jamshidian-Tehrani M. Minimum incision no skin suture external dacryocystorhinostomy. *Ophthalmic Plast Reconstr Surg*. 2014;30(5):405–409. doi:10.1097/IOP.0000000000000131
26. Kaynak-Hekimhan P, Yilmaz OF. Transconjunctival dacryocystorhinostomy: scarless surgery without endoscope and laser assistance. *Ophthalmic Plast Reconstr Surg*. 2011;27(3):206–210. doi:10.1097/IOP.0b013e3181e9a361
27. Kumar S, Dulgach P, Kamal S, Goel R. Long-term success of modified external dacryocystorhinostomy for the treatment of distal common canalicular block. *Asia-Pac J Ophthalmol*. 2013;2(2):94–98. doi:10.1097/apo.0b013e31828b9ba6
28. Mekonnen W, Adamu Y. Outcome of external dacryocystorhinostomy in Ethiopian patients. *Ethiop Med J*. 2009;47(3):221–226.
29. McKinley SH, Yen MT. Octyl-2-cyanoacrylate tissue adhesive in external dacryocystorhinostomy. *Ophthalmic Plast Reconstr Surg*. 2005;21(3):197–200. doi:10.1097/01.IOP.0000161715.69963.9C
30. Nemet AY, Fung A, Martin PA, et al. Lacrimal drainage obstruction and dacryocystorhinostomy in children. *Eye*. 2008;22(7):918–924. doi:10.1038/sj.eye.6702769
31. Su PY. Comparison of endoscopic and external dacryocystorhinostomy for treatment of primary acquired nasolacrimal duct obstruction. *Taiwan J Ophthalmol*. 2018;8(1):19–23. doi:10.4103/tjo.tjo_10_18
32. Quaranta-Leoni FM, Verrilli S, Leonardi A. Surgical outcome and unusual complications of paediatric external dacryocystorhinostomy. *Orbit*. 2019;38(3):187–191. doi:10.1080/01676830.2018.1501396
33. Rajabi MT, Mohammadi SS, Nozare A, et al. External versus endoscopic dacryocystorhinostomy for primary acquired nasolacrimal duct obstruction. *Middle East Afr J Ophthalmol*. 2022;29(1):1–6. doi:10.4103/meajo.meajo_238_21
34. Giordano Resti A, Vinciguerra A, Bordato A, et al. The importance of clinical presentation on long-term outcomes of external dacryocystorhinostomies: our experience on 245 cases. *Eur J Ophthalmol*. 2022;32(5):2646–2651. doi:10.1177/11206721211059702
35. Rizvi SAR, Saquib M, Maheshwari R, Gupta Y, Iqbal Z, Maheshwari P. Cosmetic evaluation of surgical scars after external dacryocystorhinostomy. *Int J Ophthalmol*. 2016;9(12):1745–1750. doi:10.18240/ijo.2016.12.07

36. Rizvi SAR, Sabah M, Saquib M, Mahmood F, Alam MS. A prospective comparative study between subcuticular and sutureless technique of skin closure following external dacryocystorhinostomy. *Ophthalmic Plast Reconstr Surg*. 2019;35(4):318–321. doi:10.1097/IOP.0000000000001235
37. Sharma V, Martin PA, Bengier R, et al. Evaluation of the cosmetic significance of external dacryocystorhinostomy scars. *Am J Ophthalmol*. 2005;140(3):359.e1–359.e7. doi:10.1016/j.ajo.2005.04.039
38. Sharma HR, Sharma AK, Sharma R. Modified external dacryocystorhinostomy in primary acquired nasolacrimal duct obstruction. *J Clin Diagn Res*. 2015;9(10):NC01–NC05. doi:10.7860/JCDR/2015/15940.6624
39. Torabi P, Stenstrom B, Larsson AM, Bjornberg P, Svensson C, Engelsberg K. Outcomes of external and endonasal dacryocystorhinostomy according to a modified lacrimal symptom questionnaire (Lac-Q). *Med Hypothesis Discov Innov Ophthalmol*. 2023;12(2):55–61. doi:10.51329/mehdiophthal1470
40. Wadwekar B, Hansdak A, Nirmale SD, Ravichandran K. Cutaneous scar visibility after external dacryocystorhinostomy: a comparison of curvilinear and W shaped incision. *Saudi J Ophthalmol*. 2019;33(2):142–147. doi:10.1016/j.sjopt.2019.01.009
41. Waly M, Shalaby O, Elbakary M, Hashish A. The cosmetic outcome of external dacryocystorhinostomy scar and factors affecting it. *Indian J Ophthalmol*. 2016;64(4):261–265. doi:10.4103/0301-4738.182933
42. Hii BW, McNab AA, Friebel JD. A comparison of external and endonasal dacryocystorhinostomy in regard to patient satisfaction and cost. *Orbit*. 2012;31(2):67–76. doi:10.3109/01676830.2011.648803
43. Ng DSC, Chan E. Techniques to minimize skin incision scar for external dacryocystorhinostomy. *Orbit Taylor Francis Ltd*. 2016;35(1):42–45. doi:10.3109/01676830.2015.1099700
44. Téot L, Mustoe TA, Middelkoop E, Gauglitz GG. *Textbook on Scar Management*. Springer International Publishing; 2020. doi:10.1007/978-3-030-44766-3

Clinical Ophthalmology

Publish your work in this journal

Clinical Ophthalmology is an international, peer-reviewed journal covering all subspecialties within ophthalmology. Key topics include: Optometry; Visual science; Pharmacology and drug therapy in eye diseases; Basic Sciences; Primary and Secondary eye care; Patient Safety and Quality of Care Improvements. This journal is indexed on PubMed Central and CAS, and is the official journal of The Society of Clinical Ophthalmology (SCO). The manuscript management system is completely online and includes a very quick and fair peer-review system, which is all easy to use. Visit <http://www.dovepress.com/testimonials.php> to read real quotes from published authors.

Submit your manuscript here: <https://www.dovepress.com/clinical-ophthalmology-journal>

Dovepress
Taylor & Francis Group