

Invasive *Talaromyces marneffi* Fungemia in an HIV-Negative Patient with T-Prolymphocytic Leukaemia: A Case Report and Review of Emerging Risks

Lili Zhan , Qun Wang , Xiaoyu Zhang , Yangyang Tan , Li Zhang 

Department of Clinical Laboratory Medicine, National Cancer Center/National Clinical Research Center for Cancer/Cancer Hospital & Shenzhen Hospital, Chinese Academy of Medical Sciences and Peking Union Medical College, Shenzhen, Guangdong, People's Republic of China

Correspondence: Li Zhang, Department of Clinical Laboratory Medicine, National Cancer Center/National Clinical Research Center for Cancer/Cancer Hospital & Shenzhen Hospital, Chinese Academy of Medical Sciences and Peking Union Medical College, Baohe Road No. 113, Longgang District, Shenzhen, Guangdong, 518116, People's Republic of China, Email zldh33@163.com

Background: *Talaromyces marneffi* (*T. marneffi*) is a thermally dimorphic fungus traditionally associated with HIV-related immunosuppression. However, increasing reports have described infections in HIV-negative patients with hematologic malignancies, particularly those receiving novel immunosuppressive therapies.

Case Presentation: We report a case of disseminated *T. marneffi* in an HIV-negative 55-year-old woman with T-prolymphocytic leukaemia (T-PLL) undergoing chemotherapy and targeted therapy with chidamide and golidocitinib. The patient presented with fever, pancytopenia, and signs of systemic infection. Blood cultures confirmed *T. marneffi*, with identification supported by dual-phase morphology and internal transcribed spacer (ITS) sequencing. Due to unavailability of amphotericin B, the patient was treated successfully with voriconazole, achieving rapid clinical improvement and negative follow-up cultures.

Discussion: This case adds to the growing evidence that *T. marneffi* can cause invasive infections in non-HIV immunocompromised hosts. Through a review of 10 published cases, we identify common features such as neutropenia, kinase inhibitor use, and diagnostic delays. We emphasize the importance of early fungal culture and phase-specific morphology for diagnosis, and highlight voriconazole as a viable alternative therapy when amphotericin B is inaccessible.

Conclusion: Clinicians should maintain high suspicion for talaromycosis in immunosuppressed hematologic patients in endemic regions, regardless of HIV status. Prompt recognition and appropriate antifungal therapy are essential to improve outcomes.

Keywords: *Talaromyces marneffi*, T-prolymphocytic leukaemia, hematologic malignancy, invasive fungal infection, voriconazole, HIV-negative, immunosuppression, targeted therapy, kinase inhibitors

Background

Talaromyces marneffi (*T. marneffi*, formerly known as *Penicillium marneffi*) is a thermally dimorphic fungus that can cause a severe opportunistic infection known as talaromycosis (TSM), a disseminated systemic mycosis.¹ The first case of natural human infection was reported in 1973.² This fungus is primarily endemic to the tropical regions of Southeast and South Asia, including eastern India, Thailand, Vietnam, Laos, Myanmar, and the southern provinces of China, such as Guangdong, Guangxi, Yunnan, and Fujian. With the yearly increase in population mobility, cases have also been reported in other provinces.^{1,3–8} While talaromycosis is classically an AIDS-defining infection in human immunodeficiency virus (HIV) patients with advanced immunosuppression, it is increasingly recognized in HIV-negative individuals with other immune deficits.^{9–12} Immunosuppressive chemotherapy, targeted agents such as Janus kinase (JAK) inhibitors, and prolonged neutropenia represent key risk factors.^{12,13} Among the general population with acute leukemia, the incidence of invasive fungal infections (IFIs) can reach 10–25% in acute myeloid leukemia (AML) and approximately

6.5% in acute lymphoblastic leukemia (ALL).¹⁴ However, these fungal infections are predominantly caused by *Candida albicans*, *Aspergillus* species, and others, with *T. marneffei* accounting for only a very small proportion.^{14–17}

Nevertheless, sporadic cases in hematologic malignancy patients have been documented since the early 2000s. These include patients with non-Hodgkin lymphomas (NHL), plasma cell neoplasms (PCN), myeloid malignancies, and rare hematologic disorders.¹⁸ Overall, the incidence remains low relative to more common invasive fungi – but it appears to be rising with the advent of newer immunosuppressive cancer therapies.¹²

T. marneffei primarily invades the reticuloendothelial system (RES) of human monocytes and macrophages, and is characterized by either localized or disseminated infections.¹⁹ Localized infections are relatively rare and typically involve a single organ, such as the lungs, leading to localized symptoms. Disseminated infections, on the other hand, may affect multiple systems and organs throughout the body, presenting with symptoms such as fever, anemia, weight loss, fatigue, hepatosplenomegaly, lymphadenopathy, cough, and gastrointestinal discomfort. In some cases, involvement of the central nervous system (CNS) may also occur.^{3,12,20,21} Disseminated talaromycosis may be complicated by secondary bacterial infections, often resulting in delayed diagnosis and increased mortality.²²

We report a case of *T. marneffei* fungemia combined with cytomegalovirus infection in an HIV-negative patient diagnosed with T-prolymphocytic leukaemia (T-PLL). Additionally, we provide a literature review summarizing *T. marneffei* infections in patients with hematologic malignancies, aiming to raise awareness of this rare infection in non-HIV-infected individuals with blood disorders.

Case Presentation

A 55-year-old female patient presented with a 7-month history of T-prolymphocytic leukaemia, diagnosed through histopathological examination of bone marrow and cervical lymph node, with molecular confirmation via next-generation sequencing, was admitted to our hospital due to thrombocytopenia with nasal bleeding for one day. Although alemtuzumab (anti-CD52 monoclonal antibody) is considered the first-line therapy for T-PLL in international guidelines, it is not currently approved for clinical use in our country. Therefore, a pragmatic, individualized approach was adopted. The patient initially received two cycles of chemotherapy at a referring hospital: First Cycle: CHOP regimen: Cyclophosphamide 1.2 g, Epirubicin 100 mg, Vincristine 2 mg, Intraperitoneal injection of methotrexate, cytarabine, and dexamethasone; Second Cycle: Chidamide 20 mg twice a week, Cyclophosphamide 0.5 g on days 1–2, Vincristine 1 mg, Liposomal Doxorubicin 10 mg on day 1, 20 mg on day 2, along with prednisone 30 mg/d from days 1–5. Following disease progression and hematologic intolerance, she was switched to low-dose chemotherapy with gemcitabine (0.4 g) and targeted therapy with chidamide (10 mg qd) and golidocitinib (150 mg qd).

The patient developed Grade IV thrombocytopenia (platelet count: $16 \times 10^9/L$; reference range: $125\text{--}350 \times 10^9/L$), accompanied by left nasal bleeding, scattered ecchymoses on the skin, and dense petechiae on both lower limbs. Grade IV neutropenia (neutrophil count: $0.40 \times 10^9/L$; reference range: $1.8\text{--}6.3 \times 10^9/L$) and fever (up to 39°C) were noted. Retrospective review of the medical records showed that T-cell counts/subpopulations and serum immunoglobulin levels were not assessed at the time of admission, limiting further characterization of the patient's cellular and humoral immune status. Blood cultures and infectious markers were obtained, and empirical therapy was initiated, including antipyretics (compound paracetamol), imipenem-cilastatin for antibacterial coverage, fluconazole for antifungal prophylaxis, transfusion of single-donor platelets, granulocyte colony-stimulating factor, intravenous immunoglobulin (IVIG), and temporary suspension of anti-tumor therapy.

Physical examination showed abdominal distension; there was suspected rebound tenderness at McBurney's point in the right lower quadrant, tympanic sounds on percussion, and suspected positive shifting dullness. Notable bilateral lower limb edema was observed. The patient experienced a persistent fever for three days. Laboratory tests revealed significantly elevated inflammatory markers: C-reactive protein (CRP) at 6.17 mg/L (reference range: 0–5 mg/L), procalcitonin (PCT) at 0.066 ng/mL (reference range: <0.046 ng/mL), and interleukin-6 (IL-6) at 113.00 pg/mL (reference range: <7 pg/mL). One week prior to the fever, a comprehensive metagenomic sequencing test was conducted, detecting cytomegalovirus (CMV: 3664 reads), human herpesvirus type 6B (HHV-6B: 439 reads), and Epstein-Barr virus (EBV: 276 reads). CMV DNA quantification by PCR revealed an initial viral load of 4.43×10^4 copies/mL (reference range: $<4.00 \times 10^2$ copies/mL). Oral valacyclovir was initiated as an antiviral treatment. However, a follow-up test after

one week showed a significant increase in CMV DNA levels to 2.42×10^5 copies/mL, suggesting treatment failure or resistance. CMV reactivation was considered a potential contributing factor to the patient's immunosuppression and vulnerability to invasive fungal infection.

Microbiological Identification

Blood cultures from central and peripheral venous access became positive under aerobic conditions after 86.7 and 88 hours, respectively. Gram staining and Fungal fluorescence staining showed septate hyphae with an antler-shaped morphology resembling molds (Figure 1A and B). Upon reviewing the patient's peripheral blood smear stained with Wright's stain, an elongated oval or sausage-shaped yeast-like fungal organism was observed, characterized by a transparent septum between the cells (Figure 1C). After dual-phase cultivation on Sabouraud dextrose agar (SDA) medium, the culture showed rapid growth at 25°C within four days, forming filamentous, yellow, velvety colonies that produced a characteristic diffusible red pigment (Figure 2A). At 37°C, colonies were yeast-like after four days, slow-growing and non-pigmented (Figure 2B). Lactophenol cotton blue staining revealed typical penicillate conidiophores with a rosette or broom-like arrangement and smooth, oval-shaped conidia under culture conditions of 25°C (Figure 2C), while at 37°C, microscopy showed round to oval yeast-like cells and elongated cells with septa and blunt ends (Figure 2D). Based on morphological characteristics observed through microscopic examination and culture, the isolate was highly suspected to be *T. marneffeii*. The fungal isolate was sent to Shanghai Bioengineering Co., Ltd. for ITS sequencing and species identification to further confirm the diagnosis. The isolate was definitively identified as *T. marneffeii*. The ITS region of the fungal isolate was amplified and sequenced using the primers ITS1 and ITS4, and the obtained sequence has been deposited in GenBank under the accession number PX498444.

Antifungal Treatment

The treatment of talaromycosis in HIV-negative patients generally follows the same principles as in HIV/AIDS populations, involving an initial intensive phase with amphotericin B, followed by a prolonged consolidation phase with an azole antifungal such as itraconazole or voriconazole.²³ Given the diagnosis of *T. marneffeii* fungemia, and considering its nature as a deep-seated invasive fungal infection commonly occurring in severely immunocompromised individuals with notable mortality risk, amphotericin B is considered the first-line treatment. However, in our case, liposomal amphotericin B was not available at our hospital at the time of diagnosis. Moreover, given the patient's profound immunosuppression, hematologic fragility, and the potential toxicity profile of amphotericin B, an alternative approach was deemed necessary. After thorough multidisciplinary discussion and shared decision-making with the patient's family, voriconazole was selected as the initial antifungal agent. The patient received intravenous voriconazole (0.2 g q12h) for 2 weeks during hospitalization, followed by oral administration for an additional 2 weeks after discharge. The patient's body temperature remained consistently normal following two week of antifungal treatment (Figure 3), and

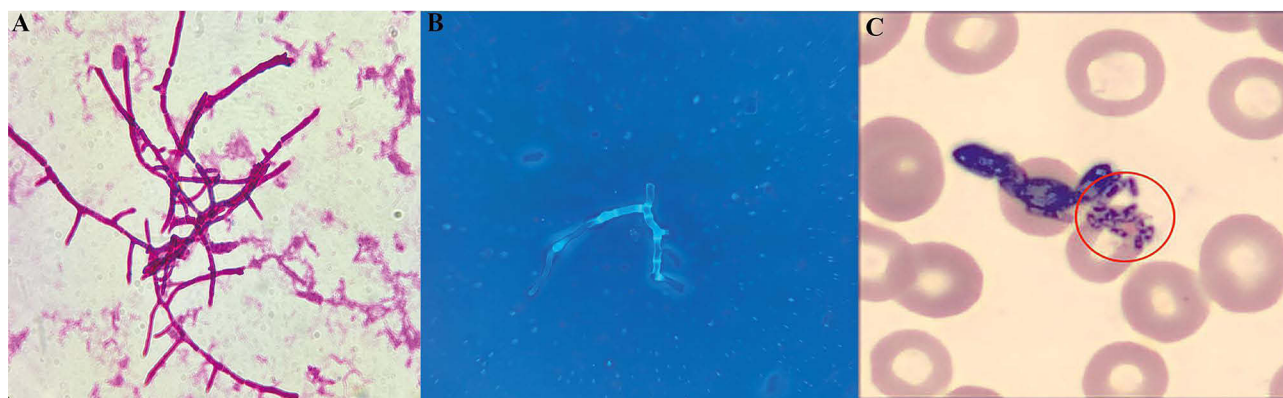

Figure 1 Morphology of fungal elements in blood culture smears observed under light and fluorescence microscopy using Gram and fungal fluorescent staining showed septate hyphae with an antler-shaped morphology. (A) Gram-stained smears under light microscopy, $\times 1000$. (B) Fluorescent-stained smears under fluorescence microscopy, $\times 1000$. (C) Wright's stained peripheral blood smear revealed an elongated oval or sausage-shaped yeast-like fungal organism, with a transparent septum separating the cells ($\times 1000$). The red circle highlights *Talaromyces marneffeii* yeast cells.

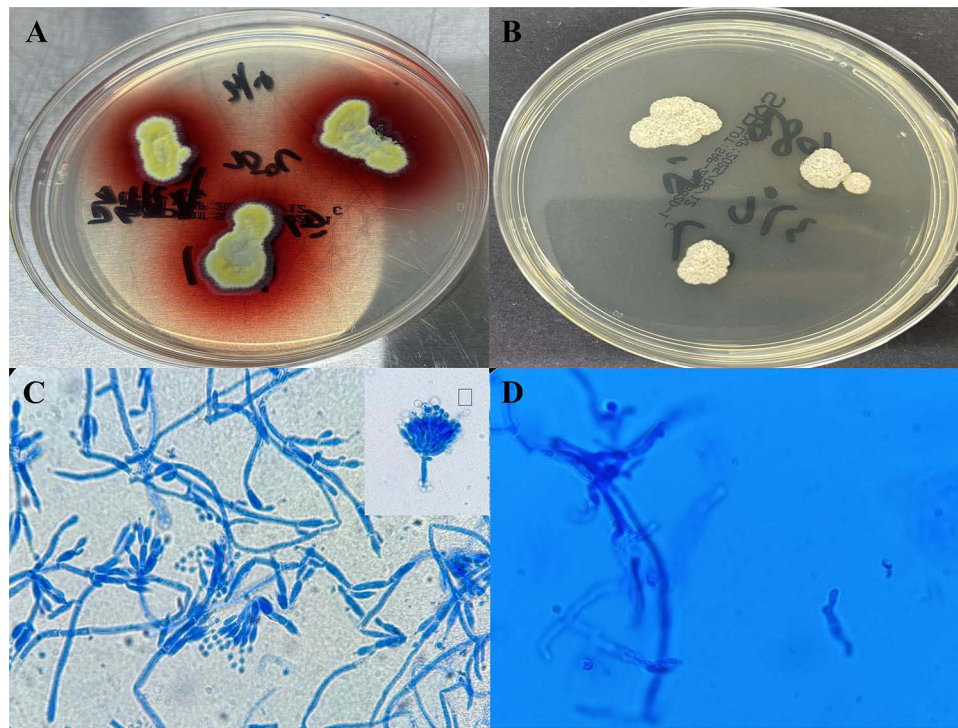


Figure 2 Colony and Microscopic Morphology of *Talaromyces marneffi* on Sabouraud Dextrose Agar under Different Incubation Conditions. **(A)** Blood culture of *T. marneffi* in the mold phase at 25°C for 4 days, showing characteristic red pigment production. **(B)** Blood culture of *T. marneffi* in the yeast phase at 37°C for 4 days. **(C)** Lactophenol cotton blue staining revealed typical penicillate conidiophores with a broom-like arrangement and smooth, oval-shaped conidia incubated at 25°C for 4 days (×1000). **(D)** Round to oval yeast-like cells and elongated cells with septa and blunt ends observed at 37°C for 4 days (×1000).

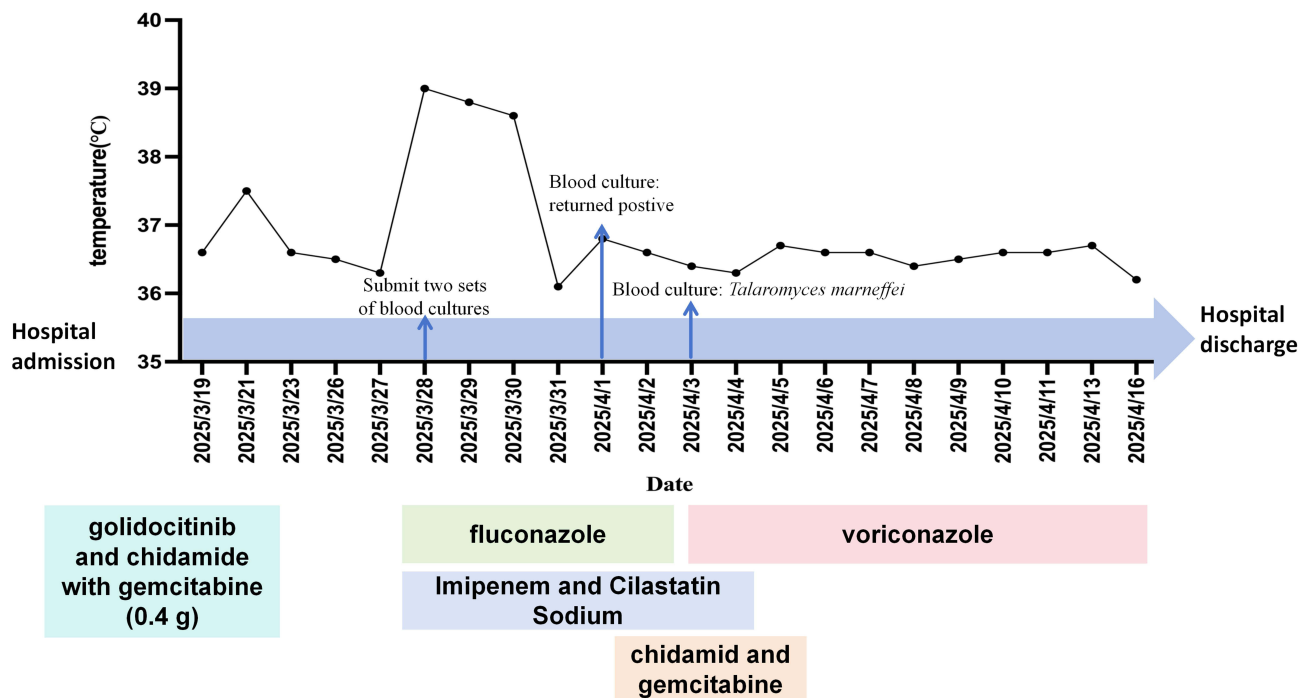


Figure 3 Hospitalization treatment timeline and changes in body temperature.

repeat blood cultures returned negative. At the time of discharge, the patient was diagnosed with stage IVB T-PLL, involving multiple lymph nodes, liver, spleen, and bone marrow, with associated malignant ascites. Following two cycles of low-dose chemotherapy (gemcitabine) combined with targeted therapy (chidamide) and corticosteroids, partial clinical

and biochemical improvement was observed, including reduced transaminase levels, LDH, and improvement in abdominal distension. However, laboratory indicators such as thrombocytopenia and hepatosplenomegaly on imaging remained, suggesting persistent disease activity. The patient was discharged in a clinically stabilized but non-remission state, with arrangements for continued outpatient follow-up and supportive care.

Discussion

Invasive *T. marneffeii* infection has traditionally been regarded as an AIDS-related opportunistic disease. However, as this and other recent cases highlight, the infection increasingly affects HIV-negative patients with hematological malignancies.^{12,13,24} Profound immune suppression, especially cell-mediated immunity deficits, and the use of targeted therapies are critical contributors to this shift in epidemiology. Notably, Chan et al reported four cases in two years in Hong Kong among patients receiving targeted therapies for hematologic malignancies.²⁵ This suggests an emerging epidemiologic pattern: patients on anti-CD20 monoclonal antibodies or kinase inhibitors in endemic regions may be at heightened risk.

We report a case of a patient with T-lymphocytic leukaemia who developed *T. marneffeii* bloodstream infection after receiving two cycles of treatment, followed by targeted therapy with chidamide, golidocitinib, and treatment with methylprednisolone.

Given the increasing use of such therapies, clinicians in or near endemic areas should be aware of talaromycosis as an opportunistic infection in hematology patients.

Summary of Reported Cases

To further analyze the characteristics of *T. marneffeii* infection in patients with hematologic malignancies undergoing immunosuppressive therapy, we have summarized the relevant literature identified through a PubMed search using the keywords “Talaromycosis”, “Penicillium”, “marneffeii”, and “penicilliosis”. Each case includes patient demographics, underlying malignancy with therapies, presenting infection sites, antifungal treatments, and outcomes (Table 1).

In the context of hematologic malignancies, *T. marneffeii* behaves not as a localized fungal infection but as a true systemic mycosis. Dissemination via the bloodstream is frequent, with potential involvement of the bone marrow, lungs, gastrointestinal tract, and skin. This systemic nature makes talaromycosis a diagnostic challenge and a clinical

Table 1 Key Features of Reported *Talaromyces marneffeii* Infections in Patients with Hematological Malignancies

Patient (Ref)	Age/ Sex	Hematologic Malignancy (Immunosuppressive Therapy)	Presentation (Symptom Duration, Days)	Infection Sites	Antifungal Treatment (Duration)	Outcome
Waldenström's macroglobulinemia (Wong et al, 2001) ²²	73/M	Waldenström's macroglobulinemia (treated with cladribine)	Initially presented with fever and septic arthritis (40days) (<i>Escherichia coli</i>).	Mixed fungemia (co-infection with <i>T. marneffeii</i> and <i>Candida tropicalis</i>)	Fluconazole 400 mg IV q24h (9 days, when <i>Candida</i> was detected) →Switched to Amphotericin B 0.5 mg/kg IV q24h on day 49 (1 day, after identification of <i>T. marneffeii</i> , before death)	Died – Rapid deterioration with pneumonia and mixed fungal sepsis
IgA Myeloma (post-Allo HSCT) (Woo et al, 2005) ²⁶	57/M	IgA myeloma (stage IIIA) s/p allogeneic stem cell transplant (conditioned with fludarabine + total body irradiation; Oral prednisolone - up to 80 mg/day)	Progressive shortness of breath (30days); Persistent fever.	Fungemia - <i>T. marneffeii</i> isolated from blood.	Amphotericin B (IV) (2.5 weeks)– started after blood culture grew fungus	Died – Multi-organ failure despite therapy

(Continued)

Table 1 (Continued).

Patient (Ref)	Age/ Sex	Hematologic Malignancy (Immunosuppressive Therapy)	Presentation (Symptom Duration, Days)	Infection Sites	Antifungal Treatment (Duration)	Outcome
Non-Hodgkin's Lymphoma (NHL) (Deesomchok et al, 2006) ²⁷	45/M	NHL (various stages, prior chemotherapy in remission)	Symptoms: Cough, dyspnea, weight loss, neck mass; Extrapulmonary signs: Cervical lymphadenopathy.	<i>T. marneffeii</i> pneumonia	Oral Itraconazole (duration not explicitly reported)	Survived—Improved with antifungal therapy
Waldenström's macroglobulinemia; ITP (Chan et al, 2015 – Case 1) ²⁵	56/M	Waldenström's macroglobulinemia (treated with fludarabine, dexamethasone, and rituximab 18 months prior); also ITP (on prednisone, mycophenolate)	Fever, night sweats, cough, left facial pain (7 days); Disseminated: cavitory lung lesions, chronic nasopharyngitis, terminal ileitis (bloody diarrhea 2 days).	Feces, biopsies of ileum and nasopharynx positive for <i>T. marneffeii</i> .	Liposomal Amphotericin B IV (2 weeks) followed by oral voriconazole (>21 months)	Survived –Full recovery; lesions resolved at 2–6 months.
Chronic Lymphocytic Leukemia (Chan et al, 2015 – Case 2) ²⁵	44/M	Chronic lymphocytic leukemia (heavily pretreated: fludarabine/cyclophosphamide, CHOP, bendamustine; on rituximab 14 months prior and receiving obinutuzumab)	Fever (2 days); Marrow involvement: pancytopenia.	Fungemia –peripheral blood and bone marrow aspirate grew <i>T. marneffeii</i> .	Amphotericin B IV (2 weeks) → Itraconazole oral (5 months)	Initial survival, cleared fungemia; later died ~5 months post-infection from other opportunistic infections (bacteremia, candidemia, then multi-organ failure)
Myelofibrosis (Chan et al, 2015 – Case 3) ²⁵	63/M	Primary myelofibrosis (post-splenectomy) on ruxolitinib (JAK1/2 inhibitor) for 6.5 months; also type 2 diabetes (well-controlled)	Intermittent fever, right cervical lymph node enlargement and productive cough (4 months).	Lymph node biopsy grew <i>T. marneffeii</i> .	Amphotericin B IV (2 weeks) → Voriconazole oral (>6 months).	Survived –Symptoms and radiologic abnormalities resolved after treatment.
Acute Myeloid Leukemia (Chan et al, 2015 – Case 4) ²⁵	67/M	Acute myeloid leukemia (on remission maintenance with sorafenib multikinase inhibitor for 8 months); multiple prior chemo cycles (cytarabine, clofarabine, etc).	Fever, malaise without focal signs (2 days).	Fungemia– blood cultures grew <i>T. marneffeii</i> .	Amphotericin B IV (2 weeks) → Voriconazole oral (>5 months).	Survived –Remained well at follow-up 6 months after symptom onset.
Nodular Sclerosing Hodgkin Lymphoma (HL) (Yang et al, 2021) ²⁸	51/M	NSHL (Stage II, Group B) (nodular sclerosis subtype) – newly diagnosed; comorbidity: diabetes mellitus; no prior chemo (HIV-negative); hormone therapy.	Cough, sputum, intermittent afternoon and nighttime fever; cervical lymph node enlargement (30 days). Pulmonary infiltrates (diffuse nodules on CT) and mediastinal nodes.	Disseminated <i>T. marneffeii</i> fungemia (in the blood, lungs, skin, and subcutaneous tissue)	Liposomal Amphotericin B IV (14 days) → Voriconazole IV (6 days) → Voriconazole oral (>5 months) →Itraconazole oral (>2 weeks).	Died – Improvement on antifungals (no relapse); Readmitted due to fever and diagnosed with Salmonella sepsis, discharged after treatment, finally died due to recurrent fever.
Non-Secretory Myeloma (NSMM) (Qin et al, 2021) ⁹	51/M	Non-secretory myeloma (diagnosed after infection); no prior myeloma therapy.	Intermittent fever, chest pain, swollen lymph nodes, and subcutaneous nodules (2 years).	Disseminated talaromycosis (lungs, lymph nodes, skin, bone, and subcutaneous tissue).	Fluconazole (400 mg/day, for 5 days) →Amphotericin B (2 weeks, gradual dose escalation: starting at 10 mg/day, gradually increasing to 25 mg/day).	Survived –Overall condition improved after the antifungal amphotericin B treatment.
Nodal Marginal Zone Lymphoma (NMZL) (Yu et al, 2024) ¹³	76/M	Nodal marginal zone B-cell lymphoma (indolent; diagnosed concurrently); no prior lymphoma treatment.	Persistent fever and cough (over 20 days); CT showed left lung infiltrate, along with multiple enlarged lymph nodes: lung hilar, mediastinal regions, the left supraclavicular side and retroperitoneal; bilateral renal and adrenal mass.	Left supraclavicular lymph node biopsy revealed NMZL with <i>T. marneffeii</i> infection (bronchial lavage fluid culture <i>T. marneffeii</i> positive).	Voriconazole IV (400 mg/day, 15 days) →Voriconazole oral (400 mg/day, 9 months)	Survived – Pulmonary lesions resolved and lymph nodes shrank on voriconazole. No recurrence of <i>T. marneffeii</i> at 3-year follow-up; lymphoma in stable without progression.

Abbreviations: ITP, immune thrombocytopenic purpura; HSCT, hematopoietic stem cell transplant; CHOP, cyclophosphamide, doxorubicin, vincristine, prednisone; JAK, Janus kinase; s/p, status post; NMZL, nodal marginal zone lymphoma.

emergency. In our case and others reviewed, fungemia was not only a marker of severity but also a key diagnostic clue. Prompt recognition of this systemic pattern is critical to improve outcomes.

Comparison with Published Cases in Hematologic Malignancies

Our patient, an HIV-negative woman with T-PLL, represents one of the few reported cases of *T. marneffeii* fungemia in this rare subtype of leukemia. Previous literature¹² includes reports of disseminated *T. marneffeii* infections in patients with chronic lymphocytic leukemia (CLL), Waldenström's macroglobulinemia, myelofibrosis, and acute myeloid leukemia. Common features across these cases include: 1) Prolonged neutropenia or lymphopenia, often due to chemotherapy or targeted agents (eg, rituximab, fludarabine, JAK inhibitors). 2) Geographic exposure to endemic regions in Southeast Asia or southern China. 3) Delayed diagnosis, frequently due to overlapping clinical presentations with malignancy progression or other opportunistic infections.

A key similarity between our case and those reported by Chan et al¹² is the occurrence of infection during or shortly after administration of novel immunosuppressive agents, particularly kinase inhibitors like ruxolitinib or golidocitinib. These therapies impair macrophage and T-cell-mediated responses, which are crucial for host defense against *T. marneffeii*. Specifically, chidamide, a histone deacetylase inhibitor (HDACi), suppresses Th1 and Th17 differentiation and impairs macrophage function. Similarly, golidocitinib (a JAK1/2 inhibitor) interferes with cytokine signaling pathways, such as IFN- γ and IL-17, that are critical for the immune response against fungal infections. In our case, the use of chidamide and golidocitinib likely synergistically contributed to profound immunosuppression and increased susceptibility to *T. marneffeii* fungemia.

Table 1 shows that disseminated fungemia was associated with a higher risk of mortality, especially when antifungal therapy was delayed or inadequate. Notably, a CLL patient developed *T. marneffeii* fungemia and marrow infiltration but eventually died from other opportunistic infections despite initial antifungal response.²⁵ Conversely, early antifungal treatment, as seen in the marginal zone lymphoma case,¹³ was associated with complete remission and no recurrence at 3-year follow-up.

Diagnostic Challenges and Mycological Clues

Clinically, talaromycosis in this population may masquerade as progressive hematologic malignancy, tuberculosis, or bacterial sepsis. Fever, lymphadenopathy, pulmonary infiltrates, and cytopenias are common but nonspecific. Our patient's rapidly worsening cytopenias and fever were initially attributed to chemotherapy-related toxicity and viral reactivations (CMV, EBV, HHV-6B), delaying suspicion for fungal infection.

The gold standard is fungal culture or histopathology from clinical specimens. Blood cultures are often positive in disseminated talaromycosis. In the reviewed cases, *T. marneffeii* was isolated from blood in at least five patients (including those with fungemia and marrow involvement). Microbiological diagnosis is also essential. In our case, fungal culture yielded characteristic morphology: a red pigment-producing mold phase at 25°C and a yeast-like form at 37°C. This dual-phase morphology is a hallmark of *T. marneffeii*, as noted in nearly all reviewed cases.

In summary, a multimodal approach is recommended when talaromycosis is in the differential. Clinicians should obtain biopsies of accessible lesions (such as lymph nodes, skin, etc.) for histopathology and culture, perform blood cultures, and consider a bone marrow biopsy if no other site is yielding a diagnosis.

Therapeutic Considerations

Amphotericin B (AmB) remains the recommended induction therapy, followed by itraconazole for consolidation.²³ However, it is worth noting that a recent randomized trial in HIV patients compared high-dose itraconazole as primary therapy to AmB, finding that itraconazole was not inferior for mild-to-moderate cases, while AmB was superior for severe disease.²⁹ In malignancy patients, most experts still advocate using AmB for induction, given the high mortality if treatment fails. That said, in cases where AmB is contraindicated (eg, renal failure or infusion reactions), an azole (voriconazole or high-dose itraconazole) can be used as an alternative initial. In several reviewed cases¹³—including ours—voriconazole monotherapy was successfully used, particularly when AmB was unavailable or contraindicated. Our patient's clinical stability and rapid defervescence support this alternative, especially in resource-limited settings.

In disseminated *T. marneffei* infection, prolonged antifungal therapy is crucial, particularly for immunocompromised patients. Current guidelines recommend a minimum of 12 weeks of treatment for severe cases, especially in those with hematologic malignancies. Treatment duration may vary depending on clinical response, relapse risk, and patient factors. Our literature review (Table 1) shows antifungal durations ranging from 2 weeks to over 21 months. Delayed diagnosis and poor initial response can lead to worse outcomes, as seen in cases like Waldenström's macroglobulinemia.²² Early initiation of appropriate therapy, as in the marginal zone lymphoma case, was associated with complete remission and no recurrence at 3-year follow-up.¹³

Managing talaromycosis does not preclude treating the cancer—delaying chemotherapy could allow the infection to worsen, while delaying antifungals could allow the fungus to proliferate. In practice, physicians have carefully employed combined therapy or staged therapy. In the NSMM myeloma case, antifungal treatment was initiated first (to address the acute infection), and once the patient stabilized and fungal burden decreased, definitive chemotherapy for myeloma was administered, leading to long-term remission.⁹ The timing requires judgment – often, antifungal induction is given for a few weeks. Cancer therapy can resume once clear improvement is seen (with careful monitoring and secondary prophylaxis to prevent fungal relapse). This coordinated approach maximizes patient outcomes.

Conclusion

This case expands the spectrum of hematologic malignancies associated with *T. marneffei* and confirms its capacity to cause infections in non-HIV patients receiving targeted therapies. Literature review highlights emerging patterns in risk factors (notably kinase inhibitors), the nonspecific clinical presentation, and the critical role of early mycological diagnosis. Voriconazole appears to be an effective treatment option when amphotericin B is unavailable. Greater awareness among hematologists and infectious disease specialists is necessary to enhance recognition and improve outcomes.

Abbreviations

T. marneffei, *Talaromyces marneffei*; T-PLL, T-prolymphocytic leukaemia; ITS, internal transcribed spacer; TSM, talaromycosis; HIV, human immunodeficiency virus; JAK, Janus kinase; IFIs, invasive fungal infections; AML, acute myeloid leukemia; ALL, acute lymphoblastic leukemia; NHL, non-Hodgkin lymphomas; PCN, plasma cell neoplasms; RES, reticuloendothelial system; CNS, central nervous system; IVIG, intravenous immunoglobulin; CMV, cytomegalovirus; HHV-6B, human herpesvirus type 6B; EBV, Epstein-Barr virus; SDA, Sabouraud dextrose agar; HSCT, hematopoietic stem cell transplant; ITP, immune thrombocytopenic purpura; CHOP, cyclophosphamide, doxorubicin, vincristine, prednisone; HL, Hodgkin Lymphoma; NSMM, nodal marginal zone lymphoma; CLL, chronic lymphocytic leukemia.

Data Sharing Statement

Data on the case clinical information and images are available for review from the corresponding author upon request.

Ethics Approval

The study was conducted according to the guidelines of the Declaration of Helsinki and approved by the Ethics Committee of Cancer Hospital Chinese Academy of Medical Sciences Shenzhen Center (JS2024-18-1; 29 August 2024). Institutional approval for the publication of the case details was not specifically required. However, the ethical approval mentioned above covers the study's ethical conduct, including the use of anonymized patient data for publication to protect patient privacy.

Consent to Participate

Informed consent was obtained from the participant included in the study.

Consent to Publish

The participant has consented to the submission of the case report to the journal.

Acknowledgments

We gratefully acknowledge the efforts and support provided by the staff of the Microbiology Laboratory, Cancer Hospital Chinese Academy of Medical Sciences, Shenzhen Center, for their valuable contributions to this work.

Author Contributions

All authors made a significant contribution to the work reported, whether that is in the conception, study design, execution, acquisition of data, analysis and interpretation, or in all these areas; took part in drafting, revising or critically reviewing the article; gave final approval of the version to be published; have agreed on the journal to which the article has been submitted; and agree to be accountable for all aspects of the work.

Funding

This work was supported by Sanming Project of Medicine in Shenzhen (No.SZSM202311002).

Disclosure

The authors declare that they have no competing interests related to this study.

References

- Supparatpinyo K, Khamwan C, Baosoung V, Nelson KE, Sirisanthana T. Disseminated *Penicillium marneffei* infection in Southeast Asia. *Lancet*. 1994;344(8915):110–113. doi:10.1016/s0140-6736(94)91287-4
- DiSalvo AF, Fickling AM, Ajello L. Infection caused by *Penicillium marneffei*: description of first natural infection in man. *Am J Clin Pathol*. 1973;60(2):259–263. doi:10.1093/ajcp/60.2.259
- Vanittanakom N, Cooper CR, Fisher MC, Sirisanthana T. *Penicillium marneffei* infection and recent advances in the epidemiology and molecular biology aspects. *Clin Microbiol Rev*. 2006;19(1):95–110. doi:10.1128/CMR.19.1.95-110.2006
- Narayanasamy S, Dat VQ, Thanh NT, et al. A global call for talaromycosis to be recognised as a neglected tropical disease. *Lancet Glob Health*. 2021;9(11):e1618–e1622. doi:10.1016/S2214-109X(21)00350-8
- Li Y, Lin Z, Shi X, et al. Retrospective analysis of 15 cases of *Penicillium marneffei* infection in HIV-positive and HIV-negative patients. *Microb Pathog*. 2017;105:321–325. doi:10.1016/j.micpath.2017.01.026
- Zheng J, Gui X, Cao Q, et al. A clinical study of acquired immunodeficiency syndrome associated *Penicillium marneffei* infection from a non-endemic area in China. *PLoS One*. 2015;10(6):e0130376. doi:10.1371/journal.pone.0130376
- Hu Y, Zhang J, Li X, et al. *Penicillium marneffei* infection: an emerging disease in mainland China. *Mycopathologia*. 2013;175(1–2):57–67. doi:10.1007/s11046-012-9577-0
- Le T, Wolbers M, Chi NH, et al. Epidemiology, seasonality, and predictors of outcome of AIDS-associated *Penicillium marneffei* infection in Ho Chi Minh City, Viet Nam. *Clin Infect Dis*. 2011;52(7):945–952. doi:10.1093/cid/cir028
- Qin H, Qiu Y, Huang Y, et al. Rare incidence of non-secretory myeloma with talaromycosis: a case report. *BMC Infect Dis*. 2021;21(1):964. doi:10.1186/s12879-021-06641-3
- Qiu Y, Liao H, Zhang J, Zhong X, Tan C, Lu D. Differences in clinical characteristics and prognosis of *Penicilliosis* among HIV-negative patients with or without underlying disease in Southern China: a retrospective study. *BMC Infect Dis*. 2015;15(1):525. doi:10.1186/s12879-015-1243-y
- Lee N. *Penicilliosis*: an AIDS-defining disease in Asia. *Hong Kong Med J*. 2008;14(2):88–89.
- Chan JF, Lau SK, Yuen KY, Woo PC. Talaromyces (*Penicillium*) *marneffei* infection in non-HIV-infected patients. *Emerg Microbes Infect*. 2016;5(3):e19. doi:10.1038/emi.2016.18
- Yu X, Xu H, Zhou J, Zhu Z, Li B. Case report: a 3-year follow-up on nodal marginal zone lymphoma coexisting with disseminated *Talaromyces marneffei* infection in a non-endemic area. *Front Oncol*. 2024;14:1407893. doi:10.3389/fonc.2024.1407893
- Pagano L, Busca A, Candoni A, et al. Risk stratification for invasive fungal infections in patients with hematological malignancies: SEIFEM recommendations. *Blood Rev*. 2017;31(2):17–29. doi:10.1016/j.blre.2016.09.002
- Ramírez I, Hidirón A, Cardona R. Successful treatment of pulmonary invasive fungal infection by *Penicillium non-marneffei* in lymphoblastic lymphoma: case report and literature review. *Clin Case Reports*. 2018;6(6):1153–1157. doi:10.1002/ccr3.1527
- Hammond SP, Marty FM, Bryar JM, DeAngelo DJ, Baden LR. Invasive fungal disease in patients treated for newly diagnosed acute leukemia. *Am J Hematol*. 2010;85(9):695–699. doi:10.1002/ajh.21776
- Wasylyshyn A, Linder KA, Castillo CG, Zhou S, Kauffman CA, Miceli MH. Breakthrough invasive fungal infections in patients with acute myeloid leukemia. *Mycopathologia*. 2020;185(2):299–306. doi:10.1007/s11046-019-00418-8
- Mehta D, Hofacker SA, Villalba JA, et al. First reported case of invasive cutaneous *penicillium cluniae* infection in a patient with acute myelogenous leukemia: a case report and literature review. *Open Forum Infect Dis*. 2021;8(7):ofab265. doi:10.1093/ofid/ofab265
- Pruksaphon K, Nosanchuk JD, Ratanabanangkoon K, Youngchim S. *Talaromyces marneffei* infection: virulence, intracellular lifestyle and host defense mechanisms. *J Fungi*. 2022;8(2):200. doi:10.3390/jof8020200
- Le T, Huu Chi N, Kim Cuc NT, et al. AIDS-associated *Penicillium marneffei* infection of the central nervous system. *Clin Infect Dis*. 2010;51(12):1458–1462. doi:10.1086/657400
- Cao C, Xi L, Chaturvedi V. Talaromycosis (*Penicilliosis*) due to *talaromyces (Penicillium) marneffei*: insights into the clinical trends of a major fungal disease 60 years after the discovery of the pathogen. *Mycopathologia*. 2019;184(6):709–720. doi:10.1007/s11046-019-00410-2

22. Wong SSY, Woo PCY, Yuen KY. *Candida tropicalis* and *penicillium marneffeii* mixed fungaemia in a patient with Waldenström's macroglobulinaemia. *EJCMID*. 2001;20(2):132–135. doi:10.1007/PL00011243
23. Supparatpinyo K, Perriens J, Nelson KE, Sirisanthana T. A controlled trial of itraconazole to prevent relapse of *penicillium marneffeii* infection in patients infected with the human immunodeficiency virus. *N Engl J Med*. 1998;339(24):1739–1743. doi:10.1056/NEJM199812103392403
24. Yang H, Liu M, Xu N, et al. Disseminated *Talaromyces marneffeii* infection associated with haemophagocytic syndrome in an HIV-negative patient in northern China: a case report. *BMC Infect Dis*. 2024;24(1):63. doi:10.1186/s12879-023-08953-y
25. Chan JFW, Chan TSY, Gill H, et al. Disseminated infections with *Talaromyces marneffeii* in non-AIDS patients given monoclonal antibodies against CD20 and kinase inhibitors. *Emerg Infect Dis J*. 2015;21(7):1101. doi:10.3201/eid2107.150138
26. Woo PCY, Lau SKP, Lau CCY, et al. *Penicillium marneffeii* fungaemia in an allogeneic bone marrow transplant recipient. *Bone Marrow Transplant*. 2005;35(8):831–833. doi:10.1038/sj.bmt.1704895
27. Deesomchok A, Tanprawate S. A 12-case series of *Penicillium marneffeii* pneumonia. *J Med Assoc Thai*. 2006;89(4):441–447.
28. Yang Z, Zeng W, Qiu Y, Liu G, Zhang J. Nodular sclerosing hodgkin lymphoma combined with disseminated *talaromyces marneffeii* infection: a case report. *Infect Drug Resist*. 2021;14:5671–5678. doi:10.2147/IDR.S340192
29. Le T, Kinh NV, Cuc NTK, et al. A trial of itraconazole or amphotericin B for HIV-associated talaromycosis. *N Engl J Med*. 2017;376(24):2329–2340. doi:10.1056/NEJMoa1613306

Infection and Drug Resistance

Publish your work in this journal

Infection and Drug Resistance is an international, peer-reviewed open-access journal that focuses on the optimal treatment of infection (bacterial, fungal and viral) and the development and institution of preventive strategies to minimize the development and spread of resistance. The journal is specifically concerned with the epidemiology of antibiotic resistance and the mechanisms of resistance development and diffusion in both hospitals and the community. The manuscript management system is completely online and includes a very quick and fair peer-review system, which is all easy to use. Visit <http://www.dovepress.com/testimonials.php> to read real quotes from published authors.

Submit your manuscript here: <https://www.dovepress.com/infection-and-drug-resistance-journal>

Dovepress

Taylor & Francis Group