


Application of Polidocanol Foam Injection Sclerotherapy in Patients with Antithrombotic Therapy Combined with Mixed Hemorrhoid Bleeding: A Retrospective Single-Center Case Series and Narrative Review (with Video)

Zhen Li*, Hailong Liu*, Wenjing Ding*, Song Wang*, Liang Lv, Xiaobin Li, Haibo Ding 

Department of General Surgery, Yangpu Hospital of Tongji University, Shanghai, 200090, People's Republic of China

*These authors contributed equally to this work

Correspondence: Haibo Ding, Department of General Surgery, Yangpu Hospital of Tongji University, 450 Tengyue Road, Shanghai, 200090, People's Republic of China, Tel +86-18317166106, Email 2812097576@qq.com



Purpose: For patients with antithrombotic therapy combined with mixed hemorrhoid bleeding, the contradiction between antithrombotic and hemostatic treatments often requires surgical intervention. However, multi-country guidelines recommend the use of injection sclerotherapy (IST), but there is little research on the application of polidocanol foam IST. The purpose of this study is to explore the retrospective single-center case series experience of polidocanol foam IST in those patients and review the related literature.

Patients and Methods: From March 2018 to May 2023, we retrospectively analyzed the clinical data of 7 patients with mixed hemorrhoid bleeding in the General Surgery Department of Yangpu Hospital affiliated with Tongji University. These patients all received antithrombotic treatment and their bleeding could not be stopped by conservative treatment. Finally, they all received polidocanol foam IST. We summarized the single-center clinical application experience of polidocanol foam IST in those patients. Through a literature search, the related literature concerning the application of polidocanol foam IST in patients with antithrombotic therapy combined with mixed hemorrhoid bleeding were reviewed.

Results: Seven patients were successfully treated with polidocanol foam IST, and the bleeding stopped. The operation time ranged from 10–30 minutes, and no serious complications occurred. At the 4-week postoperative follow-up evaluation, none of the patients had bleeding again, and hemoglobin significantly increased (106.0 ± 17.4 g/L vs 70.9 ± 19.7 g/L, $p=0.004$). Four weeks after surgery, the overall clinical efficacy rate reached 100%, with a satisfaction rate of 100%. Through a literature review, three studies were ultimately included for analysis.

Conclusion: Polidocanol foam IST is a relatively safe and effective method for patients receiving antithrombotic therapy combined with mixed hemorrhoid bleeding. However, larger multicenter prospective studies are needed before this is the preferred treatment for such patients.

Keywords: polidocanol foam sclerotherapy, antithrombotic therapy, bleeding, hemorrhoids

Introduction

Epidemiological studies have shown that for patients receiving antithrombotic drug treatment, 1.5%–4.5% may experience gastrointestinal bleeding during treatment,¹ with 21.7% coming from hemorrhoid bleeding.² This stubborn hemorrhoid bleeding induced by sustained antithrombotic drugs can often be life-threatening.³ This contradiction



between antithrombotic and hemostatic treatment makes conservative treatment ineffective and often requires surgical intervention. However, guidelines from multiple countries do not recommend traditional Rubber band ligation (RBL) therapy but Injection sclerotherapy (IST),⁴ due to the high risk of rebleeding.

IST, a minimally invasive treatment method, has shown good efficacy and safety in the treatment of internal hemorrhoids in recent years.⁵ Some prospective studies on polidocanol foam IST also found that it has satisfactory hemostasis effect for patients receiving antithrombotic drugs.⁶ The Chinese expert consensus on hemorrhoid injection therapy (2023 edition) also strongly recommends the use of polidocanol for the treatment of Grade I–III hemorrhoids and hemorrhoid bleeding.⁷ However, there are also many studies on the polidocanol foam IST that list the history of antithrombotic drug treatment as the exclusion criteria.^{8,9} In addition, there is no clear international consensus on the use of polidocanol foam IST in patients with antithrombotic therapy combined with mixed hemorrhoid bleeding.

The research team of the author started performing polidocanol foam IST in 2018 and has completed 119 patients, with some clinical experience. On this basis, the research team of the author extended polidocanol foam IST to the patients with antithrombotic therapy combined with mixed hemorrhoid bleeding and achieved relatively ideal results. In this study, we conducted a retrospective analysis of single center case data and conducted a literature review of relevant research. The purpose is to provide single center experience and the latest literature review results for the application of polidocanol foam IST in patients with antithrombotic therapy combined with mixed hemorrhoid bleeding.

Materials and Methods

Patient Selection

From March 2018 to May 2023, a total of 7 patients with mixed hemorrhoid bleeding who were treated with antithrombotic therapy but failed conservative treatment for hemorrhoids were admitted to the General Surgery Department of Yangpu Hospital affiliated with Tongji University consecutively. The patients and their families signed a surgical consent form before the operation, and this study was approved by the Ethics Committee of Yangpu Hospital of Tongji University (Yangpu District Central Hospital) (No. LL-2024–LW-015) and followed the precepts established by the Helsinki Declaration.

The inclusion criteria were as follows: (1) Patient with hemorrhoid bleeding and failed conservative treatment; (2) Patients require continuous antithrombotic therapy; (3) Patients with anemia or coagulation dysfunction; (4) Patients inability to tolerate anesthesia and surgery.

The exclusion criteria were as follows: (1) Patients allergic to polidocanol; (2) Patients combined with incarcerated mixed hemorrhoids and other anorectal diseases (perianal abscess, anal fistula, anal fissure, rectal polyps, rectal cancer, etc.); (3) Internal hemorrhoids with thrombosis, entrapment, ulceration, infection, etc.

Surgical Methods

Patient Preparation

- (1) Routine digital rectal examination is performed to rule out other anal and rectal diseases;
- (2) No need to stop using antithrombotic drugs, just empty the stool before treatment, no need for intestinal preparation (recommended enemas for patients with constipation), and no need for anesthesia or prophylactic antibiotic use;
- (3) The patient's condition should be communicated, and informed consent should be obtained before treatment.

Preparation of Venue and Equipment

- (1) Polidocanol foam IST can be performed in outpatient operating rooms/operating rooms without the need for monitoring equipment;
- (2) Adult anoscope;
- (3) Polidocanol 3% injection, three-way tube*1, 10 mL/20 mL syringe*2, 21G needle.

Preparation of Polidocanol Foam (Tessari Technique)

- (1) Configuration proportion: A 10 mL syringe without silica gel (with a rubber plug) draws 8 mL of air, and another 10 mL syringe draws 2 mL of liquid sclerosant to make a 10 mL foam sclerosing agent (20 mL syringe draws multiple times);
- (2) Configuration method: A three-way valve is used to connect these two syringes and rotate them to a 90-degree angle; the syringe is quickly injected until it reaches the end, promoting the mixing of air and sclerosants, and vice versa (10 times); the three-way valve is rotated to tilt it, and the two syringes are still connected, but the channel is closed; then, 10 back–forth injections are carried out to prepare white uniform foam-like sclerosants (Figure 1A).¹⁰

Injection Therapy Steps

- (1) Position and disinfection: The patient was placed in a Jack-knife Prone Position, a lithotomy position, or a left lateral position. The surgical field of view is routinely disinfected, and sterile towels are laid in place;
- (2) Anal examination: An anal endoscope is inserted to identify the distribution and size of the hemorrhoids;
- (3) Precautions for IST: The injection should be started immediately after the successful preparation of polidocanol foam (delayed injection after the preparation of foam will lead to liquid accumulation and a decrease in the foam volume, which will affect the therapeutic effect);⁹
- (4) Injection method: The injection site should be located at the base of the hemorrhoid above the dentate line, and the depth should be strictly controlled in the submucosal layer. The injection angle should include multiple angles (3, 7, and 11 directions and an obvious venous plexus). The injection volume should be determined according to the size and tolerance of the hemorrhoids until they become larger and white (0.4–2 mL of sclerosant foam should be injected at each injection point, with a total amount of 2–10 mL, and the needles should be withdrawn during injection) (Figure 1B and C).
- (5) Postinjection treatment: After injection, the hemorrhoids were fully massaged to evenly distribute the sclerosants under the mucosa, and the wounds were covered with Vaseline gauze. All patients who receive IST can be discharged and resume daily activities or work on the same day after surgery. Patients do not need to take a sitz bath after surgery, but need to be treated with anhemorrhoid suppositories and sodium aescinate tablets for 2 weeks.

Postinjection Efficacy Evaluation and Treatment Course

- (1) Efficacy evaluation: After the injection is complete, the patient is followed up for the fourth week to assess improvements in symptoms such as bleeding and prolapse and to evaluate the patient's efficacy. The definition of a cure is the disappearance of symptoms such as rectal bleeding, prolapse, or pain in the patient and the disappearance of varicose veins without serious complications. The definition of improvement was significant improvement in symptoms such as rectal bleeding and prolapse, significant reduction in varicose veins, and no serious complications. The definition of vitiation is as follows: clinical symptoms; the size of the hemorrhoids has not changed after treatment; and even the condition has worsened or is accompanied by serious complications.

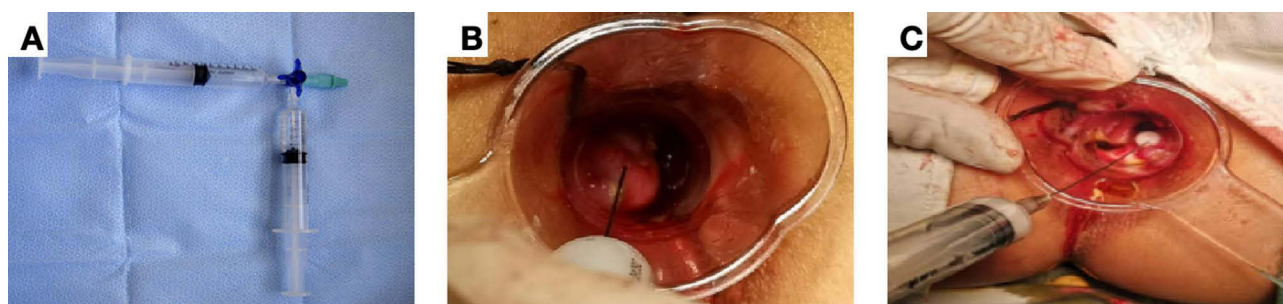


Figure 1 Preparation and injection method of polidocanol foam. Preoperative diagnosis and treatment. (A) Preparation of polydocanol foam via the Tessari technique; (B) Injection site of polydocanol foam; (C) Injection effect of polydocanol foam.

The definitions of serious complications are as follows: (a) bleeding that requires hospitalization for hemostasis and blood transfusion treatment; (b) severe pain that requires hospitalization for treatment; and (c) urinary retention requiring catheterization. The clinical total effective rate = (number of cured cases + number of improved cases) / total number of cases \times 100%.¹¹

- (2) Treatment course: If the patient's symptoms do not improve, IST can be performed again, with a recommended treatment interval of 2 weeks; if the patient does not improve after 4 treatments, it is recommended to switch to other treatment methods.

Literature Review

Literature Search

We searched for literature on the key words polidocanol and hemorrhoids published in the PubMed, Embase, Web of Science, and Cochrane Library databases until September 1, 2025. The search strategies are shown in [Table 1](#).

Inclusion Criteria

- Original research articles published in international journals;
- The research subjects were clinically diagnosed with hemorrhoids;
- Literature directly reported the efficacy of polidocanol foam IST in antithrombotic patients, or we could obtain them through data calculation or extraction from the literature charts;

Exclusion Criteria

- Reviews, animal research, basic research, case reports, research protocols, conference papers, etc.
- Studies that did not report the efficacy of polidocanol foam IST in hemorrhoid patients with antithrombotic therapy.
- Duplicate publications or studies.

Literature Screening and Summary

The literature retrieval was conducted by two independent researchers according to a unified search strategy. NoteExpress literature management software was used to screen all the retrieved literature. For literature which was uncertain whether they could be included, two researchers discussed them first. If they could still not decide, a third researcher intervened to decide whether to include it. If they could still not decide, they contacted the author to decide whether to include it.

The final included literature on the application of polidocanol foam IST in patients with antithrombotic therapy combined with mixed hemorrhoid bleeding was summarized.

Statistical Analysis

SPSS 26.0 was used for data analysis. The haemoglobin data were expressed as $X \pm S$. A simple *t*-test was used to compare hemoglobin levels before and after surgery. $P < 0.05$ indicated a statistically significant difference.

Results

Seven patients were successfully treated with polidocanol foam injection for hemostasis ([Supplement Video](#)). The operation time ranged from 10–30 minutes, with an average of 19.7 ± 8.2 minutes. When reexamination was conducted 4 weeks after the operation, none of the patients experienced rebleeding ([Figure 2](#)). These 7 patients all had varying degrees of preoperative anemia, but their postoperative hemoglobin levels significantly increased at 4 weeks (106.0 ± 17.4 g/L vs 70.9 ± 19.7 g/L, $p = 0.004$). After 4 weeks of postoperative follow-up, no patients experienced serious complications, with a total clinical efficacy rate of 100% and a satisfaction rate of 100% ([Table 2](#)). After one year of postoperative follow-up, only one patient experienced recurrence, which improved after IST was performed again.

Through the literature review, only 3 studies were eligible for inclusion, as shown in [Table 3](#).

Discussion

There is a contradiction in patients receiving antithrombotic therapy combined with mixed hemorrhoid bleeding. The risk of thromboembolism increases after discontinuation,¹⁵ continuous antithrombotic drug treatment not only increases the

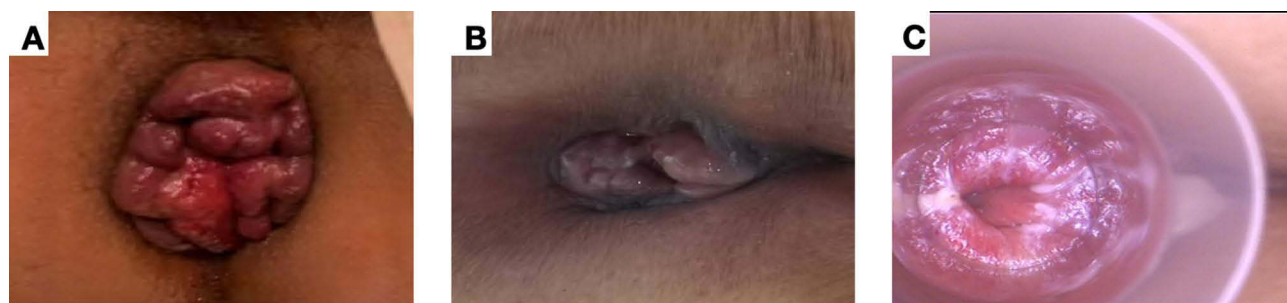


Figure 2 Therapeutic effect of polidocanol foam injection for sclerotherapy. (A) Preoperative hemorrhoid condition; (B) Hemorrhoid condition 2 weeks after surgery. (C) Follow-up examination of hemorrhoids 4 weeks after surgery.

success rate of 93–98% in patients with Grade I–III hemorrhoids.^{6,24} Compared with RBL, it has a lower incidence of postoperative complications such as rebleeding and pain²⁴ and is safer in the treatment of patients with hemorrhoidal bleeding who are receiving antithrombotic therapy.²⁵ Therefore, it is recommended as the preferred therapy for drug-resistant low-grade bleeding hemorrhoids.²⁶ In addition, IST does not require anesthesia or bowel preparation and can be quickly treated for hemostasis in outpatient settings.⁶ It not only has high reproducibility and cost-effectiveness but also high patient satisfaction.²⁷ The mechanism of IST for internal hemorrhoids is mainly to inject sclerosants into the submucosa and nucleus of the hemorrhoids, producing a sterile inflammatory response. This can lead to hemorrhoid coagulation, hemorrhoid vascular occlusion, fibrosis, and hemorrhoid tissue fixation. Thus achieving the effect of hemorrhoid atrophy and hemostasis, reducing patient's stool and itching, and alleviating prolapse symptoms.²⁸ This treatment method not only conforms to the theory of prolapse of the anatomical anal cushions, but also conforms to the principle of minimally invasive treatment of internal hemorrhoids with the main goal of eliminating or reducing hemorrhoids symptoms.^{20,29,30} As a new sclerosant in recent years, polidocanol has been proven to have good efficacy and safety in the treatment of Grade I to III hemorrhoids and hemorrhoid bleeding.^{7,9} Compared with other sclerosants, polidocanol foam has good curative effects and high safety, and its effective rate is up to 94.7%-98.0%,^{6,31} with a complication rate as low as 0.15%-1.50%.^{13,31} In addition, polidocanol also has a local anesthetic effect,¹⁴ which can alleviate pain during treatment and improve patient comfort and satisfaction.¹³ Therefore, polidocanol has long been recommended for the treatment of varicose veins in the European Guidelines for the Treatment of Chronic Venous Disease.³²

The 7 patients we treated were all elderly patients with grade II–III mixed hemorrhoids who had undergone long-term antithrombotic therapy. They had undergone a long conservative treatment process and had varying degrees of anemia due to repeated bleeding, resulting in poor surgical tolerance. Therefore, we learned from the advantages of polidocanol foam in hemostasis, anesthesia and safety and conducted IST for these patients without anesthesia or preoperative intestinal preparation. The patients were satisfied with the treatment effect, and all patients successfully stopped bleeding after one session of sclerotherapy. Four weeks after surgery, the patient's hemoglobin level significantly increased compared to before surgery. In terms of safety, the incidence of severe postoperative complications in this group was 0%. This is much lower than the 6.3% incidence of bleeding complications after hemorrhoidectomy in Nelson et al's antithrombotic treatment patients¹⁸ and is consistent with the study by Salgueiro et al in the literature review.²⁴ They reported that only one patient experienced serious postoperative complications (bleeding requiring blood transfusion) and demonstrated that the effects of polidocanol foam on hemorrhoids with and without bleeding diseases are equivalent. In terms of efficacy, the overall efficacy rate and satisfaction rate of our group of patients 4 weeks after surgery reached 100%, which is equivalent to the effective rate of 88.89%–94.52% reported in the literature review. This finding is similar to the results of a single-center prospective study by Fernandes et al, who analyzed the efficacy in 2000 hemorrhoid patients (including 210 who also received antithrombotic therapy) and reported that 98% of patients were satisfied with bleeding control and prolapse reduction at 4 weeks after surgery.⁶ In terms of the postoperative recurrence rate, we reported a recurrence rate of 0% at 4 weeks after surgery, and only 1 patient experienced recurrence at the 1-year follow-up. The overall recurrence rate was 14.29% (1/7), which is not only lower than the 16.67% recurrence rate reported by

Table 2 A Report of 7 Cases of Antithrombotic Therapy Combined with Mixed Hemorrhoid Bleeding Treated with Polidocanol Foam Injection Sclerotherapy

Patient	Age (Years)	Gender (M/F)	Goligher Grade	Reasons for Antithrombotic Therapy	Antithrombotic Drugs	TT(s)	PT(S)	INR	Preoperative Hb (g/L)	Operation Time (min)	Operative Bleeding (mL)	Hb 4 Weeks after Surgery (g/L)	Efficiency at 4 Weeks after Surgery (%)	Degree of Satisfaction (%)
1	86	M	III	Cerebral infarction	Aspirin	18.8	11.6	0.99	49	10	5	118	100	100
2	62	M	III	Cerebral infarction	Alteplase	17.4	12.3	1.03	56	30	0	83	100	100
3	86	F	III	Late stage chronic kidney disease, hemodialysis	Lmwh	17.8	11.7	1	95	10	0	105	100	100
4	86	F	III	Persistent atrial fibrillation	Dabigatran	143.9	15.3	1.31	52	20	0	91	100	100
5	98	F	III	Coronary Stent	Aspirin	15.8	11.5	0.97	92	30	0	136	100	100
6	68	M	II	Late stage chronic kidney disease, hemodialysis	Lmwh	15.7	12.4	1.05	86	20	0	106	100	100
7	75	M	III	Mitral valve replacement	Clopidogrel	17.1	11.2	0.93	66	18	20	103	100	100

Abbreviations: M, male; F, female; TT, thrombin time; PT, prothrombin time; INR, international normalized ratio; Hb, haemoglobin.

Table 3 A Literature Review of Researches of Polidocanol Foam Injection Sclerotherapy in Patients with Antithrombotic Therapy Combined with Mixed Hemorrhoid Bleeding

Researcher, Date	Subjects (N)	Age (Years)	Gender (M/F)	Goligher Grade	Sclerosant	Remission of Symptoms	Maintenance of Symptoms	Efficacy Rate	Severe Complication	Mild Complication	No Complication	Incidence of Severe Complications	Recurrence	Recurrence Rate
Current report	7	80.1 ±12.4	4M/3F	II to III	3% polydocanol foam	7	0	100.00%	0	0	7	0.00%	1	14.29%
Salgueiro et al (2022) ¹²	73	70.1 ± 12.0	42M/31F	I to III	3% polydocanol foam	69	4	94.52%	1	3	66	1.37%	13	17.81%
Santos et al (2019) ¹³	18	67.4 (51–82)	15M/3F	I to III	3% polydocanol foam	17	1	94.44%	1	2	15	5.56%	Not available	Not available
Figueiredo et al (2022) ¹⁴	45	Not available	Not available	I to III	2% polydocanol foam	40	5	88.89%	Not available	Not available	Not available	Not available	Not available	Not available

Abbreviation: M, male; F, female.

Cartell et al in a randomized controlled study of rubber band ligation for mixed hemorrhoids but also lower than the 17.81% recurrence rate reported by Salgueiro et al in a literature review.²⁴

Although our research suggests that IST is a relatively safe and effective option for patients with mixed hemorrhoid bleeding who are receiving antithrombotic therapy, it also has several limitations. First, this study is retrospective with a small sample size and a follow-up period of only four weeks, without a control group. Although we summarized and compared existing relevant research results through a literature review, the number of studies included in the literature review was relatively small, and the number of cases was not sufficient. All of these may affect the strength, reliability, and generalizability of the conclusions. Second, the outcome indicators such as efficacy and complications in this study mainly depend on the subjective feelings of patients, and there are no specific objective indicators or scale scores such as the number of hemorrhoids, the volume of foam, and the number of injection points for further evaluation. Additionally, owing to the small sample size, we did not analyze the differences in the efficacy of different antithrombotic drugs combined with hemorrhoid bleeding for sclerotherapy separately. Finally, although all the patients included in our study were treated with antithrombotic drugs, the preoperative coagulation function of these patients was basically normal, and the international normalized ratio (INR) was within the normal range. Thus, further clarification of the efficacy of polidocanol foam for patients with mixed hemorrhoid bleeding combined with abnormal coagulation function was impossible. Therefore, larger prospective randomized controlled trials are needed in the future to clarify these findings further.

Conclusion

Our research revealed that the use of polidocanol foam for IST is a relatively safe and effective method for patients receiving antithrombotic therapy combined with mixed hemorrhoid bleeding. However, larger prospective studies are needed before this is the preferred treatment for such patients.

Abbreviations

IST, Injection sclerotherapy; RBL, Rubber band ligation; INR, international normalized ratio.

Disclosure

The authors report no conflicts of interest in this work. This paper has been uploaded to ResearchSquare as a preprint: <https://www.researchsquare.com/article/rs-5025279/v1>.

References

- Pannach S, Goetze J, Marten S, Schreier T, Tittel L, Beyer-Westendorf J. Management and outcome of gastrointestinal bleeding in patients taking oral anticoagulants or antiplatelet drugs. *J Gastroenterol*. 2017;52(12):1211–1220. doi:10.1007/s00535-017-1320-7
- Brodie MM, Newman JC, Smith T, Rockey DC. Severity of gastrointestinal bleeding in patients treated with direct-acting oral anticoagulants. *Am J Med*. 2018;131(5):573.e9–573.e15. doi:10.1016/j.amjmed.2017.11.007
- Dean KR, Pavuluri H, Fox S, et al. The impact of antithrombotic medications on postoperative bleeding events following hemorrhoidectomy. *Am Surg*. 2023;89(11):4610–4615. doi:10.1177/00031348221124332
- Hawkins AT, Davis BR, Bhamra AR, et al. The American society of colon and rectal surgeons clinical practice guidelines for the management of hemorrhoids. *Dis Colon Rectum*. 2024;67(5):614–623. doi:10.1097/DCR.0000000000003276
- Abe T, Kunimoto M, Hachiro Y, Ohara K, Inagaki M. Long-term outcomes of aluminum potassium sulfate and tannic acid sclerotherapy for prolapsed hemorrhoids: a single-center, observational study. *Dis Colon Rectum*. 2022;65(2):271–275. doi:10.1097/DCR.0000000000002284
- Fernandes V, Fonseca J. Polidocanol Foam injected at high doses with intravenous needle: the (Almost) perfect treatment of symptomatic internal hemorrhoids. *GE - Port J Gastroenterol*. 2019;26(3):169–175. doi:10.1159/000492202
- Anorectal Branch of Chinese Medical Doctor Association, Colorectal Surgery Group SS of CMA. [Chinese expert consensus on the treatment of hemorrhoids by injection(2023 edition)]. *Zhonghua Wei Chang Wai Ke Za Zhi = Chin J Gastrointest Surg*. 2023;26(12):1103–1111. doi:10.3760/ema.j.cn441530-20231012-00128.
- Gallo G, Picciariello A, Pietroletti R, et al. Sclerotherapy with 3% polidocanol foam to treat second-degree haemorrhoidal disease: three-year follow-up of a multicentre, single arm, IDEAL phase 2b trial. *Colorectal Dis*. 2023;25(3):386–395. doi:10.1111/codi.16380
- Gallo G, Pietroletti R, Novelli E, et al. A multicentre, open-label, single-arm Phase II trial of the efficacy and safety of sclerotherapy using 3% polidocanol foam to treat second-degree haemorrhoids (SCLEROFOAM). *Tech Coloproctol*. 2022;26(8):627–636. doi:10.1007/s10151-022-02609-w
- Salgueiro P, Garrido M, Santos RG, Pedroto I, Castro-Poças FM. Polidocanol foam sclerotherapy versus rubber band ligation in hemorrhoidal disease grades I/II/III: randomized trial. *Dis Colon Rectum*. 2022;65(7):e718–e727. doi:10.1097/DCR.0000000000002117
- Khan RN, Jindal V, Kapoor S, et al. Randomized clinical trial of symptom control after stapled anapexy or diathermy excision for haemorrhoid prolapse (*Br J Surg* 2010; 97: 167–176). *Br J Surg*. 2010;97(6):961. doi:10.1002/bjs.7144

12. De Schepper H, Coremans G, Denis MA, et al. Belgian consensus guideline on the management of hemorrhoidal disease. *Acta Gastro Enterol Belg.* 2021;84(1):101–120. doi:10.51821/84.1.497
13. Moser KH, Mosch C, Walgenbach M, et al. Efficacy and safety of sclerotherapy with polidocanol foam in comparison with fluid sclerosant in the treatment of first-grade haemorrhoidal disease: a randomised, controlled, single-blind, multicentre trial. *Int J Colorectal Dis.* 2013;28(10):1439–1447. doi:10.1007/s00384-013-1729-2
14. Eckmann DM. Polidocanol for endovenous microfoam sclerosant therapy. *Expert Opin Invest Drugs.* 2009;18(12):1919–1927. doi:10.1517/13543780903376163
15. Serebruany VL, Midei MG, Meilman H, Malinin AI, Lowry DR. Rebound platelet activation after termination of prasugrel and aspirin therapy due to confirmed non-compliance in patient enrolled in the JUMBO Trial: ANTIPLATELET THERAPY. *Int J Clin Pract.* 2008;60(7):863–866. doi:10.1111/j.1742-1241.2006.00999.x
16. Atallah S, Maharaja GK, Martin-Perez B, Burke JP, Albert MR, Larach SW. Transanal hemorrhoidal dearterialization (THD): a safe procedure for the anticoagulated patient? *Tech Coloproctol.* 2016;20(7):461–466. doi:10.1007/s10151-016-1481-z
17. Gogarten W, Vandermeulen E, Van Aken H, Kozek S, Llau JV, Samama CM. Regional anaesthesia and antithrombotic agents: recommendations of the European Society of Anaesthesiology. *Eur J Anaesthesiol.* 2010;27(12):999–1015. doi:10.1097/EJA.0b013e32833f6f6f
18. Nelson RS, Ewing BM, Ternent C, Shashidharan M, Blatchford GJ, Thorson AG. Risk of late bleeding following hemorrhoidal banding in patients on antithrombotic prophylaxis. *Am J Surg.* 2008;196(6):994–999. doi:10.1016/j.amjsurg.2008.07.036
19. Albuquerque A. Rubber band ligation of hemorrhoids: a guide for complications. *World J Gastrointest Surg.* 2016;8(9):614. doi:10.4240/wjgs.v8.i9.614
20. Van Tol RR, Kleijnen J, Watson AJM, et al. European Society of ColoProctology: guideline for haemorrhoidal disease. *Colorectal Dis.* 2020;22(6):650–662. doi:10.1111/codi.14975
21. Gallo G, Martellucci J, Sturiale A, et al. Consensus statement of the Italian society of colorectal surgery (SICCR): management and treatment of hemorrhoidal disease. *Tech Coloproctol.* 2020;24(2):145–164. doi:10.1007/s10151-020-02149-1
22. Yamana T. Japanese practice guidelines for anal disorders I. hemorrhoids. *J Anus Rectum Colon.* 2017;1(3):89–99. doi:10.23922/jarc.2017-018
23. Agarwal N, Singh K, Sheikh P, Mittal K, Mathai V, Kumar A. Executive summary - the association of colon & rectal surgeons of India (ACRSI) practice guidelines for the management of haemorrhoids—2016. *Indian J Surg.* 2017;79(1):58–61. doi:10.1007/s12262-016-1578-7
24. Salgueiro P, Rei A, Garrido M, et al. Polidocanol foam sclerotherapy in the treatment of hemorrhoidal disease in patients with bleeding disorders: a multicenter, prospective, cohort study. *Tech Coloproctol.* 2022;26(8):615–625. doi:10.1007/s10151-022-02600-5
25. Batra P, O'Connor A, Walmsley J, Baraza W, Sharma A. Injection sclerotherapy for the treatment of haemorrhoids in anticoagulated patients. *Ann R Coll Surg Engl.* 2024;rcsann.2023.0097. doi:10.1308/rcsann.2023.0097
26. Lohsiriwat V. Treatment of hemorrhoids: a coloproctologist's view. *World J Gastroenterol.* 2015;21(31):9245. doi:10.3748/wjg.v21.i31.9245
27. Rosa B. Polidocanol foam: a breath of fresh air for the treatment of internal hemorrhoids. *GE - Port J Gastroenterol.* 2019;26(3):153–154. doi:10.1159/000493440
28. Ganz RA. The evaluation and treatment of hemorrhoids: a guide for the gastroenterologist. *Clin Gastroenterol Hepatol.* 2013;11(6):593–603. doi:10.1016/j.cgh.2012.12.020
29. Internal Hemorrhoids Cooperative Group of Chinese Society of Digestive Endoscopy. Chinese digestive endoscopic practice guidelines and operation consensus for internal hemorrhoids(2021). *Chin J Dig Endosc.* 2021;38(9):676–687.
30. Muldoon R. Review of American society of colon and rectal surgeons clinical practice guidelines for the management of hemorrhoids. *JAMA Surg.* 2020;155(8):773. doi:10.1001/jamasurg.2020.0788
31. Pondicherry I, Mishra S, Sahoo AK, et al. Department of Surgery, Jawaharlal Institute of Postgraduate Medical Education and Research. Polidocanol versus phenol in oil injection sclerotherapy in treatment of internal hemorrhoids: a randomized controlled trial. *Turk J Gastroenterol.* 2020;31(5):378–383. doi:10.5152/tjg.2020.19276.
32. Rabe E, Breu F, Cavezzi A, et al. European guidelines for sclerotherapy in chronic venous disorders. *Phlebology.* 2014;29(6):338–354. doi:10.1177/0268355513483280

Patient Preference and Adherence

Publish your work in this journal

Patient Preference and Adherence is an international, peer-reviewed, open access journal that focusing on the growing importance of patient preference and adherence throughout the therapeutic continuum. Patient satisfaction, acceptability, quality of life, compliance, persistence and their role in developing new therapeutic modalities and compounds to optimize clinical outcomes for existing disease states are major areas of interest for the journal. This journal has been accepted for indexing on PubMed Central. The manuscript management system is completely online and includes a very quick and fair peer-review system, which is all easy to use. Visit <http://www.dovepress.com/testimonials.php> to read real quotes from published authors.

Submit your manuscript here: <https://www.dovepress.com/patient-preference-and-adherence-journal>

Dovepress
Taylor & Francis Group