

# An update on purple urine bag syndrome

Yoshiro Hadano<sup>1</sup>  
Taro Shimizu<sup>2</sup>  
Shimon Takada<sup>3</sup>  
Toshiya Inoue<sup>4</sup>  
Sumire Sorano<sup>5</sup>

<sup>1</sup>Department of General Internal Medicine and Infectious Diseases, Rakuwakai Otowa Hospital, Yamashina-ku, Kyoto, Japan; <sup>2</sup>Rollins School of Public Health, Emory University, Atlanta, GA, USA;

<sup>3</sup>Department of General Internal Medicine, Osaka City General Hospital, Miyakojima-ku, Osaka, Japan;

<sup>4</sup>Department of Emergency Medicine, Urasoe General Hospital, Urasoe-city, Okinawa, Japan; <sup>5</sup>Kobe University School of Medicine, Kusunokicho, Chuoku, Kobe, Japan

**Abstract:** Purple urine bag syndrome is characterized by the urinary drainage bag turning purple in patients on prolonged urinary catheterization, especially those in the bedridden state. It is associated with bacterial urinary tract infections caused by indigo-producing and indirubin-producing bacteria, usually affects women, and is associated with alkaline urine, constipation, and a high bacterial load in the urine. Almost all patients with purple urine bag syndrome are catheterized due to significant disability, and the urinary pH is 7.0 or more. In general, intensive treatment with antibiotics is not recommended. Purple urine bag syndrome per se almost always appears to be asymptomatic and harmless. However, caution is needed, because some cases have been reported to show progression to severe disease states, so further research into the morbidity and mortality of this infection is warranted.

**Keywords:** purple urine, urinary catheterization, geriatrics, urinary tract infection

## Introduction

Purple urine bag syndrome (PUBS) refers to purple discoloration of the urinary drainage bag occurring in patients on long-term urinary catheterization (Figure 1).<sup>1</sup> It is associated with urinary tract infection caused by bacteria that produce sulfatase or phosphatase. The purple color is due to the compounds indigo and indirubin, which are metabolic degradation products of tryptophan released at multiple stages by bacterial enzymes in the intestine and urine. Female gender, constipation, urinary tract infection, dementia, alkaline urine, and high urinary bacterial counts are associated with PUBS.<sup>2-7</sup> PUBS can be associated with significant morbidity and mortality, but PUBS itself is a benign condition. Treatment should be aimed at the underlying medical problem rather than at PUBS itself. Here we present a concise review of the epidemiology, symptomatology, laboratory findings, treatment, and prognosis of PUBS.

## Epidemiology

PUBS was first reported in 1978.<sup>1</sup> It is seen in patients on chronic catheterization with urinary tract infection, and was thought to be rare. However, some reports suggest a prevalence of 8.3%–16.7% in patients with long-term urinary catheterization.<sup>2-4</sup> In one study, 27% of elderly patients with dementia in a geriatric hospital who required urinary catheterization developed PUBS.<sup>8</sup> Thus, PUBS seems to be associated with dementia and is not considered so rare by geriatric physicians.<sup>9</sup> Associated factors include female gender, alkaline urine, and constipation.<sup>2-7</sup> Numerous studies have indicated a predominance of PUBS in women as compared with men.<sup>4,7</sup> One explanation

Correspondence: Yoshiro Hadano  
2 Otowachinji-cho, Yamashina-ku, Kyoto  
607-8062, Japan  
Tel +817 5593 4111  
Fax +817 5581 6935  
Email hatayoshiyoshi@gmail.com



**Figure 1** Purple discoloration of urine in the urine bag and tubing.

is that the female urethra is more prone to bacterial infections due to its short length and proximity to the anus.<sup>4</sup> Chronic constipation and intestinal obstruction are reported to be strongly associated with PUBS,<sup>2</sup> which is supported by the fact that a decrease in intestinal motility causes bacterial overgrowth in the intestine, which increases the metabolism of tryptophan to indole, resulting in high levels of indigo and indirubin in the urine.<sup>9</sup> Some studies have reported an association between self-oral intake, chronic kidney disease, and PUBS.<sup>4,11</sup> A case control study reported that bacterial counts in urine were significantly higher (by 1 to 2 logs) in patients with PUBS than in those without the syndrome. This suggests that a higher bacterial load in the urine is an important factor involved in development of PUBS, in addition to the aforementioned factors.<sup>7</sup>

## Symptomatology

Almost all PUBS patients are catheterized due to significant disability, and are chair-bound or bed-bound.<sup>2</sup> Discoloration of the urine bag appears after about 2–3 months of catheterization, and will be shown after more than 1 year.<sup>4,7</sup> Constipation and use of laxative suppositories are frequently

reported among patients with PUBS.<sup>2</sup> The proportion of patients with constipation is higher among patients with PUBS than among those without the syndrome, although the difference is not consistently statistically significant.<sup>2,4</sup> Purple discoloration is observed not only in the urine bag, but also in the indwelling catheter; on the other hand, the urine itself often does not turn markedly purple.<sup>2,4</sup> Dehydration, advanced chronic kidney disease, and azotemia are reported to be risk factors for the development of PUBS.<sup>11,12</sup>

## Laboratory findings

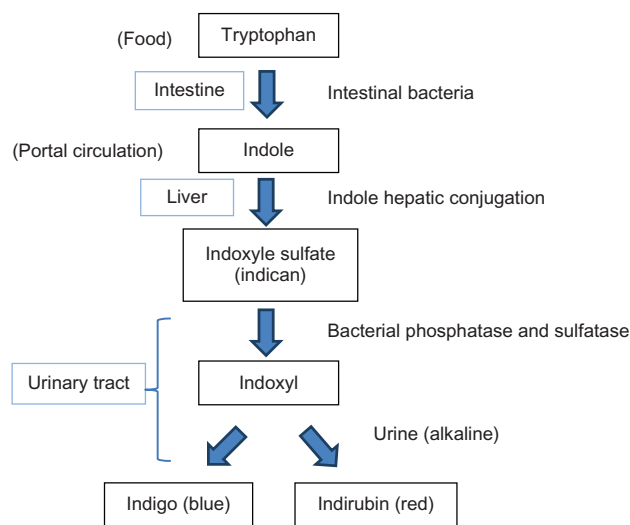
In almost all reports of PUBS, the urinary pH of the patients is reported to be  $\geq 7.0$ , and is reported to be higher in patients with PUBS than in those without the syndrome.<sup>7,12</sup> Although the alkaline state of the urine is thought to be responsible for the formation of indigo and indirubin, with a purple-colored appearance, some cases of PUBS without alkaline urine have also been reported.<sup>5,12</sup> Hence, alkaline urine may be one of the facilitating factors for diagnosis of PUBS. Leukocyte and bacterial counts in the urine of patients with PUBS are not always higher than the counts in the urine of patients without PUBS.<sup>7</sup> The common bacterial strains cultured from the urine bag are shown in Table 1.<sup>2,7,13</sup> The purple pigment in the urine is thought to originate from indican and indirubin (Figure 2), but there are some reports of cases of PUBS without any evidence of indicanuria.<sup>2,5</sup> The pathogenesis of purple PUBS is due to metabolism of tryptophan by intestinal bacteria such as *Proteus mirabilis* to indole and conversion to indoxyl sulfate in the liver. Indole sulfate is then catalyzed by bacterial phosphatases or sulfatases to indoxyl. In urine, indoxyl is converted into two pigments, indigo and indirubin. These two pigments create a purple color because indigo is blue and indirubin is red.

## Treatment

PUBS is benign, harmless, and asymptomatic in almost all cases. Its morbid significance remains unclear, and the

**Table 1** Bacterial strains associated with purple urine bag syndrome

<i>Citrobacter</i> species, including <i>C. freundii</i> , <i>C. diversus</i> , <i>C. koseri</i>
<i>Enterobacter</i> species, including <i>E. aerogenes</i> , <i>E. agglomerans</i> , <i>E. cloacae</i>
<i>Enterococcus</i> species, including <i>E. avium</i> , <i>E. faecalis</i>
<i>Escherichia coli</i>
<i>Klebsiella pneumoniae</i>
<i>Morganella morganii</i>
<i>Proteus</i> species, including <i>P. mirabilis</i> , <i>P. vulgaris</i>
<i>Providencia</i> species, including <i>P. rettgeri</i> , <i>P. stuartii</i>
Methicillin-resistant <i>Staphylococcus aureus</i>



**Figure 2** Pathogenesis of purple urine bag syndrome.

available evidence is insufficient to discuss the need or otherwise for treatment of PUBS. Improving urological sanitation and control of constipation by appropriate nutritional management are essential for the prevention of PUBS, while treatment of underlying urinary tract infection with an antibiotic, such as ciprofloxacin, is sometimes helpful.<sup>14</sup> Improving the care of urinary catheters may be expected to prevent both PUBS and catheter-associated urinary tract infection.<sup>3</sup> Drainage bags and long-term indwelling catheters may need to be changed on a more regular basis in catheterized patients to prevent discoloration of the contents of the urine bag or worsening odor.<sup>2</sup> While PUBS is widely believed to be benign and not to warrant treatment, two cases of PUBS in immunocompromised patients showed progression to Fournier's gangrene.<sup>15</sup> Hence, more attention may be needed in patients with PUBS, especially those who are immunocompromised.

## Prognosis

PUBS is a benign condition with no impact on prognosis other than the possibility of urinary tract infection. Long-term catheterization with indwelling catheters is one of the causes of PUBS, so this should be avoided unless absolutely necessary. Even though purple urine bag syndrome is almost certainly benign, it poses a burden to family members, health care workers, and nurses who are unaware of the phenomenon, so become alarmed by the sudden inexplicable discoloration of the urine, urine bag, and urinary catheter.<sup>16</sup> It is important to inform them that PUBS is benign and can be prevented by improved urological sanitation.

## Conclusion

PUBS is a relatively rare clinical phenomenon but is not uncommon for geriatric physicians, with female gender, dementia, alkaline urine, constipation, chronic catheterization with indwelling catheters, high bacterial loads in the urine, and chronic kidney disease serving as risk factors for its development. The pigments associated with PUBS are produced by indigo-producing and indirubin-producing bacteria in most cases. Although PUBS is usually harmless and does not require treatment, it is important to consider in the prevention of catheter-associated urinary tract infection by removing an unnecessarily inserted urinary catheter. Moreover, it is especially important to note that PUBS in immunocompromised patients may represent the first sign of severe disease, such as Fournier's gangrene. Further research is warranted on indications for treatment, as well as the morbidity and mortality implications of PUBS.

## Disclosure

The authors report no conflicts of interest in this work.

## References

- Barlow GB, Dickson JAS. Purple urine bags. *Lancet*. 1978;311:220–221.
- Su FH, Chung SY, Chen MH, et al. Case analysis of purple urine-bag syndrome at a long-term care service in a community hospital. *Chang Gung Med J*. 2005;28:636–642.
- Dealler SF, Belfield PW, Bedford M, Whitley AJ, Mulley GP. Purple urine bags. *J Urol*. 2005;142:769–770.
- Shiao CC, Weng CY, Chuang JC, Huang MS, Chen ZY. Purple urine bag syndrome: a community-based study and literature review. *Nephrology (Carlton)*. 2008;13:554–559.
- Muneoka K, Igawa M, Kurihara N, et al. Biochemical and bacteriological investigation of six cases of purple urine bag syndrome (PUBS) in a geriatric ward for dementia. *Nihon Ronen Igakkai Zasshi*. 2008;45:511–519. Japanese.
- Tsumura H, Satoh T, Kurosaka S, Fujita T, Matsumoto K, Baba S. Clinical characteristics in patients with purple urine bag syndrome. *Hinyokika Kyo*. 2008;54:185–188. Japanese.
- Mantani N, Ochiai H, Imanishi N, Kogure T, Terasawa K, Tamura J. A case-control study of purple urine bag syndrome in geriatric wards. *J Infect Chemother*. 2003;9:53–57.
- Ga H, Park KH, Choi GD, et al. Purple urine bag syndrome in geriatric wards: two faces of a coin? *J Am Geriatr Soc*. 2007;55:1676–1678.
- Ga H, Kojima T. Purple urine bag syndrome. *JAMA*. 2012;307:1912–1913.
- Nakayama T, Kanmatsuse K. Serum levels of amino acid in patients with purple urine bag syndrome. *Nihon Jinzo Gakkai Shi*. 1997;39:470–473. Japanese.
- Yang CJ, Lu PL, Chen TC, et al. Chronic kidney disease is a potential risk factor for the development of purple urine bag syndrome. *J Am Geriatr Soc*. 2009;57:1937–1938.
- Chung SD, Liao CH, Sun HD. Purple urine bag syndrome with acidic urine. *Int J Infect Dis*. 2008;12:526–527.
- Siu G, Watanabe T. Purple urine bag syndrome in rehabilitation. *PM R*. 2010;2:303–306.

14. Lin CH, Huang HT, Chien CC, Tzeng DS, Lung FW. Purple urine bag syndrome in nursing homes: ten elderly case reports and a literature review. *Clin Interv Aging*. 2008;3:729–734.
15. Tasi YM, Huang MS, Yang CJ, Yeh SM, Liu CC. Purple urine bag syndrome, not always a benign process. *Am J Emerg Med*. 2009;27:895–897.
16. Khan F, Chaudhry MA, Qureshi N, Cowley B. Purple urine bag syndrome: an alarming hue? A brief review of the literature. *Int J Nephrol*. 2011;2011:419213.

### International Journal of General Medicine

Dovepress

### Publish your work in this journal

The International Journal of General Medicine is an international, peer-reviewed open-access journal that focuses on general and internal medicine, pathogenesis, epidemiology, diagnosis, monitoring and treatment protocols. The journal is characterized by the rapid reporting of reviews, original research and clinical studies across all disease areas.

A key focus is the elucidation of disease processes and management protocols resulting in improved outcomes for the patient. The manuscript management system is completely online and includes a very quick and fair peer-review system. Visit <http://www.dovepress.com/testimonials.php> to read real quotes from published authors.

Submit your manuscript here: <http://www.dovepress.com/international-journal-of-general-medicine-journal>