

Retinopathy associated with interferon therapy in patients with hepatitis C virus

Mahmoud Abd El-Badie
Mohamed¹
Khaled Abd-El azeem Eed²

¹Ophthalmology Department, Faculty of Medicine, Al-Azhar University, Assiut, Egypt; ²Gastroenterology and Hepatology Department, Faculty of Medicine, Al-Azhar University, Assiut, Egypt

Purpose: To evaluate retinopathy associated with interferon therapy in patients with chronic hepatitis C.

Methods: One hundred patients with chronic hepatitis C undergoing interferon therapy were examined for the presence of cotton wool spots, retinal hemorrhages, cystoid macular edema, capillary non-perfusion, and arteriolar occlusion. Complete ophthalmological examination including indirect ophthalmoscopic fundus examination was carried out for all patients and colored fundus photography and fluorescein angiography were carried out for the patients with positive fundus findings. The follow-up period was 9 months.

Results: Sixteen percent of patients developed retinopathy in the form of cotton wool spots, retinal hemorrhages, cystoid macular edema, and capillary non-perfusion.

Conclusion: Interferon therapy can lead to retinopathy which is mostly reversible and dose related. Periodic fundoscopic examinations help in early detection and prevent progression to permanent visual loss.

Keywords: retinopathy, interferon, hepatitis C, complications

Introduction

An estimated 170 million people worldwide have hepatitis C virus (HCV) infection and over 20,000 new cases emerge every year. HCV infection frequently persists and may cause cirrhosis and hepatocellular carcinoma. In the US and most developed nations, where the prevalence of infection is 1%–2%, HCV is the leading cause of chronic liver disease.¹

HCV infection is a serious public health problem in Egypt, and is the country with the highest HCV prevalence, where 10%–20% of the general population is infected.²

Interferons are a group of glycoproteins that modulate the activity of the immune system. Recombinant alpha-interferon (IFN) has recently been approved as a therapy for chronic hepatitis C, for its antiviral effects and inhibition of cell proliferation.³

Although interferon-based therapy is widely used for the treatment of chronic HCV, it is not without its disadvantages. Treatment duration lasts for months, and is often fraught with potentially dangerous side effects. Some of these side effects, such as influenza-like illness, myalgias, depression, and cytopenias can be intolerable resulting in premature treatment cessation, but have no lasting effects. Ocular complications are among the complications of interferon therapy and include retinal hemorrhages, cotton wool spots, loss of color vision, cataracts, glaucoma, and occasionally retinal

Correspondence: Mahmoud Abd El-Badie Mohamed
Ophthalmic Department Al-Azhar University Hospital, Assuit, Egypt
Email badie_eye@yahoo.com

artery or vein obstruction. Although the incidence of ophthalmological disorders while on interferon therapy is low, this can result in loss of vision.⁴⁻¹¹

Patients and methods

In this prospective case series study, One hundred patients with chronic hepatitis-C under Interferon (INF) therapy were consecutively recruited from patients attending the outpatient ophthalmic clinic at the University Hospital, Faculty of Medicine, Al-Azhar University, Assuit. The research followed the tenets of declaration of Helsinki. The study protocol was approved by the Ethics Committee at Al-Azhar University Hospital. Written informed consent was obtained from all patients included in the study, and then in addition to the medical and laboratory examination, all patients were subjected to full ophthalmological assessment to evaluate the retinopathy associated interferon therapy.

Inclusion criteria were: (1) seropositivity for anti-HCV antibodies determined using ELISA; (2) first use of interferon therapy.

Exclusion criteria were: (1) previous interferon therapy; (2) patients with hepatitis B; (3) patients with decompensated liver; (4) patients with renal failure; (5) patients with cardiovascular disorders such as coronary insufficiency, congestive heart failure, and ischemic stroke; (6) patients with a dense cataract, visual field abnormality, glaucoma, or any other ocular abnormalities.

Evaluation before treatment:

- A. History of visual loss, hazy vision, and ocular disease or ocular surgeries
- B. Ophthalmological examination: (1) best corrected visual acuity (BCVA) measured using Landolt's broken rings; (2) pupillary reaction (direct and consensual) and if there is afferent pupillary defect; (3) full slit-lamp examination; (4) intraocular pressure (IOP) measured by Goldmann's applanation tonometer; (5) fundus biomicroscopy (carried out after maximum pupillary dilation by a combination of tropicamide 1% eye drops and phenylephrine 2.5% eye drops using both slit-lamp biomicroscopy with non-contact +90 D Volk lens and/or Goldmann contact lens); (6) examination of the retinal periphery using an indirect ophthalmoscope.
- C. Medical examinations and abdominal ultrasonography.
- D. Investigations: (1) Ocular, both colored fundus photography and fundus fluorescein angiography (FFA); (2) Laboratory (including enzyme-linked immunosorbent assay (ELISA) test for hepatitis surface Ag and Ab; polymerase chain reaction (PCR) for hepatitis C virus RNA; Full blood count;

prothrombin time; direct and indirect bilirubin; fasting blood sugar; serum creatinine; liver enzymes (serum glutamic oxaloacetic transaminase and serum glutamic pyruvic transaminase); alanine aminotransferase.

Treatment protocol

Patients were treated with pegylated interferon α -2a at a dose of 180 mcg injected subcutaneously once weekly for 48 weeks. Ribavirin was given orally 800–1200 mg/day according to body weight.

Follow-up

All patients underwent clinical and laboratory assessments, ophthalmic examination, at 15 days, 1 month, 2 months, 3 months, 6 months, 8 months, and 9 months after the start of IFN treatment.

Results

Initially, 120 patients fulfilled the criteria for IFN therapy, but 20 of them were excluded due to non-compliance with the follow-up visits and due to the presence of diabetic or hypertensive retinopathy. Also, two patients died during the study time, due to a disease not related to hepatitis, so these patients are not included.

Therefore, a total of 100 patients (68 male and 32 female), with chronic HCV were selected. The mean age was 46 years.

After the start of interferon therapy, 16 out of 100 patients (16%) developed retinopathy which was bilateral in 12 (75%) patients and unilateral in 4 (25%) patients.

Retinopathy was initially diagnosed by the appearance of a cotton wool spot in 14 patients. In four of the 14 patients, retinal hemorrhage was also observed simultaneously or sequentially. Two of the 16 patients who developed retinopathy were diagnosed by retinal hemorrhage without cotton wool spots. One patient (not diabetic or hypertensive) had

Table 1 Clinical data

Clinical data	No	%
Age	46 (mean)	–
Sex (M/F)	68/32	68/32
Hypertension	16	16
Diabetes	13	13
Retinopathy	16	16
Laterality (bilateral/unilateral)	12/4	75/25
Hemorrhage	10	10
Cotton wool spots	14	14
Cystoid macular edema	1	1

Table 2 Laboratory data

Laboratory data	Baseline		At the end of follow-up	
	Mean	SD	Mean	SD
Full blood count				
Red blood cells ($10^6/\mu\text{L}$)	4.6	0.6	4.1	0.5
White blood cells ($10^3/\mu\text{L}$)	4.7	1.3	4.3	1.5
Platelets	164.6	54.1	159.2	55.3
Hemoglobin (g/dL)	13.7	1.8	13.1	1.6
Prothrombin time	90.6	12.8	88.5	12.3
Virus load (copies/mL)	616.3	324.5	96.6	221.2
Alanine transaminase (IU/L)	101.3	80.6	138	87

cystoid macular edema, this was the only patient who complained of the visual disturbance due to interferon.

All patients had BCVA of (6/6) during IFN treatment except for three patients: the one who had cystoid macular edema (BCVA was 6/12 and returned to 6/6 after cessation of treatment) and two patients with ametropic amblyopia.

No patient with diabetes had retinopathy before IFN treatment. In addition, we confirmed that all patients with hypertension had no retinopathy using the standard classification. To exclude the possibility of the development of diabetic or hypertension retinopathy after IFN treatment, we deleted the data obtained from patients who had diabetes or hypertension and any retinopathy 2 months after the cessation of IFN treatment.

Retinopathy was first diagnosed 2–14 weeks after the start of treatment and disappeared in 11 of the 16 patients despite the continuation of therapy. A few cotton wool spots, retinal hemorrhages, or both were observed in the remaining five patients at the end of treatment but resolved within 1 month after treatment was stopped. Retinopathy did not recur in any patient after the IFN-induced retinopathy resolved. No other ocular complications (ie, cataracts, glaucoma, retinal artery, or vein obstruction) were observed.

The mean hemoglobin values, white blood cell, red blood cell, and platelet counts decreased significantly ($P < 0.0001$) during IFN treatment.

The clinical profiles and laboratory data of the patients are shown in Tables 1 and 2, respectively.

Discussion

Interferon-associated retinopathy was first recognized in 1990 when Ikebe and associates reported a 39-year-old patient who developed retinal hemorrhages and cotton wool spots following intravenous administration of interferon.¹²

The underlying mechanisms of interferon-induced retinopathy are not completely understood. Guyer et al¹³ had proposed an immune complex deposition causing occlusion of retinal capillaries leading to cotton wool spot formation. On the other hand, an ischemic insult, similar to that seen in hypertensive and diabetic patients could be another potential mechanism by which these changes develop.¹⁴

Some studies^{15,16} have shown a relatively higher incidence of retinopathy (symptomatic or asymptomatic) ranging from 19% to 64% during treatment with interferon. Panetta and Gilani¹⁷ and Cuthbertson et al¹⁴ show relatively lower incidences of retinopathy (3.8% and 6.25%, respectively). The incidence of retinopathy in our study was 16%.

Similar to other studies,^{4,5,9} our study also shows that retinal changes usually develop within the first 3 months of interferon treatment, a fact that may favor an immune etiology rather than a cumulative effect of interferon leading to the development of retinopathy.

Retinopathy developed by week 14 in most of the patients (13/16, 81.25%) after the start of therapy and disappeared in the majority of the patients (11/16, 68.75%) during the 4–8 week period in which the patients were receiving the treatment. This suggests that treatment can be continued despite the development of retinopathy in many patients. However, two patients who developed cotton wool spots early in the therapy (2 weeks) thereafter suffered from retinal hemorrhage in a prolonged manner. Therefore, patients who develop cotton wool spots early on during therapy should be carefully monitored.

However, as reported in previous studies,^{4,13,14} most of the patients with retinopathy in this study were asymptomatic. This study confirms previous reports that retinopathy is a temporary and asymptomatic complication of interferon therapy.

There is no classification for IFN-induced retinopathy, like diabetic retinopathy. Therefore there is no rule for

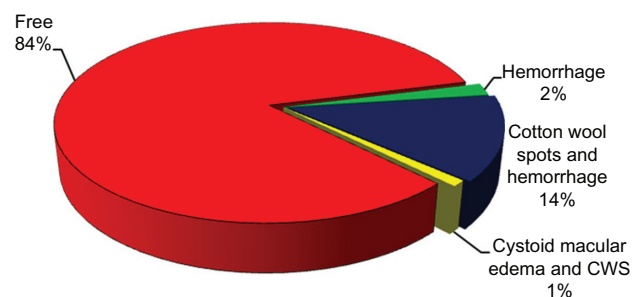


Figure 1 Pie graph represents the type and percentage of retinopathy in patients included in the study.

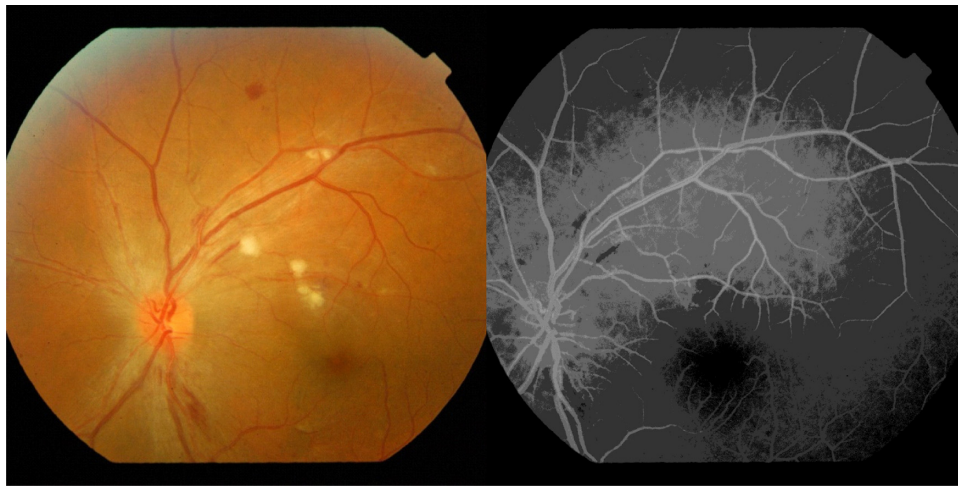

Figure 2 Cotton wool exudate and retinal hemorrhage after 12 weeks of treatment.

suspending the use of interferon in patients who develop retinopathy or any other ocular side effects. It's commonly agreed among authors that careful monitoring should be performed in the presence of any ocular sign, even without symptoms.¹⁸

Conclusion

Interferon therapy can lead to retinopathy which is almost reversible and dose related. Periodic fundoscopic examinations help in early detection and prevent progression to permanent visual loss.

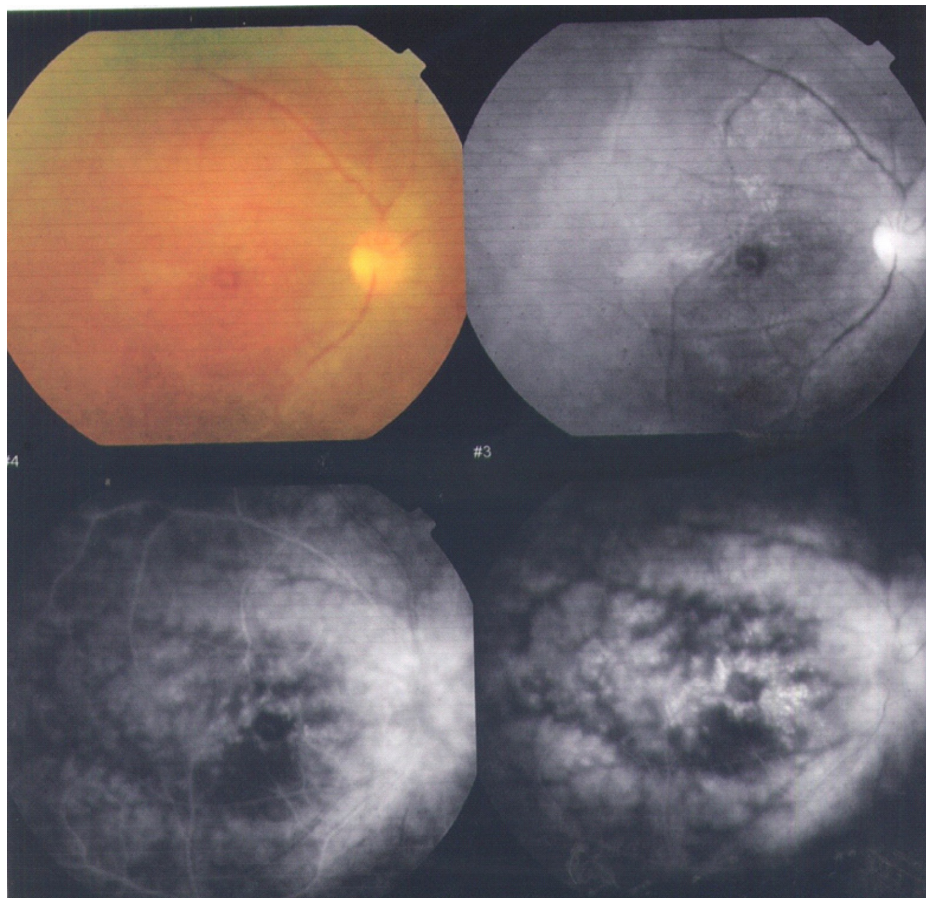


Figure 3 The only case with cystoid macular in the study.

Disclosure

The authors report no conflicts of interest in this work.

References

- World Health Organization. Hepatitis C. *Weekly Epidemiological Record*. 1997;72:65–69.
- Hassan MM, Zaghoul AS, El-Serag HB, et al. The role of hepatitis C in hepatocellular carcinoma: a case control study among Egyptian patients. *J Clin Gastroenterol*. 2001;33:123–126.
- Tokai R, Ikeda T, Miyaura T, Sato K. Interferon-associated retinopathy and cystoid macular edema. *Arch Ophthalmol*. 2001;119(7):1077–1079.
- Hayasaka S, Fujii M, Yamamoto Y, Noda S, Kurome H, Sasaki M. Retinopathy and subconjunctival haemorrhage in patients with chronic viral hepatitis receiving interferon alfa. *Br J Ophthalmol*. 1995;79:150–152.
- Kawano T, Shigehira M, Uto H, et al. Retinal complications during interferon therapy for chronic hepatitis C. *Am J Gastroenterol*. 1996;91:309–313.
- Kadayifcilar S, Boyacioglu S, Kart H, GURSOY M, Aydin P. Ocular complications with high-dose interferon alpha in chronic active hepatitis. *Eye (Lond)*. 1999;13:241–246.
- Saito H, Ebinuma H, Nagata H, et al. Interferon-associated retinopathy in a uniform regimen of natural interferon-alpha therapy for chronic hepatitis C. *Liver*. 2001;21:192–197.
- Nadir A, Amin A, Chalisa N, van Thiel DH. Retinal vein thrombosis associated with chronic hepatitis C: a case series and review of the literature. *J Viral Hepat*. 2000;7:466–470.
- Manesis EK, Moschos M, Brouzas D, et al. Neurovisual impairment: A frequent complication of alpha-interferon treatment in chronic viral hepatitis. *Hepatology*. 1998;27:1421–1427.
- Farel C, Suzman DL, McLaughlin M, et al. Serious ophthalmic pathology compromising vision in HCV/HIV co-infected patients treated with peginterferon alpha-2b and ribavirin. *AIDS*. 2004;18:1805–1809.
- Kwon YS, Choe YH, Chin HS. Development of glaucoma in the course of interferon alpha therapy for chronic hepatitis B. *Yonsei Med J*. 2001;42:134–136.
- Ikebe T, Nakatsuka K, Goto M. A case of retinopathy induced by intravenous administration of interferon. *Folia Ophthalmologica Japonica*. 1990;41:2291–2296.
- Guyer DR, Tiedeman J, Yannuzzi LA, et al. Interferon-associated retinopathy. *Arch Ophthalmol*. 1993;111:350–356.
- Cuthbertson FM, Davies M, McKibbin M. Is screening for interferon retinopathy in hepatitis C justified? *Br J Ophthalmol*. 2004;88:1518–1520.
- Okuse C, Yotsuyanagi H, Nagase Y, et al. Risk factors for retinopathy associated with interferon alpha-2b and ribavirin combination therapy in patients with chronic hepatitis C. *World J Gastroenterol*. 2006;12:3756–3759.
- Nagaoka T, Sato E, Takahashi A, Yokohama S, Yoshida A. Retinal circulatory changes associated with interferon-induced retinopathy in patients with hepatitis C. *Invest Ophthalmol Vis Sci*. 2007;48:368–375.
- Panetta JD, Gilani N. Interferon-induced retinopathy and its risk in patients with diabetes and hypertension undergoing treatment for chronic hepatitis C virus infection. *Aliment Pharmacol Ther*. 2009;30(6):597–602.
- Hayasaka S, Nagaki Y, Matsumoto M, Sato S. Interferon associated retinopathy. *Br J Ophthalmol*. 1998;82(3):323–325.

Clinical Ophthalmology

Publish your work in this journal

Clinical Ophthalmology is an international, peer-reviewed journal covering all subspecialties within ophthalmology. Key topics include: Optometry; Visual science; Pharmacology and drug therapy in eye diseases; Basic Sciences; Primary and Secondary eye care; Patient Safety and Quality of Care Improvements. This journal is indexed on

Submit your manuscript here: <http://www.dovepress.com/clinical-ophthalmology-journal>

Dovepress

PubMed Central and CAS, and is the official journal of The Society of Clinical Ophthalmology (SCO). The manuscript management system is completely online and includes a very quick and fair peer-review system, which is all easy to use. Visit <http://www.dovepress.com/testimonials.php> to read real quotes from published authors.