


Differential Diagnostic Value of Gastrointestinal Ultrasound Contrast Filling Method in Differentiating Gastric Tumors and Ulcers in the Elderly

Yuanyuan Sun^{1,*}, Yujie Deng^{2,*}, Lin Sang¹, Qian Zhang¹ ²

¹Department of Ultrasound Medicine, The First Affiliated Hospital of Air Force Military Medical University, Xi 'an, 710032, People's Republic of China;

²Department of Geriatrics, The First Affiliated Hospital of Air Force Military Medical University, Xi 'an, 710032, People's Republic of China

*These authors contributed equally to this work

Correspondence: Qian Zhang, Email zq6019dr@126.com, Lin Sang, Department of Ultrasound Medicine, The First Affiliated Hospital of Air Force Military Medical University, Xi 'an, 710032, People's Republic of China, Email dr_sang@126.com

Objective: To evaluate the differential diagnostic value of the gastrointestinal ultrasound contrast filling method in distinguishing gastric tumors from gastric ulcers in elderly patients.

Methods: We retrospectively analyzed 274 elderly patients diagnosed with gastric diseases between January 2022 and October 2024, confirmed by endoscopic pathology as gastric tumors (n=82) or gastric ulcers (n=192). All underwent gastrointestinal ultrasound contrast filling. Differences in conventional ultrasound features (internal echo, calcification, morphology, classification) and contrast-enhanced ultrasound parameters [enhancement intensity (EI), time to peak (TTP), area under curve (AUC), arrival time (AT)] were compared. Spearman correlation assessed parameter-tumor relationships. ROC curves evaluated diagnostic performance.

Results: The tumor group showed higher rates of low internal echo, calcification, irregular morphology, and type II classification than the ulcer group (P<0.05). EI, TTP, AUC, and AT were significantly elevated in tumors (P<0.05), correlating positively with tumor occurrence (r=0.524–0.597, P<0.05). ROC analysis yielded an AUC of 0.947, with sensitivity 96.72% and specificity 98.91%.

Conclusion: Gastrointestinal ultrasound contrast filling effectively demonstrates both conventional and enhancement features of gastric lesions in the elderly, providing high sensitivity and specificity for differentiating gastric tumors from gastric ulcers.

Keywords: gastrointestinal ultrasound contrast filling, elderly, gastric tumor, gastric ulcer, differential diagnosis

Introduction

Gastric diseases are increasingly prevalent among the elderly population. With advancing age, immune function declines, gastric mucosal defense weakens, and factors such as long-term irrational diet, chronic comorbidities, and medication stimulation make elderly individuals more susceptible to gastric lesions.^{1,2} Gastric tumors are among the most common malignant tumors of the digestive system worldwide,³ with gastric cancer ranking among the top malignancies in China.⁴ Gastric ulcers, although benign,⁵ can progress to ulcerative cancer if not effectively managed, representing a precancerous condition of gastric cancer.⁶ The molecular mechanisms underlying gastric tumors involve abnormal activation of oncogenes (eg, HER2, c-Met), tumor suppressor gene mutations (eg, TP53), and dysregulation of pathways such as Wnt/ β -catenin and PI3K/Akt.^{7,8} In contrast, benign gastric ulcers are primarily caused by *Helicobacter pylori* infection or NSAID-induced mucosal injury, with intact cellular regulatory mechanisms and no neoplastic infiltration.⁹ Understanding these pathological differences underscores the importance of accurate differentiation.

In clinical practice, gastric tumors and gastric ulcers often present with similar symptoms, such as upper abdominal pain, bloating, nausea, and weight loss, making clinical differentiation challenging.¹⁰ While gastroscopy offers high

diagnostic accuracy with direct visualization and biopsy, it remains invasive. Even though modern gastroscopy is generally safe, elderly patients—especially those with cardiovascular or cerebrovascular diseases—may face increased procedural risks, including arrhythmia, respiratory depression, or exacerbation of comorbidities.¹¹ Furthermore, patient frailty, psychological resistance, and intolerance to sedation limit its applicability in certain elderly populations.¹² Therefore, a safe, well-tolerated, non-invasive alternative remains clinically valuable.

Ultrasound is non-invasive, convenient, and repeatable, but conventional transabdominal ultrasound is limited by gas and food residues that obscure gastric wall visualization.¹³ The gastrointestinal ultrasound contrast filling technique, which uses oral contrast agents to expand the stomach and displace gas, improves imaging quality.¹⁴ When combined with intravenous contrast-enhanced ultrasound (CEUS), it enables dynamic assessment of lesion microcirculation, assisting in distinguishing benign from malignant lesions.¹⁵ However, CEUS also has limitations: image quality depends on operator skill, deep lesions may be less visible, and microbubble contrast agents have a short imaging window.¹⁶

Although preliminary studies have explored this method in gastric disease diagnosis, few have systematically evaluated its application in differentiating gastric tumors from ulcers specifically in the elderly. This study retrospectively analyzed 274 elderly patients, comparing lesion characteristics and CEUS parameters between tumor and ulcer groups under the gastrointestinal ultrasound contrast filling method. By integrating morphological and perfusion information, this research aims to provide a safe, efficient, and practical non-invasive diagnostic approach, representing a novel contribution to improving diagnostic accuracy for gastric diseases in the elderly.

Data and Methods

Study Subjects

This study is a retrospective analysis that included 274 elderly patients with gastric diseases who were treated in the Department of Gastroenterology and the Department of Ultrasound at our hospital between January 2022 and October 2024. All patients underwent gastrointestinal ultrasound contrast examination with gastric filling method and were diagnosed via gastroscopy and histopathological examination. Based on the final pathological diagnosis, patients were divided into a gastric tumor group (n=82) and a gastric ulcer group (n=192). Inclusion criteria: (1) Age \geq 65 years (considering physiological changes and disease prevalence, a stricter age threshold was applied to better represent the elderly population); (2) Clinical manifestations including epigastric discomfort, difficulty eating, weight loss, gastrointestinal bleeding, etc.; (3) Gastric lesions clearly identified via gastroscopy and pathologically confirmed as gastric tumors or gastric ulcers through biopsy; (4) Complete gastrointestinal ultrasound filling and contrast examination, with complete imaging data; (5) Informed consent signed by the study subjects and good compliance. Exclusion criteria: (1) Concomitant esophageal, duodenal, or other malignancies; (2) History of gastric surgery, chemotherapy, or radiotherapy; (3) Severe dysfunction of the heart, lungs, liver, or kidneys, or other systemic diseases that may affect image quality; (4) Unclear ultrasound images, incomplete data, or contraindications to contrast agents; (5) Adult patients under 60 years of age. This study has been approved by the Medical Ethics Committee of the First Affiliated Hospital of Air Force Medical University (Approval Number: YXK24-1126). The study was conducted in strict accordance with the ethical standards of the Declaration of Helsinki.

Instruments and Equipment

Gastroscopy equipment: This study used the Olympus GIF-H290 electronic gastroscopy system (Olympus Medical Systems, Japan), equipped with high-definition magnification endoscopy and capable of multi-mode image observation. Combined with techniques such as Narrow Band Imaging (NBI) and chromoendoscopy, it helps clarify the boundaries, surface morphology, and microvascular structure of gastric lesions. All procedures were performed by digestive endoscopists at the associate chief physician level or above, with extensive clinical experience. **Ultrasound equipment:** The GE LOGIQ E9 ultrasound diagnostic instrument was used, equipped with a contrast imaging module and a probe frequency of 3.5–5.0 MHz, with real-time contrast-enhanced ultrasound functionality. **Contrast agents:** Oral gastrointestinal ultrasound filling contrast agent: Zhi Zhuo An (Perfluorobutane Microbubbles for Injection, Approval No.: H20201000, GE Healthcare AS, USA); Intravenous contrast agent: SonoVue (Bracco, Italy), dissolved in 5 mL of

normal saline and gently shaken before use. Data collection and analysis software: QontraXt software was used for post-contrast image analysis and quantitative measurement of perfusion parameters.

Examination Methods

Gastroscopy Examination

(1) Preparation: Patients were required to fast for 6–8 hours before the examination to empty gastric contents. For patients who could not tolerate the procedure, topical anesthesia and sedation (eg, lidocaine throat spray, optional midazolam) were administered as appropriate. (2) Gastroscopy procedure: Patients were placed in the left lateral position. After routine disinfection of the throat, the gastroscope was inserted to observe the morphology of the mucosa in the esophagus, cardia, gastric body, angle, antrum, and pylorus. Particular attention was paid to signs of congestion, edema, erosion, ulceration, hyperplasia, or mass. Suspicious lesions were subjected to multi-point biopsy (at least 2–3 samples per lesion), sent for HE staining and immunohistochemistry to determine the pathological type. In the case of ulcerative lesions, the morphology, size, boundary clarity, base characteristics, and presence of bleeding were evaluated. For suspected malignant tumors, the depth of invasion, ulceration extent, and submucosal vascular proliferation were recorded in detail. After the examination, the patient's recovery was observed, and the specimen numbers and locations were documented. (3) Pathological diagnostic criteria: ① Gastric tumor diagnosis: Based on biopsy pathology results, including gastric adenocarcinoma, signet ring cell carcinoma, and undifferentiated carcinoma, classified according to the 5th edition of the WHO Classification of Tumours of the Digestive System;¹⁷ ② Gastric ulcer diagnosis: Defined as mucosal defect extending below the muscularis mucosa under microscopy, with surrounding inflammatory cell infiltration, necrotic tissue, and fibrinous exudate, excluding malignant cellular components.

Gastrointestinal Ultrasound Filling Method with Contrast

(1) Pre-examination preparation: Patients fasted and avoided water intake for 6–8 hours to empty gastric contents. (2) Examination procedure: Patients were placed in the left lateral or semi-supine position to fully expose the gastric body, antrum, and cardia to the ultrasound field. About 10 minutes before the examination, patients were instructed to slowly drink approximately 800–1000 mL of a gastric cavity contrast suspension to maintain gastric expansion and minimize bubble interference. An initial scan was performed to assess gastric wall structure, cavity morphology, lesion size, internal echo, boundary features, calcification, and ultrasound typing. Once the lesion site was determined, 2.4 mL of SonoVue contrast agent was injected via the cubital vein, followed by a rapid flush of 5 mL normal saline. The enhancement process of the lesion area was recorded in real time. (3) Image analysis and parameter measurement: The most enhanced plane of the lesion in the contrast image was selected, and the Region of Interest (ROI) was drawn using QontraXt software. A time-intensity perfusion curve was automatically generated, and the following parameters were extracted: ① Arrival Time (AT): The time when the contrast agent first reaches the lesion; ② Time to Peak (TTP): The time required for the contrast to reach maximum intensity; ③ Enhancement Intensity (EI): The difference between the maximum gray scale value and the baseline; ④ Area Under the Curve (AUC): Reflects the total blood perfusion of the lesion. To minimize bias in image interpretation, all ultrasound examinations were performed by physicians who were blinded to patients' endoscopic images and pathological diagnoses. Additionally, to reduce inter-operator variability, only senior physicians with more than 10 years of gastrointestinal ultrasound experience participated in the imaging acquisition and analysis. All data interpretation was performed independently by two blinded senior ultrasound physicians. If discrepancies occurred, a third blinded expert reviewed the case to reach a consensus. This approach aimed to further mitigate potential operator-related bias and enhance the reproducibility of the results.

Statistical Methods

All data were statistically analyzed using SPSS 26.0 software. Measurement data were expressed as ($\bar{x} \pm s$), and comparisons between groups were conducted using independent sample *t*-tests. Categorical data were expressed as frequency and percentage, and comparisons between groups were made using the χ^2 -test. Spearman correlation

coefficients were used for correlation analysis. ROC curves were plotted to calculate the AUC, sensitivity, specificity, and their 95% confidence intervals. A p-value < 0.05 was considered statistically significant.

Results

Comparison of Baseline Data

There were no statistically significant differences between the two groups in terms of gender, age, body mass index (BMI), main symptoms, comorbidities, or education level ($P > 0.05$), indicating comparability. See [Table 1](#).

Comparison of Conventional Ultrasound Lesion Characteristics

The proportions of internal hypoechoic areas, calcification, irregular morphology, and type II ultrasound classification were significantly higher in the gastric tumor group than in the gastric ulcer group ($P < 0.05$). See [Table 2](#).

Comparison of Contrast-Enhanced Ultrasound Parameters

The levels of EI, TTP, AUC, and AT in the gastric tumor group were (20.41±2.38, 26.23±2.57, 1879.12±165.23, 7.84±1.12), respectively; in the gastric ulcer group, these levels were (15.76±1.12, 22.04±1.46, 1653.97±201.85, 5.63±0.88), respectively. The gastric tumor group had significantly higher levels of EI, TTP, AUC, and AT compared to the gastric ulcer group ($P < 0.05$). See [Figure 1](#).

Correlation Between Contrast-Enhanced Ultrasound Parameters and Occurrence of Gastric Tumors

Spearman correlation analysis showed that levels of EI, TTP, AUC, and AT were positively correlated with the occurrence of gastric tumors (non-occurrence = 1, occurrence = 2) ($P < 0.05$). See [Table 3](#) and [Figure 2](#).

Table 1 Comparison of Baseline Data ($\bar{x} \pm s$, n [%])

	GT Group (n=82)	GU Group (n=192)	t/ χ^2	P
Gender	–	–	0.282	0.595
Male	46 (56.10)	101 (52.60)	–	–
Female	36 (43.90)	91 (47.40)	–	–
Age (years)	68.74±5.11	67.83±4.95	1.380	0.168
BMI (kg/m ²)	22.98±2.53	23.19±2.46	0.641	0.521
Comorbidities	–	–	–	–
Diabetes	21 (25.61)	47 (51.09)	0.039	0.842
Hypertension	26 (31.71)	60 (31.25)	0.005	0.940
Coronary heart disease	18 (21.95)	40 (20.83)	0.043	0.835
Education level	–	–	0.128	0.719
Primary school and below	55 (67.07)	133 (69.27)	–	–
Middle school and above	27 (32.93)	59 (30.73)	–	–

Abbreviations: GT, Gastric Tumor; GU, Gastric Ulcer.

Table 2 Comparison of Conventional Ultrasound Lesion Characteristics [n (%)]

	GT Group (n=82)	GU Group (n=192)	χ^2	P
Internal hypoechoic area	31 (37.80)	17 (8.85)	33.329	<0.001
Calcification	39 (47.56)	10 (5.21)	70.185	<0.001
Irregular morphology	51 (62.20)	41 (21.35)	42.973	<0.001
Ultrasound classification	–	–	79.033	<0.001
Type I	20 (24.39)	155 (80.73)	–	–
Type II	62 (75.61)	37 (19.27)	–	–

Abbreviations: GT, Gastric Tumor; GU, Gastric Ulcer.

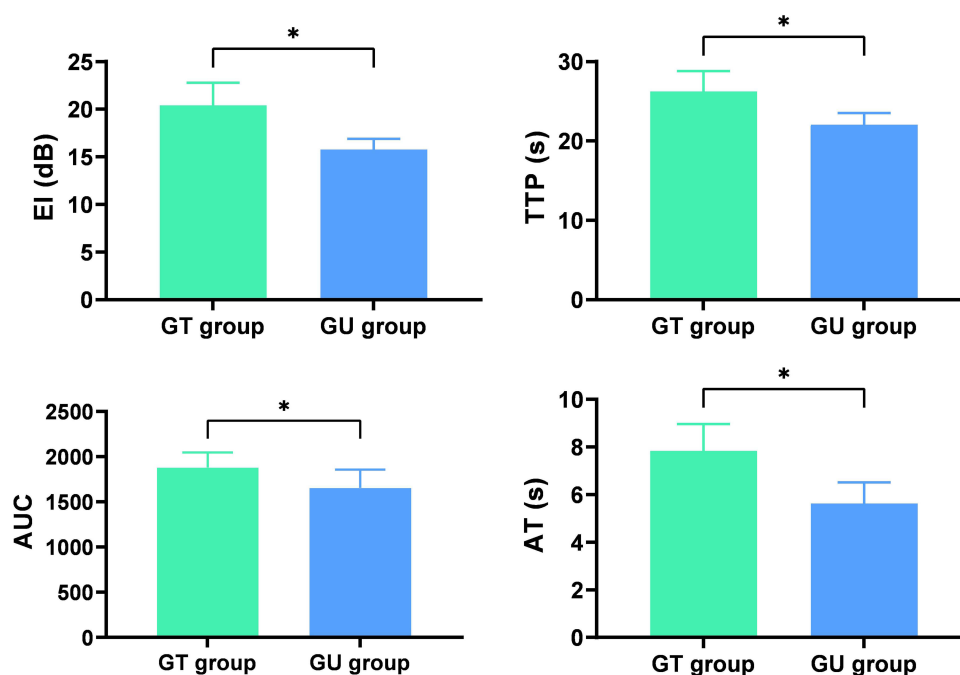


Figure 1 Comparison of Contrast-Enhanced Ultrasound Parameters ($\bar{x} \pm s$).

Note: * $P < 0.05$.

Abbreviations: GT, Gastric Tumor; GU, Gastric Ulcer; comparison between groups.

Diagnostic Value of Gastrointestinal Ultrasound Filling Contrast for Differentiating Gastric Tumors and Ulcers in the Elderly

ROC curve analysis showed that gastrointestinal ultrasound filling contrast had an AUC of 0.947 for differentiating gastric tumors from ulcers in the elderly, with a sensitivity of 96.72% and specificity of 98.91%. The optimal cutoff values for each quantitative parameter (EI, TTP, AUC, AT) were determined using the Youden index, calculated as sensitivity + specificity – 1, based on the ROC curve analysis. See [Figure 3](#).

Discussion

Gastric diseases are highly prevalent among the elderly population, with gastric tumors and gastric ulcers being the two major categories. Their clinical symptoms, such as epigastric pain, bloating, and indigestion, are often nonspecific, making misdiagnosis and missed diagnosis common occurrences.^{18,19} Since elderly patients often suffer from underlying conditions or have poor physical status, traditional reliance on invasive diagnostic methods such as gastroscopy—although considered the “gold standard” for diagnosis²⁰—is often limited due to poor compliance and tolerability, and some patients are even unable to complete the examination.²¹ Therefore, identifying a safe, non-invasive, convenient, and

Table 3 Correlation Between Contrast-Enhanced Ultrasound Parameters and Occurrence of Gastric Tumors

Index	Occurrence of Gastric Tumors	
	r	P
EI	0.565	<0.05
TTP	0.537	<0.05
AUC	0.597	<0.05
AT	0.524	<0.05

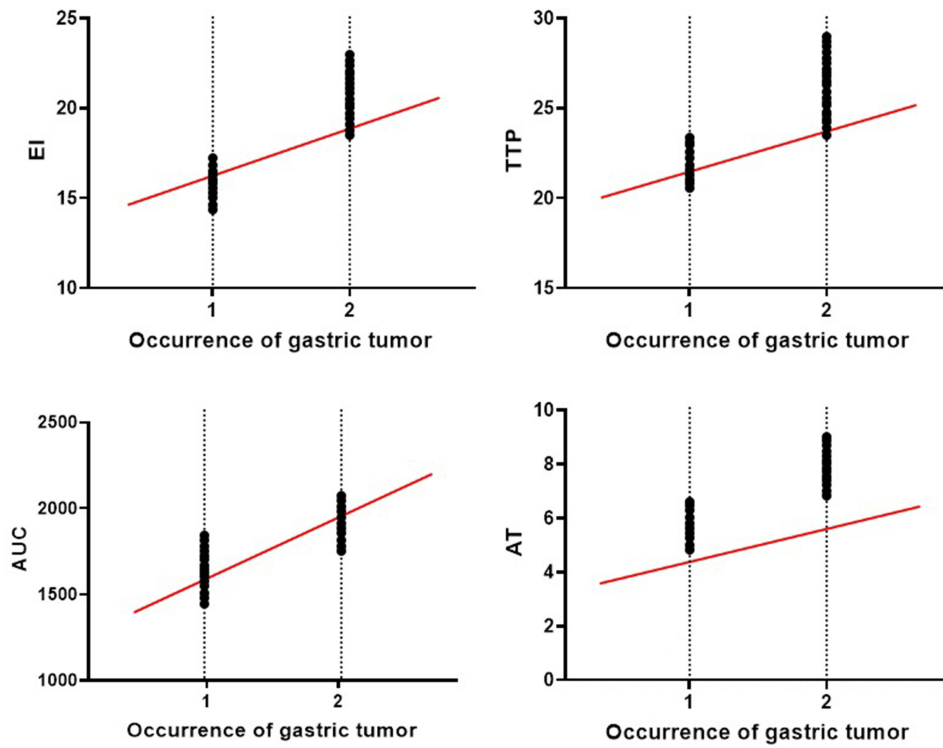


Figure 2 Scatter Plot of Correlation Between Contrast-Enhanced Ultrasound Parameters and Occurrence of Gastric Tumors.

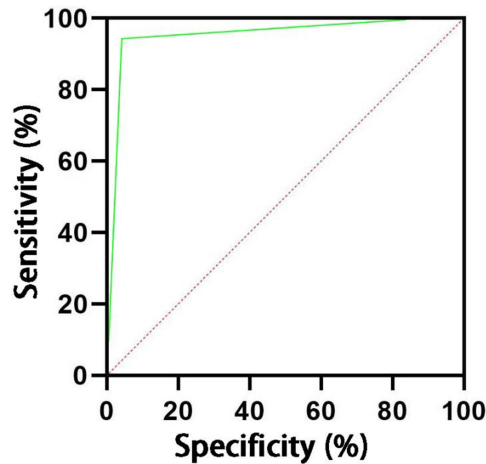


Figure 3 ROC Curve of Gastrointestinal Ultrasound Filling Contrast for Differentiating Gastric Tumors and Ulcers in the Elderly.

accurate auxiliary diagnostic method is particularly crucial for the elderly population. This study retrospectively analyzed 274 elderly patients with gastric diseases and explored the imaging differences and differential diagnostic value of gastrointestinal ultrasound filling contrast in distinguishing between gastric tumors and ulcers. The results showed that this method demonstrated good resolution in both tissue structure imaging and blood perfusion characteristics.

Differential Diagnostic Value of Conventional Ultrasound Features in Gastric Tumors and Ulcers

The results of this study showed that the proportions of low internal echo, irregular morphology, calcification, and type II classification under ultrasound were significantly higher in the gastric tumor group than in the gastric ulcer group,

suggesting that tumor lesions exhibit certain typical echographic features. During the progression of gastric tumors, destruction of the mucosal layer structure, increased cell density, and dysplasia lead to low or heterogeneous internal echoes on ultrasound, often accompanied by blurred borders and irregular shapes.²² Some gastric cancer lesions may present as punctate or mass-like strong echoes due to intratumoral hemorrhage, necrosis, or calcification.²³ Moreover, tumor progression often invades across layers, destroying the gastric wall structure, resulting in uneven thickening and classification tending toward type II or higher.²⁴ In contrast, gastric ulcers usually present as focal echo attenuation in the mucosal layer with clear borders and enhanced echoes at the ulcer base, with the structure relatively well preserved.²⁵

Analysis of Contrast-Enhanced Ultrasound Parameters in Gastric Tumors

Gastrointestinal ultrasound filling combined with contrast-enhanced ultrasound offers significant advantages in assessing gastric wall perfusion status and microvascular distribution.²⁶ The study found that the gastric tumor group had higher values in EI, TTP, AUC, and AT compared with the gastric ulcer group, and Spearman analysis indicated that all these parameters were positively correlated with the occurrence of gastric tumors. Among them, EI reflects local blood perfusion volume; due to abundant neovascularization and high blood flow in gastric cancer tissues, EI was significantly higher than in ulcers.²⁷ Prolonged TTP indicates slower vascular perfusion and structural disorganization in the lesion area.²⁸ A larger AUC reflects prolonged enhancement duration and a higher total perfusion volume, aligning with the hypermetabolic and oxygen-demanding nature of gastric cancer.²⁹ Meanwhile, earlier AT suggests that the lesion area is rapidly perfused.³⁰ These contrast-enhanced features provide hemodynamic evidence of dynamic perfusion for gastric tumors, enhancing disease identification from a “functional” perspective.

Evaluation of Diagnostic Value via ROC Analysis and Summary of Advantages

ROC curve analysis further demonstrated that gastrointestinal ultrasound filling contrast has high accuracy in differentiating gastric tumors from ulcers (AUC = 0.947), with sensitivity and specificity of 96.72% and 98.91%, respectively, indicating good diagnostic consistency and reliability in clinical practice. This method not only clearly visualizes the gastric wall layers and internal lesion structure but also, through contrast-enhanced modes, quantitatively analyzes perfusion parameters, thereby improving early detection capability for gastric tumors. Compared with gastroscopy, gastrointestinal ultrasound filling contrast has multiple advantages: (1) Non-invasive, radiation-free, and highly repeatable—especially suitable for frail elderly patients who cannot tolerate gastroscopy; (2) Simple to operate and time-efficient—ideal for large-scale use in outpatient settings or health check-ups; (3) Combined with contrast-enhancement technology, it enables real-time dynamic evaluation of lesion blood supply characteristics, providing new evidence for benign-malignant differentiation; (4) Useful for follow-up of lesions to assess progression and treatment response.

Limitations and Future Outlook

This study still has certain limitations: First, it is a single-center retrospective study. Although the sample size is relatively adequate, further verification with multi-center, large-sample studies is needed to confirm its generalizability. Second, extracorporeal ultrasound visualization of gastric cancer can be influenced by lesion location, infiltration depth, histological type, and size. In this study, these parameters were recorded for gastric cancer cases but could not be fully standardized between groups, as gastric ulcers do not share comparable characteristics such as infiltration depth or histological classification. Moreover, due to the retrospective design, lesion location and size were not strictly matched across all cases. Although this may have introduced some variability, the overall trends and statistically significant differences in imaging features and contrast-enhanced parameters remained consistent. Future prospective studies with standardized lesion characteristics and matched case-control design would further enhance the reliability of such findings.

Third, the results of gastrointestinal ultrasound filling contrast partly rely on operator experience, and subjectivity in image interpretation has not been fully excluded. Additionally, some early gastric cancer lesions are small and show no significant perfusion differences, thus still requiring confirmation via gastroscopy and biopsy. Another consideration is the applicability of the contrast agent in elderly patients with comorbidities such as severe cardiac, hepatic, or renal

dysfunction. In such cases, the safety profile and hemodynamic effects of the agent should be carefully evaluated before use.

From a clinical translation perspective, we recommend incorporating the study's findings into a simplified diagnostic workflow: (1) Perform routine gastrointestinal ultrasound filling examination in elderly patients with suspected gastric lesions; (2) If suspicious features (eg, low internal echo, irregular morphology) are detected, proceed to contrast-enhanced evaluation; (3) Integrate perfusion parameters (EI, TTP, AUC, AT) into the diagnostic decision-making process; (4) Refer patients with high-risk patterns for confirmatory gastroscopy and biopsy. Such an algorithm could improve diagnostic efficiency while minimizing unnecessary invasive procedures. In the future, the incorporation of advanced technologies such as AI-assisted analysis and 3D ultrasound modeling could further enhance the objectivity and sensitivity of imaging analysis. In summary, gastrointestinal ultrasound filling contrast is a non-invasive, safe, and highly practical examination method for the elderly, offering relatively accurate differentiation between gastric tumors and ulcers. Especially when conventional ultrasound is combined with contrast-enhanced parameter analysis, the early detection rate of gastric cancer can be effectively improved, demonstrating considerable clinical value for widespread application.

Conclusion

Gastrointestinal ultrasound filling contrast, especially when combined with contrast-enhanced parameter analysis, demonstrates high accuracy in differentiating gastric tumors from gastric ulcers in the elderly population. This technique offers a safe, non-invasive, and convenient diagnostic option with excellent clinical applicability, particularly for elderly patients who are frail, have poor tolerance to invasive examinations, or have contraindications to gastroscopy. In outpatient settings, primary care facilities, and health screening programs, it can serve as a valuable complementary tool for early detection and follow-up of gastric lesions. Its application is especially beneficial for cases where invasive procedures are not feasible, providing both structural and functional imaging information to aid in clinical decision-making.

Disclosure

The authors report no conflicts of interest in this work.

References

1. Shi HX, Wang ZF, Sun XH. [Characteristics of esophageal motility and clinical presentation in gastroesophageal reflux disease patients of different age groups]. *Zhonghua Yi Xue Za Zhi*. 2021;101(14):1015–1019. Danish. doi:10.3760/cma.j.cn112137-20200713-02110
2. Liu YY, Li DJ, Wu SS, et al. [Cancer incidence, mortality and trends among elderly in Hebei province, 2011–2020]. *Zhonghua Zhong Liu Za Zhi*. 2025;47(3):228–236. Polish. doi:10.3760/cma.j.cn112152-20240110-00019
3. Xiang XS, Guo FL, Su Y, et al. [Efficacy and prognosis of preoperative treatment based on arterial infusion chemotherapy in patients with advanced gastric cancer: a real-world study]. *Zhonghua Zhong Liu Za Zhi*. 2025;47(2):183–192. Polish. doi:10.3760/cma.j.cn112152-20240425-00166
4. Jiang F, Fu ZT, Lu ZL, et al. [Trends of stomach cancer incidence and mortality in Shandong province from 2012 to 2012 and predictions from 2023 to 2030]. *Zhonghua Zhong Liu Za Zhi*. 2024;46(9):871–877. Polish. doi:10.3760/cma.j.cn112152-20231227-00387
5. Zheng W, Peng KR, Li FB, et al. [Characteristics of gastric mucosa microbiota in children with chronic gastritis and duodenal ulcer]. *Zhonghua Er Ke Za Zhi*. 2021;59(7):551–556. Xhosa. doi:10.3760/cma.j.cn112140-20210331-00270
6. Ravi KVR, Rathi S, Singh S, et al. A comprehensive review on ulcer and their treatment. *Zhongguo Ying Yong Sheng Li Xue Za Zhi*. 2023;39:e20230006. doi:10.62958/j.cjap.2023.006
7. Chen XL, Ge F, Wan MQ, Qi SM, Qi ZL. Lactate promotes HMGB1 phosphorylation and release via Akt signaling pathway in gastric cancer cells HGC-27. *Zhonghua Zhong Liu Za Zhi*. 2023;45(11):919–925. [Chinese]. doi:10.3760/cma.j.cn112152-20220901-00590
8. Gong CF, Sun YK, Xie YB. Advances in molecular classification and precision immunotherapy for gastric cancer. *Zhonghua Yi Xue Za Zhi*. 2021;101(34):2649–2652. [Chinese]. doi:10.3760/cma.j.cn112137-20210728-01672
9. Lee JH, Kim YJ, Kim YW, et al. Spotting malignancies from gastric endoscopic images using deep learning. *Surg Endosc*. 2019;33(11):3790–3797. doi:10.1007/s00464-019-06677-2
10. Zhang K, Wang H, Cheng Y, et al. Early gastric cancer detection and lesion segmentation based on deep learning and gastroscopic images. *Sci Rep*. 2024;14(1):7847. doi:10.1038/s41598-024-58361-8
11. Xu MQ, Sun K, Cao C, et al. Age-related twin-peak prevalence profiles of *H. pylori* infection, gastritis, GIN and gastric cancer: analyses of 70,534 patients with gastroscopic biopsies. *PLoS One*. 2022;17(7):e0265885. doi:10.1371/journal.pone.0265885
12. Gao MJ, Li SB, Zhu XJ, et al. Analysis of risk factors for gastric cancer and precancerous lesions: a case-control study. *J Dig Dis*. 2024;25(11–12):674–684. doi:10.1111/1751-2980.13326

13. Feng L, Wang Y, Niu LJ. Ultrasound-guided percutaneous thermal ablation assisted by artificial ascites and soft tissue edema in the treatment of special-region hepatic tumors. *Zhonghua Zhong Liu Za Zhi*. 2024;46(2):155–160. doi:10.3760/cma.j.cn112152-20231026-00269
14. Xu D, Liu R, Xu H, et al. Adoption of two-dimensional ultrasound gastrointestinal filling contrast on artificial intelligence algorithm in clinical diagnosis of gastric cancer. *Comput Math Methods Med*. 2022;2022:7385344. doi:10.1155/2022/7385344
15. Wang LL, Nie F, Wang YQ, et al. [Application of dual-channel contrast-enhanced ultrasound in classification of hilar cholangiocarcinoma and diagnosis of etiology of low biliary obstruction]. *Zhonghua Yi Xue Za Zhi*. 2021;101(17):1262–1268. Danish. doi:10.3760/cma.j.cn112137-20200815-02387
16. Feng C, Cheng J, Xiang H, et al. [Value of preoperative abdominal contrast-enhanced multiple-row detector computed tomography in predicting the postoperative 1-year disease-free survival for gastric cancer]. *Zhonghua Wei Chang Wai Ke Za Zhi*. 2018;21(9):1059–1064. Hawaiian
17. Rath A, Pradeep I, Nigam JS. Diagnostic performance of bile duct brush cytology with risk of malignancy of standardized categories in the wake of world health organization reporting system for pancreaticobiliary cytopathology: an updated systematic review and meta-analysis. *Acta Cytol*. 2023;67(6):639–649. doi:10.1159/000534764
18. Yang D, Zhou Y, Peng Z, et al. Effects of MSCT enhanced scan image diagnosis on clinical outcome of patients after radical gastrectomy and its influence on misdiagnosis rate. *J Buon*. 2021;26(4):1479–1484.
19. Lee HJ, Kim Y-W, Park DJ, et al. Laparoscopic pylorus-preserving gastrectomy versus distal gastrectomy for early gastric cancer: a multicenter randomized controlled trial (KLASS-04). *Ann Surg*. 2025;281(4):573–581. doi:10.1097/SLA.0000000000006503
20. Feng Y, Yang K, Sun H-H, et al. Value of preoperative gastroscopic carbon nanoparticles labeling in patients undergoing laparoscopic radical gastric cancer surgery. *Surg Oncol*. 2021;38:101628. doi:10.1016/j.suronc.2021.101628
21. Ji L, Liu Z, Zhou B, et al. Community-based pilot study of a screening program for gastric cancer in a chinese population. *Cancer Prev Res*. 2020;13(1):73–82. doi:10.1158/1940-6207.CAPR-19-0372
22. Liang Y, Jing W-Y, Song J, et al. Clinical application of oral contrast-enhanced ultrasound in evaluating the preoperative T staging of gastric cancer. *World J Gastroenterol*. 2024;30(41):4439–4448. doi:10.3748/wjg.v30.i41.4439
23. Nan M, Ye W, Liu Y, et al. Diagnostic accuracy of gastric filling ultrasonography in preoperative invasion depth (T stage) of gastric cancer: meta-analysis. *Medicine*. 2022;101(42):e31066. doi:10.1097/MD.00000000000031066
24. Wang S, Hong Y, Wang L. Clinical study on the evaluation of the condition of patients with gastric tumors and the choice of surgical treatment by gastric ultrasonic filling method. *Contrast Media Mol Imaging*. 2022;2022:3960929. doi:10.1155/2022/3960929
25. Mu K, Sun Q, Li X, et al. The value of oral contrast-enhanced gastric ultrasonography in the diagnosis and staging of benign peptic ulcer. *Sci Rep*. 2024;14(1):17390. doi:10.1038/s41598-024-68430-7
26. Fan F, Cao S, Zhang LM, et al. [Endoscopic ultrasonographic features of submucosal lesions of upper digestive tract suspected gastrointestinal stromal tumors and their correlation with progression and pathological risk grade of the lesions]. *Zhonghua Yi Xue Za Zhi*. 2023;103(21):1643–1648. Danish. doi:10.3760/cma.j.cn112137-20230207-00177
27. Wen Z, He X, Chen C, et al. Evaluation of the efficacy of gastric lymphoma treated with non-surgical therapy using oral and double contrast-enhanced gastric ultrasonography. *Med Ultrason*. 2023;25(3):255–262. doi:10.11152/mu-4007
28. Lei K, Wang J, Wang X, et al. Extended lymphadenectomy based on the TRIANGLE for pancreatic head cancer: a single-center experience. *Langenbecks Arch Surg*. 2024;409(1):54. doi:10.1007/s00423-024-03245-8
29. Wang YK, Shan F, Ying XJ, et al. [Accuracy comparison of abdominal enhanced CT and endoscopic ultrasound in the staging of gastric cancer after neoadjuvant chemotherapy: a post hoc analysis of a randomized clinical trial]. *Zhonghua Wai Ke Za Zhi*. 2020;58(8):614–618. Hawaiian. doi:10.3760/cma.j.cn112139-20200114-00027
30. Xu ZW, Zhao K, Hong QQ, et al. [Short-term outcomes and long-term quality of life after undergoing radical proximal gastrectomy with esophageal gastric tube anastomosis and total gastrectomy with Roux-en-Y anastomosis for Siewert type II and III adenocarcinoma of the esophagogastric junction: a propensity score matching analysis]. *Zhonghua Wei Chang Wai Ke Za Zhi*. 2023;26(2):181–190. Hawaiian. doi:10.3760/cma.j.cn441530-20220728-00330

International Journal of General Medicine

Publish your work in this journal

The International Journal of General Medicine is an international, peer-reviewed open-access journal that focuses on general and internal medicine, pathogenesis, epidemiology, diagnosis, monitoring and treatment protocols. The journal is characterized by the rapid reporting of reviews, original research and clinical studies across all disease areas. The manuscript management system is completely online and includes a very quick and fair peer-review system, which is all easy to use. Visit <http://www.dovepress.com/testimonials.php> to read real quotes from published authors.

Submit your manuscript here: <https://www.dovepress.com/international-journal-of-general-medicine-journal>

Dovepress
Taylor & Francis Group