

# Preliminary Short-Term Results of Supraciliary Ab-Interno MINject<sup>®</sup> Implantation Following Failed Filtering Glaucoma Surgery in Primary Open-Angle Glaucoma

Jan Niklas Lücke, Vincent Lücke, Thomas Dietlein, Johanna Wiedemann, Alexandra Lappas

Department of Ophthalmology, Medical Faculty and University Hospital of Cologne, Cologne, 50937, Germany

Correspondence: Jan Niklas Lücke, Department of Ophthalmology, Medical Faculty and University Hospital of Cologne, Köln, DE-50937, Germany, Tel +49 0221-478 4300, Fax +49 0221-478 86052, Email jan.lueke@uk-koeln.de

**Purpose:** To investigate the efficacy of MINject<sup>®</sup> (suprachoroidal stent) in lowering intraocular pressure (IOP) in eyes following failed filtering glaucoma surgery.

**Methods:** In this single-center retrospective study, 18 patients who had undergone suprachoroidal stent implantation after failed filtering surgery were analyzed. Follow-up was at least 12 months, and surgical success was measured by 12-month postoperative intraocular pressure (IOP), glaucoma medication, and revision surgery (criteria A: IOP < 21 mmHg, IOP reduction >20%, no revision surgery; criteria B: IOP < 18 mmHg, IOP reduction >20%, no revision surgery; criteria C: IOP ≤ 15 mmHg, IOP reduction ≥40%, no repeat surgery).

**Results:** After a follow-up period of 12 months, the mean IOP decreased from 27.11±5.65 mmHg to 15.94±9.56 mmHg (p<0.01). The median 12-month postoperative IOP was 14.0 mmHg (IQR: 10.0–20.0 mmHg). The probability of surgical success was 66.66% for criteria A and B and 50% for criteria C. The identical success rates for criteria A and B were due to overlapping responder groups in this limited sample. Topical medication was significantly reduced from 4.06±1.08 to 2.13±1.36 (p<0.0001).

**Conclusion:** Supraciliary stent implantation provided an effective and safe treatment option for advanced glaucoma following failed filtering surgery and demonstrated significant intraocular pressure reduction. However, the small sample size limits the generalizability of these findings.

**Keywords:** intraocular pressure, CyPass Micro-Stent, MIGS, trabeculectomy, supraciliary, glaucoma drainage device

## Introduction

Glaucoma is a multifactorial disease leading to retinal nerve fiber loss and progressive visual field defects.<sup>1,2</sup> Lowering intraocular pressure (IOP) is the main treatment approach to reduce the risk of nerve fiber loss.<sup>3</sup> Filtering surgeries such as trabeculectomies or tube implantations have been proven effective in severe cases of glaucoma and in revision glaucoma surgery, when medication or less invasive surgical techniques were not sufficient. Although IOP can be significantly reduced over the long term, the success of filtering surgery is primarily limited by bleb failure due to scarring or by endophthalmitis resulting from bleb infection.<sup>4</sup>

After bleb failure, there are several treatment options, all of which may be associated with some specific disadvantages.

Repeating trabeculectomy can be performed but is usually associated with a higher rate of bleb failure compared to the primary procedure. Glaucoma drainage implants, such as Ahmed, Baerveldt, or Molteno devices, have been shown to lower intraocular pressure effectively and safely.<sup>5</sup> In addition to the common risks following filtering surgery, trabeculectomies are associated with a higher risk of postoperative hypotony. For example, the Tube Versus Trabeculectomy

(TVT) study reported persistent hypotony in 13% of eyes treated with tubes, compared to 31% after trabeculectomy at 5 years follow-up.<sup>6</sup>

Beyond repeating trabeculectomy or tube implantation, a range of alternative surgical approaches has been explored in the setting of failed filtering surgery. These include deep sclerectomy with mitomycin C,<sup>7</sup> canaloplasty,<sup>8</sup> ab interno trabeculectomy with the Trabectome,<sup>9</sup> gonioscopy-assisted transluminal trabeculotomy (GATT),<sup>10</sup> as well as minimally invasive implants such as the PreserFlo<sup>®</sup> MicroShunt<sup>11</sup> and the XEN<sup>®</sup> Gel Stent.<sup>12</sup>

However, in addition to the common risks following filtering surgery, these tubes are associated with a higher risk of postoperative hypotony.

An alternative surgical approach to conjunctival filtration is supraciliary stenting. Supraciliary devices, like the CyPass Micro-Stent<sup>®</sup> (Alcon, Vernier-Geneva, Switzerland), use the uveoscleral aqueous outflow to lower IOP but were withdrawn from the market in 2018 due to corneal endothelial cell loss.<sup>13</sup>

The suprachoroidal stent (MINIject<sup>®</sup>; iSTAR Medical, Wavre, Belgium) is a new, silicone-based glaucoma implant, approved in 2021, which is placed into the suprachoroidal space via the anterior chamber.<sup>14,15</sup> Clinical trials have shown a clinically significant IOP-lowering effect combined with a good safety profile. However, the long-term effect is still unknown, as the longest follow-up in these studies was two years.<sup>16</sup>

So far, its success has been demonstrated for surgically naïve eyes, but not for eyes that have undergone failed filtering glaucoma surgery.<sup>17</sup>

This study aimed to evaluate the suprachoroidal device after failed filtering glaucoma surgery.

## Methods and Materials

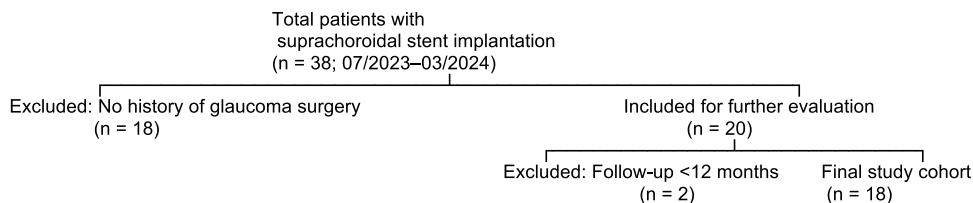
### Study Design

This retrospective single-center study was based on data extracted from the electronic medical records of patients treated at the Department of Ophthalmology, University Hospital of Cologne between 07/2023 and 03/2024. Suprachoroidal stent implantation was performed in 38 patients during this period. Of these 38 patients, 18 were excluded because they had not undergone prior filtering glaucoma surgery (eg, trabeculectomy or glaucoma drainage device), which was an essential inclusion criterion for this study. Eighteen patients had previously undergone trabeculectomy, and two patients had prior GDD implantation additionally. The location of the GDD were not mentioned in the medical records. Two additional patients were excluded due to a follow-up period of less than 12 months. A flowchart summarizing the inclusion and exclusion process is provided in [Figure 1](#).

All included patients had a diagnosis of pseudoexfoliation glaucoma (PEX) or primary open-angle glaucoma (POAG). No patient had a history of strabismus or refractive corneal surgery. Only one eye per patient was included in the analysis.

The following pre- and postoperative parameters were considered: intraocular pressure (IOP), maximum IOP, medication score, visual acuity, cup-to-disc ratio, follow-up time, and age.

Although the Goldmann applanation tonometer is considered the gold standard, IOP measurements were performed consistently using the iCare<sup>®</sup> tonometer (IC200, Icare Finland Oy) throughout the study, both pre- and postoperatively, due to logistical considerations in our outpatient setting and to lower risk of intraocular infections.



**Figure 1** Patient Selection Flowchart: This retrospective study included patients who underwent suprachoroidal stent implantation between July 2023 and March 2024. From an initial cohort of 38 patients, 18 were excluded due to no history of prior glaucoma surgery, and 2 additional patients were excluded due to insufficient follow-up (<12 months). The final study cohort consisted of 18 patients.

Follow-up periods were defined as: first to third postoperative day (Day 1–3), 3 months (Day 60–120), 6 months (Day 150–210), and 12 months (Day 330–390).<sup>18</sup>

The primary outcomes were measured by pre- and postoperative differences in IOP and medication score at several time points surgical success was assessed using three pre-defined criteria, based on established literature: Criteria A (IOP < 21 mmHg, IOP reduction >20%, no repeat surgery) and Criteria B (IOP < 18 mmHg, IOP reduction >20%, no repeat surgery) were derived from the Tube vs Trabeculectomy Study, while Criteria C (IOP ≤ 15 mmHg, IOP reduction ≥40%, no repeat surgery) followed World Glaucoma Association recommendations. These definitions were selected to provide a stepwise assessment of efficacy in a high-risk, pre-operated cohort. A distinction between complete and qualified success was not made, as medication use was analyzed separately. Hypotony (<6 mmHg) was considered surgical failure (according to TVT Study, Gedde et al 2012).<sup>5,19</sup> Additionally, hypotony of <6 mmHg was regarded as a failure.

## Inclusion and Exclusion Criteria

Eligible patients were identified from a surgical database and included if they met all of the following inclusion criteria: (1) a documented history of failed filtering glaucoma surgery—defined as previous trabeculectomy or glaucoma drainage device (GDD) implantation with insufficient IOP control, (2) a diagnosis of either primary open-angle glaucoma (POAG) or pseudoexfoliation glaucoma (PEX), (3) a minimum postoperative follow-up period of 12 months, and (4) age of 18 years or older at the time of surgery.

Patients were excluded if they met any of the following criteria: (1) absence of prior filtering glaucoma surgery, (2) follow-up duration of less than 12 months, (3) history of strabismus or previous corneal refractive surgery, which may interfere with accuracy of tonometry, or (4) inability to obtain reliable visual field testing, due to either poor test performance or advanced disease precluding meaningful perimetric data.

## Surgical Procedure

The suprachoroidal implant is made of silicone-based material providing high biocompatibility.<sup>20</sup> The stent implantations were performed as described below, according to the instructions of the manufacturer:

General anesthesia or a sub-tenon block was performed to ensure sufficient anesthesia. A 2 mm temporal, clear corneal incision was made 1.5 mm anteriorly to the limbus. After application of miotic drops and intracameral cohesive viscoelastics, the iridocorneal angle was gonioscopically visualized by tilting the microscope. The suprachoroidal implant was introduced into the anterior chamber using the delivery sheath of the delivery tool. The implant was then injected into the supraciliary space: It was released by gradually rolling the deployment wheel of the delivery tool until the implant was properly placed into the supraciliary space, while retaining 0.5 mm of it in the anterior chamber. Quadrant selection was based on conjunctival integrity; areas with significant scarring from previous filtering surgery were avoided. The nasal quadrant was preferred when available.

Postoperative treatment included topical corticosteroids (dexamethasone 0.1%) five times daily for the first week, tapered over 4 weeks, and antibiotic eye drops (ofloxacin) three times daily for one week.

## Statistical Analysis

Data were collected from patient records. Values were expressed as mean ± standard deviation (SD). Baseline characteristics and outcomes were analyzed using independent-samples Student's *t*-test. When data were not normally distributed, the Mann–Whitney *U*-test was applied. Normality was assessed using the D'Agostino–Pearson test prior to selecting the appropriate statistical test.

Cases with missing postoperative data at specific time points were excluded from the respective analysis but included in the demographic and baseline summaries.

All analyses and data presentations were performed with Excel (Microsoft Office Excel 2016, California, USA), SPSS v. 22 (IBM, Chicago, Illinois, USA), and GraphPad Software (GraphPad Prism 7, Inc, La Jolla, USA). Statistical significance was set at  $p < 0.05$ . Other levels of significance were  $p < 0.01$ ,  $p < 0.001$ , and  $p < 0.0001$ .

## Results

After applying the respective inclusion criteria, 18 eyes from 18 patients with complete 12-months follow-up were included in the analysis. In two cases, revision surgery was indicated immediately after the 3 months follow-up visit. The baseline characteristics of the group are shown in Table 1. During surgery, the implant was successfully placed into the supraciliary space in all patients.

Postoperatively, the placement of the implant was monitored. During all examinations the correct placement of the implant was confirmed in all eyes except for two cases. In those cases, the implant had to be repositioned during the first postoperative month.

A dislocated implant was immediately repositioned during the same surgical session by implanting it into a more nasal supraciliary quadrant after identifying suboptimal placement. No additional incisions were required.

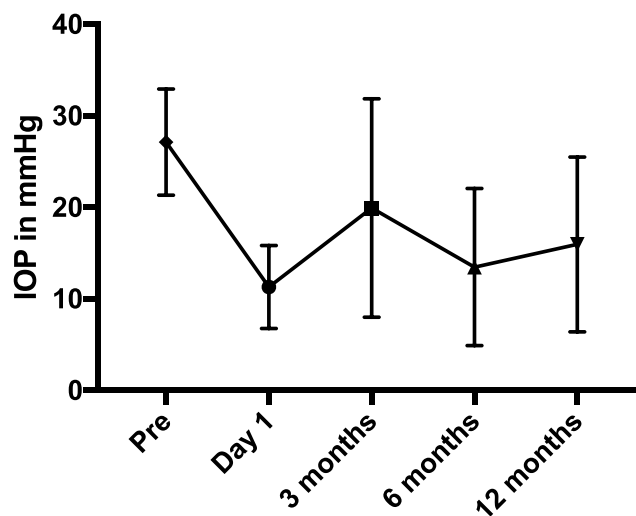
The surgical outcome was determined by criteria A, B and C, representing the postoperative range of IOP. Criteria A and B were met in 12 of 18 cases (66.66%). Criteria C were met in 9 of 18 cases (50.00%), reflecting the more stringent criteria of a postoperative IOP of at least 15 mmHg, an IOP reduction of at least 40%, and no repeat surgery.

Due to the retrospective nature of the study and incomplete IOP and medication data at interim visits (eg, 3 and 6 months), surgical success was evaluated at the 12-month follow-up only. A time-to-failure analysis (eg, Kaplan-Meier) was not feasible in this dataset.

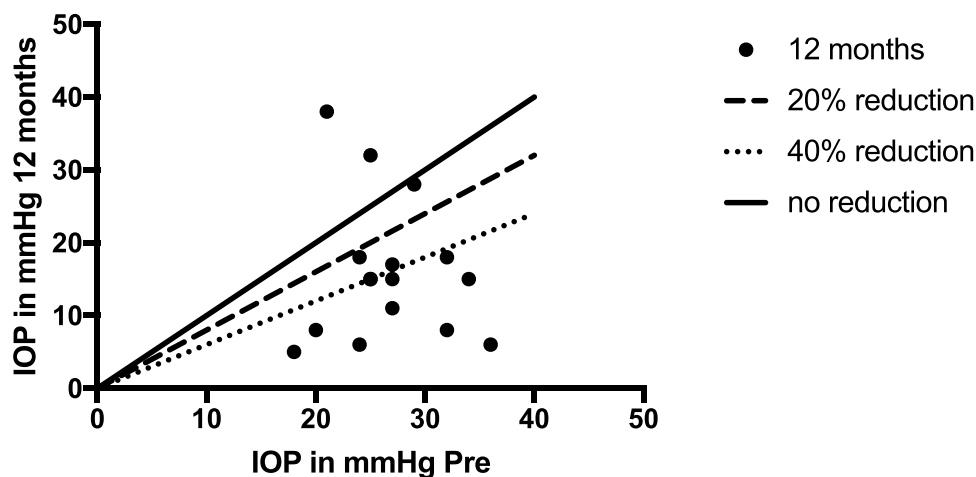
The mean IOP at the 12-month follow-up was  $15.94 \pm 9.56$  mmHg, which was significantly different from the preoperative value ( $27.11 \pm 5.65$  mmHg;  $p < 0.01$ ) (Figure 2). The standard deviation reflects high interindividual variability, which may be attributed to the advanced disease stage and previous surgical interventions.

**Table 1** Baseline Characteristics of the Study Cohort

	<b>Miniject Implantation Following Glaucoma Surgery n=18</b>
Age (refers to the age at the time of suprachoroidal stent implantation) (years)	69.11±10.41
Caucasian	18/18
Maximum preoperative IOP (mmHg)	31.8±8.9
Actual preoperative IOP (mmHg)	27.11±5.6
Medication score initial	4.05±1.07
Glaucoma subtype	
Primary open angle (n)	10/18
Pseudoexfoliation (n)	8/18
Phakic status	
Pseudophakic (n)	15/18
Phakic (n)	3/18
Glaucoma surgery	
Trabeculectomy	18/18
Baerveldt Tube	2/18
Baseline C/D ratio	0.83±0.06
Follow up time (months)	12
Baseline BCVA (logMAR)	0.21±3.6



**Figure 2** Course of IOP during the first year after surgery. Values are presented in mmHg with SD in bars.



**Figure 3** X-axis: preoperative IOP in mmHg, Y-axis: IOP in mmHg one year after surgery; Lines represent the relative IOP reduction (0%; 20%, 40%).

The relative IOP reduction at the last follow-up averaged  $37.84 \pm 41.21\%$  (Figure 3).

The postoperative IOP differed significantly from the baseline value at all postoperative examinations, which were performed on the first postoperative day ( $11.28 \pm 4.54$  mmHg,  $p < 0.0001$ ), 3 months ( $19.91 \pm 11.94$  mmHg,  $p < 0.05$ ), and 6 months after surgery ( $13.45 \pm 8.58$  mmHg;  $p < 0.01$ ) (Figure 2). The topical medication score was reduced from  $4.06 \pm 1.08$  preoperatively to  $2.13 \pm 1.36$  postoperatively ( $p < 0.0001$ ).

The medication score represents the number of topical glaucoma medications used.

The mean time interval between failure of previous glaucoma surgery and implantation of the suprachoroidal device was  $5.1 \pm 4.3$  years.

In some patients with surgical failure, additional laser or surgical treatment was considered necessary during follow-up. In total, 6 of 18 patients (33.3%) required additional surgical intervention during follow-up: 5 patients received Baerveldt implants and 1 patient underwent cyclophotocoagulation.

In two cases, the suprachoroidal stent required surgical replacement due to luxation into the anterior chamber. In one patient, the luxation was detected during the first postoperative examination. The implant was dislocated and appeared inferiorly in the anterior chamber. It was immediately repositioned during the same surgical session by implanting it into a more nasal supraciliary quadrant after identifying suboptimal placement. No additional incisions were required.

**Table 2** Complications 12 Months After MINIject Implantation with the Respective Relative Values

Complications	N=18
Hyphema	5 (27.77%)
Stent luxation	2 (11.11%)
Retinal ablation, endophthalmitis	0
Hypotony	2 (11.11%)

In the second case, gonioscopy revealed partial extrusion of the implant within one month of implantation. Although the implant was revised, the intraocular pressure (IOP) remained elevated, necessitating the subsequent implantation of a glaucoma drainage device within the next 3 months. In total, 5 Baerveldt implantations were considered necessary: in 2 patients 3 months, and in 3 patients 12 months, after the initial suprachoroidal stent implantation. In one case, cyclophotocoagulation was performed 3 and 6 months postoperatively due to elevated intraocular pressure.

No severe complications, such as endophthalmitis or retinal detachment, occurred in the study group. As early complications, slight postoperative intracameral bleeding was noted in 5 cases (27.78%), and postoperative hyphema (11.11%) occurred in 2 cases. It was absorbed without further intervention (Table 2). Hypotony was observed in 3 cases (16.66%) and resolved within 12 months in 2 cases. In one patient, hypotony persisted at 5 mmHg until the last follow-up. Visual acuity in the two cases with persistent hypotony restored from 0.1 to 0.2 logMAR preoperatively to 0.2 and 0.2 logMAR at 12-months follow-up, respectively.

The baseline mean deviation (MD) was  $-13.9 \pm 6.5$  dB, indicating advanced visual field loss.

## Discussion

This retrospective study presents preliminary results assessing the efficacy and safety of suprachoroidal stent implantation following failed filtering surgery with a follow-up of 12 months. The surgical outcome, with a success rate of 66.66% for criteria A and B (IOP < 21 mmHg, IOP reduction >20%, no repeat surgery), and a success rate of 50% for the more stringent criteria C (IOP  $\leq$  15 mmHg, IOP reduction  $\geq$ 40%, no repeat surgery), demonstrates a clinically meaningful finding. There were, however, some revision surgeries necessary throughout the follow-up period, including two cyclophotocoagulations in one patient (n=1; 5.5%) and five drainage glaucoma implants (n=5; 27.7%).

Most complications were mild to moderate (intracameral bleeding, n=5; hyphema, n=2; hypotony, n=3), one of which was persistent hypotony. Regarding the reoperation rate, we must consider the severe preoperative condition of the included eyes in this study. All patients had progressed glaucoma, a prolonged history of topical treatment, and prior filtering glaucoma surgeries. There is still no standardized treatment approach for this complex preoperative situation.

There are some conventional surgical strategies that are usually considered when topical therapy is insufficient and there is a history of glaucoma surgery. Depending on the conjunctiva's condition, including vascularization, fibrosis, and mobility, surgical options would include repeat trabeculectomy with anti-proliferative mitomycin or 5-fluorouracil, as well as filtering implants, all of which are known to be associated with even higher rates of failure in revision surgery.<sup>21</sup> Severe complications like hypotony, choroidal hemorrhages, and blebitis may also occur.<sup>4</sup> In cases of failed trabeculectomy, various secondary surgical approaches have been described, including repeat trabeculectomy with adjunctive antimetabolites, glaucoma drainage device implantation, and cyclodestructive procedures. These approaches differ in invasiveness, complication profile, and long-term efficacy, and are often influenced by conjunctival status and previous scarring.

The suprachoroidal stent was approved in 2021, and its efficacy and safety have been demonstrated in first clinical trials.<sup>14,15</sup> It effectively reduced IOP and was FDA-approved and CE-certified in Europe. It uses the alternative uveal-outflow mechanism, bypassing the trabecular meshwork, the Schlemm canal, as well as the subconjunctival space. Unlike

conventional filtering surgical options (eg, XEN<sup>®</sup>, PRESERFLO<sup>®</sup>, trabeculectomy, glaucoma drainage implants), it is independent of a subconjunctival filtration zone and should be less prone to scarring.

Glaucoma drainage devices like the Ahmed-, Baerveldt-, or Molteno-devices offer an effective and safe technique to lower intraocular pressure in advanced glaucoma.<sup>5</sup> Their effective lowering of intraocular pressure provides an alternative for eyes with previously failed trabeculectomy. The Tube vs Trabeculectomy study evaluated the implantation of the Baerveldt implant following unsuccessful filtering surgery and reported substantial rates of early and late complications (21%; 34%).<sup>5</sup> Secondary implantation after the failure of an initial tube device can also present challenges, as increased complication rates have been documented in such cases, largely attributed to the inferior placement of the subsequent tube.<sup>22</sup>

Our study demonstrated a mean intraocular pressure (IOP) reduction of 37.84%±41.21%, resulting in a mean IOP of 15.94±9.26 mmHg. By comparison, IOP values after tube implantation were slightly lower, averaging 12.5±3.9 mmHg one year postoperatively.<sup>5</sup> The cumulative probability of failure within the first year of follow-up was 3.9% in the tube group, which is lower than the corresponding rate observed one year after suprachoroidal stent implantation in our study.<sup>23</sup> It is worth noting that the standard deviation (SD) was significantly higher in the suprachoroidal stent cohort of our study. This could be attributed to 3 cases with elevated intraocular pressure (IOP) at the 12-month follow-up, who underwent subsequent Baerveldt implantation. Three cases presented persistent hypotony (5–6 mmHg) throughout the follow-up. As effective as they may be compared to filtering surgery without implants, glaucoma drainage devices bear an elevated risk of severe postoperative hypotony and visual loss. Another long-term risk is corneal decompensation due to the tube located in the anterior chamber.<sup>24</sup>

To minimize complications of glaucoma surgery, minimally invasive bleb surgeries (MIBS) were developed. Filtering implants like the PRESERFLO<sup>®</sup> or XEN<sup>®</sup> were developed to reduce hypotony and hemorrhage. They also reduced recovery time by minimizing surgical trauma and by standardizing surgery.<sup>25,26</sup> Nevertheless, they still rely on the classical outflow path, with its long-term limitations, including subconjunctival fibrosis and bleb-related endophthalmitis.<sup>27</sup>

Compared to repeat trabeculectomy, which may result in lower IOP but is associated with higher complication rates and lower success in revision settings, suprachoroidal stent implantation provides a less invasive alternative without bleb-related complications. In the Tube vs Trabeculectomy study, failure rates for repeat filtering surgery remained significant, especially in eyes with compromised conjunctiva.<sup>5</sup> Our results suggest that suprachoroidal stent implantation may represent a viable and safer second-line option in such scenarios.

The stent used in this study is not the first supraciliary stent to be introduced. Stand-alone surgery with implanting the CyPass<sup>®</sup> Micro-Stent (Micro-Stent) showed a remarkable IOP lowering from 22.6±6.7 mmHg at baseline to 16.7±3.8 mmHg (−17.7%) after 2 years and to 16.9±4.2 mmHg (−16.9%) after 3 years. Glaucoma medication could be reduced from 2.2±1.2 to 1.8±1.2 after 2 years (n=120), and to 2.0±1.2 after 3 years (n=112).<sup>27</sup>

In contrast to our cohort of patients with advanced, pre-treated glaucoma, studies of suprachoroidal stent implantation in treatment-naïve eyes have reported lower mean IOP values and narrower standard deviations. For instance, a meta-analysis of the STAR trials reported a mean IOP of 14.4±4.5 mmHg at 24 months in eyes without prior surgery. These findings underscore the more challenging baseline condition of the eyes included in our study. A separate study investigating Cypass Micro-Stent implantation in 20 eyes with a history of glaucoma surgery demonstrated similar levels of IOP reduction (32.9%, with a mean IOP of 15.1±4.0 mmHg at 12 months) to those observed in our study. In contrast to the aforementioned study, our standard deviation was higher, which is attributable to some postoperative failures with high eye pressure above 30 mmHg. In these cases, Baerveldt implantation was planned within the next few weeks (27.7%/n=5).

Due to corneal endothelial cell loss following Cypass Micro-Stent implantation, the manufacturer's sale has been discontinued, resulting in the stent used in this study currently being the only suprachoroidal ab-interno implant approved in Europe. Currently, no studies are available that investigate the effects on corneal endothelial cells following suprachoroidal stent implantation used in this study. In our study, we did not observe any corneal opacification.

Depending on the eye's functional status, patient age, comorbidities, and intraocular pressure, cyclodestructive procedures may represent a reasonable therapeutic approach. However, these procedures carry risks such as hypotony,

visual deterioration, and phthisis bulbi.<sup>24</sup> The advantages, however, include a significantly simpler surgical technique and lower perioperative morbidity, particularly in older or more comorbid patients.

Future studies should aim to include quality of life (QoL) metrics and patient-reported outcome measures to capture the broader clinical benefit of this minimally invasive procedure beyond IOP control.

Several limitations must be acknowledged when interpreting our results. First and foremost, the retrospective nature of this study imposes inherent constraints compared to prospective studies. Our medical data were extracted from medical records rather than standardized study protocols, which could affect data consistency. No control group means that our IOP results reflect relative success rates, as the untreated IOP remains unknown. The reported IOP data included topical medication, which was prescribed at the discretion of the investigators. Some elderly patients did not return for follow-up visits at the tertiary care center (n=1), although the impact of this bias was low. The objective of this study was to evaluate early postoperative outcomes, for which a 12-month follow-up period was deemed appropriate. These findings can provide a basis for future randomized-controlled trials to assess the safety and efficacy of suprachoroidal stent implantation for long-term outcomes following filtration surgery. In summary, this study is limited by its retrospective design, lack of control group, relatively small sample size, and short follow-up of 12 months. Nevertheless, it offers preliminary real-world insights into the performance of the MINIject device following failed filtering glaucoma surgery.

In conclusion, considering the results of this study, suprachoroidal stent implantation after filtration surgery appeared to be an effective approach for managing advanced pre-operated glaucoma, representing an alternative to repeat trabeculectomy or tube implantation. However, the findings of this study must be interpreted in light of its limitations, including its retrospective single-arm design, lack of a control group, and a relatively short follow-up period of 12 months. It demonstrated a promising potential for lowering IOP and reducing the need for IOP-lowering medication, combined with a tolerable risk profile in demanding glaucoma cases. Finally, the implantation of a supraciliary stent does not preclude the possibility of using glaucoma drainage devices or trabeculectomies in the future, making it an even more attractive option in desperate cases.

## Abbreviations

IOP, intraocular pressure; BCVA, best corrected visual acuity; SD, standard deviation of mean; POAG, primary open-angle glaucoma; PEX, Pseudoexfoliation.

## Ethics Approval

According to regulations of the professional code for Physicians and after consultation with the Ethics Committee of the University of Cologne, an ethical review of the analysis was not required due to the retrospective nature of the study. As patient consent to review medical records was not required by the Ethics Committee of the University of Cologne, all data were anonymized prior to analysis, and the study was conducted in full accordance with the principles of the Declaration of Helsinki.

## Funding

Department of Ophthalmology, University of Cologne, Faculty of Medicine and University Hospital Cologne; SFB 1607/1 2024, Project number 501530074, Projects A03, C01, C02.

## Disclosure

The authors have no relevant financial or non-financial interests to disclose in this work.

---

## References

1. Thakur S, Lavanya R, Yu M, et al. Six-year incidence and risk factors for primary open-angle glaucoma and ocular hypertension. *Ophthalmol Glaucoma*. 2024;7:157–167. doi:10.1016/j.ogla.2023.08.003
2. Vogel R, Crick RP, Newson RB, et al. Association between intraocular pressure and loss of visual field in chronic simple glaucoma. *Br J Ophthalmol*. 1990;74:3–6. doi:10.1136/bjo.74.1.3

3. The AGIS Investigators. The advanced glaucoma intervention study (AGIS): 7. the relationship between control of intraocular pressure and visual field deterioration. *Am J Ophthalmol.* 2000;130:429–440. doi:10.1016/S0002-9394(00)00538-9
4. Kirwan JF, Lockwood AJ, Shah P, et al. Trabeculectomy in the 21st Century. *Ophthalmology.* 2013;120:2532–2539. doi:10.1016/j.ophtha.2013.07.049
5. Gedde SJ, Schiffman JC, Feuer WJ, et al. Three-year follow-up of the tube versus trabeculectomy study. *Am J Ophthalmol.* 2009;148:670–684. doi:10.1016/j.ajo.2009.06.018
6. Gedde SJ, Schiffman JC, Feuer WJ, et al. Treatment outcomes in the tube versus trabeculectomy (TVT) study after five years of follow-up. *Am J Ophthalmol.* 2012;153:789–803.e2. doi:10.1016/j.ajo.2011.10.026
7. Anand N, Wechsler D. Deep sclerectomy with mitomycin C in eyes with failed glaucoma surgery and pseudophakia. *Eye.* 2012;26:70–79. doi:10.1038/eye.2011.238
8. Brusini P, Tosoni C. Canaloplasty after failed trabeculectomy: a possible option. *J Glaucoma.* 2014;23:33–34. doi:10.1097/IJG.0b013e318264cdbf
9. Bussel II, Kaplowitz K, Schuman JS, et al. Outcomes of ab interno trabeculectomy with the trabectome after failed trabeculectomy. *Br J Ophthalmol.* 2015;99:258–262. doi:10.1136/bjophthalmol-2013-304717
10. Cubuk MO, Ucgul AY, Unsal E. Gonioscopy-assisted transluminal trabeculectomy as an option after failed trabeculectomy. *Int Ophthalmol.* 2020;40:1923–1930. doi:10.1007/s10792-020-01364-x
11. Quaranta L, Micheletti E, Carassa R, et al. Efficacy and safety of PreserFlo<sup>®</sup> MicroShunt after a failed trabeculectomy in eyes with primary open-angle glaucoma: a retrospective study. *Adv Ther.* 2021;38:4403–4412. doi:10.1007/s12325-021-01811-w
12. Bormann C, Schmidt M, Busch C, et al. Implantation of XEN after failed trabeculectomy: an efficient therapy? *Klin Monatsblätter Für Augenheilkd.* 2022;239:86–93. doi:10.1055/a-1553-4547
13. Lass JH, Benetz BA, He J, et al. Corneal endothelial cell loss and morphometric changes 5 years after phacoemulsification with or without CyPass micro-stent. *Am J Ophthalmol.* 2019;208:211–218. doi:10.1016/j.ajo.2019.07.016
14. Denis P, Hirneiß C, Reddy KP, et al. A first-in-human study of the efficacy and Safety of MINJect in patients with medically uncontrolled open-angle glaucoma (STAR-I). *Ophthalmol Glaucoma.* 2019;2:290–297. doi:10.1016/j.ogla.2019.06.001
15. García Feijóo J, Denis P, Hirneiß C, et al. A European study of the performance and safety of MINJect in patients with medically uncontrolled open-angle glaucoma (STAR-II). *J Glaucoma.* 2020;29:864–871. doi:10.1097/IJG.0000000000001632
16. Dick HB, Mackert MJ, Ahmed IIK, et al. Two-year performance and safety results of the MINJect supraciliary implant in patients with primary open-angle glaucoma: meta-analysis of the STAR-I, II, III trials. *Am J Ophthalmol.* 2024;260:172–181. doi:10.1016/j.ajo.2023.12.006
17. Vold S, Ahmed IIK, Craven ER, et al. Two-year COMPASS trial results: supraciliary microstenting with phacoemulsification in patients with open-angle glaucoma and cataracts. *Ophthalmology.* 2016;123:2103–2112. doi:10.1016/j.ophtha.2016.06.032
18. Rödter TH, Knippschild S, Baulig C, Krummenauer F. Meta-analysis of the concordance of Icare<sup>®</sup> PRO-based rebound and Goldmann applanation tonometry in glaucoma patients. *Eur J Ophthalmol.* 2020;30:245–252. doi:10.1177/1120672119866067
19. Shaarawy T; World Glaucoma Association. Guidelines on design and reporting of glaucoma surgical trials. Amsterdam: Kugler; 2009.
20. Grierson I, Minckler D, Rippey MK, et al. A novel suprachoroidal microinvasive glaucoma implant: in vivo biocompatibility and biointegration. *BMC Biomed Eng.* 2020;2:10. doi:10.1186/s42490-020-00045-1
21. Widder RA, Lappas A, Rennings C, et al. Primary versus posttrabeculectomy XEN45 gel stent implantation: comparison of success rates and intraocular pressure-lowering potential in pseudophakic eyes. *J Glaucoma.* 2020;29:1115–1119. doi:10.1097/IJG.0000000000001649
22. Pakravan M, Yazdani S, Shahabi C, Yaseri M. Superior versus inferior Ahmed glaucoma valve implantation. *Ophthalmology.* 2009;116:208–213. doi:10.1016/j.ophtha.2008.09.003
23. Gedde SJ, Schiffman JC, Feuer WJ, et al. Treatment outcomes in the tube versus trabeculectomy study after one year of follow-up. *Am J Ophthalmol.* 2007;143:9–22.e2. doi:10.1016/j.ajo.2006.07.020
24. Iliev ME, Gerber S. Long-term outcome of trans-scleral diode laser cyclophotocoagulation in refractory glaucoma. *Br J Ophthalmol.* 2007;91:1631–1635. doi:10.1136/bjo.2007.116533
25. Lüke JN, Dietlein TS, Widder RA, et al. Matched case–control comparison of surgical success after XEN45 gel stent and PRESERFLO MICROSHUNT implantation in a Caucasian population. *Clin Exp Ophthalmol.* 2024;52:732–739. doi:10.1111/ceo.14407
26. Gambini G, Carlà MM, Giannuzzi F, et al. PreserFlo<sup>®</sup> MicroShunt: an overview of this minimally invasive device for open-angle glaucoma. *Vision.* 2022;6:12. doi:10.3390/vision6010012
27. Grisanti S, Grisanti S, Garcia-Feijoo J, et al. Supraciliary microstent implantation for open-angle glaucoma: multicentre 3-year outcomes. *BMJ Open Ophthalmol.* 2018;3:e000183. doi:10.1136/bmjophth-2018-000183

## Clinical Ophthalmology

### Publish your work in this journal

Clinical Ophthalmology is an international, peer-reviewed journal covering all subspecialties within ophthalmology. Key topics include: Optometry; Visual science; Pharmacology and drug therapy in eye diseases; Basic Sciences; Primary and Secondary eye care; Patient Safety and Quality of Care Improvements. This journal is indexed on PubMed Central and CAS, and is the official journal of The Society of Clinical Ophthalmology (SCO). The manuscript management system is completely online and includes a very quick and fair peer-review system, which is all easy to use. Visit <http://www.dovepress.com/testimonials.php> to read real quotes from published authors.

Submit your manuscript here: <https://www.dovepress.com/clinical-ophthalmology-journal>

**Dovepress**  
Taylor & Francis Group