

Effectiveness of Ultrasound Guided Intraarticular Injections with Lidocaine and Triamcinolone: A Retrospective Study of Primary Hip Injections

Maya Jurgens, Tarandeep Sidhu, Amir A Jamali

Department of Orthopedic Surgery, Joint Preservation Institute, Walnut Creek, CA, USA

Correspondence: Amir A Jamali, Department of Orthopedic Surgery, Joint Preservation Institute, 100 N. Wiget Lane, Suite 200, Walnut Creek, CA, USA, Email contact@hipandknee.net

Background: Ultrasound guided hip injections have played a major role in the in-office diagnosis and treatment of a variety of traumatic and degenerative hip joint conditions. There is limited information as to the onset and duration of relief from these types of injections using a uniform medication combination.

Hypothesis/Purpose: The purpose of the study is to evaluate the clinical characteristics of a population of patients undergoing ultrasound guided hip corticosteroid injections. We hypothesized that these injections have a low complication rate and a high degree of pain relief for patients.

Study Design: Case Series.

Methods: We performed a retrospective study on 117 first time hip intraarticular injections performed by one operator using a single ultrasound machine and using the identical technique. In all cases, the hip joint was injected with 4 mL of 1% lidocaine and triamcinolone 40mg. The preinjection pain score was available in 98 hips with a mean of 6.4 ± 1.9 (mean \pm S.D).

Results: 96% of patients had immediate improvement of pain (113/117). There were more right than left hips (67 vs 50) and more females than males (63 vs 54). The most common underlying diagnosis was osteoarthritis (53%). The relief duration was less than 3 months for most patients but longer than 6 months in 4 patients. Adverse outcomes were minimal with no infections and one allergic reaction.

Conclusion: This series represents the largest series of first time hip intraarticular injections with lidocaine and triamcinolone. This regimen has a high probability of immediate pain relief and low complications based on this series of patients.

Keywords: ultrasound guidance, intraarticular injection, femoroacetabular impingement, corticosteroid, hip osteoarthritis

Introduction

Intra-articular injections play an important role in diagnosis and treatment of joint disorders. These injections have been performed with a wide range of medications including local anesthetics, corticosteroids, non-steroidal anti-inflammatory medications, and hyaluronic acid preparations.^{1,2} One of the most widely utilized treatments consists of a combination of corticosteroids and local anesthetics. Local anesthetic injections provide a diagnostic benefit in distinguishing intraarticular sources of pain from referred sources such as those arising from peripheral nerve compression, radiculopathy, or other extraarticular sources. Lidocaine is one of the most widely used local anesthetic preparations. Its advantage is that it has a relatively rapid onset of effect and short half life. It can be combined with longer acting anti-inflammatory corticosteroid treatments such as triamcinolone. This combination confirms the delivery of the corticosteroid into the same anatomical areas that are anesthetized immediately by the lidocaine. Unfortunately both the lidocaine and the corticosteroid preparations have some degree of toxicity to the cartilage and therefore multiple injections are usually not warranted, particularly in younger patients.³⁻⁷ The hip, due to its depth, usually requires guidance for a successful injection.^{8,9} This has been achieved to a high degree with ultrasound guidance.

Ultrasound-guided injections have been used in our clinic since 2010. This study is a retrospective case series of patients who underwent intraarticular ultrasound guided lidocaine and triamcinolone injections in our clinic. The objective of the study is to evaluate the degree of improvement, the duration of improvement, and the complications of ultrasound-guided injections performed by one operator using one ultrasound machine with the same combination of medications in all cases.

Materials and Methods

This is a retrospective cohort study performed in a private clinic setting. In the period between June 2011 and April 2018, the senior author performed a total of 442 ultrasound guided injections.(Figure 1) Two hundred and fifty-seven were intra-articular hip injections. Eight cases were injections of local anesthetic only, thirty-three were injections in the setting of known previous surgery, three injections were done with platelet rich plasma and thirteen were with viscosupplementation agents. The remaining two hundred injections were intra-articular corticosteroid injections, all with 4mL lidocaine and triamcinolone at a dose of 40mg. All injections were performed in the supine position with a portable ultrasound unit with a curvilinear probe (Logiq-E, Probe 4C, GE, Chicago, IL, USA). From this group of intra-articular hip injections, a subgroup of 117 injections were first time injections in patients with no known previous surgery or injections into that hip and are the subject of this study.

The endpoints analyzed were obtained through an electronic medical records system and included the underlying diagnosis pertaining to the hip joint, the level of pain on a visual analog scale from 0–10 with 10 being the worst pain ever experienced by the patient and noted in the clinic notes. Additional endpoints included any adverse outcomes and the perceived duration of pain relief which we uniformly obtained on patients on the visit after the index injection. The duration of pain relief was categorized into five categories based on the most common reported ranges: less than one week (< 1 week), between one week and one month (< 1 month), between 1 month and 3 months (< 3months), between 3 months and 6 months (< 6 months), and between 6 months and one year (< 1 year).

In order to minimize bias, the data was obtained by a research analyst with no familiarity with any of the patients.

The study was IRB reviewed and deemed to represent minimal risk to human subjects and was therefore considered IRB exempt by Pearl IRB, Indianapolis, IN, USA. Our study was in compliance and adherence to the Declaration of Helsinki.

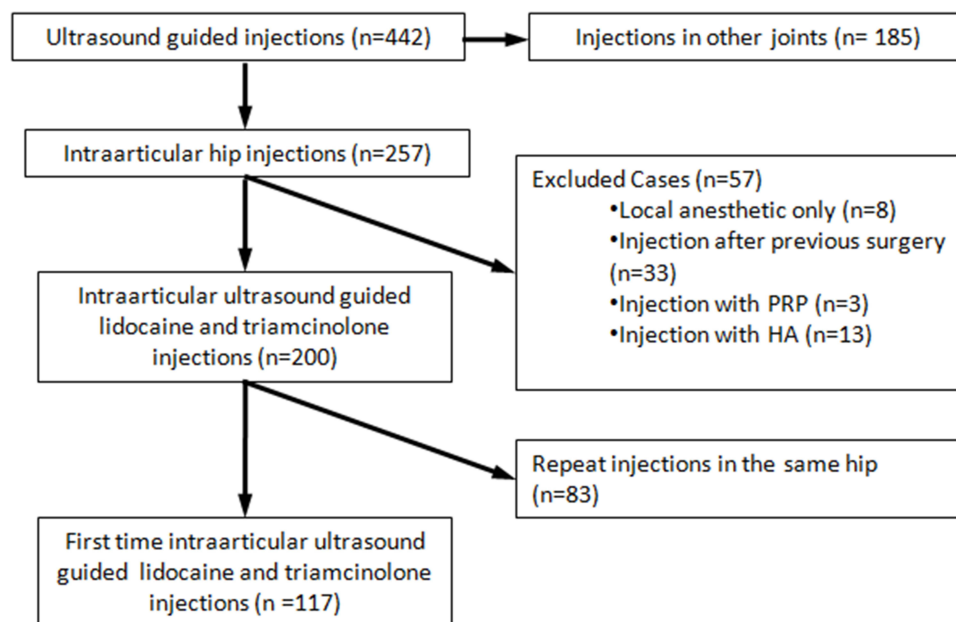


Figure 1 Selection of 117 cases analyzed in this study.

Statistical Analysis: Data on patient pain scores was analyzed with descriptive statistics, mean \pm standard deviation. All tables were produced in standard graphical software (Excel, Microsoft, Redmond, WA).

Technique

The procedure is performed on a standard clinic examination table after a thorough examination of the hip with attention given to the maneuvers that reproduce the patient's pain. The necessary supplies are: 1. Two 10mL syringes with 20 g needles. 2. One 25 g 1.5 inch needle. 3. One 3.5 inch 22 g spinal needle. 4. One 5 inch etched ultrasound 20 g needle. 5. One sterile ultrasound transducer cover (Civco), 6. Two unfenestrated sterile paper towel drapes. 7. Ethyl chloride spray. 8. Betadine swabstick. 9. Isopropyl alcohol pads. 10. 1% lidocaine minimum 10mL. 11. Triamcinolone 40 mg/, mL, 1 mL preferred) (Figure 2).

The patient is given paper shorts which are divided to expose the hip all the way to the level of inguinal ligament. An initial view is obtained in the longitudinal plane demonstrating the femoral neck, the femoral head, and the acetabular rim. If there is any issue with visualization, due to obesity, calcifications in the soft tissues, or osteophytes leading to an anomalous view, the patient's hip is flexed up to confirm the location of the hip joint. Once this has been established, a mark is made on the planned point of entry with a marker. We utilize ethyl chloride to superficially anesthetize the skin. The area is then prepared with betadine followed by isopropyl alcohol and draped with towels. Two syringes are drawn up with 4 mL of lidocaine each. The first one is used with a 25 gauge needle to raise a skin wheal over the planned area of the injection to maximize patient comfort. After about 1–2 minutes, a longer needle typically a 3.5 inch 22 gauge needle or a 6 inch 20 gauge ultrasound etched needle is used with the remainder of the lidocaine from that syringe to anesthetize the path down to the hip. The most painful part of injection procedure is entry into the capsule and we typically anesthetize the surface of the capsule for 30 seconds prior to entry into the hip joint. Once the hip joint has been entered, we aspirate to remove any synovial fluid effusion and discard or culture the fluid based on its appearance. Next the new syringe with the mixture of 4mL lidocaine and triamcinolone is placed on the luer lock of the long needle which is still inserted into the hip joint. The combination medication is then injected into the hip joint (Figure 3).

Then the needle is removed. We then ask and document the degree of patient pain improvement. We then take the patient through the same provocative maneuvers and determine the presence and degree of improvement from




Figure 2 Supplies utilized for each intraarticular Hip injection according to the uniform technique used in this study.

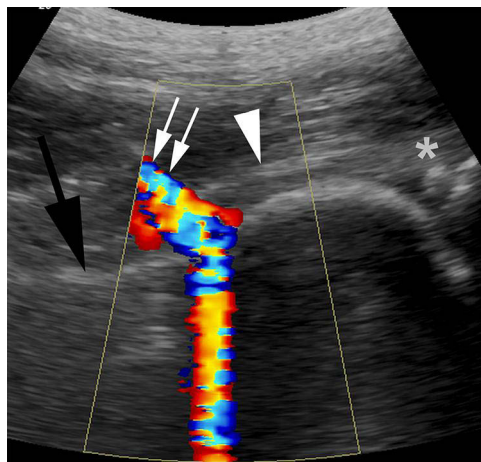


Figure 3 Longitudinal color-flow ultrasound view using color view mode demonstrating injection of combination medication into the hip joint. The path of the needle is shown by the white arrows. The anterior hip capsule is shown by the white arrowhead. The femoral neck is shown by the black arrow. The acetabular labrum is show adjacent to the white asterisk.

preinjection. We also confirm that the patient has full strength of the quadriceps and does not have any evidence of blockade of the femoral nerve.

Results

There were 50 left hips and 67 right hips. There were 54 males and 63 females in this study group. Thirteen patients were lost to follow up. Of the remaining 104 patients, the mean follow-up period was 118 days (14 days to 59 months).

Within the included group, the injections were performed for the following diagnoses: osteoarthritis of the hip in 62 hips, femoroacetabular impingement with presumed labrum tear in 12 hips, isolated labrum tear in 28 hips, Legg Calve Perthes disease in one hip (Figure 4). There was no clear diagnosis in 14 hips.

The preinjection pain score was available in 98 hips with a mean of 6.4 ± 1.9 (mean \pm standard deviation, range 2–10). Details of the scores are given in histogram form in Figure 5. A small subgroup of patients had long term benefit based on the retrospective analysis. Details of the duration of pain relief is provided in Figure 6.

Of the 117 hips, 112 had immediate excellent pain relief. One patient had slight relief and two other patients had no pain relief. Information on pain relief after the injection was not available on two of the patients.

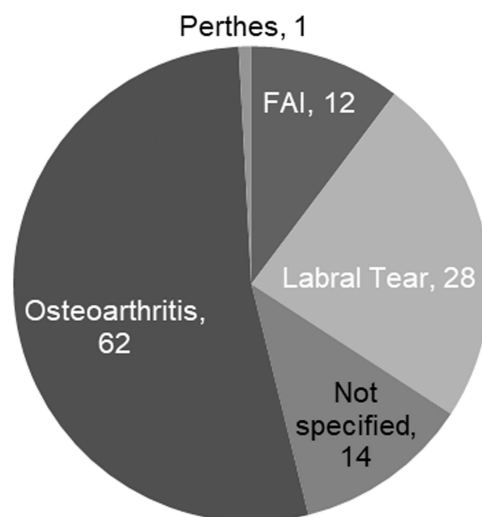


Figure 4 Breakdown of underlying diagnoses for 117 cases included in this study.

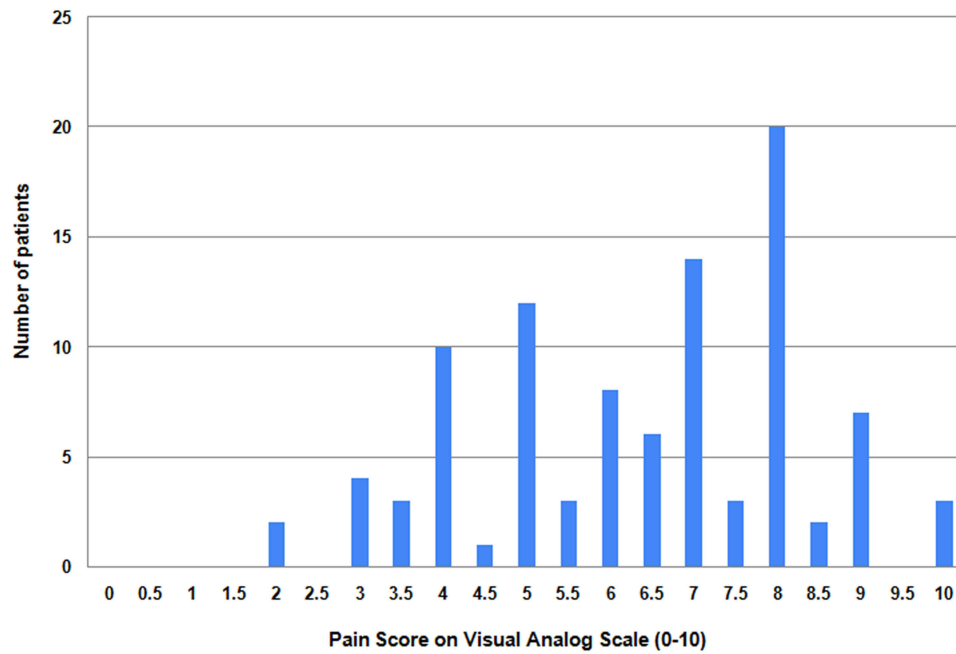


Figure 5 Histogram of pain scores prior to injection for cases included in this study (# of patents vs VAS pain score from (0-10).

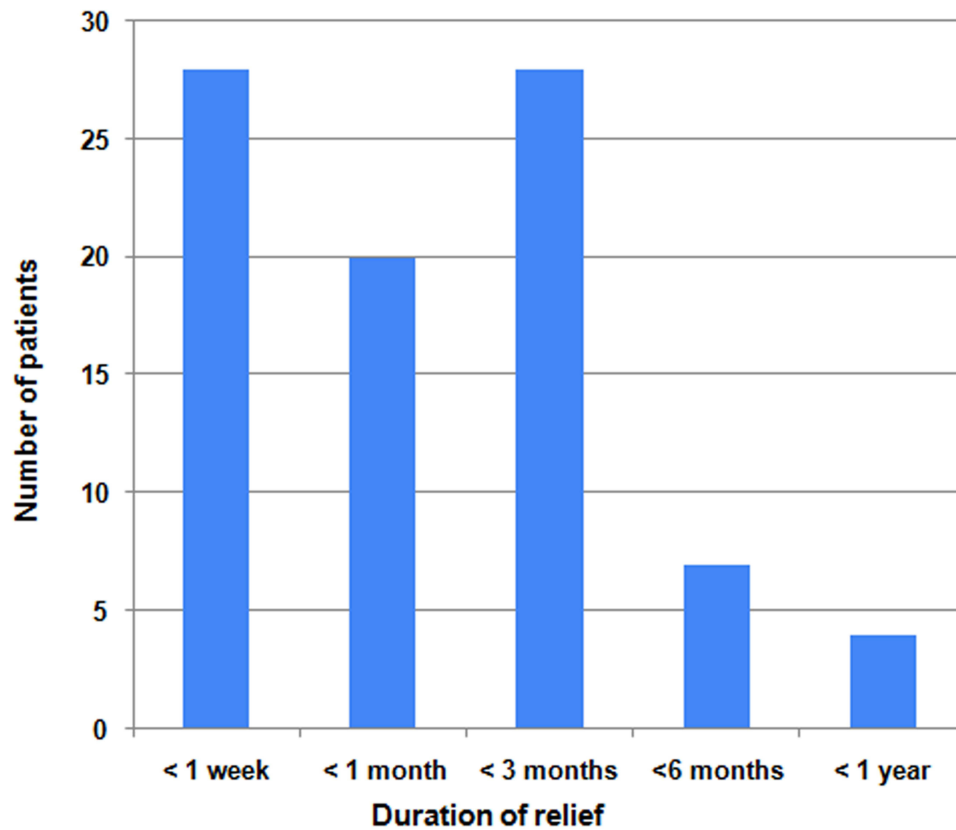


Figure 6 Duration of pain relief based on retrospective review (# of patients vs category of maximum pain relief).

Adverse outcomes information was available on 102 hips. One patient had an allergic reaction. One other patient had short term tingling pain. Seven had worsening hip pain. The remaining 93 patients had no adverse outcome.

Discussion

In the current study, we performed a retrospective analysis of 117 first-time, intra-articular, ultrasound-guided corticosteroid injections with lidocaine and triamcinolone at a set dose of 40 mg per injection. The study population included a majority of patients with osteoarthritis as well as a smaller group with isolated labrum tears or femoroacetabular impingement. We found that the majority of patients had pain relief of three months or less with a relatively even distribution between those who had less than one week, less than one month, and less than three months of total relief. This study demonstrated that a successful ultrasound-guided injection will have a high likelihood of immediate relief, with 112 of 117 patients in this series reporting immediate improvement of their pain after injection. The risk of complications was quite low in the series, with the most common complication being worsening hip pain in 6% of patients. This finding was transitory and may represent the manifestations of the underlying disease. There was one case of an allergic reaction and no cases of infection in this series.

Numerous studies have shown a benefit for corticosteroid injections into the hip joint.^{10–17} Atchia et al performed a prospective randomized controlled trial of 77 hips which were assigned to four groups including no injection, saline, hyaluronic acid, and corticosteroid.¹² They evaluated multiple patient reported outcomes (PROs) including the visual analog scale (VAS) and the Western Ontario and McMaster Universities Arthritis Index (WOMAC). The corticosteroid group performed significantly better than the other treatments. Of note, there were only 19 to 20 patients in each group.

Jurgensmeier et al compared the efficacy of triamcinolone to ketorolac in the injections of the hip and knee in another randomized controlled trial.¹⁸ They demonstrated relatively equivalent improvements with both medications. Their study's findings should be viewed with some caution due to the relatively small number of patients, a total of 30 cases were included in the steroid subgroup and 28 cases were included in the hip ketorolac subgroup.

Khan et al performed a systematic review of the use of intra-articular hip injections for femoroacetabular impingement (FAI).¹⁹ The studies that they included were all relatively small with a maximum size of 72 patients. They concluded that this type of injection can be helpful in making the diagnosis of FAI. They also found that hyaluronic acid agents were more effective than corticosteroids at a follow up period of one year. Importantly, they found that a negative response to an intraarticular injection was a strong predictor for a poor surgical outcome.

Paskins et al performed a single-blind, parallel group, three arm, randomized controlled trial on the effectiveness of corticosteroid injections in patients with osteoarthritis of the hip.¹⁶ The three interventions studied were the best current treatment (BCT), compared to BCT and lidocaine injection, compared to BCT and lidocaine plus triamcinolone injection. BCT consisted of written information on osteoarthritis and advice regarding weight loss, exercise, footwear, walking aids, and pain management. The authors evaluated patient outcomes using a self-reported visual analog scale. They found that both lidocaine and lidocaine plus corticosteroid had a significant effect in alleviating pain but only up to the 2 month testing window. They also found that patients with ultrasound confirmed synovitis or a hip effusion had a significantly better response to the BCT/lidocaine/triamcinolone treatment.

The current study, in spite of its retrospective design, has a number of strengths. It is one of the largest studies published on intra-articular hip injections using ultrasound. In fact, to our knowledge, this is the largest series of ultrasound guided hip injections performed by one clinician, using the same technique, the same medication combination, and the same ultrasound machine. The main weakness of the study is its retrospective design and limited clinical information available. All information was retrieved from an electronic medical record system. Furthermore, we did not have post injection pain scores to determine the exact magnitude of improvement with this intervention. Our assessments largely depended on follow-up information from the patients at subsequent clinic visit. Another strength of this study is that we had close follow-up of the majority of patients through the senior author's clinical practice, minimizing the risk of attrition bias.

A number of therapeutic options have been developed in the treatment of hip pain. This includes utilizing different injectables such as hyaluronic acid preparations, nonsteroidal antiinflammatory drugs, and platelet rich plasma.^{2,13,18,20} Concurrently, variations in the technique and distribution of the injections have been developed. One of these is the

development of the pericapsular nerve group (PENG) block. This is an interfascial plane block that addresses the sensory nerve branches supplying the hip joint not just within the joint but in the surrounding anatomical zones while limiting motor blockade. This has typically been used in the treatment of hip fractures but more recently has been studied in chronic painful hip conditions such as osteoarthritis.^{21–23} In our patient population, we have focused on lidocaine and corticosteroid directly injected into the hip joint as the prime intervention.

Conclusion: In summary, this study demonstrates that intraarticular ultrasound guided hip injections are safe and effective with the use of lidocaine and triamcinolone. They provide reliable pain relief for between 6 months and one year in a subgroup of patients. The local anesthetic portion of the injection is associated with a high rate of immediate pain relief.

Future studies on this topic would benefit from the use of modern tracking technology and online surveys to evaluate patient activity levels with different types of injections over the course of the follow-up on a daily or weekly basis. The time course and duration of improvement are still not well characterized for these widely performed injections.

Funding

This study was internally funded by our institution. No external funding was utilized.

Disclosure

None of the authors have any conflicts of interest related to this paper.

References

- Bernetti A, Agostini F, Finamore N, et al. Effectiveness of ultrasound-guided hip injections on pain and functioning in patients with hip osteoarthritis: a systematic review. *J Back Musculoskelet Rehabil.* 2025;38(1):19–47. doi:10.1177/10538127241296338
- Ferrara PE, Codazza S, Coraci D, Malerba G, Ferriero G, Ronconi G. State of art in intra-articular Hip injections of different medications for osteoarthritis: a systematic review. *BMC Musculoskelet Disord.* 2021;22(Suppl 2):997. doi:10.1186/s12891-021-04866-6
- Dragoo JL, Danial CM, Braun HJ, Pouliot MA, Kim HJ. The chondrotoxicity of single-dose corticosteroids. *Knee Surg Sports Traumatol Arthrosc.* 2012;20(9):1809–1814. doi:10.1007/s00167-011-1820-6
- Jayaram P, Kennedy DJ, Yeh P, Dragoo J. Chondrotoxic effects of local anesthetics on human knee articular cartilage: a systematic review. *PM R.* 2019;11(4):379–400. doi:10.1002/pmrj.12007
- Karpie JC, Chu CR. Lidocaine exhibits dose- and time-dependent cytotoxic effects on bovine articular chondrocytes in vitro. *Am J Sports Med.* 2007;35(10):1621–1627. doi:10.1177/0363546507304719
- Seshadri V, Coyle CH, Chu CR. Lidocaine potentiates the chondrotoxicity of methylprednisolone. *Arthroscopy.* 2009;25(4):337–347. doi:10.1016/j.arthro.2009.01.003
- Wernecke C, Braun HJ, Dragoo JL. The effect of intra-articular corticosteroids on articular cartilage: a systematic review. *Orthop J Sports Med.* 2015;3(5):2325967115581163. doi:10.1177/2325967115581163
- Hoeber S, Aly AR, Ashworth N, Rajasekaran S. Ultrasound-guided Hip joint injections are more accurate than landmark-guided injections: a systematic review and meta-analysis. *Br J Sports Med.* 2016;50(7):392–396. doi:10.1136/bjsports-2014-094570
- Schmidt-Braekling T, Waldstein W, Renner L, Valle AG, Bou Monsef J, Boettner F. Ultrasound and fluoroscopy are unnecessary for injections into the arthritic Hip. *Int Orthop.* 2015;39(8):1495–1497. doi:10.1007/s00264-014-2648-8
- Qvistgaard E, Christensen R, Torp-Pedersen S, Bliddal H. Intra-articular treatment of hip osteoarthritis: a randomized trial of hyaluronic acid, corticosteroid, and isotonic saline. *Osteoarthritis Cartilage.* 2006;14(2):163–170. doi:10.1016/j.joca.2005.09.007
- Robinson P, Keenan AM, Conaghan PG. Clinical effectiveness and dose response of image-guided intra-articular corticosteroid injection for hip osteoarthritis. *Rheumatology.* 2007;46(2):285–291. doi:10.1093/rheumatology/kel217
- Atchia I, Kane D, Reed MR, Isaacs JD, Birrell F. Efficacy of a single ultrasound-guided injection for the treatment of hip osteoarthritis. *Ann Rheum Dis.* 2011;70(1):110–116. doi:10.1136/ard.2009.127183
- Park KD, Kim TK, Bae BW, Ahn J, Lee WY, Park Y. Ultrasound guided intra-articular ketorolac versus corticosteroid injection in osteoarthritis of the hip: a retrospective comparative study. *Skeletal Radiol.* 2015;44(9):1333–1340. doi:10.1007/s00256-015-2174-9
- Anderson ES, Hodell E, Mantuani D, Fahimi J, Pampalone I, Nagdev A. Pilot study of ultrasound-guided corticosteroid hip injections by emergency physicians. *West J Emerg Med.* 2014;15(7):919–924. doi:10.5811/westjem.2014.9.20575
- Kivlan BR, Martin RL, Sekiya JK. Response to diagnostic injection in patients with femoroacetabular impingement, labral tears, chondral lesions, and extra-articular pathology. *Arthroscopy.* 2011;27(5):619–627. doi:10.1016/j.arthro.2010.12.009
- Paskins Z, Bromley K, Lewis M, et al. Clinical effectiveness of one ultrasound guided intra-articular corticosteroid and local anaesthetic injection in addition to advice and education for hip osteoarthritis (HIT trial): single blind, parallel group, three arm, randomised controlled trial. *BMJ.* 2022;377:e068446. doi:10.1136/bmj-2021-068446
- Lynch TS, Oshlag BL, Bottiglieri TS, Desai NN. Ultrasound-guided hip injections. *J Am Acad Orthop Surg.* 2019;27(10):e451–e61. doi:10.5435/JAAOS-D-17-00908
- Jurgensmeier K, Jurgensmeier D, Kunz DE, Fuerst PG, Warth LC, Daines SB. Intra-articular injections of the hip and knee with triamcinolone vs ketorolac: a randomized controlled trial. *J Arthroplasty.* 2021;36(2):416–422. doi:10.1016/j.arth.2020.08.036

19. Khan W, Khan M, Alradwan H, Williams R, Simunovic N, Ayeni OR. Utility of intra-articular hip injections for femoroacetabular impingement: a systematic review. *Orthop J Sports Med.* 2015;3(9):2325967115601030. doi:10.1177/2325967115601030
20. Rampal S, Jaiman A, Tokgoz MA, et al. A review of the efficacy of intraarticular Hip injection for patients with hip osteoarthritis: to inject or not to inject in hip osteoarthritis? *Jt Dis Relat Surg.* 2022;33(1):255–262. doi:10.52312/jdrs.2022.402
21. Ferreira GF, Marques GL, Segantin DB, et al. Pain relief and functional improvement with ultrasound-guided pericapsular nerve group (PENG) block and viscosupplementation in hip osteoarthritis: a retrospective case series. *Int Orthop.* 2025;49(5):1047–1054. doi:10.1007/s00264-025-06482-8
22. Karaoglan M, Kucukcay Karaoglan B. PENG for chronic pain: the clinical effectiveness of pericapsular nerve group block in chronic Hip pain. *Hip Int.* 2024;34(4):524–536. doi:10.1177/11207000241227542
23. Kose SG, Kose HC, Celikel F, Tulgar S, Akkaya OT. Ultrasound-guided PENG block versus intraarticular corticosteroid injection in hip osteoarthritis: a randomised controlled study. *Korean J Pain.* 2023;36(2):195–207. doi:10.3344/kjp.22325

Orthopedic Research and Reviews

Publish your work in this journal

Orthopedic Research and Reviews is an international, peer-reviewed, open access journal that focusing on the patho-physiology of the musculoskeletal system, trauma, surgery and other corrective interventions to restore mobility and function. Advances in new technologies, materials, techniques and pharmacological agents are particularly welcome. The manuscript management system is completely online and includes a very quick and fair peer-review system, which is all easy to use. Visit <http://www.dovepress.com/testimonials.php> to read real quotes from published authors.

Submit your manuscript here: <https://www.dovepress.com/orthopedic-research-and-reviews-journal>

Dovepress

Taylor & Francis Group