

Margin Involvement After Excision with Preoperative Dermoscopic Assessment of Head and Neck Basal Cell Carcinomas - a Retrospective Study

Laura Ziuzia-Januszewska¹, Irena Walecka², Małgorzata Kołos³, Damian Zimoń², Marcin Januszewski⁴, Eliza Brożek-Mądry¹

¹Department of Otorhinolaryngology, National Medical Institute of the Ministry of Interior and Administration, Warsaw, Poland; ²Department of Dermatology, National Medical Institute of the Ministry of Interior and Administration, Warsaw, Poland; ³Department of Pathomorphology, National Medical Institute of the Ministry of Interior and Administration, Warsaw, Poland; ⁴Department of Gynecology, Oncological Gynecology and Reproduction, National Medical Institute of the Ministry of Interior and Administration, Warsaw, Poland

Correspondence: Laura Ziuzia-Januszewska, Department of Otorhinolaryngology, National Medical Institute of the Ministry of Interior and Administration, Wołoska 137, Warsaw, 02-507, Poland, Tel +48-477221182, Email laura.ziuzia@pimmswia.gov.pl

Purpose: Basal cell carcinoma (BCC) is the most common cancer in Caucasians, and its incidence is rising. Incompletely treated tumors may cause destruction of adjacent structures and significant morbidity. This study aimed to evaluate margin involvement after surgical BCC excision with preoperative dermoscopic assessment and identify tumor features associated with positive and inadequate margins.

Methods: We retrospectively analyzed electronic medical records of 230 head and neck BCCs, surgically excised after preoperative dermoscopic border assessment.

Results: Overall, 14 cases (6.2%) had positive margins, and 35 (16.1%) had inadequate (positive or close) margins. Lateral margins were positive and inadequate in 8 (3.5%) and 16 (7%) cases, respectively, while deep margins in 11 (4.8%) and 27 (12.6%) cases, respectively. The observed rate of lateral margin positivity is notably low compared to prior reports. Recurrence occurred in 2.8% of cases. Factors associated with inadequate margins included H-zone location (OR=3 [95% CI 1.1–8.1]), particularly on the nose (OR=2.3 [95% CI 1.1–4.8]), aggressive histological subtypes (OR=4.3 [95% CI 1.7–11.1]), ulceration (OR=2.3 [95% CI 1.1–4.8]), inflammatory infiltration (OR=3.9 [95% CI 1.7–8.7]), and elastosis (OR=2.9 [95% CI 1.2–6.8]). Lateral inadequate margin was more frequent in recurrent tumors (OR 5.3 [95% CI 1.6–16.9]).

Conclusion: This study supports the role of preoperative dermoscopic lesion borders assessment and multidisciplinary approach in BCC treatments, especially for high-risk tumors when micrographic surgery is not feasible. While further randomized controlled trials are warranted, incorporating preoperative dermoscopic assessment of BCC borders into clinical practice could improve patient outcomes and reduce healthcare costs.

Plain Language Summary: Basal cell carcinoma (BCC) is the most common type of skin cancer, especially in Caucasians, and its numbers are increasing. If BCC is not completely removed, it can cause damage to surrounding tissues. This study looked at how often BCCs are not completely excised when using a skin examination method called dermoscopy before surgery.

We analyzed medical records from 230 BCCs on the head or neck, all of which were surgically removed after dermoscopy was used to examine the edges of the tumor. The study found that in 3.5% of the cases, side margins were positive, which means that cancer cells were present in the cut line, indicating that cancer tissue was not completely removed. This rate is low compared to the literature.

The findings suggest that using dermoscopy before surgery to find the tumor's borders might help surgeons remove the cancer more accurately. This could reduce the need for additional surgeries and help lower healthcare costs. While the study encourages further research to confirm this conclusion, it suggests that using dermoscopy before surgery could be a useful tool for improving outcomes for patients and overall healthcare efficiency.

Keywords: basal cell carcinoma, skin neoplasms, surgical margins, dermoscopy, risk factors, recurrence

Introduction

Basal cell carcinoma (BCC) is the most common cancer in Caucasians, with a lifetime risk of approximately 30% and a growing incidence.^{1,2} Risk factors include UV exposure, ionizing radiation, immunosuppression, non-healing skin ulcers, previous skin malignancies, and genetics.^{1,3,4} BCC typically occurs in sun-exposed areas, with 80% on the head and neck.^{1,3} It is usually characterized by slow progression, a very low propensity to metastasize, and low mortality. However, untreated or incompletely treated tumors may destroy adjacent structures and progress to locally advanced disease, resulting in substantial disfigurement, particularly when located on the face.^{1,2,4,5}

A useful tool to enhance clinical assessment accuracy is dermoscopy, a quick, simple, inexpensive, and non-invasive technique using a hand-held illuminated magnifier.^{2,3,6} Evidence suggests dermoscopy can diagnose BCC with over 90% sensitivity and specificity, improving both by 15–20% compared to naked-eye evaluation.^{1,2} Dermoscopic features of BCC include arborizing and superficial telangiectasias, leaflike areas, blue/gray ovoid nests or globules, ulceration, multiple small erosions, and spoke-wheel areas, in the absence of a pigmented network.^{2,3,6} These features have their histopathological correlates, allowing the prediction of BCC subtype.^{1,3} Moreover, dermoscopy is useful in the preoperative assessment of tumor extent,^{3,4} although European guidelines recommend further studies for its clinical implementation in this application.¹

The gold standard in BCC management is surgery, with the primary goal of achieving complete resection of cancerous tissue.^{3,4} While cosmetic outcomes are important, particularly in aesthetically sensitive areas of the head and neck, they should not overshadow the need for radical tumor excision.^{7,8} However, incomplete or suboptimal BCC excision is not uncommon,^{1,9} posing a risk of recurrence and leading to significant morbidity and healthcare costs. For high-risk tumors, Mohs micrographic surgery (MMS) is often recommended when feasible,^{1,3,10} involving multiple excisions with perioperative microscopic margin examination. MMS enables complete margin evaluation while minimizing the resection defect.^{3,11,12} However, it is time-consuming, expensive, and requires surgical training, dermatopathological expertise, and specialized equipment, limiting its availability.^{5,6,10,11} It is thus essential to identify more feasible methods for improving the outcomes of standard BCC excision.⁹

The primary aim of this study was to evaluate margin involvement in head and neck BCCs excised surgically after preoperative dermoscopic assessment of lesion borders, with particular emphasis on lateral margins. The secondary objective was to identify clinical and morphologic tumor features associated with positive and inadequate margins.

Materials and Methods

This retrospective observational study was conducted through the analysis of pathology reports and electronic medical records of patients with head and neck skin BCCs treated at the Department of Otorhinolaryngology of the National Medical Institute of the Ministry of the Interior and Administration in Warsaw, Poland, from January 2018 to September 2024. The inclusion criteria were histologically confirmed head and neck BCCs that were surgically excised with radical intent. If several lesions were excised from a single patient, each lesion was included in the analysis separately. Excisional biopsies and lesions lacking information on lateral margins in the pathology report were excluded.

In our department, BCC excision is performed according to the following protocol: prior to surgery, a consultant dermatologist delineates and marks tumor borders under dermoscopy guidance. The surgeon then determines and marks the extent of excision, including the surgical margin, before administering local anesthesia. Most lesions are excised with a 5-mm margin of clinically normal skin, although surgical margins may range from 2–4 mm in aesthetically sensitive areas up to 10 mm in cases of tumors that are recurrent, large, or present an aggressive histopathological subtype on preoperative biopsy. All surgeries are performed without intraoperative margin evaluation. Specimens are oriented with sutures, fixed with buffered formalin, and, after routine preparation and staining, assessed by a pathologist according to the WHO Classification of Skin Tumours,¹³ including margin evaluation.

Recorded data included patient age, sex, history of skin malignancies, immunosuppression, organ transplantation and head and neck radiotherapy, surgical margins, type of reconstruction, as well as tumor status (primary or recurrent), anatomical location, largest dimension, border definition, histological subtype, presence of ulceration, inflammatory infiltration, elastosis, fibrosis, perineural invasion, and the width of closest lateral and deep pathological margins.

Pathological margins were considered positive in case of tumor cell involvement in any margin. Margins less than 1 mm, including positive or close margins, were considered inadequate.

Tumor size was categorized according to the TNM classification as T1 for lesions ≤ 2 cm, T2 for lesions > 2 cm and ≤ 4 cm, and T3 for lesions > 4 cm or with deep invasion.¹³ As pathology reports did not include quantitative measurements of invasion depth, deep invasion was considered present when muscular infiltration or perineural invasion was reported.

Tumor location was categorized according to the National Comprehensive Cancer Network (NCCN) into high-risk (H-zone: nose, chin, temporal, periauricular, periorbital, and perioral areas) and medium-risk (M-zone: forehead, cheek, scalp, and neck).⁴ Nodular, superficial, and infundibulocystic histological subtypes were classified as low-risk, while infiltrative, basosquamous, micronodular, and morpheaform subtypes were classified as high-risk (aggressive) according to the NCCN.¹⁰

All lesions were considered at high risk of recurrence according to NCCN due to their head and neck location.¹⁰ Additionally, tumors were classified into easy-to-treat or difficult-to-treat according to the European Association of Dermato-Oncology (EADO). Tumors were considered difficult-to-treat if they were recurrent, located in critical areas (nasal, chin, perioral, periorbital, or periauricular), had poorly defined borders, or exhibited an aggressive subtype or perineural invasion.¹

For the subgroup of patients followed for at least 1 year, we analyzed electronic records of follow-up visits with dermoscopic evaluation to determine the recurrence rate. A recurrence was defined as a BCC in the same area as a previously excised lesion, wherein we acknowledge this may overestimate its rate by misclassifying a new focus as a recurrence.

Statistical analysis was performed using Statistica (version 13.3; StatSoft). Categorical variables were presented as counts and percentages and compared with the chi-squared test or Fisher's exact test, as appropriate. As continuous variables were non-normally distributed, they were reported as median, interquartile range (IQR), and range, and compared with a Mann-Whitney *U*-test. A two-sided *p*-value < 0.05 was considered statistically significant. Univariate logistic regression analyses were performed to determine the association between tumor features and positive/inadequate margins, calculating odds ratios (OR) and 95% confidence intervals (95% CI). Data were presented graphically using IBM SPSS statistics (version 29, PS IMAGO PRO 10.0).

The study was approved by the Bioethics Committee of the National Medical Institute of the Ministry of the Interior and Administration in Warsaw (decision number 91/2024), with informed consent waived due to the retrospective analysis of anonymized data. The study was performed in accordance with the Declaration of Helsinki and its amendments.

Results

The study included 230 BCCs from 185 patients (119 lesions in women and 111 in men), with a median patient age of 77 years (range 34–94). Of the tumors, 208 (90.4%) were primary and 22 (9.6%) recurrent. Clinical and histopathological features are presented in [Table 1](#).

Surgical margins were recorded for 132 lesions, of which 99 (75%) were excised with a 5-mm margin, 12 (9.1%) with a margin smaller than 5 mm, and 21 (15.9%) with a margin of 6–10 mm. The defect was closed primarily in 48 lesions (20.9%), reconstructed with local flaps in 169 lesions (73.5%; including 6 with a paramedian forehead flap), and with free skin grafting in 13 lesions (5.7%).

The most common location was the nose (35.2%), followed by periauricular (12.2%), forehead (12.2%), and temporal regions (11.7%), with 163 lesions (70.9%) located in the H-zone and 67 lesions (29.1%) in the M-zone. The median size of the tumors was 10 mm (IQR 7–15), with 128 lesions (57.4%) measuring at least 10 mm and 35 lesions (15.7%) at least 20 mm. According to the TNM classification, 196 tumors (87.9%) were categorized as T1, 21 (9.4%) as T2, and 6 (2.7%) as T3. No regional or distant metastases were reported, and no patient underwent neck dissection.

Histological subtypes were reported for 157 lesions. The most common predominant subtype was infiltrating (34.4%), followed by nodular (31.2%), superficial (18.5%), basosquamous (7%), infundibulocystic (6.4%), micronodular (3.2%), and morpheaform (1.3%). Seventy tumors (44.6%) contained a high-risk histological pattern. Twenty-eight tumors

Table 1 Tumor and Patients Characteristics^a

| Feature | | Result |
|---|---------------------------|-------------|
| Age [years] | Median (IQR) | 77 (70;83) |
| | Range | 34 - 94 |
| Sex [N (%)] | Men | 111 (48.3%) |
| | Women | 119 (51.7%) |
| Region in head and neck [N (%)] | H zone | 163 (70.9%) |
| | Nose | 81 (35.2%) |
| | Temporal | 27 (11.7%) |
| | Periauricular | 28 (12.2%) |
| | Periorbital | 19 (8.3%) |
| | Perioral | 6 (2.6%) |
| | Chin | 3 (1.3%) |
| | M zone | 67 (29.1%) |
| | Forehead | 28 (12.2%) |
| | Cheek | 22 (9.6%) |
| | Scalp | 7 (3%) |
| | Neck | 9 (3.9%) |
| | Primary or recurrent | Primary |
| Recurrent | | 22 (9.6%) |
| Surgical margin [mm] (N=132) | Median (IQR) | 5 (5; 5) |
| | Range | 1 - 10 |
| | ≤ 5 | 111 (84.1%) |
| | 6-9 | 16 (12.1%) |
| | 10 | 5 (3.8%) |
| Maximum diameter of the lesion [mm] (N=223) | Median (IQR) | 10 (7; 15) |
| | < 5 mm | 14 (6.3%) |
| | ≥ 10 mm | 128 (57.4%) |
| | ≥ 20 mm | 35 (15.7%) |
| Morphologic characteristics | Ulceration | 99 (43%) |
| | Poorly defined borders | 89 (38.7%) |
| | Inflammatory infiltration | 38 (16.5%) |
| | Elastosis | 33 (14.3%) |
| | Fibrosis | 14 (6.1%) |
| | Perineural invasion | 1 (0.4%) |

(Continued)

**Table 1** (Continued).

| Feature | | Result | |
|--|------------------------------------|--------------------------------------|------------|
| Histological subtype (most aggressive) (N=157) | Low-risk | 87 (55.4%) | |
| | Nodular | 49 (31.2%) | |
| | Infundibulocystic | 10 (6.4%) | |
| | Superficial | 29 (18.5%) | |
| | High-risk | 70 (44.6%) | |
| | Infiltrating | 54 (34.4%) | |
| | Micronodular | 5 (3.2%) | |
| | Morpheaform | 2 (1.3%) | |
| | Basosquamous | 11 (7%) | |
| | Mixed types | 28 (17.8%) | |
| Medical history | General Medical history (N=221) | Immunosuppression | 11 (5%) |
| | | Organ transplantation | 4 (1.8%) |
| | | Radiotherapy on head and neck region | 10 (4.5%) |
| | Previous skin malignancies (N=163) | Previous BCC | 92 (56.4%) |
| | | Multiple BCCs (≥5) | 52 (22.6%) |
| | | Previous SCC | 11 (6.7%) |
| | | Previous MM | 7 (4.3%) |
| High-risk lesions | EADO Stage II (N=218) | 206 (94.5%) | |
| | NCCN High-Risk | 230 (100%) | |

Notes: ^aN=230 if not other specified.

(17.8%) had mixed subtypes. Ulceration was observed in 99 tumors (43%), inflammatory infiltration in 38 (16.5%), elastosis in 33 (14.3%), fibrosis in 14 (6.1%), perineural invasion in one case (0.4%), and poorly defined borders in 89 lesions (38.7%). Classification according to EADO was possible for 218 lesions, with 206 (94.5%) classified as difficult-to-treat.

Histopathological lateral margins were assessed for all tumors, including one case reported as “wide” without specific dimensions, where margins were recorded as neither positive nor close. Deep margins were reported in 215 cases. In 12 cases where pathology reports assessed excision as complete, margins were recorded as “not positive”, but whether they were close was not recorded (missing data). Margin involvement is shown in [Table 2](#). Positive surgical margins were found in 14 cases (6.2%), including 8 (3.5%) lateral and 11 (4.8%) deep. Inadequate margins were present in 35 cases (16.1%), including 16 (7%) lateral and 27 (12.6%) deep. Of the 35 lesions with inadequate margins, scar tissue was excised in 2 cases with no cancer cells on histopathology, 15 cases were closely followed, 4 received local chemotherapeutics, 2 underwent cryotherapy, 1 received photodynamic therapy, and 11 were lost to follow-up.

The association of patients and tumor characteristics with margin status is presented in [Tables 3–4](#) and [Supplementary Tables S1–S3](#). The age and sex of the patients were not significant for margin positivity. Recurrent tumors were significantly associated with positive (OR=6.4 [95% CI 1.4–28.9]) and inadequate (OR=5.3 [95% CI 1.6–16.9]) lateral margins compared to primary lesions, whereas no significant relationship was observed for deep margins. There were no significant differences in margin positivity depending on tumor diameter.

Table 2 Margin Status of Excised Specimens

| Pathological Margins ^a | | | |
|-----------------------------------|---------|--------------|------------|
| Lateral margin [mm] | N = 230 | Median (IQR) | 4 (2; 5) |
| Positive lateral margin | N = 230 | N(%) | 8 (3.5%) |
| Close lateral margin | N = 230 | N(%) | 8 (3.5%) |
| Inadequate lateral margin | N = 230 | N(%) | 16 (7%) |
| Deep margin[mm] | N = 215 | Median (IQR) | 2 (1–4) |
| Positive deep margin | N = 227 | N(%) | 11 (4.8%) |
| Close deep margin | N = 215 | N(%) | 16 (7.4%) |
| Inadequate deep margin | N = 215 | N(%) | 27 (12.6%) |
| Positive margin (any) | N = 227 | N(%) | 14 (6.2%) |
| Inadequate margin (any) | N = 217 | N(%) | 35 (16.1%) |
| Positive margins (both) | N = 230 | N(%) | 5 (2.2%) |
| Inadequate margins (both) | N = 228 | N(%) | 8 (3.5%) |

Notes: ^aPathological margins were defined as positive when they were involved by tumor cells, as close when they were clear of tumor but less than 1 mm, and as inadequate when they were either positive or close.

Table 3 Relationship Between Tumor Features and Margins Status

| Tumor Characteristic | | Positive Margins | | | | | | Inadequate Margins | | | | | |
|---------------------------|-----------|------------------|--------------|-----------|-------|-----------|-------|--------------------|--------------|------------|--------------|------------|------------------|
| | | Lateral | | Deep | | Any | | Lateral | | Deep | | Any | |
| | | N (%) | p | N (%) | p | N (%) | p | N (%) | p | N (%) | p | N (%) | p |
| Location | H-zone | 7 (4.3%) | 0.443 | 9 (5.6%) | 0.517 | 11 (6.9%) | 0.762 | 14 (8.6%) | 0.161 | 24 (16%) | 0.024 | 30 (19.9%) | 0.026 |
| | M-zone | 1 (1.5%) | | 2 (3%) | | 3 (4.5%) | | 2 (3%) | | 3 (4.6%) | | 5 (7.7%) | |
| Nasal location | Yes | 5 (6.2%) | 0.134 | 6 (7.5%) | 0.201 | 7 (8.8%) | 0.256 | 8 (9.9%) | 0.199 | 15 (20%) | 0.016 | 18 (23.7%) | 0.026 |
| | No | 3 (2%) | | 5 (3.4%) | | 7 (4.8%) | | 8 (5.4%) | | 12 (8.6%) | | 17 (12.1%) | |
| Tumor status | Primary | 5 (2.4%) | 0.031 | 9 (4.4%) | 0.289 | 11 (5.4%) | 0.144 | 11 (5.3%) | 0.011 | 15 (20%) | 0.714 | 30 (15.3%) | 0.262 |
| | Recurrent | 3 (13.6%) | | 2 (9.1%) | | 3 (13.6%) | | 5 (22.7%) | | 12 (8.6%) | | 5 (25%) | |
| Tumor diameter | ≥10 mm | 5 (3.9%) | 1 | 8 (6.3%) | 0.363 | 9 (7.1%) | 0.622 | 10 (7.8%) | 0.668 | 24 (12.2%) | 0.145 | 23 (18.9%) | 0.317 |
| | <10 mm | 3 (3.2%) | | 3 (3.2%) | | 5 (5.4%) | | 6 (6.3%) | | 3 (15.8%) | | 12 (13.6%) | |
| Ulceration | Yes | 5 (5.1%) | 0.295 | 5 (5.1%) | 1 | 7 (5.5%) | 0.782 | 10 (10.1%) | 0.121 | 16 (17.4%) | 0.064 | 21 (22.3%) | 0.030 |
| | No | 3 (2.3%) | | 6 (4.7%) | | 7 (7.1%) | | 6 (4.6%) | | 11 (8.9%) | | 14 (11.4%) | |
| Inflammatory infiltration | Yes | 2 (5.3%) | 0.622 | 4 (10.5%) | 0.092 | 4 (10.5%) | 0.262 | 6 (15.8%) | 0.019 | 10 (27.8%) | 0.003 | 13 (35.1%) | <0.001 |
| | No | 6 (3.1%) | | 7 (3.7%) | | 10 (5.3%) | | 10 (5.2%) | | 17 (9.5%) | | 22 (12.3%) | |
| Elastosis | Yes | 2 (6.1%) | 0.322 | 3 (9.1%) | 0.204 | 3 (9.1%) | 0.437 | 6 (18.2%) | 0.006 | 7 (23.3%) | 0.055 | 10 (31.3%) | 0.012 |
| | No | 6 (3%) | | 8 (4.1%) | | 11 (5.7%) | | 10 (5.1%) | | 20 (10.8%) | | 25 (13.6%) | |
| Histological subtype | HR | 4 (5.7%) | 1 | 6 (8.6%) | 0.301 | 7 (10%) | 0.376 | 10 (14.3%) | 0.006 | 17 (25%) | 0.001 | 21 (30.4%) | <0.001 |
| | LR | 4 (4.6%) | | 3 (3.5%) | | 5 (5.8%) | | 4 (4.6%) | | 5 (6.3%) | | 7 (8.9%) | |

(Continued)

Table 3 (Continued).

| Tumor Characteristic | | Positive Margins | | | | | | Inadequate Margins | | | | | |
|-------------------------------|-----|------------------|-------|-----------|--------------|-----------|-------|--------------------|--------------|------------|------------------|------------|--------------|
| | | Lateral | | Deep | | Any | | Lateral | | Deep | | Any | |
| | | N (%) | p | N (%) | p | N (%) | p | N (%) | p | N (%) | p | N (%) | p |
| Infiltrative | Yes | 3 (5.6%) | 1 | 5 (9.3%) | 0.277 | 5 (9.3%) | 0.605 | 8 (14.8%) | 0.060 | 12 (23.1%) | 0.039 | 15 (28.3%) | 0.029 |
| | No | 5 (4.6%) | | 4 (3.9%) | | 7 (6.9%) | | 6 (5.8%) | | 10 (10.4%) | | 13 (13.7%) | |
| Tumor ≥ 10 mm with HR subtype | Yes | 3 (6.4%) | 0.407 | 6 (12.8%) | 0.018 | 6 (12.8%) | 0.116 | 7 (14.9%) | 0.037 | 13 (28.3%) | <0.001 | 15 (31.9%) | 0.002 |
| | No | 5 (3.4%) | | 5 (3.5%) | | 8 (5.3%) | | 8 (5.5%) | | 11 (8.1%) | | 16 (11.9%) | |

Note: Statistically significant results are in bold.

Abbreviations: HR, high risk; LR, low risk.

Table 4 Odds Ratios for Positive and Inadequate Margins of Resected BCC in Relation to Tumor Features

| Variable | Positive Margin | | | | | | | | | Inadequate Margin | | | | | | | | |
|--|-----------------|-----------------|--------------|----------|-----------------|--------------|-----|----------|-------|-------------------|------------------|--------------|------------|-----------------|--------------|------------|-----------------|--------------|
| | Lateral | | | Deep | | | Any | | | Lateral | | | Deep | | | Any | | |
| | OR | 95% CI | p | OR | 95% CI | p | OR | 95% CI | p | OR | 95% CI | p | OR | 95% CI | p | OR | 95% CI | p |
| Recurrent | 6.4 | 1.4–28.9 | 0.016 | 2.2 | 0.4–10.8 | 0.340 | 2.8 | 0.7–10.9 | 0.140 | 5.3 | 1.6–16.9 | 0.005 | 1.3 | 0.4–4.9 | 0.664 | 1.8 | 0.6–5.5 | 0.269 |
| Region H | 3 | 0.4–24.6 | 0.314 | 1.9 | 0.4–9 | 0.422 | 1.5 | 0.4–5.7 | 0.518 | 3.1 | 0.7–13.8 | 0.147 | 4 | 1.2–13.7 | 0.029 | 3 | 1.1–8.1 | 0.032 |
| Nose | 3.2 | 0.7–13.8 | 0.118 | 2.3 | 0.7–7.8 | 0.180 | 1.9 | 0.6–5.7 | 0.240 | 1.9 | 0.7–5.4 | 0.206 | 2.7 | 1.2–6.2 | 0.017 | 2.3 | 1.1–4.8 | 0.026 |
| Diameter ≥ 10 mm | 1.2 | 0.3–5.2 | 0.805 | 1.9 | 0.5–7.5 | 0.337 | 1.3 | 0.4–4 | 0.656 | 1.2 | 0.4–3.5 | 0.722 | 1.8 | 0.8–4.4 | 0.182 | 1.4 | 0.7–3 | 0.352 |
| HR histological subtype | 1.3 | 0.3–5.2 | 0.752 | 2.6 | 0.6–10.8 | 0.186 | 1.8 | 0.5–5.9 | 0.335 | 3.5 | 1.04–11.6 | 0.044 | 5 | 1.7–14.4 | 0.003 | 4.3 | 1.7–11.1 | 0.002 |
| Ulceration | 2.3 | 0.5–9.7 | 0.270 | 1.1 | 0.3–3.7 | 0.900 | 1.3 | 0.4–3.8 | 0.620 | 2.3 | 0.8–6.7 | 0.112 | 2.2 | 0.96–4.9 | 0.064 | 2.3 | 1.1–4.8 | 0.030 |
| Inflammation | 1.7 | 0.3–8.9 | 0.516 | 3.1 | 0.8–11 | 0.087 | 2.1 | 0.6–7.1 | 0.230 | 3.4 | 1.2–10 | 0.026 | 3.6 | 1.5–8.8 | 0.004 | 3.9 | 1.7–8.7 | 0.001 |
| Elastosis | 2.1 | 0.4–10.6 | 0.391 | 2.3 | 0.6–9.3 | 0.231 | 1.7 | 0.4–6.3 | 0.454 | 4.2 | 1.4–12.4 | 0.010 | 2.5 | 0.95–6.6 | 0.063 | 2.9 | 1.2–6.8 | 0.015 |
| Tumor ≥ 10 mm with HR histological subtype | 1.4 | 0.3–6.1 | 0.664 | 5 | 1.2–10.9 | 0.028 | 2.4 | 0.7–8 | 0.143 | 2.5 | 0.8–7.5 | 0.107 | 4.1 | 1.6–10.4 | 0.003 | 3 | 1.3–7.1 | 0.012 |

Note: Statistically significant results are in bold.

Abbreviation: HR, high risk.

Margin positivity did not significantly differ by anatomical location; however, deep and any margin inadequacy was associated with H-zone (OR=4 [95% CI 1.2–13.7] and OR=3 [95% CI 1.1–8.1], respectively) and nasal location (OR=2.7 [95% CI 1.2–6.2] and OR=2.3 [95% CI 1.1–4.8], respectively). Margin inadequacy by anatomical region is presented in Figure 1.

High-risk histological subtypes were associated with lateral (OR=3.5 [95% CI 1.04–11.6]), deep (OR=5 [95% CI 1.7–14.4]), and any margins inadequacy (OR=4.3 [95% CI 1.7–11.1]). In lesions larger than 10 mm, high-risk subtypes were also significantly associated with deep margin positivity (OR=5 [95% CI 1.2–10.9]). Deep and any inadequate margins were significantly more frequent in the infiltrating subtype (p=0.039 and p=0.029, respectively) and less frequent in the superficial subtype (p=0.014 and p=0.029, respectively). Of 2 morpheaform BCCs, both had inadequate margins (lateral in one case and deep in the other). Inflammatory infiltration was associated with lateral, deep any margin inadequacy (OR=3.4 [95% CI 1.2–10]; OR=3.6 [95% CI 1.5–8.8]; and OR=3.9 [95% CI 1.7–8.7]; respectively), elastosis with lateral and any margin inadequacy (OR=4.2 [95% CI 1.4–12.4]; and OR=2.9 [95% CI 1.2–6.8]; respectively), and ulceration with any margin inadequacy (OR=2.3 [95% CI 1.1–4.8]).

Of 107 tumors followed for at least 1 year (median follow-up 26 months, IQR 19–40, range 12–71), three (2.8%) recurred. Of these, only one, already recurrent at the first surgery, had a positive lateral margin, but scar excision was not performed as the patient was lost to follow-up until the recurrence occurred. The other two lesions had adequate margins.

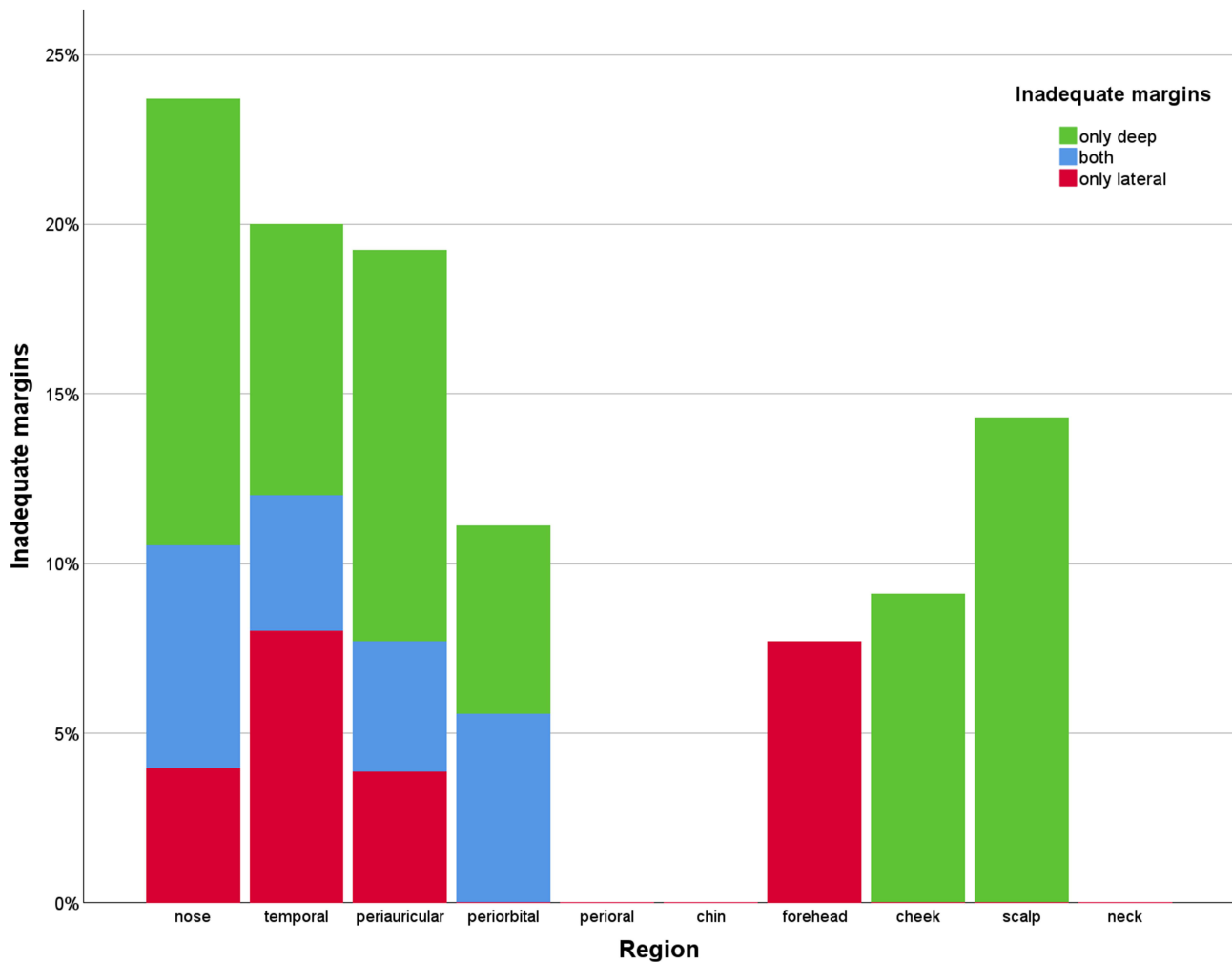


Figure 1 Incidence of inadequate margins by anatomical region of the head and neck. Cases of inadequate lateral margins with undetermined deep margins were classified here as having only inadequate lateral margins.

For one, the only risk factor for recurrence was the nasal location. The second, a 40-mm tumor in the retroauricular region, occurred in a patient with multiple BCCs, hence it could have been either a recurrence or a new focus. The median time-to-recurrence was 30 months (range 24–31). All three recurrences were excised with adequate margins.

Discussion

The reported incidence of positive BCC excision margins varies widely, from 4.7% to 24% in most studies, depending on tumor location, histologic subtype, and surgeon experience.¹ A meta-analysis by Nolan et al¹⁴ comprising 106,832 BCCs, estimated the incomplete excision rate at 11%. Notably, most studies examine BCC across all body regions, whereas literature indicates that head and neck localization carries a higher risk of incomplete excision,^{4,10,15} as summarized in Table 5.

Our positive margin rate of 6.2% compares favorably with the literature data^{15–30} (Table 5). This is particularly noteworthy given that at our institution dermatologists treat low-risk BCCs with simple excisions or non-surgical methods, while only high-risk tumors requiring wider excisions and complex reconstructions are typically referred to the otorhinolaryngology department. Moreover, we did not exclude recurrent tumors or patients on immunosuppression, as is the case in many studies.

Importantly, the incidence of positive lateral margins observed in our study, at 3.5%, is notably low compared to data reported in the literature (Table 5), such as 12.3% by Bozan et al²⁹ and 9.1% by Dalal et al.³⁰ Moreover, we found lateral

Table 5 Summary of Studies Reporting Incomplete Head and Neck BCC Excision Rates

| Authors, Year | Number of BCCs | Margin Involvement (%) | | | Comment |
|--|---------------------------------|-------------------------------------|---|--|--|
| | | Overall Positive (All Body Regions) | Head and Neck | | |
| | | | Positive | Inadequate | |
| Kumar et al, ¹⁶ 2002 | 757 HN: 644 | 4.5% | 5.1% ^a | | |
| Bogdanov-Berezovsky et al, ¹⁷ 2004 | 1478 HN: 999 | 10.8% | 14% ^a | | |
| Su et al, ¹⁸ 2007 | 2582 HN: 1554 ^a | 11.2% | 13.6% ^a | | 14.5% rate for the head, 7.7% for the neck |
| Malik et al, ¹⁹ 2010 | 1832 HN: 1598 | 13.7% | 15.4% ^a | | |
| Bassas et al, ²⁰ 2011 | 921 HN: 655 ^a | 12.6% | 15.7% ^a | | 16.4% rate for the face, 10.6% for the neck and scalp |
| Betti et al, ²¹ 2011 | 3636 HN: 2092 | 9.1% | 14% (head) | | |
| Codazzi et al, ²² 2013 | 3957 HN: 3309 | 13.9% | 15.8% ^a | | |
| Gualdi et al, ²³ 2014 | 4523 HN: 2845 | 5% | 7.1% ^a | | |
| Loizate Sarrionandia et al, ²⁴ 2023 | 966 HN: 554 ^a | 17% | 21.7% - face 17.9% - neck 15.4% - scalp | | |
| Uhlman et al, ²⁵ 2024 | 765 HN: 581 | 12% | 15% | | |
| Smeets et al, ^{26b} 2004 | HN: 301 [199 (P) 102 (R)] | | 18% - (P) 32% - (R) | | |
| Kyrgidys et al, ²⁷ 2010 | HN: 1480 | | 5% | 9.1% | Recurrent tumors excluded, wide range of excision margins (2–15 mm), not stated if both lateral and deep margins were assessed |
| Girardi et al, ¹⁵ 2020 | HN: 605 | | 2.6% | 11.1% | Most tumors <1cm; vast majority of low-risk histological subtype |
| Szewczyk et al, ²⁸ 2022 | HN: 546 | | | 20.5% ^c | |
| Bozan et al, ²⁹ 2015 | HN: 154 | | 14.9% lateral: 12.3% deep: 2.6% | | |
| Dalal et al, ³⁰ 2018 | HN: 362 | | 12.4% lateral: 9.1% ^a deep: 3.3% ^a | 30.7% ^d lateral: 16% ^a deep: 14.6% ^a | |
| Our study | HN: 230 | | 6.2% lateral: 3.5% deep: 4.8% | 16.1% lateral: 7% deep: 12.6% | |

Notes: ^athe rate of positive margins in the head and neck region not stated explicitly - data extracted from tables. ^ba study comparing MMS and simple excision (SE) - only data regarding SE group are presented in Table ^cpositive margin was reported at 20.5%, whereas margin positivity was defined as margin being involved or close, which corresponds to our definition of an inadequate margin. ^dthe sum of reported rates of positive and close margins. Rates of positive and inadequate lateral margins are in bold.

Abbreviations: BCC, basal cell carcinoma; HN, head and neck; (P), primary; (R), recurrent.

margins to be compromised considerably less frequently than deep margins, with 21.4% of cases exhibiting only lateral, 42.9% only deep, and 35.7% both margin positivity. This is in contrast to most studies, which report more frequent involvement of lateral margins.^{7,22,23,29,31} Bozan et al²⁹ reported lateral vs deep margin involvement in 82.6% vs 17.4% incompletely excised lesions, respectively. Similarly, other authors^{22,23,31} reported lateral, deep, and both margin involvement in 53%-68%, 11%-20%, and 8%-32% of incomplete excisions, respectively. Thus, our findings support the beneficial role of preoperative dermoscopic assessment of lesion borders in reducing the incidence of positive lateral margins, aligning with its expected advantage of minimizing lateral rather than deep margin involvement.⁵ Regarding deep margins, while assessing deep tumor infiltration is challenging, high-frequency ultrasound could improve the future rate of uninvolved deep margins in our patients.^{1,32}

Consistent with our findings, a study of small, primary, low-aggressive BCCs⁵ comparing clinical-dermoscopic versus clinical-only preoperative evaluations found significantly fewer improper lateral margins with dermoscopy (4% vs 20%), with no significant difference in deep margin involvement (6% vs 8%). Additionally, dermoscopy led to a mean correction of +1 mm from clinically evaluated margins.⁵ The utility of dermoscopy in preoperative BCC margin evaluation was further supported by two studies by Carducci et al,^{6,9} one showing 20% vs 7% margin involvement⁶ and the other 22% vs 7% suboptimal excisions,⁹ respectively, when comparing the clinical evaluation to digital dermoscopy. A meta-analysis by Hurley et al⁸ found that dermoscopy reduced the odds of incomplete NMSC excision (OR=0.29). Moreover, a 34.5%-67% larger peripheral tumor extension has been reported with dermoscopically determined margins compared to clinical evaluation.^{33,34} Thus, preoperative dermoscopic assessment of tumor borders appears more efficient than clinical evaluation alone, reducing the incidence of incomplete excision,⁹ and has therefore been proposed as a simple, non-invasive, low-cost, and effective method for improving outcomes of standard BCC excision.^{6,9}

However, the use of dermoscopy is typically limited to dermatology departments, as reflected by lower incomplete excision rates in procedures performed by dermatologists compared to other specialties, including surgeons and general practitioners.^{11,14,35,36} Indeed, Bassas et al²⁰ found a 3.8-fold increased relative risk of positive margins following excision by non-dermatologists compared to dermatologists. Although some of these studies can be subject to selection bias, as surgeons often treat more complicated BCC cases, dermatologists' higher success rates are likely due to their expertise in the diagnosis and preoperative demarcation of tumor borders.³⁶ Conversely, surgeons' access to advanced reconstruction methods could also be a factor in reducing rates of non-radical treatments.¹⁵ One solution is to train surgeons in dermoscopy, though they would still lack the experience gained through daily practice.⁸ In our approach, multidisciplinary cooperation combines dermatologists' expertise in dermoscopic evaluation with surgeons' skills in complex reconstructions.

There is no consensus on the optimal surgical margin for high-risk BCCs when MMS is not feasible: the Polish Dermatological Society suggests a 10-mm margin,³ with smaller margins acceptable if a considerable cosmetic defect is possible,^{3,4} the European interdisciplinary guideline recommends a margin of >5 mm,¹ while the NCCN advises wider margins without specifying size.¹⁰ A meta-analysis by Quazi et al³⁷ reported complete excision rates of 94.7%, 92.2%, 90.3%, and 88.1% with 5-mm, 4-mm, 3-mm, and 2-mm margins, respectively, and suggested 3-mm margins for low-risk BCCs <2 cm, 4-6-mm margins for larger or high-risk tumors, and MMS for complex, recurrent, or ill-demarcated lesions. Cerci et al³⁸ found 96% clearance rate with 3-mm margins for BCCs smaller than 6 mm, while 6-19-mm tumors required 4-mm margins for well-defined, 5-mm margins for non-aggressive ill-defined, and 7-mm margins for aggressive tumors. In our study, among 132 with reported surgical margins, 75% were excised with 5-mm margins, 9.1% with margins <5 mm, and 15.9% with 6-10-mm margins, achieving uninvolved lateral pathological margins in 95.5% of these cases (96.5% for all lesions).

The literature has identified several factors associated with an increased risk of positive excision margins, including tumor size, location, histologic subtype, and pathological features such as perineural invasion, ulceration, inflammatory infiltration, tumor depth, poorly defined borders, and recurrence.^{15,22,35}

The median age of our patients was 77 years, higher than in most studies.^{14,19,39} While advanced age has been linked to margin positivity,²² other authors did not observe this association,^{15,35,40} consistent with our findings. Similarly, we found no association between sex and incomplete excision, in line with other reports.^{22,35,40}

In our study, recurrent tumors were significantly more likely to have positive (OR=6.4) and inadequate (OR=5.3) lateral margins compared to primary lesions. This aligns with previous studies^{12,26,39,40} and may be due to the more aggressive behavior of recurrent tumors and postoperative distortion of skin layers and scar formation, which hinder proper identification of tumor borders.^{22,40}

Importantly, BCCs with aggressive histopathological patterns are associated with deeper dermis infiltration and subclinical spread and are more likely to be incompletely excised,^{3,11,26,29,35,36,38} particularly for infiltrative and morpheiform BCCs.^{7,11,38} Filho et al³⁵ reported that aggressive subtypes increased the risk of positive margins by over 80%. Although we did not find a significant association between histological subtypes and positive margins, this difference may be due to a large number of unspecified subtypes, as reported by others.²⁸ However, high-risk subtypes were significantly associated with margin inadequacy (OR=4.3), both lateral (OR=3.5) and deep (OR=5). In our study, ulceration was associated with inadequate margins (OR = 2.3), consistent with previous reports.^{23,35} Interestingly, we found significant associations between inadequate margins and inflammatory infiltration (OR = 3.9) and elastosis (OR = 2.9), an indicator of cumulative UV-induced skin damage.⁴¹ While the influence of these factors on incomplete excision is unclear,³⁵ chronic inflammation, non-healing ulceration, and UV exposure are established risk factors in BCC carcinogenesis.^{3,4}

Lesions located in the H-zone are reported to have a significantly higher risk of incomplete excision.^{22,35} In our study, while no significant difference was found for margin positivity, H-zone lesions had significantly higher odds of inadequate deep margins (OR=4). Among facial regions, only the nose was significantly associated with deep (OR=2.7) margin inadequacy. This aligns with other studies, with the nose being the most commonly reported site of incomplete excisions.^{7,11,22,25,29–32,35,42} Other locations that have been linked to margin positivity are the periorbital^{22,25,28,29,31,32,35,42} and periauricular areas.^{11,22,35} These regions pose surgical challenges due to their proximity to critical structures and cosmetic units, the need for complex reconstructions with limited adjacent tissue, and skin thinness. Additionally, they are fusion sites of embryonic clefts.^{29,31,42} The proximity of nasal skin to cartilage poses a risk of nasal deformity when excising the deep margin, which may explain the stronger association with deep versus lateral margin inadequacy observed in our study,^{22,30,32} while another reason may be the preoperative dermoscopic assessment of the lateral tumor borders.

Regarding tumor size, Bozan et al²⁹ found more frequent margin involvement in lesions smaller than 2 cm (15% vs 42%) and identified a 9-mm diameter as most predictive of margin positivity, and Su et al¹⁸ reported tumors larger than 20 mm were twice as likely to be incompletely excised (20.4% vs 10–11%). Conversely, other studies did not find such association.³⁵ We observed positive and inadequate margins in 7.1% and 18.9% of tumors ≥ 10 mm, respectively, compared to 5.4% and 13.6% in smaller lesions, but these differences were not significant. However, these may be due to possibly wider surgical margins in larger tumors. Notably, while neither high-risk histological patterns nor tumors ≥ 1 cm were significantly associated with margin positivity when considered separately, the odds of positive deep margins were significantly higher in lesions ≥ 1 cm of high-risk subtypes (OR=5). This suggests a stronger association between tumor size and margin positivity in aggressive subtypes.

Overall, it appears that most risk factors of margin involvement are identifiable by simple clinical evaluation,²² except for the histological subtype, which requires additional assessment methods, such as dermoscopy or preoperative biopsy. While the biopsy is generally recommended, particularly for recurrent tumors and suspected high-risk subtypes,^{1,3,4,10,36,40} one should bear in mind that it may miss aggressive patterns in mixed tumors.^{35,36} This could also explain why some recurrences exhibit more aggressive growth, as the high-risk component is more likely to be incompletely excised.^{35,42}

The importance of radical BCC excision stems from the fact that margin involvement is the strongest risk factor for recurrence.^{27,28,43} Other tumor-related factors include aggressive histological type,^{27,29} as well as perinasal, periorbital, and periauricular location.^{29,31,42} Recurrences require re-excision, often involving more complex reconstruction and a higher risk of treatment failure, thereby imposing significant burdens on patients and healthcare systems.³² Kyrgidis et al²⁷ reported over 4-fold higher odds for recurrence with positive margins (13.7%, 0%, and 4% for positive, close, and negative margins, respectively). Duarte et al⁴⁰ observed recurrences in 35% of incompletely excised lesions versus 6.8% for complete excisions, while Bozan et al²⁹ reported 26.1% and 3.1% recurrence rates for positive and negative margins,

respectively. Nagore et al⁷ found recurrences in 26% and 14% of incomplete and complete excisions. Conversely, Fidelis et al³¹ found a 28.3% recurrence rate with no significant difference by margin status, however, their follow-up was limited (median 25 months). Similarly, due to the short follow-up time (median 26 months, range 12–71), the 2.8% recurrence rate we observed is likely underestimated, given a median time to recurrence of 30 months. Indeed, although some authors report that most BCC recur within 2–3 years,^{3,7,42} 5 years is typically considered a safe follow-up period,^{7,42} and even this may underestimate recurrence rates.⁴⁴ Notably, only one of three recurrences in our study was associated with a positive lateral margin at initial excision. Some tumors recur despite negative margins, possibly due to false-negative pathology.⁷ Conversely, most margin-positive lesions do not recur, and residual tumors are found in only 7–59% of re-excisions,^{19,29,31,40,42} likely due to destruction by cautery, postoperative inflammation, and cicatrization.^{5,7,29,42} Hence, there is no consensus on managing these cases: some advocate immediate reoperation, while others recommend observation for low-risk BCCs and re-excision for high-risk tumors.^{7,20,26,29,40,42} In favor of re-excision, Codazzi et al²² reported recurrence in 26.8% of incompletely excised lesions not re-excised, compared to 6% in cases with negative margins after re-excision and 5.9% in complete primary excisions. Managing positive margins requires consideration of factors such as histological subtype, tumor size, and location, burdens associated with potential recurrence, patient clinical condition, and life expectancy.^{7,42}

Our study has several limitations. Its single-center design may limit generalizability, and the retrospective nature resulted in missing data, including tumor diameter, surgical margin size, and histological subtype. As the operations were recent, most follow-up periods were too short. Also, some deep margin status was missing, and excision depth was often not reported, however, lateral margins, which are expected to be influenced by dermoscopic assessment, were recorded in all cases. Missing data and the low number of positive margins may have reduced the power to detect risk factors for margin involvement, although this was partly compensated by analyzing also inadequate margins. Since tumor diameter was derived from pathology reports, it may have been underestimated due to specimen retraction.⁴³ Moreover, standard cross-sectioning methods may have underreported margin involvement. Furthermore, the pathology reports lacked quantitative measurements of invasion depth, which may have resulted in underestimation of the tumor T-stage according to the TNM classification system. A major limitation was the lack of a control group to compare the clinical and dermoscopic evaluation of tumor borders. This was partly compensated by reviewing relevant literature. However, a prospective controlled study may better address these issues in the future.

A key strength of our study is the cooperation between dermatologists specializing in dermoscopy and head and neck surgeons skilled in advanced reconstruction, enabling us to assess the combined potential of these methods in tertiary settings with a multidisciplinary approach. Moreover, our study focused primarily on high-risk lesions, including recurrent tumors, which are often excluded or underrepresented.

Conclusion

The use of dermoscopy in preoperative assessment of tumor borders in head and neck BCC excisions resulted in a lateral margin positivity rate of 3.5%, lower than reported in the literature. Recurrent tumors, those with aggressive histological subtype, inflammatory infiltration, elastosis, ulceration, or located in the H-zone, particularly the nose, may be at higher risk for incomplete excision. Acknowledging this can enhance preoperative planning, improving assessment of tumor borders, and thus reducing unwarranted re-interventions and recurrence burdens on patients and healthcare systems. While further high-quality evidence, including RCTs and meta-analyses, is needed, we advocate for the use of dermoscopy in preoperative BCC assessment, particularly for high-risk tumors when micrographic surgery is not feasible. This method appears valuable in enhancing the evaluation of tumor margins, with the potential to reduce incomplete excision rates, improve patient outcomes, and lower healthcare costs.

Abbreviations

BCC, basal cell carcinoma; MMS, Mohs micrographic surgery; NCCN, National Comprehensive Cancer Network; EADO, European Association of Dermato-Oncology; IQR, interquartile range; OR, odds ratio; 95% CI, 95% confidence interval.

Acknowledgments

We wish to acknowledge the personnel of the Otorhinolaryngology, Dermatology, and Pathomorphology Departments at the National Medical Institute of the Ministry of Interior and Administration in Warsaw, Poland, for their invaluable contributions to the multidisciplinary management of patients with basal cell carcinoma in our institution.

Disclosure

The authors report no conflicts of interest in this work.

References

1. Peris K, Fargnoli MC, Kaufmann R, et al. European consensus-based interdisciplinary guideline for diagnosis and treatment of basal cell carcinoma—update 2023. *Eur J Cancer*. 2023;192:113254. doi:10.1016/j.ejca.2023.113254
2. Dinnes J, Deeks JJ, Chuchu N, et al. Visual inspection and dermoscopy, alone or in combination, for diagnosing keratinocyte skin cancers in adults. *Cochrane Database Syst Rev*. 2018;2018(12). doi:10.1002/14651858.CD011901.pub2
3. Lesiak A, Czuwara J, Kamińska-Winciorek G, et al. Basal cell carcinoma. Diagnostic and therapeutic recommendations of polish dermatological society. *Dermatol Rev/Przegląd Dermatologiczny*. 2019;106(2):107–126. doi:10.5114/dr.2019.85572
4. Rutkowski P, Owczarek W, Nejc D, et al. Expert recommendation on diagnostic-therapeutic management in skin carcinomas. *Oncol Clin Pract*. 2022;18(2):69–91. doi:10.5603/OCP.2021.0032
5. Herzum A, Burlando M, Tavilla PP, et al. Dermatoscopically narrowed surgical margins for head and neck basal cell carcinoma: a retrospective case-control study. *J Deutsche Derma Gesell*. 2022;20(6):807–816. doi:10.1111/ddg.14757
6. Carducci M, Bozzetti M, Foscolo AM, Betti R. Margin detection using digital dermatoscopy improves the performance of traditional surgical excision of basal cell carcinomas of the head and neck. *Dermatol Surg*. 2011;37(2):280–285. doi:10.1111/j.1524-4725.2010.01870.x
7. Nagore E, Grau C, Molinero J, Fortea J. Positive margins in basal cell carcinoma: relationship to clinical features and recurrence risk. A retrospective study of 248 patients. *Acad Dermatol Venereol*. 2003;17(2):167–170. doi:10.1046/j.1468-3083.2003.00535.x
8. Hurley AR, Totty JP, Pinder RM. Dermoscopy as an adjunct to surgical excision of nonmelanoma Skin lesions: a systematic review and Meta-analysis. *J Clin Aesthet Dermatol*. 2022;15(9):45–49.
9. Carducci M, Bozzetti M, De Marco G, Foscolo AM, Betti R. Usefulness of margin detection by digital dermoscopy in the traditional surgical excision of basal cell carcinomas of the head and neck including infiltrative/morpheaform type. *J Dermatol*. 2012;39(4):326–330. doi:10.1111/j.1346-8138.2011.01449.x
10. NCCN Clinical Practice Guidelines in Oncology (NCCN Guidelines[®]). Basal cell skin cancer. Version 3.2024. NCCN.org; 2024.
11. Kappelin J, Nielsen K, Nilsson F, Bjellerup M, Ahnide I. Surgical treatment of basal cell carcinoma: a case series on factors influencing the risk of an incomplete primary excision. *Acad Dermatol Venereol*. 2020;34(11):2518–2525. doi:10.1111/jdv.16327
12. Van Der Eerden PA, Prins MEF, Lohuis PJFM, Balm FAJM, Vuyk HD. Eighteen years of experience in Mohs micrographic surgery and conventional excision for nonmelanoma skin cancer treated by a single facial plastic surgeon and pathologist. *Laryngoscope*. 2010;120(12):2378–2384. doi:10.1002/lary.21139
13. Elder DE, Massi D, Scolyer RA, Willemze R. *WHO Classification of Skin Tumours*. 4th ed. International agency for research on cancer; 2018.
14. Nolan GS, Kiely AL, Totty JP, et al. Incomplete surgical excision of keratinocyte skin cancers: a systematic review and meta-analysis*. *Br J Dermatol*. 2021;184(6):1033–1044. doi:10.1111/bjd.19660
15. Girardi FM, Wagner VP, Martins MD, Abentroth AL, Hauth LA. Factors associated with incomplete surgical margins in basal cell carcinoma of the head and neck. *Brazilian J Otorhinolaryngol*. 2021;87(6):695–701. doi:10.1016/j.bjorl.2020.02.007
16. Kumar P, Watson S, Brain AN, et al. Incomplete excision of basal cell carcinoma: a prospective multicentre audit. *Br J Plast Surg*. 2002;55(8):616–622. doi:10.1054/bjps.2002.3948
17. Bogdanov-Berezovsky A, Cohen A, Glesinger R, Cagnano E, Krieger Y, Rosenberg L. Risk factors for incomplete excision of basal cell carcinomas. *Acta Dermato-Venerologica*. 2003;84(1):44–47. doi:10.1080/00015550310020585
18. Su SY, Giorlando F, Ek EW, Dieu T. Incomplete excision of basal cell carcinoma: a prospective trial. *Plastic Reconstructive Surg*. 2007;120(5):1240–1248. doi:10.1097/01.prs.0000279148.67766.e1
19. Malik V, Goh KS, Leong S, Tan A, Downey D, O'Donovan D. Risk and outcome analysis of 1832 consecutively excised basal cell carcinoma's in a tertiary referral plastic surgery unit. *J Plast Reconstruct Aesthetic Surg*. 2010;63(12):2057–2063. doi:10.1016/j.bjps.2010.01.016
20. Bassas P, Hilari H, Bodet D, Serra M, Kennedy FE, García-Patos V. Evaluación de los márgenes quirúrgicos del carcinoma basocelular según la especialidad del cirujano. *Actas Dermo-Sifiliográficas*. 2013;104(2):133–140. doi:10.1016/j.ad.2012.06.001
21. Betti R, Radaelli G, Crosti C, Ghiozzi S, Moneghini L, Menni S. Margin involvement and clinical pattern of basal cell carcinoma with mixed histology. *Acad Dermatol Venereol*. 2012;26(4):483–487. doi:10.1111/j.1468-3083.2011.04104.x
22. Codazzi D, Van Der Velden J, Carminati M, et al. Positive compared with negative margins in a single-centre retrospective study on 3957 consecutive excisions of basal cell carcinomas. Associated risk factors and preferred surgical management. *J Plastic Surg Hand Surg*. 2014;48(1):38–43. doi:10.3109/2000656X.2013.800526
23. Gualdi G, Monari P, Crotti S, et al. Matter of margins. *Acad Dermatol Venereol*. 2015;29(2):255–261. doi:10.1111/jdv.12504
24. Loizate Sarrionandia I, de-la-Rosa Fernández E, González Rodríguez J, et al. [Translated article] Basal cell carcinoma in the Southern Health Area of Tenerife: key clinical and pathological factors and margin status after excision. *Actas Dermo-Sifiliográficas*. 2023;114(8):T674–T679. doi:10.1016/j.ad.2023.07.009
25. Uhlman K, Bonert M, Yuen K, Farrokhyar F, Thoma A. Margin status of basal cell carcinoma: what can be done better? *J Plast Reconstruct Aesthetic Surg*. 2024;97:156–162. doi:10.1016/j.bjps.2024.07.063
26. Smeets NW, Krekels GA, Ostertag JU, et al. Surgical excision vs Mohs' micrographic surgery for basal-cell carcinoma of the face: randomised controlled trial. *Lancet*. 2004;364(9447):1766–1772. doi:10.1016/S0140-6736(04)17399-6

27. Kyrgidis A, Vahntsevanos K, Tzellos TG, et al. Clinical, histological and demographic predictors for recurrence and second primary tumours of head and neck basal cell carcinoma. A 1062 patient-cohort study from a tertiary cancer referral hospital. *Eur J Dermatol.* 2010;20(3):276–282. doi:10.1684/ejd.2010.0903
28. Szewczyk M, Marszałek A, Golusiński P, et al. Does experience of the surgeon affect surgical margins in head and neck basal cell carcinoma? *Otolaryngol Pol.* 2022;76(2):1–6. doi:10.5604/01.3001.0015.7117
29. Bozan A, Gode S, Kaya I, et al. Long-term follow-up of positive surgical margins in basal cell carcinoma of the face. *Dermatol Surg.* 2015;41(7):761–767. doi:10.1097/DSS.0000000000000394
30. Dalal AJ, Ingham J, Collard B, Merrick G. Review of outcomes of 500 consecutive cases of non-melanoma skin cancer of the head and neck managed in an oral and maxillofacial surgical unit in a district general hospital. *Br J Oral Maxillofac Surg.* 2018;56(9):805–809. doi:10.1016/j.bjoms.2018.08.015
31. Fidelis MC, Stelini RF, Staffà LP, Moraes AMD, Magalhães RF. Basal cell carcinoma with compromised margins: retrospective study of management, evolution, and prognosis. *Anais Brasileiros de Dermatologia.* 2021;96(1):17–26. doi:10.1016/j.abd.2020.11.001
32. Miyazaki S, Hoashi T, Tone Y, et al. Narrow histopathological margins are acceptable in surgical resection of basal cell carcinoma in Japanese: a single-center retrospective study. *J Nippon Med Sch.* 2024;91(3):296–306. doi:10.1272/jnms.JNMS.2024_91-308
33. Caresana G, Giardini R. Dermoscopy-guided surgery in basal cell carcinoma. *Acad Dermatol Venereol.* 2010;24(12):1395–1399. doi:10.1111/j.1468-3083.2010.03652.x
34. Conforti C, Giuffrida R, Zalaudek I, et al. Dermoscopic findings in the presurgical evaluation of basal cell carcinoma. a prospective study. *Dermatol Surg.* 2021;47(2):e37–e41. doi:10.1097/DSS.0000000000002471
35. Filho RB, De Carvalho Fantini B, Dos Santos CA, et al. Attributes and risk factors of positive margins on 864 excisions of basal cell carcinomas: a single-center retrospective study. *J Dermatol Treat.* 2020;31(6):589–596. doi:10.1080/09546634.2019.1695724
36. Ramdas K, van Lee C, Beck S, et al. Differences in rate of complete excision of basal cell carcinoma by dermatologists, plastic surgeons and general practitioners: a large cross-sectional study. *Dermatology.* 2018;234(3–4):86–91. doi:10.1159/000490344
37. Quazi SJ, Aslam N, Saleem H, Rahman J, Khan S. Surgical margin of excision in basal cell carcinoma: a systematic review of literature. *Cureus.* 2020. doi:10.7759/cureus.9211
38. Cerci FB, Kubo EM, Werner B, Tolkachjov SN. Surgical margins required for basal cell carcinomas treated with Mohs micrographic surgery according to tumor features. *J Am Acad Dermatol.* 2020;83(2):493–500. doi:10.1016/j.jaad.2020.04.008
39. Alsaif A, Hayre A, Karam M, Rahman S, Abdul Z, Matteucci P. Mohs micrographic surgery versus standard excision for basal cell carcinoma in the head and neck: systematic review and meta-analysis. *Cureus.* 2021. doi:10.7759/cureus.19981
40. Duarte B, Vieira L, Pessoa E Costa T, et al. Predicting incomplete basal cell carcinoma excisions – a large multidisciplinary retrospective analysis in a tertiary center. *J Dermatol Treat.* 2020;31(6):583–588. doi:10.1080/09546634.2019.1687815
41. Butacu AI, Wittlich M, John SM, et al. Is occupational skin cancer more aggressive than sporadic skin cancer? *Maedica.* 2020;15(2). doi:10.26574/maedica.2020.15.2.155
42. Lara F, Santamaría JR, Garbers LEFDM. Universidade Federal do Paraná, Brazil, Faculdade Evangélica do Paraná, Brazil. Recurrence rate of basal cell carcinoma with positive histopathological margins and related risk factors. *An Bras Dermatol.* 2017;92(1):58–62. doi:10.1590/abd1806-4841.20174867
43. Sevray M, Brenaut E, Grangier Y, Misery L, Poizeau F, Staroz F. Retraction of cutaneous specimens: tumours and margins after surgical excision. *J Clin Pathol.* 2020;73(1):42–46. doi:10.1136/jclinpath-2019-205988
44. Van Loo E, Mosterd K, Krekels GAM, et al. Surgical excision versus Mohs' micrographic surgery for basal cell carcinoma of the face: a randomised clinical trial with 10 year follow-up. *Eur J Cancer.* 2014;50(17):3011–3020. doi:10.1016/j.ejca.2014.08.018

Cancer Management and Research

Publish your work in this journal

Cancer Management and Research is an international, peer-reviewed open access journal focusing on cancer research and the optimal use of preventative and integrated treatment interventions to achieve improved outcomes, enhanced survival and quality of life for the cancer patient. The manuscript management system is completely online and includes a very quick and fair peer-review system, which is all easy to use. Visit <http://www.dovepress.com/testimonials.php> to read real quotes from published authors.

Submit your manuscript here: <https://www.dovepress.com/cancer-management-and-research-journal>

Dovepress
Taylor & Francis Group