

A Case Report of Eosinophilic Enteritis Complicated with *Klebsiella Pneumoniae* Infection in a Chinese Male

Hengzhong Lun^{1,*}, Shujing Sui^{2,*}, Zhijun Zhang¹, Meijie Jiang¹

¹Department of Laboratory Medicine, The Affiliated Tai'an City Central Hospital of Qingdao University, Tai'an, 271000, People's Republic of China;

²Department of Gastroenterology, The Affiliated Taian City Central Hospital of Qingdao University, Tai'an, 271000, People's Republic of China

*These authors contributed equally to this work

Correspondence: Zhijun Zhang; Meijie Jiang, The Affiliated Tai'an City Central Hospital of Qingdao University, Tai'an, Shandong, People's Republic of China, Email ghwtzj@qdu.edu.cn; xtingw@126.com

Abstract: Eosinophilic gastrointestinal diseases (EGIDs) are chronic, progressive, immune-mediated inflammatory conditions. Its delayed diagnosis and treatment are often due to the lack of specific clinical manifestations. *Klebsiella pneumoniae* is usually considered normal flora of the gut and rarely causes intestinal infections. In this case report, we present a rare case of intestinal mucosal exfoliation associated with *K. pneumoniae* infection following eosinophilic enteritis, which was cured by intravenous levofloxacin and oral prednisone acetate and montelukast. This case highlights the importance of considering these conditions in patients presenting with clinical diarrhea when the cause of the disease can not be found and enhancing disease understanding.

Keywords: eosinophilic gastrointestinal, *klebsiella pneumoniae*, intestinal infection, diarrhea

Introduction

The digestive tract of the human body is lined with mucosa, serving as the first line of defense against the invasion of harmful substances. Studies have shown that antibiotics, bacteria, etc. can damage the mucosal barrier, affect the integrity of the intestinal mucosa, and increase the risk of intestinal infections.^{1,2} *Klebsiella pneumoniae* is a part of normal intestinal flora, but it can cause intestinal infection in some cases. When the body's immunity declines, long-term use of antibiotics leads to flora imbalance or intestinal mucosal barrier function is damaged, *K.pneumonia* may overproduce and invade intestinal mucosa, thus causing infection. Some strains of *Klebsiella pneumoniae* can express relevant adhesion factors through adhesion genes, enabling them to attach to the intestinal mucosal surface, which is a key step in their colonization and pathogenesis. After adhesion, it may cause intestinal pathological changes, such as inducing inflammatory responses in the intestinal mucosa, promoting inflammatory cell infiltration, releasing inflammatory factors, damaging the integrity of the intestinal mucosal barrier, and leading to symptoms like diarrhea and abdominal pain.

Eosinophilic enteritis is an intestinal disease characterized by eosinophil infiltration in the intestine. The etiology is not clear, which may be related to allergic reaction, immune abnormality and genetic factors.

This paper presents a rare case of intestinal mucosal exfoliation associated with *K. pneumoniae* infection following eosinophilic enteritis. The infecting *K. pneumoniae* strain exhibited an abundance of genes associated with adhesion function, suggesting that the adhesive capacity of *K. pneumoniae* may contribute significantly to intestinal infection.

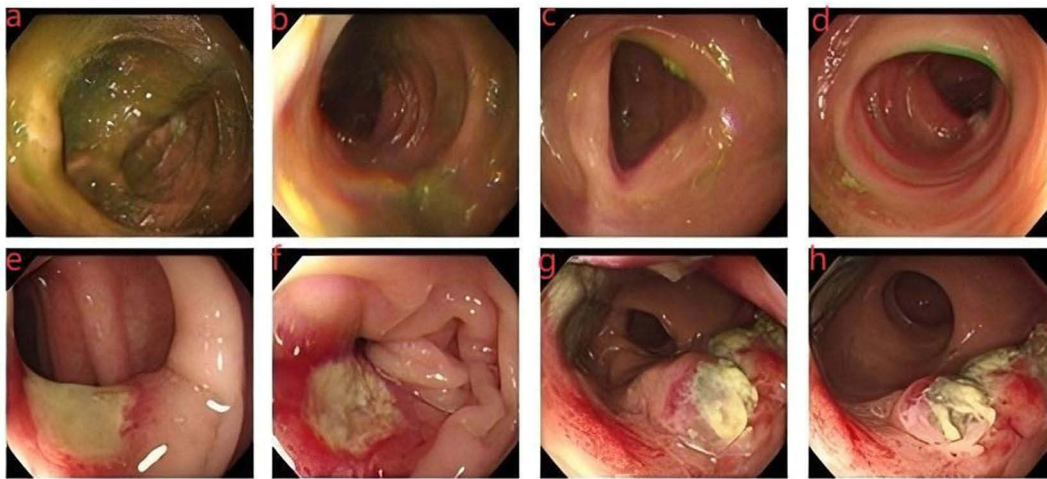


Figure 1 Gastrointestinal endoscopy results. (a) ileocecal region. (b) ascending colon. (c) transverse colon. (d) descending colon. (e and f) sigmoid colon. (g and h) rectum.

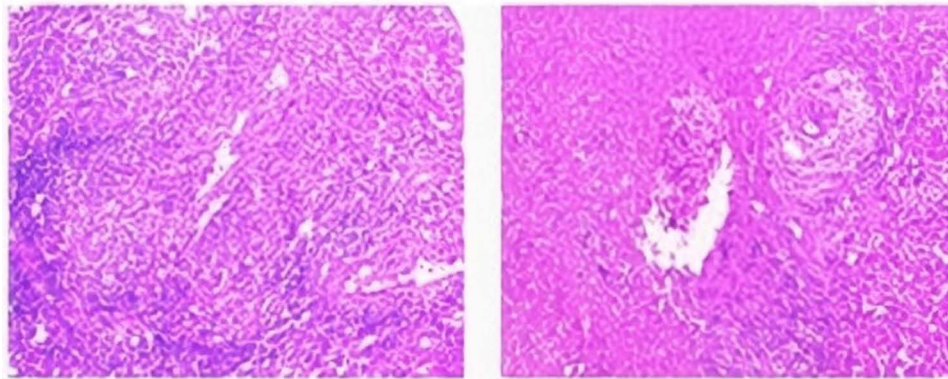


Figure 2 Pathological examination results.

Case Report

Case Presentation

An 80-year-old man presented to our hospital with recent episodes of vomiting, abdominal distension and pain, and occasional diarrhea. The patient had a history of asthma for over 30 years, with no other medical conditions. Upon presentation, his temperature measured 36.3°C, his heart rate was 108 beats/min, and his blood pressure was 117/69 mmHg. Physical examination revealed mild compression pain in the middle and lower abdomen without rebound tenderness and no palpable abdominal mass. Blood routine examination showed a white blood cell count of $30.11 \times 10^9/L$, with an eosinophil count of $19.74 \times 10^9/L$, representing 65.60% of total white blood cells. Gastrointestinal endoscopy was conducted and revealed ulcerative inflammatory changes in the sigmoid colon and rectum (Figure 1). Pathology samples were obtained via biopsy during colonoscopy.

Establishing the Diagnosis

Routine pathological examination disclosed multiple gastric fundus gland polyps in the gastric body and moderate chronic inflammation of the mucosa with necrosis and granulation tissue proliferation, rated as active (++) in the descending part of the duodenum. In the sigmoid colon, the examination revealed moderate chronic inflammation of the mucosa with active necrosis and granulation tissue proliferation, graded as (+++), accompanied by bacterial colonies indicative of ulcer formation. Eosinophils were sparsely distributed in the interstitium, with approximately 5

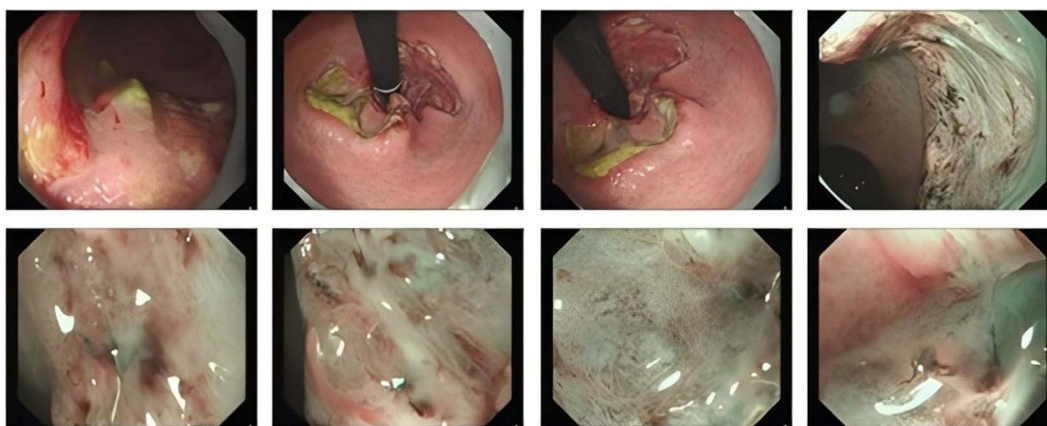


Figure 3 Second colonoscopy results Each unit in the picture represents the rectum.

to 20 eosinophils per high-power field (HPF). The rectal mucosa exhibited moderate chronic inflammation with active necrosis and granulation tissue proliferation, rated as (+++), alongside bacterial colonies suggestive of ulceration. Eosinophils were scant in the stroma, ranging from 1 to 5 eosinophils per HPF, with more prominent eosinophilic infiltrates in the lamina propria, involving focal glandular regions, with counts ranging from approximately 5 to 70 eosinophils per HPF (Figure 2). Following the detection of bacterial colonies in the pathological examination, a repeat colonoscopy was performed (Figure 3). The collected samples were cultured and isolated by streak plate method, and identified by microbial mass spectrometer, which showed *K. pneumoniae*. The antibiotic sensitivity test was performed using the minimum inhibitory concentration (MIC) method, and the results were determined according to the CLSI (Clinical and Laboratory Standards Institute) criteria (Table 1). Based on the patient's clinical presentation and the findings of various investigations, a diagnosis of eosinophilic enteritis concomitant with *K. pneumoniae* infection was established.

Result

Patient Outcome

The patient received intravenous levofloxacin and oral prednisone acetate and montelukast. His symptoms improved significantly, and his eosinophil count gradually normalized. A follow-up colonoscopy was conducted and indicated resolution of the lesion (Figure 4), leading to the patient's discharge.

Table 1 Antibiotic Sensitivity Test results

Antibiotic	MIC	KB	Break Point	Sensitivity	Antibiotic	MIC	K B	Break Point	Sensitivity
Ampicillin/sulbactam	≤8/4		≤8; ≥32	S	Tobramycin	≤4		≤4; ≥16	S
Amikacin	≤16		≤16; ≥64	S	Trimethoprim/sulfanilamide	≤2		≤2; ≥4	S
Aztreonam	≤4		≤4; ≥16	S	Cefepime		28	≤18; ≥25	S
Ceftriaxone	≤1		≤1; ≥4	S	Ertapenem		27	≤18; ≥22	S
Ceftazidime	≤1		≤4; ≥16	S	Cefotaxime		26	≤22; ≥26	S
Cefoxitin	≤8		≤8; ≥32	S	Levofloxacin		23	≤16; ≥21	S
Cefuroxime	≤4		≤8; ≥32	S	Ciprofloxacin		26	≤21; ≥26	S
Gentamicin	≤4		≤4; ≥16	S	Amoxicillin/clavulante		23	≤13; ≥18	S
Imipenem	≤1		≤1; ≥4	S	Piperacillin/tazobactam		26	≤20; ≥25	S
Tigecycline	≤2		≤2; ≥8	S	Cefoperazone/sulbactam		25	≤15; ≥21	S
Meropenem	≤1		≤1; ≥4	S	Cefazolin		23	≤19; ≥23	S

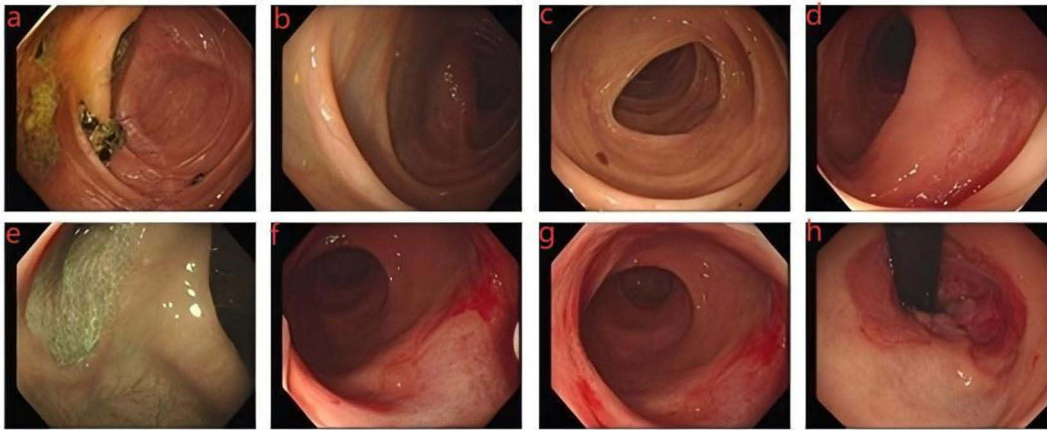


Figure 4 Enteroscopy results after treatment. (a) ileocecal region. (b) hepatic flexure of colon. (c) transverse colon. (d and e) sigmoid colon. (f–h) rectum.

Sequence results of *Klebsiella Pneumoniae*

K. pneumoniae, as a colonized bacterium in the intestinal tract, rarely causes intestinal infection. In order to investigate the mechanism of *K. pneumoniae* intestinal infection in this case, whole genome sequencing was performed on the *K. pneumoniae* strain isolated from the patient. The genomic DNA of strain *K. pneumoniae* was extracted using Bacteria DNA Kit and the sample was sequenced by the Illumina NovaSeq 6000 platform. We used Unicycler v0.4.8 to perform genome assembly with default parameters. All gene models were blastp against non-redundant databases, SwissProt, KEGG, and COG to do functional annotation by blastp module. Sequencing analysis indicated that while this strain of *K. pneumoniae* was not highly virulent, it harbored a large number of genes associated with adhesion function among its virulence factors (Figures 5 and 6). These genes related to adhesion function may cause *K. pneumoniae* to gather on the surface of the ulcer, which leads to intestinal infection when the body's immunity is low.

Discussion

Eosinophilic gastrointestinal diseases are chronic, progressive, immune-mediated inflammatory conditions that can affect the esophagus, stomach, small bowel, and/or colon.^{3,4} Due to the rarity of eosinophilic enteritis, nonspecific clinical manifestations, and limited clinician awareness, misdiagnosis and underdiagnosis rates are high. The treatment of eosinophilic enteritis is mainly medical treatment, avoiding suspicious allergic food or drugs, and glucocorticoid is the first choice for treatment at present.

The human intestinal flora is a very complex ecosystem, which consists of more than 1200 species, including bacteria, fungi and so on.⁵ Studies on intestinal colonization of healthy adults in Asian countries show that the total colonization rate of *K. pneumoniae* even exceeds 60%.⁶ Our study believes that the *K. pneumoniae* is a pathogenic bacterium rather than a colonized bacterium because a large number of bacteria are seen in histopathology, and it is *K. pneumoniae* after culture. While *K. pneumoniae* infections commonly affect the bloodstream, respiratory tract, and urinary system, intestinal infections are less frequent. The pathogenesis of *K. pneumoniae* infection remains unclear. However, studies suggest a role for adhesion-related genes in its pathogenicity.⁷ In this case, the infecting *K. pneumoniae* strain exhibited an abundance of genes associated with adhesion function, suggesting that the adhesive capacity of *K. pneumoniae* may contribute significantly to intestinal infection.

Conclusion

This case will help clinicians to realize the possible correlation or coexistence of these two diseases, expand their understanding of the disease spectrum and avoid missed diagnosis or misdiagnosis. In addition, it will remind doctors to take into account atypical disease combinations when encountering similar cases, and conduct comprehensive examination and comprehensive judgment.

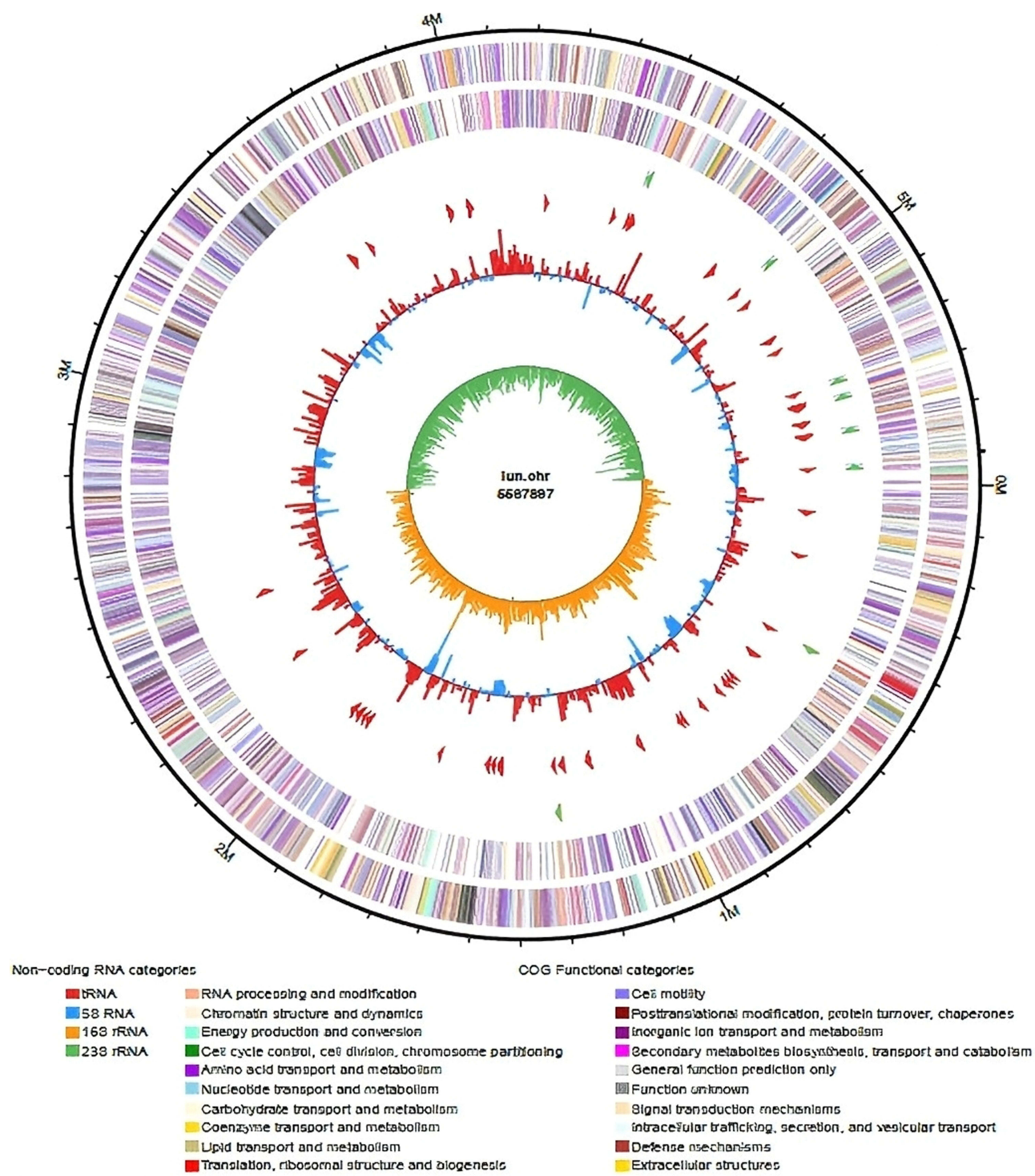


Figure 5 Whole genome sequencing diagram of *K. pneumoniae*.

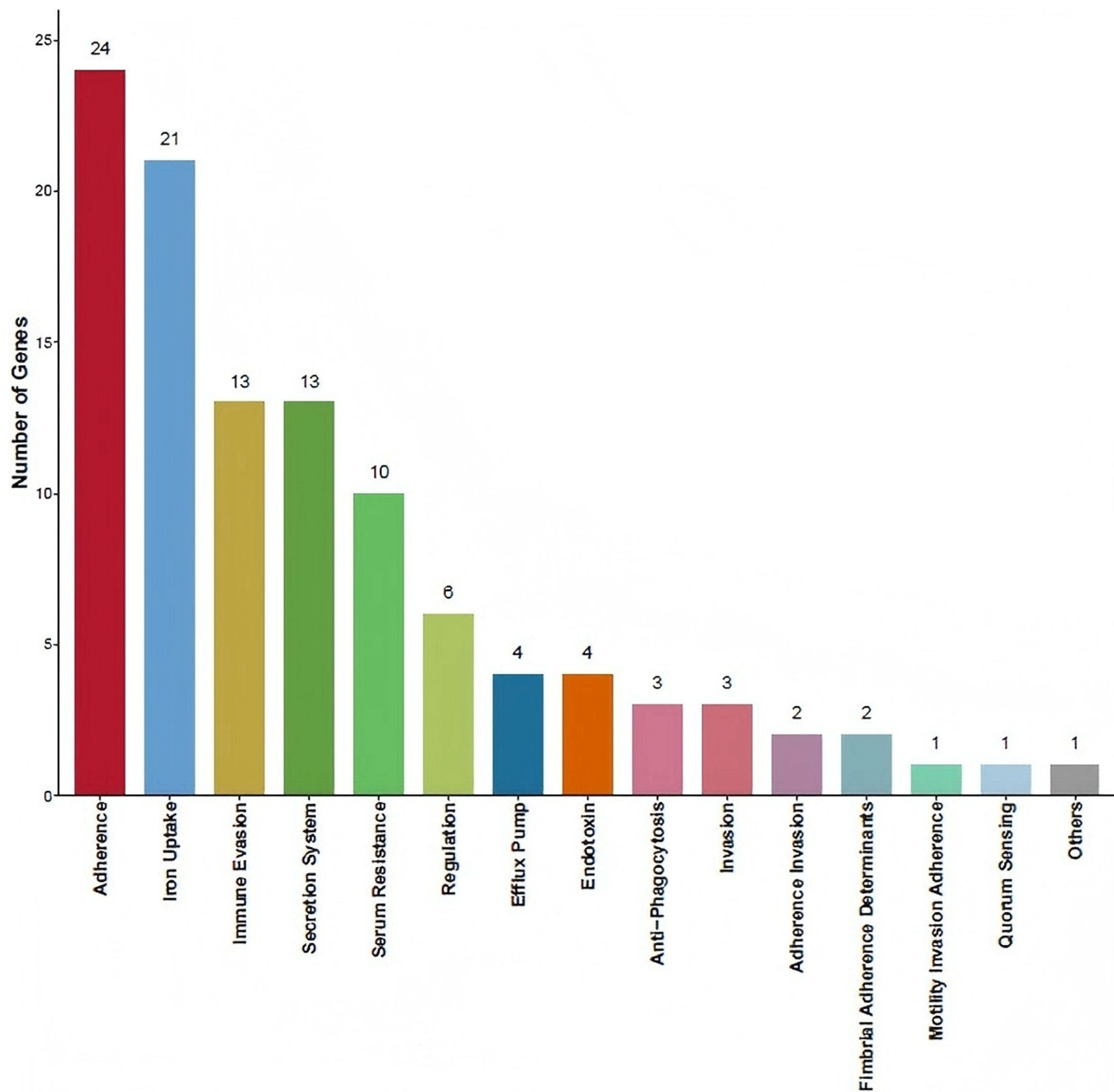


Figure 6 Classification statistics of virulence factor. Note: The X-axis represents the type of toxicity factor classification, and the Y-axis indicates the number annotated for each type.

Ethical Approval

Approval was not required.

Acknowledgments

We would like to acknowledge the patient and his family, who provided their informed consent for this publication.

Funding

No funding was received from any public, commercial, or non-profit organization for this research.

Disclosure

The authors declare that they have no known competing financial interests or personal relationships that could have appeared to influence the work reported in this paper.

References

1. Jasmin S, Lilach Z, Yehonatan L, et al. Antibiotics damage the colonic mucus barrier in a microbiota-independent manner. *Sci Adv.* 2024;10(37). doi:10.1126/sciadv.adp4119
2. Julie LM, Sara KL, Chin Wen P, et al. MUC1 cell surface mucin is a critical element of the mucosal barrier to infection. *J Clin Invest.* 2007;117(8). doi:10.1172/jci26705
3. Evan SD, Nirmala G, A JP, et al. International consensus recommendations for eosinophilic gastrointestinal disease nomenclature. *Clin Gastroenterol Hepatol.* 2022;20(11). doi:10.1016/j.cgh.2022.02.017
4. Monica S, Kathryn A, Amiko P&, M U. Eosinophilic gastrointestinal disease. *JAMA.* 2024;331. doi:10.1001/jama.2024.2143.
5. Bjoern OS, Fredrik B. Signals from the gut microbiota to distant organs in physiology and disease. *Nat Med.* 2016;22(10). doi:10.1038/nm.4185
6. Yi-Tsung L, Kristopher S, Jung-Chung L, et al. Seroepidemiology of klebsiella pneumoniae colonizing the intestinal tract of healthy Chinese and overseas Chinese adults in Asian countries. *BMC Microbiol.* 2012;12. doi:10.1186/1471-2180-12-13
7. Qianjin Z, Xiaomin S, Chunze Z, et al. Klebsiella pneumoniae induces inflammatory bowel disease through caspase-11-mediated IL18 in the gut epithelial cells. *Cell Mol Gastroenterol Hepatol.* 2022;15(3). doi:10.1016/j.jcmgh.2022.11.005

Infection and Drug Resistance

Publish your work in this journal

Infection and Drug Resistance is an international, peer-reviewed open-access journal that focuses on the optimal treatment of infection (bacterial, fungal and viral) and the development and institution of preventive strategies to minimize the development and spread of resistance. The journal is specifically concerned with the epidemiology of antibiotic resistance and the mechanisms of resistance development and diffusion in both hospitals and the community. The manuscript management system is completely online and includes a very quick and fair peer-review system, which is all easy to use. Visit <http://www.dovepress.com/testimonials.php> to read real quotes from published authors.

Submit your manuscript here: <https://www.dovepress.com/infection-and-drug-resistance-journal>

Dovepress
Taylor & Francis Group