

# Retinal Microangiopathy as a Marker of Coronary Atherosclerotic Heart Disease

Xinyu Wang<sup>1,2</sup>, Hui Zhang<sup>3</sup>, Hui Lu<sup>1</sup>, Baixue Zhang<sup>2,3</sup>, Bo Li<sup>3</sup>, Lifan Gao<sup>1</sup>

<sup>1</sup>Department of Ophthalmology, Zibo Central Hospital, Zibo, Shandong Province, 255000, People's Republic of China; <sup>2</sup>Shandong Second Medical University, Weifang City, Shandong Province, 261053, People's Republic of China; <sup>3</sup>Department of Cardiology, Zibo Central Hospital, Zibo, Shandong Province, 255000, People's Republic of China

Correspondence: Bo Li; Lifan Gao, Email bolidoc@163.com; Gaolifen1971@163.com

**Abstract:** Coronary atherosclerotic heart disease is the main cause of death worldwide. This disease is characterized by the formation of atherosclerotic plaque in the heart artery and the reduction of myocardial blood circulation caused by vasospasm. The risk factors of atherosclerosis include old age, dyslipidemia, hypertension, and diabetes. Research has shown that coronary heart disease not only causes kidney and cerebrovascular diseases, but also leads to dysfunction and structural changes in the retinal microvasculature of the eye. Therefore, several studies have proposed that retinal microvascular changes can be used as a diagnostic tool to assess coronary heart disease course and prognosis. This article will review the mechanism of retinal microvascular disease, retinal vascular morphological changes, and microvascular density changes related to coronary atherosclerotic heart disease.

**Keywords:** coronary heart disease, retinal microvasculature, retinal arteriovenous ratio, OCTA, retinal vessel density

## Background

Coronary atherosclerotic heart disease has a high incidence rate and mortality rate worldwide.<sup>1</sup> Coronary heart disease (CHD) is characterized by the formation of atherosclerotic plaque in the heart artery and the reduction of myocardial blood circulation caused by vasospasm.<sup>2</sup> Recent studies believe that inflammation plays an important role in all stages of atherosclerosis. When vascular endothelial cells encounter certain antigenic substances or risk factors, such as dyslipidemia, vasoconstrictor hormone in hypertension, glucose oxidation products, or excessive inflammatory cytokines from adipose tissue, they will secrete factors that promote leukocyte adhesion, leading to vascular endothelial cell damage, smooth muscle cell migration, and ultimately atherosclerosis.<sup>3</sup> Atherosclerosis, as a chronic arterial inflammation that can affect the whole body, causes structural changes and dysfunction of microvessels while affecting the function of large arteries, leading to retinal microvascular disease, renal failure, and small vascular encephalopathy.<sup>4,5</sup> Research has shown that patients with coronary microvascular disease have significantly increased mortality rates and an increased incidence of cardiovascular adverse events.<sup>6</sup> Seidelmann et al found that the CHD population with narrowed retinal arterioles and widened retinal venules has a higher mortality rate.<sup>7,8</sup> The retina is the only location where microcirculation can be non-invasively imaged in vivo and can be a pathway to make non-invasive analysis in blood vessels.<sup>9,10</sup> In recent years, with the continuous exploration of the functional and structural changes of retinal microvessels in patients with CHD, it is of great significance to understand the changes in retinal function and structure during the progression of CHD, and to predict adverse phenomena in patients before it occurs.

## Retina as a Window to Evaluate Microvascular Changes in Body

The central retinal artery which is the first branch of the ophthalmic artery and appears on the surface of the optic nerve papilla. The central retinal artery first divides into four arteries and then they gradually form precapillary arterioles, and finally form capillaries. Small arteries and arterioles are characterized by a relatively thick layer of vascular smooth muscle cells depending on the distance to the optic nerve. Capillaries are divided into 2 layers: the superficial vascular

plexus (SVP) located in the nerve fiber and the ganglion cell layer; and the deep capillary plexus (DCP) which lies in the inner nuclear layer. Within the range of 0.4–0.5mm around the fovea, there is an avascular area.<sup>11</sup> Radial peripapillary capillaries (RPC) are retinal capillaries that radiate from the optic nerve and supply retinal nerve fibers around the optic nerve head.<sup>12</sup> Retinal capillaries are mainly composed of endothelial cells, intramural pericytes, and basement membrane. Endothelial cells are located on the inner side of the capillary wall and are tightly connected, forming the internal barrier of the retina, also known as the blood retina barrier.<sup>13</sup> Retinal veins are generally accompanied with arteries. The five layers of the retina and the optic nerve papilla flow back through the central retinal vein.

On the one hand, the blood flow supply to the retina needs to compensate for microcirculatory changes caused by press such as intraocular pressure changes. On the other hand, it needs to quickly generate changes according to the needs of the retina itself.<sup>10</sup> The retinal blood flow which lacks neural control can be autoregulated in response to changes by intraocular pressure elevations. When the intraocular pressure changes, changes in the diameter of the retinal blood vessel lumens under control of myogenic and metabolic mechanisms will happen.<sup>14</sup> Retinal blood flow regulation which retinal endothelial cells take part in is mainly controlled by metabolic autoregulation to keep stable.<sup>15</sup> The retinal flow change is influenced by the local mediators like adenosine, nitric oxide (NO), and endothelin-1, which can make an effect of vasoconstriction and vasodilation.<sup>16</sup> In addition, the retina as the highest oxygen consumption per volume in the whole body. The retinal blood flow is sensitive to changes in O<sub>2</sub> and CO<sub>2</sub>. High level of O<sub>2</sub> can cause a decrease in retinal diameter in order to avoid the damage of reactive oxygen species.<sup>17</sup> And high level of CO<sub>2</sub> in blood can make retinal vessel diameter increasing so that enough oxygen and nutrition can be transported to retina quickly.<sup>18</sup>

## Methods for Retinal Vascular Assessment

There are many methods to assess the retinal vascular changes and each of them has own emphasis. Combining multiple evaluation methods can more accurately and comprehensively assess eye blood flow.

### Retinal Photography

In the many researches, retinal photography can be the common method to evaluate changes of retinal vessel. By using software like Retinal Analysis (RA) and Integrative Vessel Analysis (IVAN), researches can collect arteriolar and venular caliber from retinal photography and central retinal arteriolar (CRAE) and venular equivalents (CRVE) can be calculated.<sup>19</sup> And The CRAE and CRVE are used to calculate the retinal arteriolar-to-venular diameter ratio (AVR). The other software like Singapore I Vessel Assessment (SIVA) and VAMPIRE can also detects additional geometry parameters (branching, bifurcation, tortuosity) to get extra parameters to analyze early retinal vessel damage.<sup>20,21</sup>

### Optical Coherence Tomography Angiography (OCTA)

OCTA is a novel non-invasive retinal imaging technique that can directly evaluate microvascular density by capturing red blood cell movement signals. It can measure foveal avascular zone (FAZ) area that stands for the irregular central fovea avascular area in macula. And it can quantify superficial and deep vascular density in the macula and optic disc microvascular density, and nerve thickness with advantages of being fast, non-invasive, and repeatable to detect easily of microvascular changes.<sup>22</sup> This method can also be used to measure the diameter of retinal blood vessels, but studies have found that the diameter of retinal blood vessels measured by OCTA is larger than that measured by fundus photographs.<sup>23</sup> Furthermore, the image quality of OCTA is also affected by refractive interstitial opacity and low compatibility of patients, making it different degree of error.

### Fluorescein Angiography

Fundus angiography is an examination method that uses a special fundus camera to dynamically observe the circulation status of retinal blood vessels after intravenous injection of fluorescent contrast agents.<sup>24</sup> It is the gold standard for patients to assess retinal circulation, which can help make diagnosis by providing key evidence.<sup>25</sup> But at the same time, there are also complicated inspection processes, long inspection times, and limitations due to allergic reactions.

## The Mechanism of Retinal Microangiopathy Affected by CHD

Atherosclerosis as an inflammatory chronic condition is known as the most important cause of coronary heart disease.<sup>26</sup> Arteriosclerosis can lead to increased blood flow resistance and decreased perfusion, resulting in retinal ischemia. Atherosclerotic lesions can lead to various changes in vascular structure, such as intimal thickening and medial wall hyperplasia.<sup>11</sup> Atherosclerosis risk factors such as diabetes, old age, smoking, hyperlipidemia, and hypertension can lead to systemic inflammation and vascular oxidative stress, resulting in coronary artery dysfunction and microvascular damage.<sup>27,28</sup> Elevated levels of inflammatory biomarkers like C-reactive protein (CRP) play a crucial role in atherosclerosis. CRP is associated with endothelial dysfunction by upregulating ICAM-1, VCAM-1, and nuclear factor- $\kappa$ B, which can facilitate the leukocyte-endothelial interaction.<sup>29-31</sup> The other inflammatory biomarkers interleukin-6, tumor necrosis factor- $\alpha$ , interleukin-1, and interleukin-8 are involved in leukocyte recruitment and endothelial activation, exacerbating atherosclerotic processes and promoting plaque instability to cause endothelial dysfunction.<sup>32</sup> Endothelial dysfunction can cause microvascular pathogenic functional and structural changes including vessel functional reducing, structural remodeling, and local tissue hypoxia.<sup>10,33,34</sup> In terms of mechanism, endothelial cell damage will lead to the attachment of inflammatory cells, the release of a large number of inflammatory factors, the migration of monocytes and macrophages, and the absorption of oxidized low-density lipoprotein cholesterol (LDL-C) in the blood to form foam cells. These cells will further promote the progress of inflammation level during the activation process, further leading to vascular endothelial dysfunction.<sup>35,36</sup>

Some studies suggest that inflammation is the key of the pathogenesis of cardiovascular diseases. The arterial and venous vessels undergo functional and structural changes in response to inflammation, leading to an increased risk of cardiovascular disease events.<sup>33-37</sup> Leticia et al examined systemic arteries such as femoral artery, carotid artery, and iliac artery in patients with CHD, and found that patients with arterial inflammation had higher plaque burden.<sup>38</sup> Aruna et al found that CHD patients have a high recurrence rate of cardiovascular events due to sustained elevation of high sensitivity C-reactive protein levels.<sup>39</sup> In addition, Paul et al treated CHD patients with a history of myocardial infarction by anti-inflammatory monoclonal antibody canakinumab. They found that the level of interleukin-10 was significantly inhibited and the probability of cardiovascular adverse events has been reduced.<sup>40</sup> The microvascular structures of coronary arteries and retinal vessels are similar, both being diameter less than 500  $\mu$ m and located in the same internal environment.<sup>41</sup> Liu et al summarized multiple research findings to find that there is a significant correlation between widening of retinal venules and increased levels of inflammatory markers such as C-reactive protein and white blood cell count in patients with CHD.<sup>33</sup> Some studies reported associations between interleukin-6 and venular caliber not arteriolar caliber.<sup>42,43</sup> Hannappe et al found that macular microvasculature in patients with acute coronary syndrome has a significant decrease in vessel length and density compared to healthy individuals, which is significant correlation with inflammatory biomarkers as angiopoietin-2.<sup>44</sup> Al Fiadh et al investigated the relationship between retinal microvascular endothelial function and CHD. They evaluated the retinal microvascular endothelial function of healthy individuals and patients with CHD by measuring the dilation of retinal arterioles and venules to flicker light. After adjusting for age, gender, cardiovascular risk factors, and drugs, they found that the ability of retinal arterioles to dilate in response to flicker light is an independent predictor of CHD and retinal endothelial dysfunction occurred affected by CHD.<sup>45</sup> The above evidence shows that coronary atherosclerosis will lead to coronary artery and retinal microvascular disease.

## Morphological Changes of Retinal Vessels Associated with CHD

Retinal vascular diameter is affected by many cardiovascular factors, including atherosclerosis, inflammation, hypertension, hyperglycemia, and hyperlipidemia.<sup>46</sup> The active substances secreted by endothelial cells, such as endothelium and nitric oxide, play a major role in vascular contraction and relaxation. However, as coronary heart disease progresses, endothelial function is impaired, and the balance of vascular contraction and relaxation factors cannot be maintained, resulting in a decrease in the inner diameter, outer diameter, and cross-sectional area of retinal arteries.<sup>47</sup> In recent years, many studies have shown that the structure dysfunction of the retinal vascular system, such as narrowing arteriole, widening venule, decreased arteriovenous ratio, and changes on vascular tortuosity are associated with cardiovascular disease.<sup>48</sup>

The retinal microvascular geometry parameters are mathematical ways that quantifies retinal microvascular network.<sup>49</sup> The changes in geometry parameters of retinal blood vessels may be related to different cardiovascular risk factors including age, gender, diabetes, hyperlipidemia, smoking, obesity, and acute cardiovascular events. Owen et al used a fully automated

validated computerized system to analyze retinal blood vessels, which found that increased curvature of retinal venules was related to higher body mass index and type 2 diabetes. In addition, the widening retinal venules were related to old age, abnormally high triglycerides and smoking history. Meanwhile, increased curvature of retinal arterioles is associated with old age and elevated systolic blood pressure, while narrowing retinal artery is correlated with elevated total cholesterol levels.<sup>50</sup> Wang et al collected retinal photographs of CHD patients by using a semi-automatic software to analyze the parameters such as fractal dimension and diameter of retinal blood vessels and they found that the decreased fractal dimension of retinal blood vessels was related to the severity of coronary heart disease and female gender.<sup>51</sup> Carol et al's study also reached this conclusion, but at the same time proposed that retinal small artery tortuosity is associated with higher BMI levels, while small vein tortuosity is also associated with lower high-density lipoprotein levels.<sup>52</sup> At same time, physical exercise, the protective factor in CHD, is found can make increasing of fractal dimension.<sup>53</sup> This may be related to the fact that exercise can increase blood pressure and cardiac blood flow.<sup>54</sup> Meanwhile, changes in left ventricular contract and diastolic function were also associated with tortuosity index, which have different conclusion in several researches.<sup>55,56</sup>

Multiple studies have found that narrowing retinal arterioles and widening retinal venules are associated with mortality in cardiovascular disease.<sup>7,57</sup> In the diagnosis of hypertensive retinopathy, changes in the diameter of retinal arterioles are an important indicator.<sup>58</sup> Matthias et al found that compared patients with chronic heart failure to healthy individuals, flicker induced retinal arteriolar dilation (FIDart), which can be used to assess retinal microvascular function was significantly reduced.<sup>59</sup> Xu et al used SD-OCT to measure retinal arterial outer diameter in CHD patients, and found that retinal arterial outer diameter decreased compared to health controls, which are negatively related to the severity of ischemic heart disease.<sup>60</sup> Wang et al collected patients with abnormal blood pressure to measure the diameters of retinal arterioles and venules by using retinal photographs, and assessed the severity of coronary heart disease by using the Gensini score. They found that compared to health controls, patients had significantly narrowing retinal arterioles, but no significant difference in SYNTAX score of retinal venules.<sup>61</sup> Many studies have found the significant correlation between the degree of retinal atherosclerosis assessed by fundus photography and severity of coronary heart disease by Gensini score and SYNTAX score.<sup>62,63</sup> The changes were not only found in the old. In adolescents with blood lipid abnormalities aged 12 and above, compared with healthy controls, central retinal arteriolar equivalent was significantly narrowed, which was related to the increase of triglycerides, total cholesterol, low-density lipoprotein cholesterol, and apolipoprotein.<sup>64</sup> At the same time, some studies also found that the arteriovenous ratio increased, the diameter of venules decreased and the diameter of arterioles increased when CHD patients treated by lipid control drugs, such as simvastatin and rosuvastatin. It indicates that the retinal vascular function can be significantly improved after adjusting blood lipids, which may be explained by the decreasing LDL-C and controlled pathological reactions such as thrombotic reaction of atherosclerosis.<sup>65,66</sup>

At present, it is believed that changes in retinal venules diameter which may be related to systemic inflammatory factors, ischemia, and hypoxia are important biomarkers for monitoring microvascular diseases.<sup>67</sup> Xu et al found that ischemic heart disease causes significant decreasing retinal arterial lumen diameter and retinal arterial outer diameter as consequence of endothelial dysfunction and inhibition of diastolic function.<sup>60</sup> M Kamran et al conducted a large-scale study of 5000 individuals and found that wider retinal venular diameters were associated with higher serum high-sensitivity C-reactive protein, interleukin 6, and amyloid A levels and they believed that the caliber of retinal venules was influenced by the systemic inflammation.<sup>68</sup> Vincent et al collected patients with history of smoking as a risk factor of CHD and found the smokers had a wider central retinal venular equivalent compared to the nonsmokers.<sup>69</sup> Phan et al found that the significant correlation between the widening of retinal venules diameter and abnormal blood glucose was found in male population and it may also be affected by the scope of coronary artery stenosis.<sup>70</sup> Meanwhile, Manon et al found that after controlling for cardiovascular risk factors such as hyperglycemia, the relationship between retinal venules diameter and degree of arteriosclerosis became insignificant.<sup>71</sup>

The retinal arteriovenous ratio is the ratio of the diameter of the retinal arterioles to the diameter of the accompanying retinal venules. In previous studies, it was believed that the diameter of retinal venules was stable, so a decrease in the ratio was considered to indicate significant stenosis of small arteries. However, later research has shown that a decrease in the ratio can also occur as the diameter of retinal venules increases. But the retinal arteriovenous ratio remains the standard for evaluating retinal vessel function.<sup>72</sup> Previous studies have found that the changes of retinal arteriovenous ratio are related to the incidence

rate of coronary microvascular disease and stroke.<sup>73</sup> Li et al found that after 6–12 months of treatment with statins, the retinal arteriovenous ratio increases in hypercholesterolemia patients, which is related to the decrease in low-density lipoprotein and C-reactive protein.<sup>38</sup> Xu et al found that the severity of non-obstructive ischemic heart disease was negatively correlated with the diameter of the retinal arteriovenous ratio by using spectral domain optical coherence tomography.<sup>60</sup> The same conclusion also has been identified in the study of internal carotid artery stenosis.

The severity of carotid artery stenosis is correlated with narrowing retinal arterioles and a decrease in retinal arteriovenous ratio. At the same time, researchers also found that there is no significant difference in retinal arteriovenous ratio between patients with mild stenosis and healthy controls.<sup>45,74</sup> This may be due to the fact that when the retinal perfusion pressure decreases, the retinal arterioles first dilate to maintain constant blood flow. However, when the retinal blood vessels are unable to self-regulate and compensate, the retinal arterioles will contract. Therefore, these results indicate that the morphological changes of retinal blood vessels are influenced by the severity of CHD. For patients facing different cardiovascular risk factors, the changes in retinal blood vessel morphology may vary, and it is necessary to determine the degree of retinal microvessels which are affected.

## Changes of Retinal Microvessels Associated with Coronary Atherosclerosis

### Changes in FAZ in Macula

The FAZ can be seen as a clear circular or elliptical avascular area. Due to the lack of vascular structure, the blood supply of FAZ comes from the choroid supplied by the posterior ciliary artery. And it is because that FAZ area and other parameters are often used as a quantitative indicator to measure macular ischemia.<sup>75</sup> Atherosclerosis will lead to retinal vessel stenosis and increase of retinal artery resistance, finally causing expansion of FAZ area.<sup>22,76</sup> Lee et al found that the expansion of FAZ is associated with an increase in LDL-C.<sup>22</sup> Hyperlipidemia can lead to lipid deposition and oxidative stress response in blood vessels and can downregulate vascular endothelial growth factor, which can result in a decrease in superficial and deep retinal vascular density in the macular area, as well as an increase in FAZ area due to reduced blood flow.<sup>77</sup> After summarizing multiple studies, Monteiro Henriques et al concluded that patients with various cardiovascular diseases have lower retinal vascular density and larger FAZ area.<sup>54</sup> Anna et al measure retinal microvessels from patients with ST elevation myocardial infarction CHD by using optical coherence tomography and found that decrease in left ventricular ejection fraction may mainly affect the retinal fovea.<sup>78</sup> Indre et al compared the FAZ area of patients with CHD and acute myocardial infarction with that of healthy controls. Although there was an increasing trend in FAZ area, no significant statistical differences were found, which may be due to insufficient sample size.<sup>77</sup> At the same time, Duan et al investigated the parameter changes of retinal FAZ in patients with ischemic stroke, and found that the decrease of FAZ axis ratio and FAZ circularity were related to ischemic stroke caused by atherosclerosis.<sup>79</sup> FAZ area and perimeter were significantly increasing in patients with hypertension over 5 years than in healthy and patients with hypertension less 5 years so that the changes on retinal vessel can be influenced in chronic process.<sup>80</sup> In addition, the parameters changes in FAZ including increasing FAZ area and perimeter can also be detected without visual impairment or retinopathy.<sup>81,82</sup>

### Changes in Vessel Density in the Macula

The retina is one of the most active tissues for oxygen and metabolic substances. The central retinal artery provides blood to the inner five layers of the retina, while the outer five layers are supplied by the choroidal capillaries.<sup>83</sup> Insufficient blood supply and hemodynamic disorders can lead to dysfunction of the macular retina. De Aguiar et al found that macular nerve thickness was significantly decreased in the patients with cyanotic congenital heart disease, which is considered to be caused by hypoxia.<sup>84</sup> Many studies have found macular vessel density decreasing in the patients with CHD, which is often attributed to slower blood flow velocity in the central retinal artery, increased vascular resistance, microcirculatory disorders, and impaired autoregulation function<sup>85</sup> (Figures 1 and 2). Hannappe et al compared the retinal vascular length in the macula patients with acute coronary syndrome with healthy controls, and there was a significant correlation between angiopoietin-2 in serum, a factor involved in atherosclerosis.<sup>44</sup> Wang et al used optical coherence tomography to examine the retina of patients with non-obstructive coronary artery disease, obstructive coronary artery disease, and healthy controls. They found that patients with coronary artery disease had significantly

HD Angio Retina

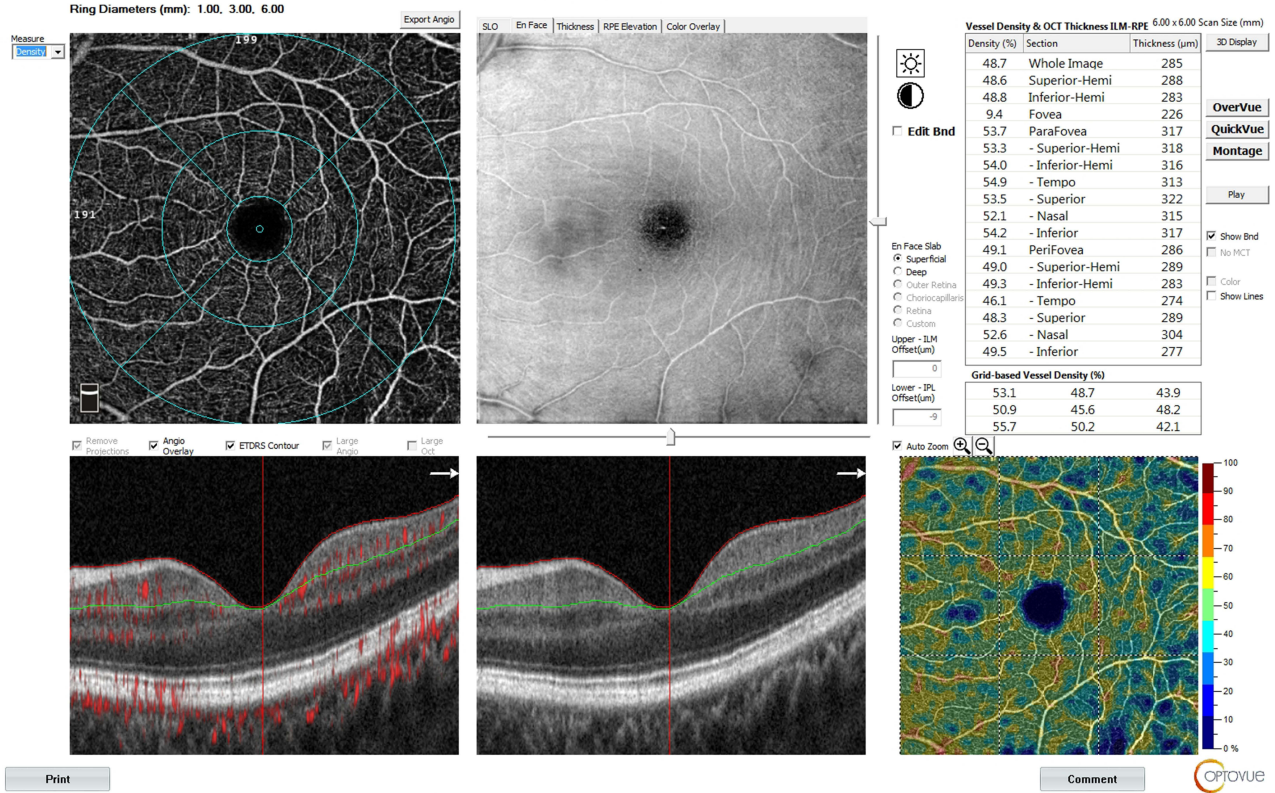


Figure 1 Imaging of retinal capillary structures in macula of health male (images were taken from the macula in a 6×6 mm area with the fovea).

HD Angio Retina

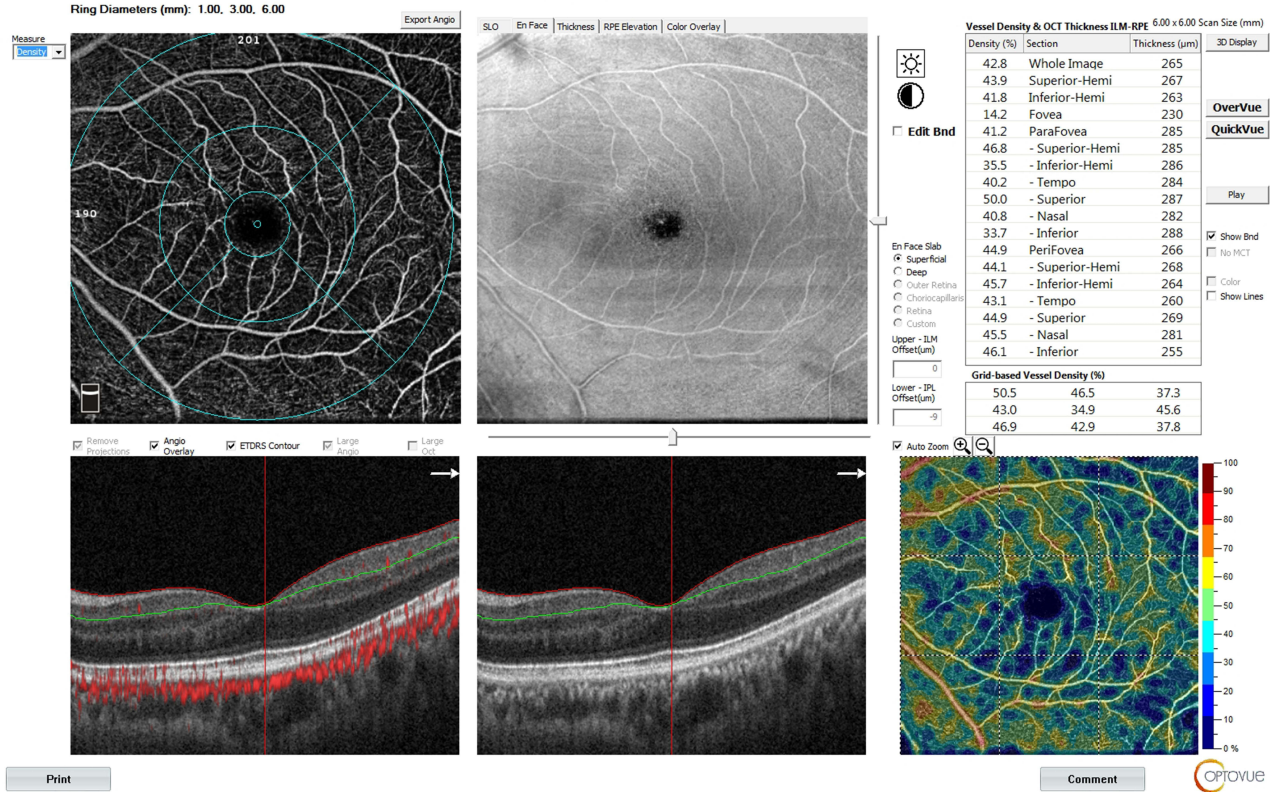


Figure 2 Imaging of retinal capillary structures in macula of coronary heart disease male (images were taken from the macula in a 6×6 mm area with the fovea).

reduced blood flow in both the superficial and deep layers of the macula. Additionally, the vascular density in the upper part of the superficial macular area was found to be an independent risk factor for non-obstructive coronary artery disease.<sup>36</sup> Wang et al used OCTA to analyze the correlation between changes in retinal microvasculature and the Gensini score of each coronary artery branch, and found that the degree of stenosis in the left main coronary artery, and proximal portion of the right coronary artery and left circumflex coronary artery was correlated with a decrease in microvascular density in the macula.<sup>5</sup> Anna et al study found that in patients with myocardial infarction caused by coronary heart disease, the decrease in superficial and deep capillary density in the macula is positively correlated with the decrease in left ventricular ejection fraction which may be caused by mechanical damage caused by retinal ischemia and reperfusion due to decreased cardiac function.<sup>78</sup> Louis et al used OCTA to analyze the superficial retinal macular vascular density in patients with acute coronary syndrome, and found that its density decrease was negatively correlated with the impaired left ventricular ejection fraction and the global acute coronary score.<sup>86</sup> However, Arnould et al examined patients with confirmed myocardial infarction and found that there was no significant correlation between retinal vascular density and hemodynamic variables in the acute phase of myocardial infarction or 3 months after cardiac rehabilitation. Therefore, they proposed a different conclusion that the retinal microvascular density seems not to be affected by hemodynamic changes related to myocardial infarction, such as left ventricular ejection fraction, aortic blood flow, systolic blood pressure, diastolic blood pressure and cardiac output, and has its own regulatory mechanism.<sup>87</sup> Michell et al studied the correlation between different cardiovascular risk factors and retinal microvascular changes in different scanning modes. They found that old age, hypertension, hyperglycemia and dyslipidemia were associated with the reduction of vascular density, vascular perfusion and average vascular length in the  $3 \times 3$  mm mode. Smoking would lead to the increase of vascular density, vascular length and connection density in the  $3 \times 3$  mm scanning mode, but with the expansion of scanning range and the reduction of scanning accuracy, the correlation between these metabolic factors and microvascular changes gradually weakened, suggesting that the risk factors of atherosclerosis may preferentially affect the minimum caliber microvascular function in the human body.<sup>88</sup> Recently, vascular density in the macula of the retina in hypertensive patients has been found lower than that in healthy controls, and poor controlled blood pressure can further decrease.<sup>89–91</sup> Whether both surface and deep blood vessels will decrease, other studies have a different conclusion. Christopher has found that hypertension was found to have a significant effect in the deep vessel plexus but not the superficial vessel plexus.<sup>92</sup> Deep vessel plexus is the connection between superficial vessel plexus and vein so that deep vessel plexus is more distal from the arterial circulation. It makes it more susceptible to disruption in retinal blood flow.<sup>93</sup> In addition, another study found that although the effect of smoking on the macula of the retina has not yet been found, there is a significant decrease in the capillary flow of the choroid in the macula, indicating that smoking can cause vasoconstriction and reduce eye blood flow, which may have an impact on retinal vascular disease in the later stages.<sup>94</sup>

## Changes in Vessel Density in the Optic Disc

The RPC that radiates from the optic disc form a unique vascular network within the optic nerve fiber layer of the retina. Changes in RPC vascular density can be used to evaluate retinal vascular function and reflect neurological conditions.<sup>95,96</sup> Previous studies have shown that the vascular density of RPC is closely related to the thickness of the optic nerve fiber layer.<sup>97</sup> There is a correlation between RPC changes and coronary heart disease, and they are independently associated with risk factors such as age, dyslipidemia, hypertension, and so on<sup>98</sup> (Figures 3 and 4). Niro et al found that aged 65 and above patients with hypertensive and abnormal elevated total cholesterol and triglycerides, the density of RPC blood vessels below the temporal inferior of the optic disc decreased, but on the contrary, the density of blood vessels within the optic disc showed an increasing trend. This result may be due to microvascular damage caused by hypertension, resulting in increased reflux resistance, as well as poor self-regulation ability of the RPC blood vessel network, leading to restricted blood flow and increased capillary density detected.<sup>99</sup> This may also be used to explain the findings that compared with patients with a history of hypertension for 5–10 years showing both decreased optic nerve fiber layer thickness and blood vessels within the optic disc, only the optic nerve fiber layer thickness was significantly thinner in patients with a history of hypertension for more than 10 years.<sup>81</sup> Peng et al found that the RPC vessels density of hypertensive patients was significantly reduced compared with healthy controls.<sup>100</sup> Although there are different research designs on systemic microvascular changes such as atherosclerosis

HD Angio Disc

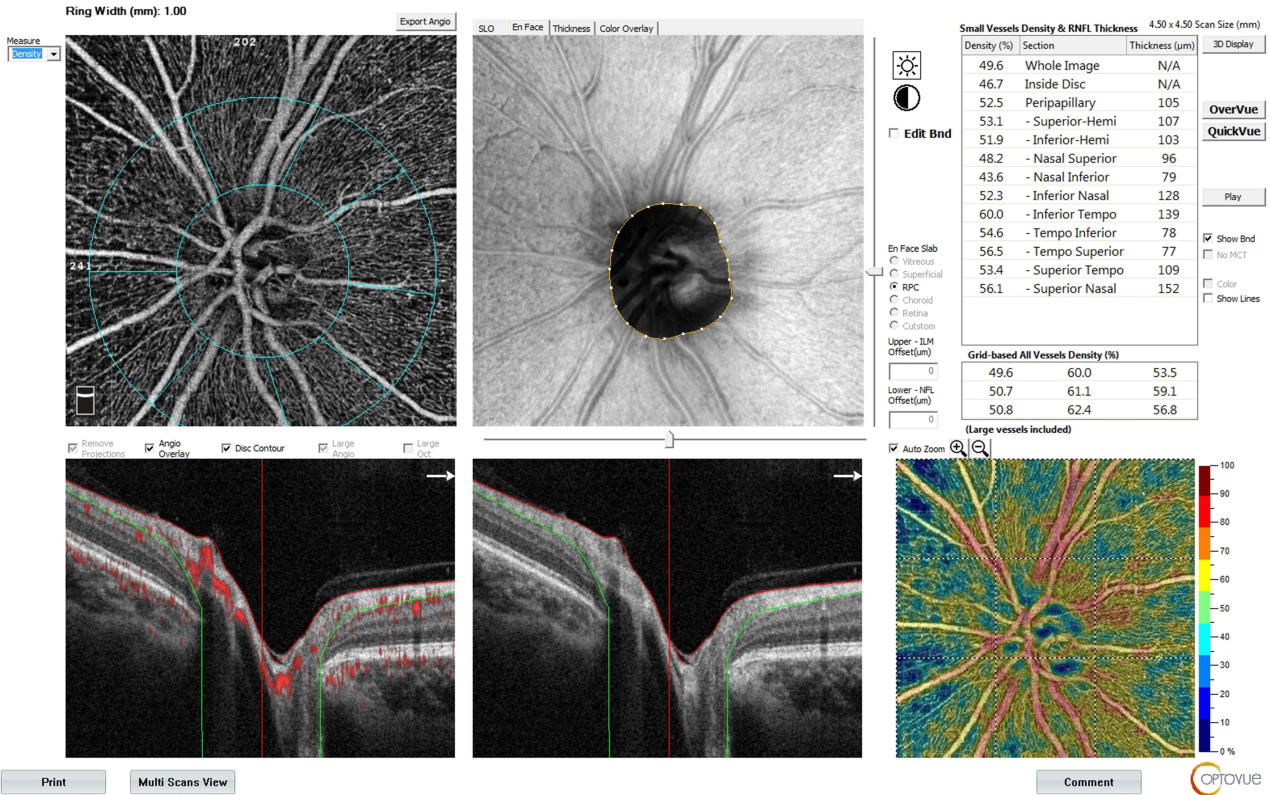


Figure 3 Imaging of retinal capillary structures in macula of health male (images were taken from the optic disc in a 4.5×4.5 mm area).

HD Angio Disc

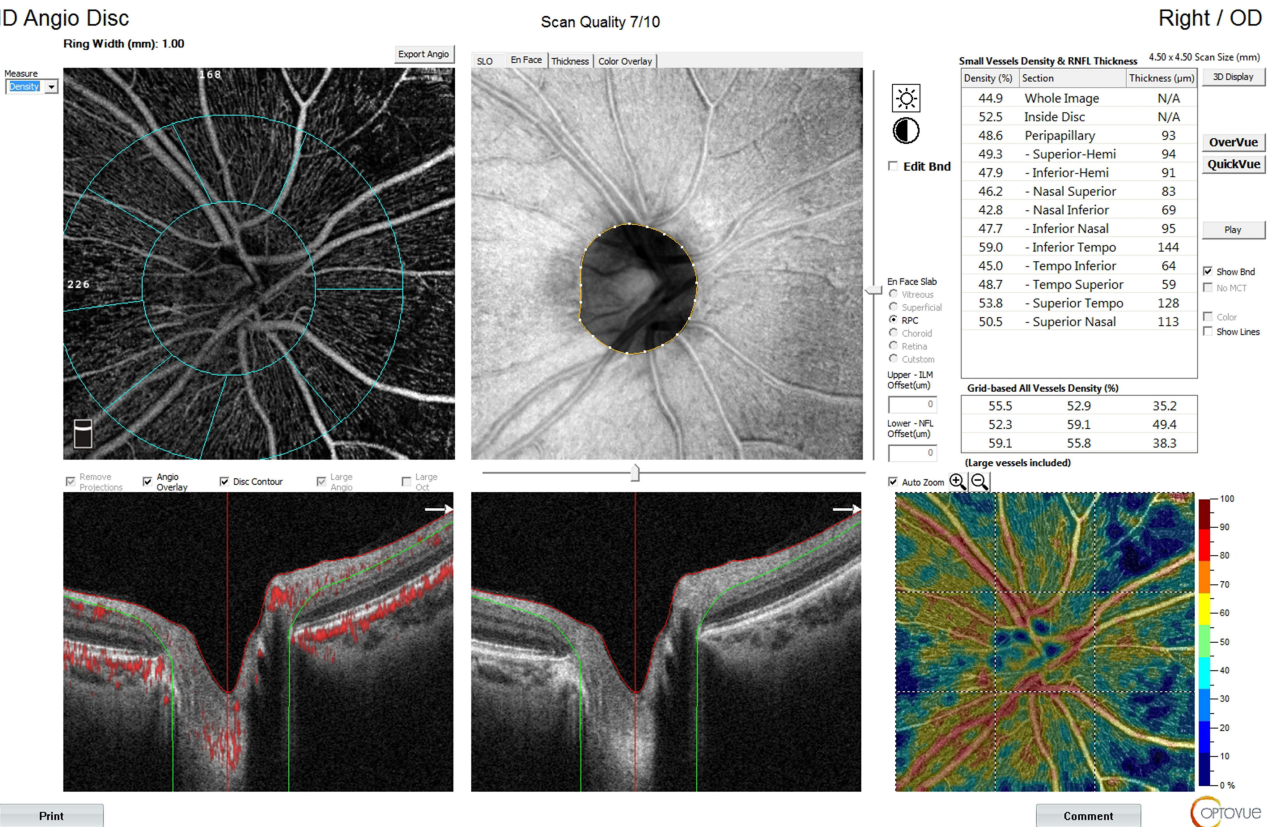
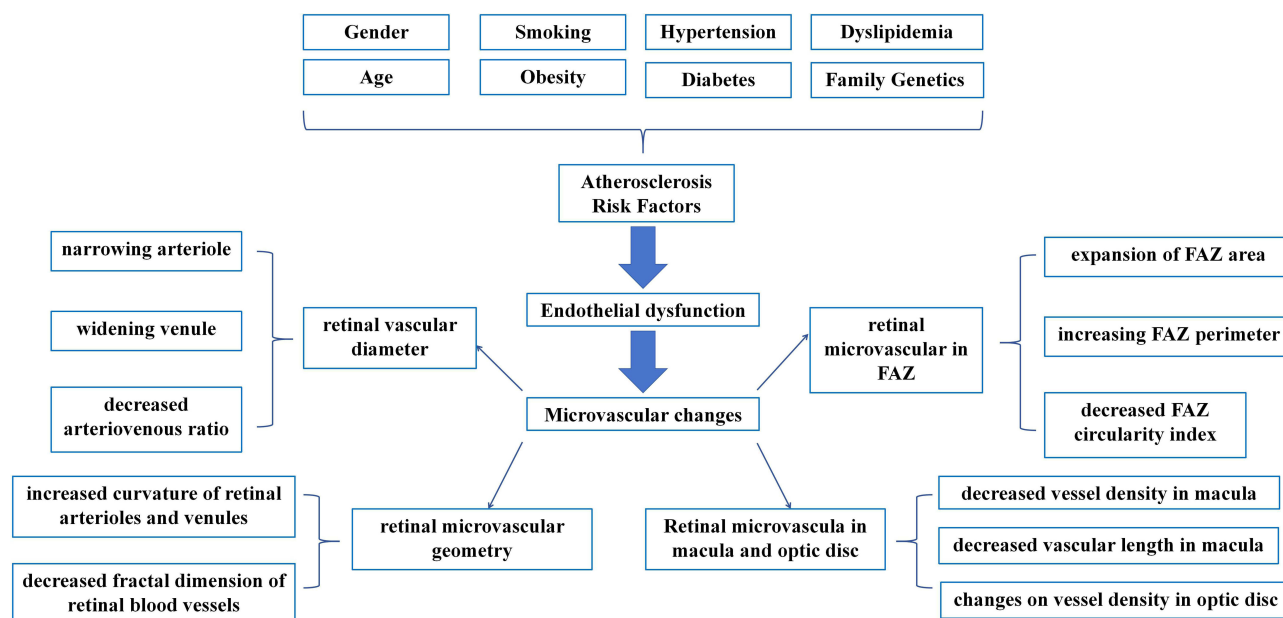


Figure 4 Imaging of retinal capillary structures in macula of coronary heart disease male (images were taken from the optic disc in a 4.5×4.5 mm area).



**Figure 5** Changes that can be monitored after atherosclerosis leads to retinal microvascular disease.

and microvascular dysfunction of the optic disc, and some results have not been agreed, it can be proved to some extent that microvascular changes of the optic disc are related to coronary heart disease.

## Conclusion

The retinal microvascular diseases related to coronary atherosclerosis include narrowing arterioles, wider venules, decreased arteriovenous ratio, FAZ area expansion and vessels density changes in the macula and optic disc (Figure 5). By analyzing the changes in retinal microvascular disease, we can further understand the disorders of retinal vascular wall, endothelial dysfunction, and inflammatory reaction, which are related to coronary atherosclerotic heart disease. In the face of the overall impact of atherosclerosis on the systemic vascular system and control of the impact of atherosclerosis on the retina are important. At the same time, retinal blood vessel, as the only directly visible microvascular in the human body, with the help of advanced retinal equipment can provide an observation window for evaluating coronary microcirculation. Since these years, more and more research has focused on monitoring changes in the body through the retina, such as cerebral infarction and Parkinson's disease.<sup>101,102</sup> Although the literature on the correlation between retinal vascular changes and coronary heart disease is still limited, non-invasive monitoring of the retina such as OCTA still has great potential in the future to help diagnose and evaluate the prognosis of cardiovascular diseases.

## Method of Literature Search

Searches were conducted using PubMed, Cochrane, and ScienceDirect databases using key words: "retinal imaging", "OCT", "OCTA", "fundus photography", "retinal vessel diameter", "cardiovascular disease", "hypertension", "coronary artery disease", and "cardiac". The same MeSH terms were used, with appropriate synonyms and keywords, in combination with Boolean operators (AND, OR). The search scope includes title, abstract and keywords. Through the search, a total of 881 articles were found. Inclusion criteria of articles include written in English; retinal imaging techniques such as optical coherence tomography (OCT), optical coherence tomography angiography (OCTA), or fundus photography; published after January 2015. And exclusion criteria include written in other languages; the types of article such as review, case report, books and documents, protocol; published before 2015, not relevant to the topic, any types of retinopathy in researches and repeat in different literature databases. After two researchers read the articles separately, the selected articles were organized using Microsoft Excel table software. Finally, after the application of the inclusion and exclusion criteria, 52 articles were chosen for the review.

## Acknowledgments

Li Bo and Gao Lifen are both co-corresponding authors. Wang Xinyu and Zhang Hui are both the first authors.

## Disclosure

The authors report no conflicts of interest in this work.

## References

1. Townsend N, Wilson L, Bhatnagar P, et al. Cardiovascular disease in Europe: epidemiological update 2016. *Eur Heart J*. 2016;37(42):3232–3245. doi:10.1093/eurheartj/ehw334
2. Wirtz PH, von Känel R. Psychological stress, inflammation, and coronary heart disease. *Curr Cardiol Rep*. 2017;19(11):111. doi:10.1007/s11886-017-0919-x
3. Libby P, Theroux P. Pathophysiology of coronary artery disease. *Circulation*. 2005;111(25):3481–3488. doi:10.1161/CIRCULATIONAHA.105.537878
4. Ross R. Atherosclerosis—an inflammatory disease. *N Engl J Med*. 1999;340(2):115–126. doi:10.1056/NEJM199901143400207
5. Wang J, Jiang J, Zhang Y, et al. Retinal and choroidal vascular changes in coronary heart disease: an optical coherence tomography angiography study. *Biomed Opt Express*. 2019;10(4):1532–1544. doi:10.1364/BOE.10.001532
6. Gdowski MA, Murthy VL, Doering M, et al. Association of isolated coronary microvascular dysfunction with mortality and major adverse cardiac events: a systematic review and meta-analysis of aggregate data. *J Am Heart Assoc*. 2020;9(9):e014954. doi:10.1161/JAHA.119.014954
7. Seidelmann SB, Claggett B, Bravo PE, et al. Retinal vessel calibers in predicting long-term cardiovascular outcomes: the atherosclerosis risk in communities study. *Circulation*. 2016;134(18):1328–1338. doi:10.1161/CIRCULATIONAHA.116.023425
8. Wang N, Liang C. Relationship of Gensini score with retinal vessel diameter and arteriovenous ratio in senile CHD. *Open Life Sci*. 2021;16(1):737–745. doi:10.1515/biol-2021-0068
9. Girach Z, Sarian A, Maldonado-García C, et al. Retinal imaging for the assessment of stroke risk: a systematic review. *J Neurol*. 2024;271(5):2285–2297. doi:10.1007/s00415-023-12171-6
10. Hanssen H, Streese L, Vilser W. Retinal vessel diameters and function in cardiovascular risk and disease. *Prog Retin Eye Res*. 2022;91:101095. doi:10.1016/j.preteyeres.2022.101095
11. Dzedziak J, Zaleska-żmijewska A, Szaflik JP, et al. Impact of arterial hypertension on the eye: a review of the pathogenesis, diagnostic methods, and treatment of hypertensive retinopathy. *Med Sci Monit*. 2022;28:e935135. doi:10.12659/MSM.935135
12. Zizas A, Wood K, Judickaitė A, et al. Relationship between intracranial pressure, ocular blood flow and vessel density: insights from OCTA and Doppler imaging. *Medicina*. 2025;61(5):800. doi:10.3390/medicina61050800
13. McLellan FC, Huang K, Wong E, et al. The angiofibrotic switch in retinal and choroidal vascular diseases: mechanistic drivers of angiogenesis and endothelial-mesenchymal transition. *Am J Pathol*. 2025. doi:10.1016/j.ajpath.2025.05.004
14. Iwase T, Akahori T, Yamamoto K, et al. Evaluation of optic nerve head blood flow in response to increase of intraocular pressure. *Sci Rep*. 2018;8(1):17235. doi:10.1038/s41598-018-35683-y
15. Luo X, Shen YM, Jiang MN, et al. Ocular blood flow autoregulation mechanisms and methods. *J Ophthalmol*. 2015;2015:864871. doi:10.1155/2015/864871
16. Lesk MR, Wajszilber M, Deschenes MC. The effects of systemic medications on ocular blood flow. *Can J Ophthalmol*. 2008;43(3):351–355. doi:10.3129/i08-057
17. Palkovits S, Lasta M, Told R, et al. Retinal oxygen metabolism during normoxia and hyperoxia in healthy subjects. *Invest Ophthalmol Vis Sci*. 2014;55(8):4707–4713. doi:10.1167/iovs.14-14593
18. Venkataraman ST, Hudson C, Fisher JA, et al. Retinal arteriolar and capillary vascular reactivity in response to isoxic hypercapnia. *Exp Eye Res*. 2008;87(6):535–542. doi:10.1016/j.exer.2008.08.020
19. Knudtson MD, Lee KE, Hubbard LD, et al. Revised formulas for summarizing retinal vessel diameters. *Curr Eye Res*. 2003;27(3):143–149. doi:10.1076/ceyr.27.3.143.16049
20. Perez-Rovira A, MacGillivray T, Trucco E, et al. VAMPIRE: vessel assessment and measurement platform for images of the REtina. *Annu Int Conf IEEE Eng Med Biol Soc*. 2011;2011:3391–3394. doi:10.1109/IEMBS.2011.6090918
21. Yip W, Tham YC, Hsu W, et al. Comparison of common retinal vessel caliber measurement software and a conversion algorithm. *Transl Vis Sci Technol*. 2016;5(5):11. doi:10.1167/tvst.5.5.11
22. Lee DH, Yi HC, Bae SH, et al. Risk factors for retinal microvascular impairment in type 2 diabetic patients without diabetic retinopathy. *PLoS One*. 2018;13(8):e0202103. doi:10.1371/journal.pone.0202103
23. Ghasemi Falavarjani K, Al-Sheikh M, Darvizeh F, et al. Retinal vessel calibre measurements by optical coherence tomography angiography. *Br J Ophthalmol*. 2017;101(7):989–992. doi:10.1136/bjophthalmol-2016-309678
24. Haridas S, Indurkha S, Kumar S, et al. Sensitivity and specificity of pseudocolor ultrawide field imaging in comparison to wide field fundus fluorescein angiography in detecting retinal neovascularization in diabetic retinopathy. *Eye*. 2022;36(10):1940–1944. doi:10.1038/s41433-021-01772-y
25. François J, de Laey JJ. Fluorescein angiography of the glaucomatous disc. *Ophthalmologica*. 1974;168(4):288–298. doi:10.1159/000307051
26. Iorga RE, Costin D, Munteanu-Dănulescu RS, et al. Non-invasive retinal vessel analysis as a predictor for cardiovascular disease. *J Pers Med*. 2024;14(5):501. doi:10.3390/jpm14050501
27. Sorop O, Heinonen I, van Kranenburg M, et al. Multiple common comorbidities produce left ventricular diastolic dysfunction associated with coronary microvascular dysfunction, oxidative stress, and myocardial stiffening. *Cardiovasc Res*. 2018;114(7):954–964. doi:10.1093/cvr/cvy038
28. Shamaki GR, Markson F, Soji-Ayoade D, et al. Peripheral artery disease: a comprehensive updated review. *Curr Probl Cardiol*. 2022;47(11):101082. doi:10.1016/j.cpcardiol.2021.101082

29. Colak E, Majkic-Singh N, Zoric L, et al. The role of CRP and inflammation in the pathogenesis of age-related macular degeneration. *Biochem Med.* 2012;22(1):39–48. doi:10.11613/BM.2012.005
30. Verma S, Badiwala MV, Weisel RD, et al. C-reactive protein activates the nuclear factor-kappaB signal transduction pathway in saphenous vein endothelial cells: implications for atherosclerosis and restenosis. *J Thorac Cardiovasc Surg.* 2003;126(6):1886–1891. doi:10.1016/j.jtcvs.2003.07.026
31. van der Meer IM, de Maat MP, Bots ML, et al. Inflammatory mediators and cell adhesion molecules as indicators of severity of atherosclerosis: the Rotterdam study. *Arterioscler Thromb Vasc Biol.* 2002;22(5):838–842. doi:10.1161/01.ATV.0000016249.96529.B8
32. Fragão-Marques M, Francisca-Marques M, Rocha Neves J, et al. Association of inflammatory biomarkers with morbidity and mortality risk in patients with peripheral artery disease: a systematic review and -meta-analysis. *Crit Rev Clin Lab Sci*;2025. 1–20. doi:10.1080/10408363.2025.2512472
33. Liu M, Lovern C, Lycett K, et al. The association between markers of inflammation and retinal microvascular parameters: a systematic review and meta-analysis. *Atherosclerosis.* 2021;336:12–22. doi:10.1016/j.atherosclerosis.2021.09.025
34. Granger DN, Senchenkova E. Inflammation and the Microcirculation. San Rafael (CA): Morgan & Claypool Life Sciences; 2010. doi:10.4199/C00013ED1V01Y201006ISP008
35. Ding Z, Pothineni NVK, Goel A, et al. PCSK9 and inflammation: role of shear stress, pro-inflammatory cytokines, and LOX-1. *Cardiovasc Res.* 2020;116(5):908–915. doi:10.1093/cvr/cvz313
36. Ren Y, Hu Y, Li C, et al. Impaired retinal microcirculation in patients with non-obstructive coronary artery disease. *Microvasc Res.* 2023;148:104533. doi:10.1016/j.mvr.2023.104533
37. Moriya J. Critical roles of inflammation in atherosclerosis. *J Cardiol.* 2019;73(1):22–27. doi:10.1016/j.jcc.2018.05.010
38. Fernández-Friera L, Fuster V, López-Melgar B, et al. Vascular inflammation in subclinical atherosclerosis detected by hybrid PET/MRI. *J Am Coll Cardiol.* 2019;73(12):1371–1382. doi:10.1016/j.jacc.2018.12.075
39. Pradhan AD, Aday AW, Rose LM, et al. Residual inflammatory risk on treatment with PCSK9 inhibition and statin therapy. *Circulation.* 2018;138(2):141–149. doi:10.1161/CIRCULATIONAHA.118.034645
40. Ridker PM, Everett BM, Thuren T, et al. Antiinflammatory therapy with canakinumab for atherosclerotic disease. *N Engl J Med.* 2017;377(12):1119–1131. doi:10.1056/NEJMoa1707914
41. Camici PG, d'Amati G, Rimoldi O. Coronary microvascular dysfunction: mechanisms and functional assessment. *Nat Rev Cardiol.* 2015;12(1):48–62. doi:10.1038/nrcardio.2014.160
42. McGrory S, Taylor AM, Pellegrini E, et al. Towards standardization of quantitative retinal vascular parameters: comparison of SIVA and VAMPIRE measurements in the Lothian birth cohort 1936. *Transl Vis Sci Technol.* 2018;7(2):12. doi:10.1167/tvst.7.2.12
43. Ikram MK, Ong YT, Cheung CY, et al. Retinal vascular caliber measurements: clinical significance, current knowledge and future perspectives. *Ophthalmologica.* 2013;229(3):125–136. doi:10.1159/000342158
44. Hannappe MA, Arnould L, Méloux A, et al. Vascular density with optical coherence tomography angiography and systemic biomarkers in low and high cardiovascular risk patients. *Sci Rep.* 2020;10(1):16718. doi:10.1038/s41598-020-73861-z
45. Al-Fiadh AH, Wong TY, Kawasaki R, et al. Usefulness of retinal microvascular endothelial dysfunction as a predictor of coronary artery disease. *Am J Cardiol.* 2015;115(5):609–613. doi:10.1016/j.amjcard.2014.12.011
46. Guo S, Yin S, Tse G, et al. Association between caliber of retinal vessels and cardiovascular disease: a systematic review and meta-analysis. *Curr Atheroscler Rep.* 2020;22(4):16. doi:10.1007/s11883-020-0834-2
47. Chakrala T, Prakash R, Valdes C, et al. Circulating biomarkers in coronary microvascular dysfunction. *J Am Heart Assoc.* 2023;12(12):e029341. doi:10.1161/JAHA.122.029341
48. Zhong P, Hu Y, Jiang L, et al. Retinal microvasculature changes in patients with coronary total occlusion on optical coherence tomography angiography. *Front Med.* 2021;8:708491. doi:10.3389/fmed.2021.708491
49. Patton N, Aslam TM, MacGillivray T, et al. Retinal image analysis: concepts, applications and potential. *Prog Retin Eye Res.* 2006;25(1):99–127. doi:10.1016/j.preteyeres.2005.07.001
50. Owen CG, Rudnicka AR, Welikala RA, et al. Retinal vasculometry associations with cardiometabolic risk factors in the European prospective investigation of cancer-Norfolk study. *Ophthalmology.* 2019;126(1):96–106. doi:10.1016/j.ophtha.2018.07.022
51. Wang SB, Mitchell P, Liew G, et al. A spectrum of retinal vasculature measures and coronary artery disease. *Atherosclerosis.* 2018;268:215–224. doi:10.1016/j.atherosclerosis.2017.10.008
52. Cheung CY, Zheng Y, Hsu W, et al. Retinal vascular tortuosity, blood pressure, and cardiovascular risk factors. *Ophthalmology.* 2011;118(5):812–818. doi:10.1016/j.ophtha.2010.08.045
53. Vo Kim S, Semoun O, Pedinielli A, et al. Optical coherence tomography angiography quantitative assessment of exercise-induced variations in retinal vascular plexa of healthy subjects. *Invest Ophthalmol Vis Sci.* 2019;60(5):1412–1419. doi:10.1167/iovs.18-24389
54. Monteiro-Henriques I, Rocha-Sousa A, Barbosa-Breda J. Optical coherence tomography angiography changes in cardiovascular systemic diseases and risk factors: a Review. *Acta Ophthalmol.* 2022;100(1):e1–e15. doi:10.1111/aos.14851
55. Rusu AC, Chistol RO, Tinica G, et al. Retinal microvascular profile of patients with coronary artery disease. *Medicina.* 2025;61(5):834. doi:10.3390/medicina61050834
56. Wei FF, Thijs L, Melgarejo JD, et al. Diastolic left ventricular function in relation to the retinal microvascular fractal dimension in a Flemish population. *Hypertens Res.* 2021;44(4):446–453. doi:10.1038/s41440-021-00623-3
57. Wang JJ, Liew G, Klein R, et al. Retinal vessel diameter and cardiovascular mortality: pooled data analysis from two older populations. *Eur Heart J.* 2007;28(16):1984–1992. doi:10.1093/eurheartj/ehm221
58. Xu BL, Zhou WL, Zhu TP, et al. Author Correction: a full-width half-maximum method to assess retinal vascular structural changes in patients with ischemic heart disease and microvascular angina. *Sci Rep.* 2019;9(1):18824. doi:10.1038/s41598-019-55182-y
59. Nägele MP, Barthelmes J, Ludovici V, et al. Retinal microvascular dysfunction in heart failure. *Eur Heart J.* 2018;39(1):47–56. doi:10.1093/eurheartj/ehx565
60. Xu BL, Zhou WL, Zhu TP, et al. A full-width half-maximum method to assess retinal vascular structural changes in patients with ischemic heart disease and microvascular angina. *Sci Rep.* 2019;9(1):11019. doi:10.1038/s41598-019-47194-5

61. Wang SB, Mitchell P, Plant AJ, et al. Metabolic syndrome and retinal microvascular calibre in a high cardiovascular disease risk cohort. *Br J Ophthalmol*. 2016;100(8):1041–1046. doi:10.1136/bjophthalmol-2015-307637
62. Tabatabaee A, Asharin MR, Dehghan MH, et al. Retinal vessel abnormalities predict coronary artery diseases. *Perfusion*. 2013;28(3):232–237. doi:10.1177/0267659112473173
63. Seecheran NA, Rafeeq S, Maharaj N, et al. Correlation of RETINAL artery diameter with coronary artery disease: the RETINA CAD pilot study—are the eyes the windows to the heart? *Cardiol Ther*. 2023;12(3):499–509. doi:10.1007/s40119-023-00320-x
64. Xiao W, Guo X, Ding X, et al. Serum lipid profiles and dyslipidaemia are associated with retinal microvascular changes in children and adolescents. *Sci Rep*. 2017;7(1):44874. doi:10.1038/srep44874
65. Lympelopoulou C, Kandarakis SA, Tzanaki I, et al. The effect of statins on ocular disorders: a systematic review of randomized controlled trials. *Pharmaceuticals*. 2023;16(5):711. doi:10.3390/ph16050711
66. István L, Czákó C, Benyó F, et al. The effect of systemic factors on retinal blood flow in patients with carotid stenosis: an optical coherence tomography angiography study. *Geroscience*. 2022;44(1):389–401. doi:10.1007/s11357-021-00492-1
67. Lendzioszek M, Mrugacz M, Bryl A, et al. Prevention and treatment of retinal vein occlusion: the role of diet-A review. *Nutrients*. 2023;15(14):3237. doi:10.3390/nu15143237
68. Ikram MK, de Jong FJ, Vingerling JR, et al. Are retinal arteriolar or venular diameters associated with markers for cardiovascular disorders? The Rotterdam study. *Invest Ophthalmol Vis Sci*. 2004;45(7):2129–2134. doi:10.1167/iops.03-1390
69. Yuen VL, Zhang XJ, Ling X, et al. Effects of firsthand tobacco smoking on retinal vessel caliber: a systematic review and meta-analysis. *Graefes Arch Clin Exp Ophthalmol*. 2024;262(5):1397–1407. doi:10.1007/s00417-023-06223-w
70. Phan K, Mitchell P, Liew G, et al. Associations between retinal arteriolar and venular calibre with the prevalence of impaired fasting glucose and diabetes mellitus: a cross-sectional study. *PLoS One*. 2018;13(5):e0189627. doi:10.1371/journal.pone.0189627
71. van Hecke MV, Dekker JM, Nijpels G, et al. Are retinal microvascular abnormalities associated with large artery endothelial dysfunction and intima-media thickness? The Hoorn study. *Clin Sci*. 2006;110(5):597–604. doi:10.1042/CS20050270
72. Mimoun L, Massin P, Steg G. Retinal microvascularisation abnormalities and cardiovascular risk. *Arch Cardiovasc Dis*. 2009;102(5):449–456. doi:10.1016/j.acvd.2009.02.008
73. Wong TY, Klein R, Couper DJ, et al. Retinal microvascular abnormalities and incident stroke: the atherosclerosis risk in communities study. *Lancet*. 2001;358(9288):1134–1140. doi:10.1016/S0140-6736(01)06253-5
74. Wu DH, Wu LT, Wang YL, et al. Changes of retinal structure and function in patients with internal carotid artery stenosis. *BMC Ophthalmol*. 2022;22(1):123. doi:10.1186/s12886-022-02345-7
75. Shuang L, Zhiyang J, Huika X, et al. Research progress on macular foveal avascular zone in glaucoma based on optical coherence tomography angiography. *Recent Advances in Ophthalmology*. 2022;42(08):659–663 doi:10.13389/j.enki.rao.2022.0135
76. Parodi MB, Visintin F, Della Rupe P, et al. Foveal avascular zone in macular branch retinal vein occlusion. *Int Ophthalmol*. 1995;19(1):25–28. doi:10.1007/BF00156415
77. Matulevičiūtė I, Sidaraitė A, Tatarūnas V, et al. Retinal and choroidal thinning—a predictor of coronary artery occlusion? *Diagnostics*. 2022;12(8):2016. doi:10.3390/diagnostics12082016
78. Sideri AM, Kanakis M, Katsimpris A, et al. Correlation between coronary and retinal microangiopathy in patients with STEMI. *Transl Vis Sci Technol*. 2023;12(5):8. doi:10.1167/tvst.12.5.8
79. Duan H, Xie J, Zhou Y, et al. Characterization of the retinal microvasculature and FAZ changes in ischemic stroke and its different types. *Transl Vis Sci Technol*. 2022;11(10):21. doi:10.1167/tvst.11.10.21
80. Lim HB, Lee MW, Park JH, et al. Changes in Ganglion cell-inner plexiform layer thickness and retinal microvasculature in hypertension: an optical coherence tomography angiography study. *Am J Ophthalmol*. 2019;199:167–176. doi:10.1016/j.ajo.2018.11.016
81. Hua D, Xu Y, Zeng X, et al. Use of optical coherence tomography angiography for assessment of microvascular changes in the macula and optic nerve head in hypertensive patients without hypertensive retinopathy. *Microvasc Res*. 2020;129:103969. doi:10.1016/j.mvr.2019.103969
82. Li T, Jia Y, Wang S, et al. Retinal microvascular abnormalities in children with type 1 diabetes mellitus without visual impairment or diabetic retinopathy. *Invest Ophthalmol Vis Sci*. 2019;60(4):990–998. doi:10.1167/iops.18-25499
83. Agea FV, Sensoy B, Aslanci ME, et al. Retinal microvascular changes in patients with coronary artery disease and apnea. *Microvasc Res*. 2023;148:104514. doi:10.1016/j.mvr.2023.104514
84. de Aguiar Remigio MC, Brandt CT, Santos CC, et al. Macular and peripapillary retinal nerve fibre layer thickness in patients with cyanotic congenital heart disease. *Eye*. 2015;29(4):465–468. doi:10.1038/eye.2014.330
85. Wu Y, Li S, Zu X, et al. Changes of central retinal artery blood flow and endothelial function in patients with coronary artery disease. *Curr Eye Res*. 2007;32(9):813–817. doi:10.1080/02713680701572664
86. Arnould L, Guenancia C, Azemar A, et al. The EYE-MI pilot study: a prospective acute coronary syndrome cohort evaluated with retinal optical coherence tomography angiography. *Invest Ophthalmol Vis Sci*. 2018;59(10):4299–4306. doi:10.1167/iops.18-24090
87. Arnould L, Guenancia C, Gabrielle PH, et al. Influence of cardiac hemodynamic variables on retinal vessel density measurement on optical coherence tomography angiography in patients with myocardial infarction. *J Fr Ophthalmol*. 2020;43(3):216–221. doi:10.1016/j.jfo.2019.07.026
88. Sun MT, Huang S, Chan W, et al. Impact of cardiometabolic factors on retinal vasculature: a 3 × 3, 6 × 6 and 8 × 8-mm ocular coherence tomography angiography study. *Clin Exp Ophthalmol*. 2021;49(3):260–269. doi:10.1111/ceo.13913
89. Lee WH, Park JH, Won Y, et al. Retinal microvascular change in hypertension as measured by optical coherence tomography angiography. *Sci Rep*. 2019;9(1):156. doi:10.1038/s41598-018-36474-1
90. Donati S, Maresca AM, Cattaneo J, et al. Optical coherence tomography angiography and arterial hypertension: a role in identifying subclinical microvascular damage? *Eur J Ophthalmol*. 2021;31(1):158–165. doi:10.1177/1120672119880390
91. Chua J, Chin CWL, Hong J, et al. Impact of hypertension on retinal capillary microvasculature using optical coherence tomographic angiography. *J Hypertens*. 2019;37(3):572–580. doi:10.1097/HJH.0000000000001916
92. Sun C, Ladores C, Hong J, et al. Systemic hypertension associated retinal microvascular changes can be detected with optical coherence tomography angiography. *Sci Rep*. 2020;10(1):9580. doi:10.1038/s41598-020-66736-w
93. Dupas B, Minvielle W, Bonnin S, et al. Association between vessel density and visual acuity in patients with diabetic retinopathy and poorly controlled type 1 diabetes. *JAMA Ophthalmol*. 2018;136(7):721–728. doi:10.1001/jamaophthalmol.2018.1319

94. Ayhan Z, Kaya M, Ozturk T, et al. Evaluation of macular perfusion in healthy smokers by using optical coherence tomography angiography. *Ophthalmic Surg Lasers Imaging Retina*. 2017;48(8):617–622. doi:10.3928/23258160-20170802-03
95. Shin YI, Nam KY, Lee SE, et al. Changes in peripapillary microvasculature and retinal thickness in the fellow eyes of patients with unilateral retinal vein occlusion: an OCTA study. *Invest Ophthalmol Vis Sci*. 2019;60(2):823–829. doi:10.1167/iovs.18-26288
96. Chen L, Yuan M, Sun L, et al. Evaluation of microvascular network with optical coherence tomography angiography (OCTA) in branch retinal vein occlusion (BRVO). *BMC Ophthalmol*. 2020;20(1):154. doi:10.1186/s12886-020-01405-0
97. Yu PK, Cringle SJ, Yu DY. Correlation between the radial peripapillary capillaries and the retinal nerve fibre layer in the normal human retina. *Exp Eye Res*. 2014;129:83–92. doi:10.1016/j.exer.2014.10.020
98. Liang C, Gu C, Wang N. Retinal vascular caliber in coronary heart disease and its risk factors. *Ophthalmic Res*. 2023;66(1):151–163. doi:10.1159/000526753
99. Niro A, Sborgia G, Lampignano L, et al. Association of neuroretinal thinning and microvascular changes with hypertension in an older population in Southern Italy. *J Clin Med*. 2022;11(4):1098. doi:10.3390/jcm11041098
100. Peng Q, Hu Y, Huang M, et al. Retinal neurovascular impairment in patients with essential hypertension: an optical coherence tomography angiography study. *Invest Ophthalmol Vis Sci*. 2020;61(8):42. doi:10.1167/iovs.61.8.42
101. Stefánsson E, Olafsdóttir OB, Eliasdóttir TS, et al. Retinal oximetry: metabolic imaging for diseases of the retina and brain. *Prog Retin Eye Res*. 2019;70:1–22. doi:10.1016/j.preteyeres.2019.04.001
102. Zhao Y, Dai W, Liu D. Quantitative analysis of related parameters of retinal nerve fiber layer and ganglion cell complex thickness in patients with different degrees of Parkinson's disease. *Aging Clin Exp Res*. 2022;34(10):2355–2361. doi:10.1007/s40520-022-02211-y

International Journal of General Medicine

Publish your work in this journal

The International Journal of General Medicine is an international, peer-reviewed open-access journal that focuses on general and internal medicine, pathogenesis, epidemiology, diagnosis, monitoring and treatment protocols. The journal is characterized by the rapid reporting of reviews, original research and clinical studies across all disease areas. The manuscript management system is completely online and includes a very quick and fair peer-review system, which is all easy to use. Visit <http://www.dovepress.com/testimonials.php> to read real quotes from published authors.

Submit your manuscript here: <https://www.dovepress.com/international-journal-of-general-medicine-journal>

**Dovepress**  
Taylor & Francis Group