

Combined phacovitrectomy with preoperative cyclosporin A in management of resistant panuveitis

Mohammad A Rashad

Ophthalmology Department,
Ain Shams University, Cairo, Egypt

Purpose: This paper evaluates the visual outcome and report complications and uveitis control of one-stage combined pars plana vitrectomy, phacoemulsification, and intraocular lens (IOL) implantation in eyes with resistant noninfective uveitis after preoperative control by oral cyclosporin A (CSA).

Methods: This paper uses an interventional case-series study of ten eyes in nine patients with panuveitis, controlled by oral CSA with the least dose of topical and systemic steroids. All eyes underwent standard pars plana vitrectomy, microcoaxial phacoemulsification, and IOL implantation. The data recorded were visual acuity (VA), intraoperative and postoperative complications, and recurrences of activity through a minimum follow-up of 6 months.

Results: The mean logarithm of the minimum angle of resolution (logMAR) significantly improved from 1.597 at baseline (3/60 Snellen's equivalent), to 0.819 at the 3-month follow-up meeting (6/45 Snellen's equivalent), to 0.663 at the 6-month postoperative visit. VA improved in 70% of eyes, worsened in 20%, and stabilized in 10%. There was improvement (>6 lines) in 30% of eyes. The rate of posterior synechia formation and uncontrollable glaucoma decreased from 60% preoperative to 10% postoperative ($P = 0.01$). There was significant decline in the number of eyes requiring topical steroids from 100% preoperative to 50% postoperative ($P = 0.01$). The same is true for oral CSA, which decreased from 100% preoperatively to 10% postoperatively.

Conclusion: A single-stage combination of phacovitrectomy and IOL implantation is able to control noninfective panuveitis with less need for systemic treatment and topical steroids, and results in fewer incidence of glaucoma and posterior synechia. Furthermore, it restores useful postoperative vision.

Keywords: phacovitrectomy, panuveitis, cyclosporin A

Introduction

Intraocular inflammatory diseases are the leading cause of visual impairment. Of those suffering from the diseases, 55% have additional systemic diseases such as Behçet's disease and Vogt Koyanagi-Harada (VKH) disease. Many systemic entities associated with uveitis cause concomitant iridocyclitis and posterior uveitis (ie, panuveitis or diffuse uveitis). Diffuse uveitis may originate as iritis or as posterior uveitis that eventually involves all of the uvea as well as other ocular structures such as the trabecular meshwork, cornea, and optic nerve. Cataract is the most common complication of chronic uveitis, and cataract extraction in these eyes represents a significant challenge due to the high number of possible complications.

Other causes of visual impairment in chronic uveitis include glaucoma, hypotony, phthisis, cyclitic membrane, synechiae, vitreous opacities, macular edema, and retinal

Correspondence: Mohammad A Rashad,
Othman Buildings, Ali Amen Street,
Nasr City, Cairo, Egypt
Tel +20 122 346 3327
Fax +20 111 575 8888
Email mahmad_r@yahoo.com

detachment. Some of these cause irreversible damage such as chronic macular edema.¹ The original report on combined pars plana vitrectomy and lensectomy for complicated cataract was published in 1978.² Combined vitreoretinal surgery, phacoemulsification, and posterior chamber intraocular lens (IOL) implantation has since been reported.^{3,4} A sutureless 25-gauge vitrectomy system was combined with standard phacoemulsification for the management of uveitic patients with cataracts and coexisting posterior segments in 2008.⁵ However, these studies did not describe the suppression of preoperative intraocular inflammation in detail.

The repeated use of topical steroids increases the risk of complications such as glaucoma and cataracts. Furthermore, systemic side effects such as osteoporosis, diabetes, and hypertension are serious complications associated with the long-term full-dose use of systemic steroids.¹ Anti-inflammatory and immunomodulators such as cyclosporin A (CSA) and azathioprine represent steroid-free options for recurrent or chronic cases.⁶

This study describes the complete suppression of intraocular inflammation using CSA with or without half-dose systemic steroids. The method used in this study is a combination of microcoaxial phacoemulsification and standard 20-gauge pars plana vitrectomy once the cataract is visually significant. Postoperative visual acuity (VA) and intraocular inflammation with its potential complications were assessed in comparison with the preoperative level.

Methods

This study examined ten eyes of ten patients with different types of panuveitis from 2007 to 2011.

Inclusion criteria

- Chronic uveitis with recurrent episodes or persistent activity after a maximum of 3 weeks of systemic steroids.
- Anterior and posterior segment involvement secondary to chronic uveitis.
- Complete suppression of intraocular inflammation for a minimum of 8 weeks.
- Visually significant complicated cataract.

Exclusion criteria

- Previous surgery or trauma.
- Uveitis limited to anterior segment only.
- Controlled uveitis under topical steroids alone with or without short course of systemic steroids.
- Clear crystalline lens.

- Infective aetiology.

The degrees of cells and flare in the anterior chamber and vitreous were determined according to a scale from zero to four as reported by Hogan et al.⁷ Intraocular inflammation was controlled using topical steroids, and weight-adjusted CSA. Half-dose systemic steroids were added on-demand for further control.

CSA dose and administration

The patients in our study received an oral dose of 2.5 mg/kg/day with reduced steroids to 0.5 mg/kg/day. If a favorable response was obtained, the dose was reduced by 0.5 mg/kg/day/month after receiving the optimum dose for 12 weeks. The side effects of CSA—mainly hypertension and renal dysfunction—were assessed every 3 weeks. Topical dexamethazone was administered six times a day 1 week before surgery even if intraocular inflammation was controlled. If the patient was a steroid responder, antiglaucoma drugs were administered to control intraocular pressure (IOP). All patients completed a questionnaire about the possible systemic manifestations of uveitis as well as routine laboratory and radiological workup when indicated. All eyes underwent preoperative biometry to determine the power of the IOL to be implanted. Finally, eyes with dense cataracts or vitreous opacification underwent an ultrasound assessment to assess the condition of the retina.

Surgical technique

After informed consent was obtained, the patients underwent surgery using local anesthesia in seven eyes and general anesthesia in three eyes. Microcoaxial phacoemulsification was performed using the Alcon INFINITI™ System with OZil IP (Houston, TX) phacoemulsification machine through a 2.2 mm corneal incision. Next, a viscoelastic was installed in the anterior chamber while using the injecting cannula to dissect the posterior synechia. The pupillary and retroirideal membranes were removed by microcoaxial capsulorhexis forceps (Figure 1). The pupil was dilated through iris retractors or microsphenchrotomies. The anterior chamber was refilled with the viscoelastic. A capsulorhexis was performed by microcoaxial forceps, and hydrodissection was performed using a capsule cleavage technique. The hard nuclei were removed using the quick-chop technique and the soft nuclei were removed using the chip-and-flip technique. Cortical material was aspirated using the bimanual technique, and the capsular bag was filled with viscoelastic to stabilize the posterior capsule.

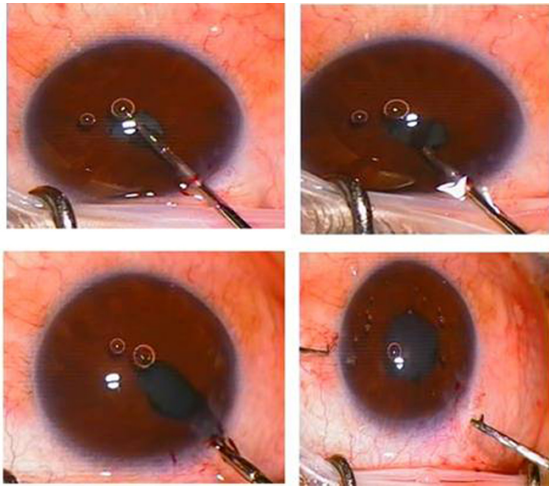


Figure 1 Dissection of papillary membrane attached to retroiridial membrane.

The infusion cannula of the 20-gauge system was fixed using a 7.0 vicryl in the lower temporal quadrant, 3.5 mm from the limbus. Two other sclerotomies were made in the superotemporal and superonasal quadrants for the light pipe and vitrectomy probe. The core and peripheral vitreous were removed and the posterior hyaloid was stained using diluted triamcinolone acetonide to remove all of the cortical vitreous and epiretinal membranes (Figure 2). Next, the pars plana sclerotomies were closed by 7.0 vicryl. Six eyes were left to be filled with fluid, and one eye was tamponaded with slightly expansile mixture (18%) of C_3F_8 gas. Silicon oil was used in two eyes: one for expected hypotony and one for long-term tamponade of retinal breaks. When the phacoemulsification was concluded, a foldable hydrophobic acrylic IOL was implanted in the bag in seven eyes, and in the sulcus in one eye. Two eyes were left aphakic and were siliconized. Retinopexy was performed in two eyes: one using cryopexy

in the sclerotomy-related break, and one using a laser in the posterior pole break.

None of the wounds were left sutureless. The corneal wounds, including paracentesis, were sutured using 10.0 nylon. Posterior subtenon triamcinolone acetonide (40 mg) was injected at the end of the surgery in all eyes. The patients usually received a follow-up evaluation at 1 day, 7 days, 1 month, and every 2 months after surgery. A complete ophthalmic examination was performed at every visit. Optical coherence tomography was performed when cystoid macular edema (CME) or epiretinal membrane (ERM) were suspected or unexplained vision loss was found.

The postoperative medication administered in this study was topical dexamethazone 8 times/day for the first week, 6 times/day for the second week, 4 times/day for the third week, and two times/day for the fourth week. A final maintenance dose of dexamethazone was administered once/day or twice/week until no recurrence was found. If anterior chamber inflammation recurred, the topical dexamethazone treatment returned to its previous dose. Postoperative systemic prednisolone or CSA was administered only if vitreous inflammation and haze were found postoperatively, and was stopped once the inflammation was resolved. Finally, postoperative inflammatory activities were defined using a scale of zero to four for a minimum of 6 months, as reported by Hogan et al.⁷

Outcome measures

- Postoperative VA in logMAR.
- Inflammatory activity monitored by anterior chamber cells and/or vitreous cells.
- IOP
- Complications in surgery.

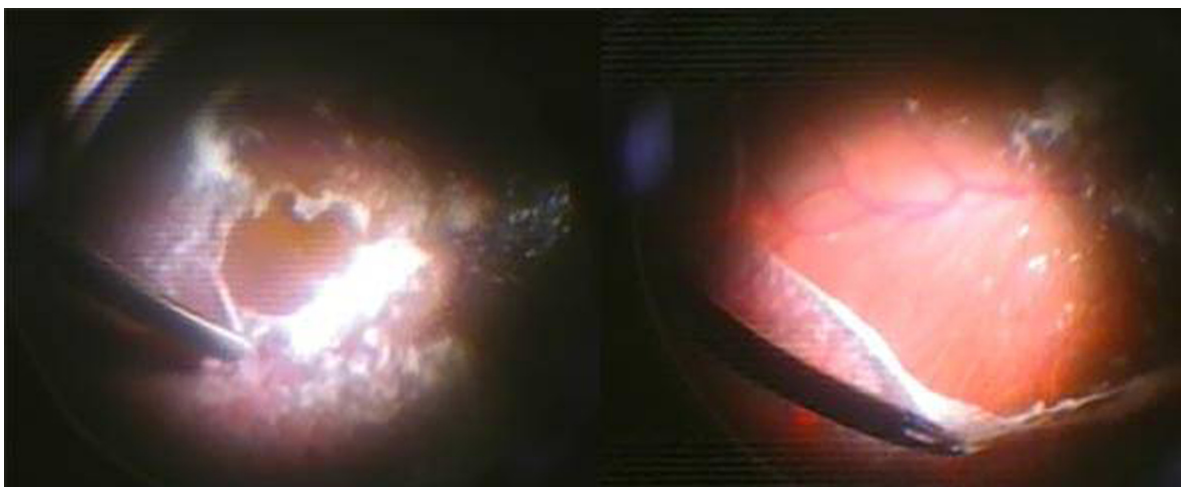


Figure 2 Removal of vitreous cortex stained by triamcinolone.

Success was defined as the absence of inflammatory episodes in the postoperative period extending to a minimum of 6 months.

Statistical analysis

Data were collected, coded, and entered into SPSS software (version 16; SPSS Inc, Chicago, IL). Qualitative data are presented as numbers and percentages, while the quantitative data were presented as mean and standard deviations. Fisher's exact test was used to compare the two qualitative data groups when the expected count was less than five. A paired sample *t*-test was used to compare the two paired groups with normal distribution. The *P*-value was considered as follows: $P > 0.05$ = not significant; $P < 0.05$ = significant; and $P < 0.01$ = highly significant.

Results

The age of the patients ranged from 15–65 years with a mean age of 35.7 years. Seven eyes belonged to females and three eyes belonged to males. The mean duration of uveitis before surgery was 9.4 months with the shortest duration being two months due to uncontrollable glaucoma. The aetiological classification of uveitis was identified as Vogt-Koyanagi-Harada disease in one eye, Behçet's disease in two eyes, juvenile idiopathic arthritis in one eye, and idiopathic in six eyes.

Table 1 demonstrates the preoperative and postoperative complications related to uveitis fibrinoid reactions. Less postoperative complications was the only significant difference found in the posterior synechia case.

The incidence of postoperative cystoid macular edema was 20%. Inflammatory activity is related to a need for topical and/or systemic steroids and CSA. There was a significantly lower number of eyes that required long-term (≥ 2 months) maintenance topical steroids and systemic CSA in the postoperative period (Table 2).

The incidence of unresponsive glaucoma to medical treatment was significantly higher (60%) preoperative

than it was postoperative (10%) (Fisher's exact test = 5.5, P value = 0.01). Postoperative IOP was elevated for a limited time (maximum 4 weeks) and controlled by medical treatment in 40% of eyes. Recurrent attacks of anterior uveitis after surgical intervention was reported in three eyes (3%). All of these eyes developed two attacks during the 6-month postoperative follow-up time. Success, according to our definition, was observed in seven eyes (70%).

The preoperative mean logMAR was 1.597 (Snellen's equivalent of 0.025 or 3/60). The mean logMAR was 0.883 (Snellen's equivalent of 0.133 or 6/45) at the 3-month follow-up visit and 0.763 (Snellen's equivalent 0.173 or 6/36) at the 6-month follow-up visit. The preoperative mean logMAR (0.025) improved to 0.883 at the 3-month visit and 0.763 at the 6-month visit. This represents a statistically significant improvement (P value = 0.013 and 0.04, respectively) (Table 3 and Figure 3).

VA improved in 70% of eyes, worsened in 20%, and stabilized in 10%. VA improvement (≥ 6 lines) occurred in 30% of eyes. Table 4 summarizes the preoperative VA and final VA for all patients.

Intraoperative complications included retinal breaks in two eyes (20%) and lens material in vitreous cavity in one eye (10%). Table 5 lists the postoperative complications. The causes of limited postoperative VA (Table 5) were CME in two eyes (20%) (Figure 4), pale optic nerve head in one eye (10%), hypotony in three eyes (30%), and residual ERM in two eyes (20%). Residual ERM with no anteroposterior traction and no macular detachment (Figure 5) did not undergo reinterference.

Reinterference was required in two eyes. One eye required subscleral trabeculectomy for glaucoma that was resistant to medical treatment. Epiretinal membrane with traction macular detachment was found in one eye (Figure 6), requiring dissection and a silicon oil reinjection. Posterior capsule opacification (PCO) was found in two

Table 1 Comparison between preoperative and postoperative complications related to fibrinoid reaction

Complications	Postoperative		Postoperative		Fisher's exact test	P-value
	N	%	N	%		
Posterior synechia	6	60	1	10	5.53	0.019*
Retroiridial membrane	2	20	0	0	2.22	0.14
Occlusio papillae	2	20	1	10	0.39	0.53
Cylytic membrane	1	10	1	10	0.00	1.00
Epiretinal membrane	2	20	2	20	0	1.00
Vitreous membranes	1	10	0	0	1.05	0.3
Vitreomacular membranes	2	20	0	0	2.22	0.14

Note: *Significant.

Table 2 Preoperative and postoperative steroids and immunosuppressants

Compilations	Preoperative		Postoperative		Fisher exact test	P-value
	N	%	N	%		
Systemic steroids	4	40	1	10	2.4	0.121
CSA	10	100	1	10	16.364	0.000**
Topical steroid maintenance	10	100	5	50	6.67	0.01*

Notes: *Significant; **Highly significant.

Abbreviation: CSA, cyclosporin A.

eyes, which were indicated for neodymium supported by yttrium-aluminum-garnet (Nd:YAG) laser posterior capsulotomy.

Discussion

The visual rehabilitation of eyes with chronic uveitis and cataracts is a difficult challenge, especially when the posterior segment is involved.⁸ One report describes the technique performing cataract surgery first (phacoemulsification or standard extracapsular cataract extraction) and posterior chamber IOL implantation followed by subsequent vitreous surgery.⁹ This technique may be useful for eyes in which the vitreous haze is not significant enough to impair VA. Inflamed vitreous containing inflammatory cells and cytokines come in close contact with the posterior capsule. Posterior capsule opacification and cyclitic membrane are high when this technique is used. Furthermore, inflammatory membranes on the ciliary body and retina lead to hypotony and traction retinal detachment, respectively. This complicates subsequent vitrectomy as some eyes require IOL removal due to severe membranous reactions around the implant, which hinder the viewing of the posterior segment and the patient's vision.^{2,10}

Another technique is to remove the whole lens and conduct a complete vitrectomy without IOL implantation. This technique is associated with less recurrence of uveitis, less postoperative inflammatory activity, and a decreased number of drugs needed for control due to the removal of vitreous containing inflammatory cells and cytokines. However, there is a risk of developing rubeosis and neovascular glaucoma especially in eyes with retinal ischemia.¹¹

Table 3 Comparison between preoperative and postoperative logMAR

Mean logMAR	Mean logMAR	SD	t/z	P value
Preoperative	1.597	0.91	3.101	0.013*
Postoperative at 3 months	0.883	0.57		
Preoperative	1.597	0.91	2.74	0.023*
Postoperative at 6 months	0.663	0.57		

Note: *P < 0.05 = significant.

Another study described the technique of pars plana phacofragmentation and posterior chamber IOL in front of the anterior capsule after the vitrectomy is finished in diabetic eyes undergoing phacovitrectomy.¹² This technique avoids corneal wound leakage. Our study used microcoaxial phacoemulsification with a 2.2 mm incision and suturing of small corneal wounds at the end of the phacoemulsification to decrease hypotony and leakage. Furthermore, pars plana phacofragmentation defers corneal clouding to the end of surgery. The present study used Alcon INFINITI™ System with OZil IP (Houston, TX) that has the advantages of torsional and micro pulsed ultrasound delivery, which has less effect on corneal endothelium and clarity and less ultrasound and less iris trauma that may increase iritis. The pars plana phacofragmentation technique has a high incidence of nuclear fragment dislocation to vitreous cavity, iris shaving by IOL haptics, and PCO requiring YAG laser capsulotomy. All of these disadvantages make this technique unsuitable for uveitic eyes. Therefore, the present study used an anterior approach to phacoemulsification with hydrophobic acrylic IOL implantation in the bag. The value of hydrophobic acrylic was similarly reported previously.¹³

Another study also described a phacoemulsification technique that is followed by total vitrectomy and defers IOL implantation until the end of surgery.⁵ This technique allows aphakic vitrectomy by eliminating optical interference with the IOL edge, which allows for safer indentation

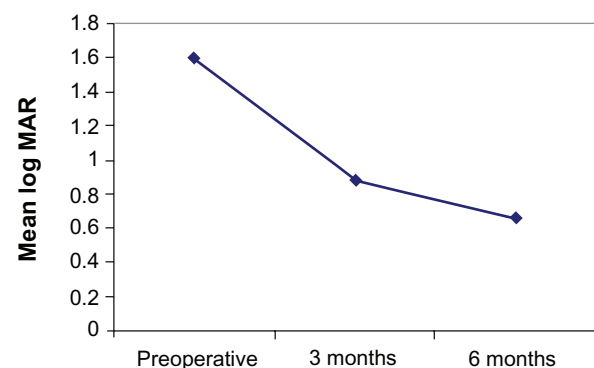
**Figure 3** Improvement of mean logMAR from preoperative to postoperative visits (3 and 6 months).

Table 4 Preoperative and postoperative VA at 6 months

VA (decimal)	Preoperative		Postoperative	
	N	%	N	%
0.5–1.0	0	0	3	30
0.2–0.4	3	30	2	20
0.05–0.1	2	20	3	30
0.016–0.033	2	20	1	10
CF, HM	3	30	1	10
NPL	0	0	0	0

Abbreviations: CF, counting fingers; HM, hand motion; LP, light perception; NLP, no light perception; VA, visual acuity.

and fluid-gas exchange with better visualization and without IOL endothelial touch. Therefore, we selected this technique for our study.

Our study also involved 20-gauge vitrectomy with proper suturing of sclerotomies at the end of surgery. The only difference of our technique from that described by Soheilian et al⁵ is that they used sutureless 25-gauge vitrectomy. The advantages of the 25-gauge vitrectomy are smaller instruments and incisions leading to improved operative time and hastened recovery with less inflammation postoperatively. However, our study intentionally avoided a sutureless 25-gauge or even a 23-gauge vitrectomy because of potential postoperative hypotony that may lead to activation of uveitis that itself may induce more hypotony. This is supported by the higher incidence of posterior synechiae (47.36%) in Soheilian et al⁵ compared to our study (10%). Therefore, 25-gauge vitreous surgery had more incidents of peripheral anterior synechiae and CME than the 20-gauge technique in uveitic eyes. This may be explained by temporary hypotony with the sutureless 25-gauge technique. It should be noted, on the other hand, Hsu et al¹⁴ reported lower incidents of hypotony with oblique cannula insertions (1.8%) than with direct cannula insertions (10%) in 25-gauge vitrectomy. The concept of temporary hypotony in sutureless vitrectomy is supported by a 12-fold higher incidence of endophthalmitis after 25-gauge vitrectomy (0.23%; 7/3103 eyes) than in 20-gauge vitrectomy (0.018%; 1/5498 eyes)¹⁵ reported by the Wills Eye Institute retina

Table 5 Postoperative complications and causes of limited postoperative visual acuity

Postoperative complications	N	%
Corneal edema	2	20
Cystoid macular edema	2	20
Hypotony	3	30
Posterior capsule opacification	2	20
Residual epiretinal membrane	2	20
Pale optic nerve head	1	10

service. The same issue was reported by Scott et al¹⁶ who found the incidence of endophthalmitis was 28-fold higher in 25-gauge vitrectomy (0.84%; 11/1307 eyes) compared to the 20-gauge technique (0.03%; 2/6375 eyes).

None of the eyes in our study showed VA of 0.5–1.0 preoperatively, and 30% of eyes showed this level of acuity postoperatively. Our study also reported postoperative VA of 0.2–0.4 in 20% of eyes and VA of 0.05–0.1 in 30% of eyes. These results were similar to Soheilian et al⁵ who reported postoperative VA of 0.2–0.4 in 31% of eyes and VA of 0.05–0.1 in 31% of eyes. Therefore, both studies found an improvement in VA postoperatively.

Our study reported a VA improvement in 70% of eyes, deterioration in 20%, and stabilization in 10%. This was similar to Androudi et al⁸ who described VA improvement in 72%, deterioration in 14%, and stabilization in 14%. One of the eyes with worsened postoperative VA had persistent hypotony that needed permanent silicon oil tamponade. Another eye had ERM that induced macular detachment (Figure 6) and required reinterference to dissect the ERM. The eye with no improvement in postoperative VA had CME (Figure 4). This patient refused posterior subtenon TA injection after the operation.

Another potential role for combining pars plana vitrectomy with phacoemulsification in these eyes was the removal of the vitreous collagen depot for antigen. Furthermore, removal of the gel substrate for lymphocytes adhesion may play a role in longterm control. The free circulation of aqueous in the posterior segment with anterior chamber-associated immune deviation (ASAIID) and topically applied steroids¹ helps to control intraocular inflammation.¹

The need for systemic CSA as well as topical steroids for maintenance significantly decreased after phacovitrectomy in this study. Figueroa et al provide evidence that this is mainly attributed to vitrectomy.¹⁷ They reported a drop in the number of relapses with a decreased need for further treatment following vitrectomy as anti-inflammatory for intermediate uveitis.

The role of pars plana vitrectomy in VA improvement was the removal of vitreous membranes and opacities and the management of associated traction macular detachment during the operation. Furthermore, vitrectomy may play a role in treating cystoid macular edema. This may be achieved by removing vitreous traction or allowing the free circulation of topically applied diclofenac to the posterior segment. This is supported by a randomized study¹⁸ that reported a significantly higher number of eyes with improved CME in the vitrectomy group (33%) versus the medical treatment group (9%).

Macula thickness: macular cube 512 × 128

OD OS

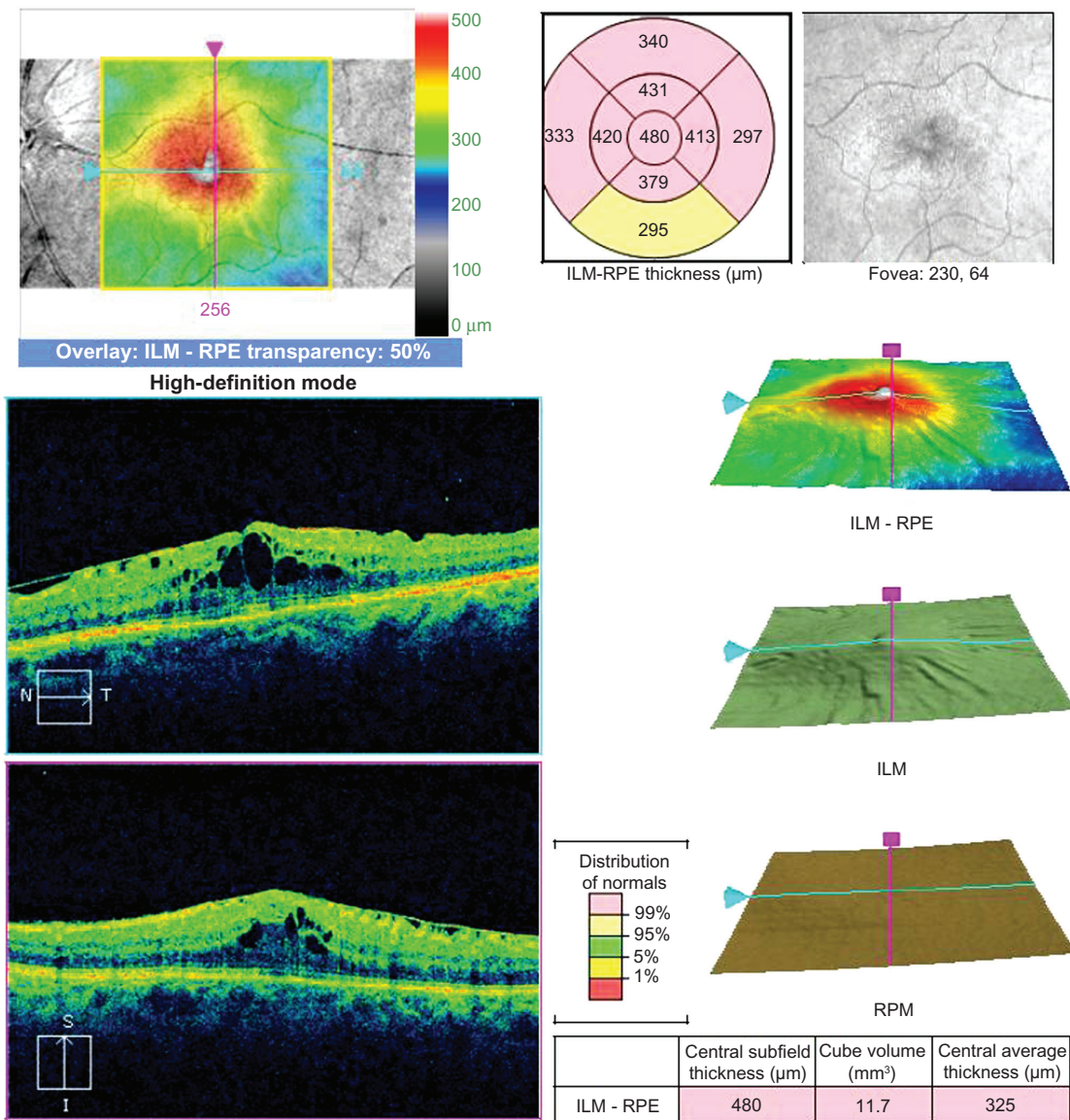


Figure 4 Eye 5 in the series with postoperative cystoid macular edema.

Furthermore, CME may be treated using intraocular triancinolone acetonide during surgery to stain the posterior hyaloid or through its use in the posterior subtenon injection. This explains the low incidence of postoperative CME (20%) in the present study compared to the postoperative incidence (63.1%) in the study by Soheilian et al.⁵ Moreover, their higher rate of incidence may be due to the inclusion of eyes (40%) with pars planitis and the high incidence (84%) of CME preoperatively. The higher incidence of CME in the study by Soheilian et al.⁵ may also be related to temporary hypotony, which is associated with the sutureless 25-gauge technique compared to the 20-gauge sutured technique used in this study.

In our study, ERM was detected postoperatively in two eyes (20%). One eye and did not require surgical interference for the absence of anteroposterior traction. while another eye required further removal of ERM for macular detachment. The value of vitrectomy is clear in its prevention of ERM by removing the vitreous scaffold. This is supported by the 40% incidence of ERM reported by Donaldson et al.¹⁹

The potential role that phacoemulsification plays in VA improvement is removing cataracts that represent media opacity and controlling IOP through the dissection of synchiae. Furthermore, removing cataracts plays a diagnostic role by removing media-opacity in order to clinically examine the posterior segment and allow OCT macula

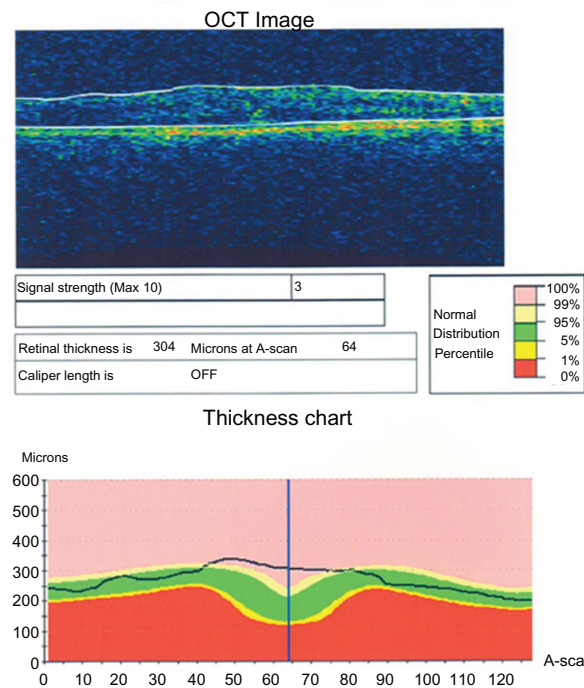
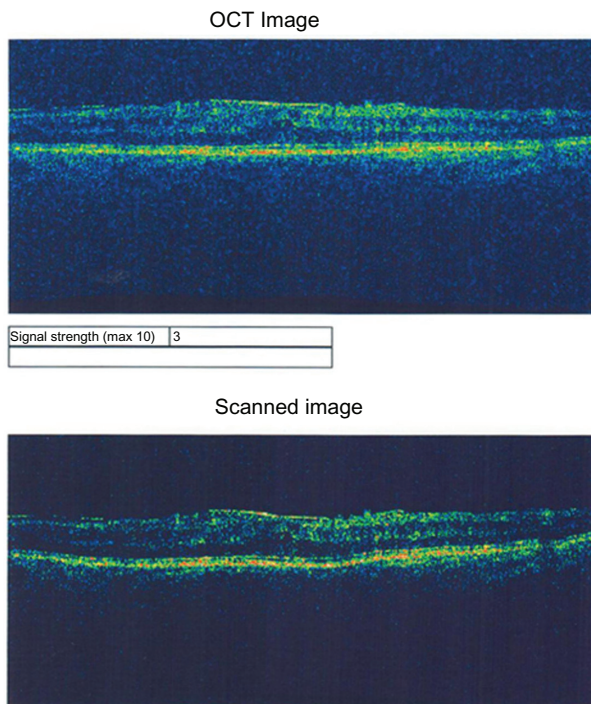
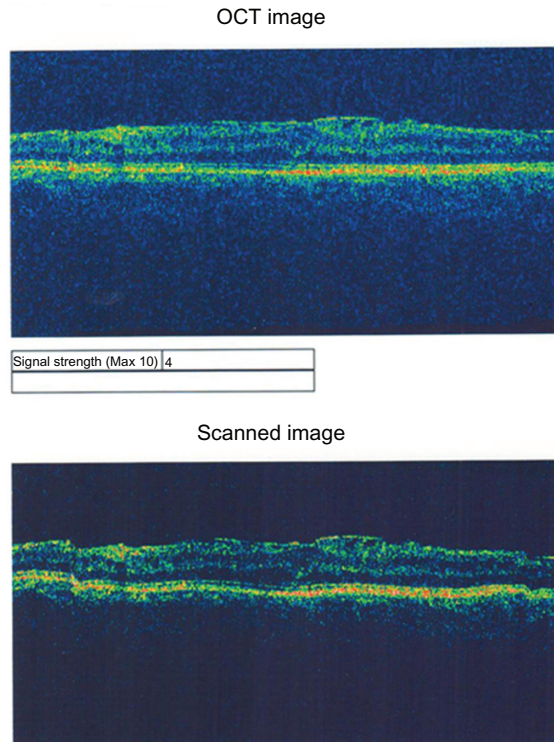
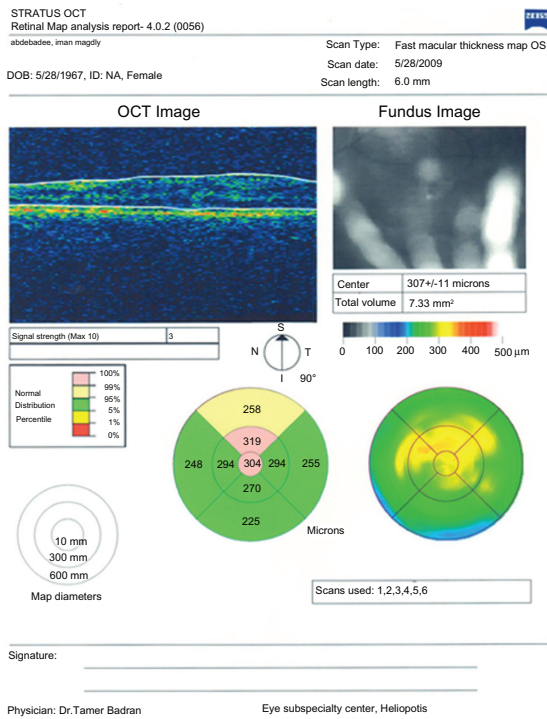


Figure 5 Eye 3 in the series with residual epiretinal membrane exerting no anteroposterior traction or macular detachment.

examination whenever needed. This denotes the importance of phacoemulsification combined with vitrectomy rather than vitrectomy alone. This importance of removing cataracts during surgery is clear in the evidence of another study¹⁷ that used pars plana vitrectomy alone as a treatment for

intermediate uveitis. Approximately 55% of eyes in this study developed posterior subcapsular cataracts throughout the follow-up period. They stated that vitrectomy could have accelerated the development of cataracts, especially in uveitic eyes.

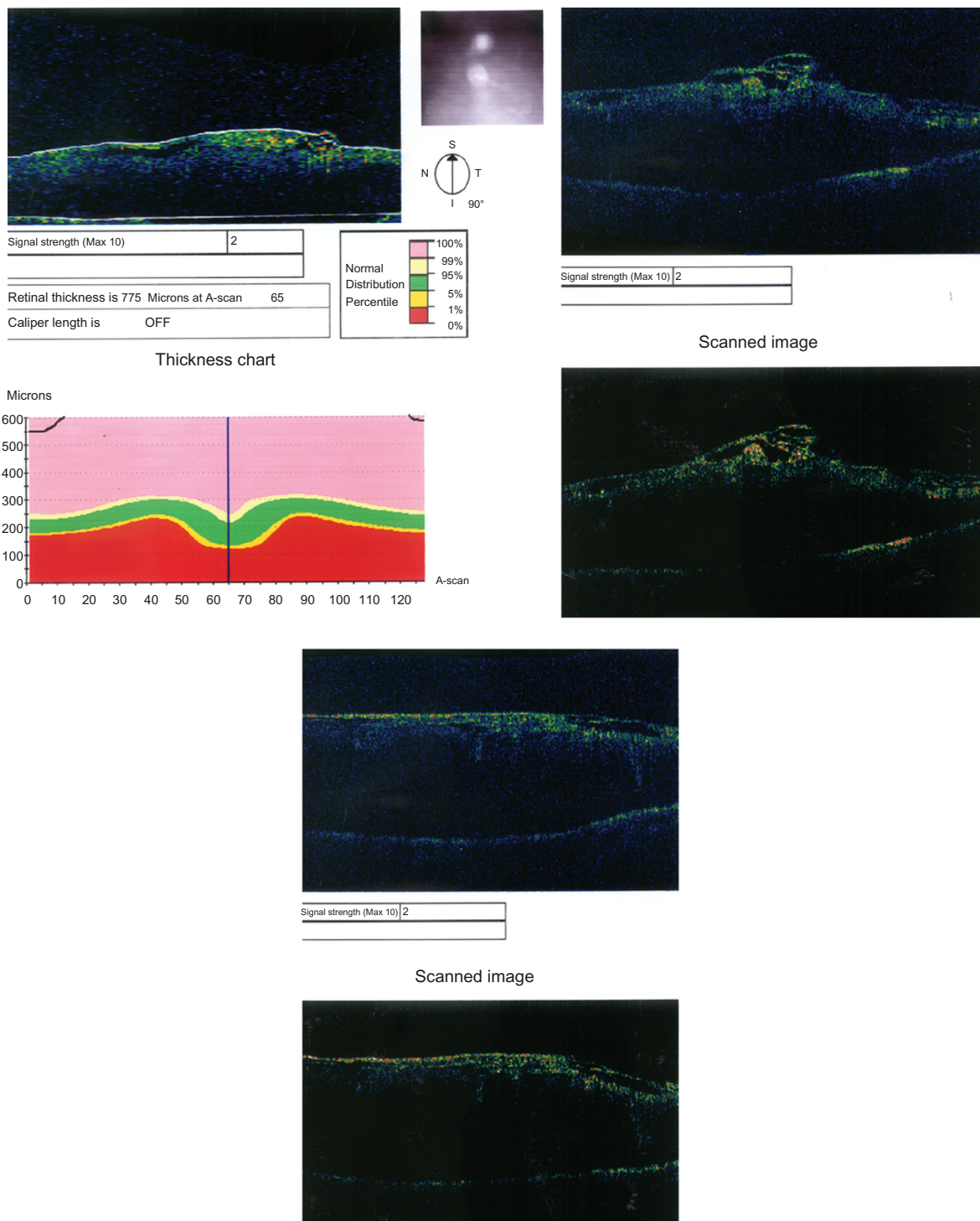


Figure 6 Eye 7 in the series with residual epiretinal membrane, inducing macular detachment.

Postoperative IOP was elevated in 40% of eyes. The IOP was out of medical control in 10% of eyes while preoperative glaucoma was out of control in 60% of eyes. This difference is statistically significant. This may be explained by the fact that preoperative elevated IOP was multifactorial due to synechia,

and it responded to the use of longterm steroids. Postoperative IOP elevation could be due to posterior subtenon TA or the administration of a short-course of topical steroids, making it easier to control. The dissection of posterior synechia and peripheral anterior synechia may help to reverse IOP elevation.

Pars plana vitrectomy may play a role in the treatment and/or prevention of hypotony through the dissection of the epiciliary membrane during surgery and/or injection of silicon oil at the end of surgery. Only one eye (10%) in our study had persistent hypotony and required the permanent use of silicon oil. This was similar to an incidence in another study⁵ where phthisis bulbi appeared in one eye (5.3%); however, it is unclear whether silicon oil was used.

Conclusion

Perfect suppression of intraocular inflammation using CSA enhances combination of microincision phacoemulsification and sutured standard pars plana vitrectomy in resistant non-infective panuveitis with visually significant cataracts. This technique helps to control uveitis with less medication while reducing complications related to fibrinous reactions as PAS. These help to decrease the incidence of glaucoma secondary to uveitis and to restore useful vision in most eyes.

Disclosure

The author reports no conflicts of interest in this work.

References

- American Academy of Ophthalmology. Section 9: Intraocular inflammation and uveitis. In: *Basic and Clinical Science Course*. San Francisco: American Academy of Ophthalmology; 2007–2008.
- Diamond JG, Kaplan HJ. Lensectomy and vitrectomy for complicated cataract secondary to uveitis. *Arch Ophthalmol*. 1978; 96(10):1798–1804.
- Koenig SB, Mieler WF, Han DP, Abrams GW. Combined phacoemulsification, pars plana vitrectomy, and posterior chamber intraocular lens insertion. *Arch Ophthalmol*. 1992;110(8):1101–1104.
- Foster RE, Lowder CY, Meisler DM, Zavok ZN, Meyers SM, Ambler JS. Combined extracapsular cataract extraction, posterior chamber intraocular lens implantation, and pars plana vitrectomy. *Ophthalmic Surg*. 1993;24(7):446–452.
- Soheilian M, Mirdehghan SA, Peyman GA. Sutureless combined 25-gauge vitrectomy, phacoemulsification, and posterior chamber intraocular lens implantation for management of uveitic cataract associated with posterior segment disease. *Retina*. 2008;28(7):941–946.
- Nussenblatt R. The expanding use of immunosuppression in the treatment of non-infectious ocular disease. *J Autoimmun*. 1995; 5(Suppl A):247–257.
- Hogan MJ, Kimura SJ, Thygeson P. Signs and symptoms of uveitis. I. Anterior uveitis. *Am J Ophthalmol*. 1959;47(5 Part 2):155–170.
- Androudi S, Ahmed M, Fiore T, Brazitikos P, Foster CS. Combined pars plana vitrectomy and phacoemulsification to restore visual acuity in patients with chronic uveitis. *J Cataract Refract Surg*. 2005; 31(3):472–478.
- Foster CS, Fong LP, Singh G. Cataract surgery and intraocular lens implantation in patients with uveitis. *Ophthalmology*. 1989; 96(3):281–288.
- Hooper PL, Rao NA, Smith RE. Cataract extraction in uveitis patients. *Surv Ophthalmol*. 1990;35(2):120–144.
- Poliner LS, Christianson DJ, Escoffery RF, Kolker AE, Gordon ME. Neovascular glaucoma after intracapsular and extracapsular cataract extraction in diabetic patient. *Am J Ophthalmol*. 1985;100(5):637–643.
- Mackool RJ. Pars plana vitrectomy and posterior chamber intraocular lens implantation in diabetic patients. *Ophthalmology*. 1989; 96(11):1679–1980.
- Kim CY, Kang SJ, Lee SJ, Park SH, Koh HJ. Opacification of a hydrophilic acrylic intraocular lens with exacerbation of Behçet's uveitis. *J Cataract Refract Surg*. 2002;28(7):1276–1287.
- Hsu J, Chen E, Gupta O, Fineman MS, Grag SJ, Regillo CD. Hypotony after 25-gauge vitrectomy using oblique versus direct cannula insertions in fluid-filled eyes. *Retina*. 2008;28(7):937–940.
- Kunimoto DY, Kaiser RS, for Wills Eye Retina Service. Incidence of endophthalmitis after 20- and 25-gauge vitrectomy. *Ophthalmology*. 2007;114(12):2133–2137.
- Scott IU, Flynn HW Jr, Dev S, et al. Endophthalmitis after 25-gauge and 20-gauge pars plana vitrectomy: incidence and outcomes. *Retina*. 2008;28(1):138–142.
- Figueroa MS, Noval S, Contreras I, et al. Pars plana vitrectomy as anti-inflammatory therapy for intermediate uveitis in children. *Arch Soc Esp Oftalmol*. 2010;85(12):390–394.
- Tranos P, Scott R, Zambarajki H, Ayliffe W, Pavesio C, Charteris DG. The effect of pars plana vitrectomy on cystoid macular oedema associated with chronic uveitis: a randomised controlled pilot study. *Br J Ophthalmol*. 2006;90(9):1107–1110.
- Donaldson MJ, Pulido JS, Herman DC, Diehl N, Hodge D. Pars planitis: a 20-year study of incidence, clinical features, and outcomes. *Am J Ophthalmol*. 2007;144(6):812–817.

Clinical Ophthalmology

Publish your work in this journal

Clinical Ophthalmology is an international, peer-reviewed journal covering all subspecialties within ophthalmology. Key topics include: Optometry; Visual science; Pharmacology and drug therapy in eye diseases; Basic Sciences; Primary and Secondary eye care; Patient Safety and Quality of Care Improvements. This journal is indexed on

Submit your manuscript here: <http://www.dovepress.com/clinical-ophthalmology-journal>

Dovepress

PubMed Central and CAS, and is the official journal of The Society of Clinical Ophthalmology (SCO). The manuscript management system is completely online and includes a very quick and fair peer-review system, which is all easy to use. Visit <http://www.dovepress.com/testimonials.php> to read real quotes from published authors.