


Generalized Pustular Psoriasis During Early Pregnancy Successfully Treated with Spesolimab: A Case Report

Xinlong Chen , Degui Chang, Chenjian Tang

Hospital of Chengdu University of Traditional Chinese Medicine, Chengdu, People's Republic of China

Correspondence: Chenjian Tang, Hospital of Chengdu University of Traditional Chinese Medicine, Chengdu, People's Republic of China, Email chenjiantang2025@163.com

Abstract: Generalized pustular psoriasis (Gpp) of pregnancy usually occurs in the third trimester of pregnancy. We present a patient with Gpp at 8 weeks of gestation. The patient was finally treated with spesolimab, and her condition improved significantly after 3 days.

Keywords: spesolimab, generalized pustular psoriasis

Introduction

Generalized Pustular Psoriasis (GPP) is a rare, severe, and potentially life-threatening form of psoriasis characterized by widespread sterile (non-infectious) pustules, systemic inflammation, and abrupt onset. It is distinct from plaque psoriasis and requires urgent medical intervention due to its systemic complications. GPP triggered or worsened by pregnancy, predominantly occurs in the third trimester.¹ This condition poses significant risks for adverse neonatal outcomes, such as placental insufficiency, congenital anomalies, stillbirth, and neonatal mortality.^{2–4} GPP is driven by dysregulation of the interleukin-36 (IL-36) pathway, where excessive IL-36 signaling bridges innate and adaptive immune responses, leading to neutrophil-dominated inflammation. While the exact etiology remains unclear, genetic predispositions (eg, IL36RN mutations) contribute to disease susceptibility.⁵ Effective management requires prompt therapeutic intervention and rigorous maternal-fetal monitoring to minimize fetal risks. Treatment options for GPP during pregnancy remain understudied. Current approaches include cyclosporine, corticosteroids, TNF- α inhibitors, IL-17/IL-12/23 inhibitors, and granulocyte/monocyte adsorption apheresis.^{6,7} As a humanized anti-IL-36 receptor monoclonal antibody, spesolimab directly inhibits the proinflammatory IL-36 cascade. This mechanism is particularly relevant in GPP, where IL-36 overexpression drives pathological neutrophil activation and epidermal hyperkeratosis. To date, there have been no reported cases of biologic agents, particularly IL-36 inhibitors, being used to treat GPP during early pregnancy. We present a novel case of early pregnancy-associated generalized pustular psoriasis demonstrating remarkable therapeutic response to spesolimab.

Case Presentation

A 38-year-old woman at 8 weeks of pregnancy with more than 10 years of history of plaque psoriasis was well controlled with topical corticosteroids. Family history of similar symptoms was denied. Her temperature on admission was 37.5°C. Physical examination revealed generalized edematous erythema, with edema of the lower limbs marked by numerous pustules that partially fused into pus lakes (Figure 1). The PGA (Physician Global Assessment) score and PASI (Psoriasis area and severity index) score were 3.2 and 45, respectively. Laboratory tests showed increased white blood cells ($11.85 \times 10^9/L$), C-reactive protein (CRP) (67.93mg/L). After multi-department consultation, Gpp was diagnosed and the patient was asked to be hospitalized in the dermatology department after induced abortion. The patient underwent induced abortion on

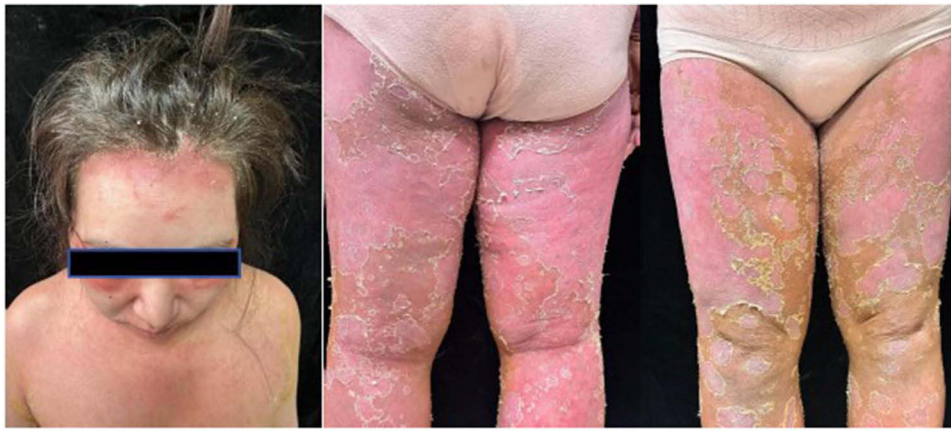

Figure 1 Clinical presentation of skin lesions before treatment.

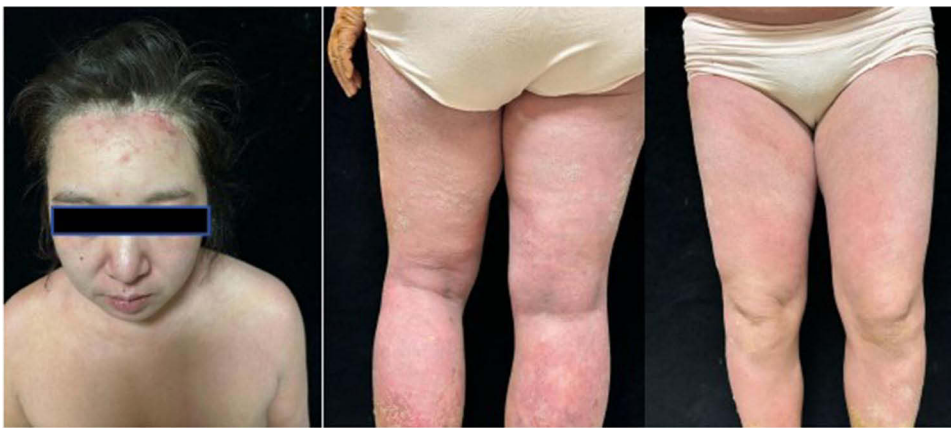

Figure 2 Clinical improvement of skin lesions following treatment.

December 2 and was hospitalized in the Department of dermatology after surgery. After completing the relevant examinations, the patient received an intravenous infusion of spesolizumab injection 900mg, and his condition improved 3 days later (Figure 2). Eighteen days later, the patient was administered Methotrexate tablets to control plaque psoriasis. Unfortunately, the patient had a strong desire to continue the pregnancy, but she was required to undergo an abortion.

Discussion

The management of GPP in pregnancy demands special consideration. Nevertheless, therapeutic evidence remains limited for this population. Notably, retinoids and methotrexate are strictly contraindicated during pregnancy due to their teratogenic risks. Narrowband UVB, topical steroids, prednisone, cyclosporine, certolizumab, secukinumab, Infliximab, Ustekinumab and spesolimab have been reported in the treatment of pustular psoriasis with good safety.⁷⁻¹¹ However, these reports were not sufficient to fully evaluate the safety of the aforementioned treatment options in pregnant women with GPP, and further investigation is warranted. Most of the current treatment options are derived from case reports, lacking large-scale clinical studies or robust real-world data. This study provides preliminary evidence supporting the short-term efficacy and safety of spesolimab in early pregnant patients with GPP, several limitations should be acknowledged: Firstly, the observational period was restricted to the active phase of GPP flare and immediate postpartum outcomes. Long-term data on maternal health, fetal development, and potential late-onset adverse effects (eg, immune impacts on the infant) are lacking. Further studies with extended follow-up are warranted. Secondly, the study primarily included women with severe GPP flares requiring urgent intervention. Thus, the findings may not generalize to pregnant patients with mild/moderate GPP, or women at high risk of miscarriage, in whom the risk-benefit profile of biologics remains uncertain.

Conclusion

In summary, this case highlights the potential of spesolimab as a safe and effective therapy for refractory GPP during early pregnancy, achieving rapid disease control.

Data Sharing Statement

Data supporting the findings of this study are available from the corresponding author upon reasonable request.

Ethics Approval

Institutional approval was obtained for the study and for the publication of the case details by Hospital of Chengdu University of Traditional Chinese Medicine.

Consent for Publication

The patient had signed informed consent and provided written informed consent for publication of anonymized clinical details and images. No identifiable information is included in this report. This article adheres to the applicable CARE REport (CARE) guidelines.

Funding

There is no funding to report.

Disclosure

The authors report no conflicts of interest in this work.

References

1. Trivedi MK, Vaughn AR, Murase JE. Pustular psoriasis of pregnancy: current perspectives. *Int J Womens Health*. 2018;10:109–115. doi:10.2147/IJWH.S125784
2. Iwasaki A, Kawakami H, Okubo Y. Granulocyte/monocyte adsorption apheresis as a novel therapeutic approach in the treatment of an impetigo herpeticiformis case. *Ther Apher Dial*. 2018;22(4):414–416. doi:10.1111/1744-9987.12653
3. Chhabra G, Chanana C, Verma P, et al. Impetigo herpeticiformis responsive to secukinumab. *Dermatol Ther*. 2019;32(5):e13040. doi:10.1111/dth.13040
4. Mohaghegh F, Galehdari H, Rezaie M. Pustular psoriasis of pregnancy in early first trimester: a case report. *Clin Case Rep*. 2021;9(7):e04438. doi:10.1002/ccr3.4438
5. Samotij D, Szczech J, Reich A. Generalized pustular psoriasis: divergence of innate and adaptive immunity. *Int J Mol Sci*. 2021;22(16):9048. doi:10.3390/ijms22169048
6. Seishima M, Fujii K, Mizutani Y. Generalized pustular psoriasis in pregnancy: current and future treatments. *Am J Clin Dermatol*. 2022;23(5):661–671. doi:10.1007/s40257-022-00698-9
7. Yang C, Wang Y, Li R, et al. Successful treatment of recalcitrant generalized pustular psoriasis of pregnancy with spesolimab. *J Dermatolog Treat*. 2024;35(1):2334791. doi:10.1080/09546634.2024.2334791
8. van Ierland K, Vredevoogd C, Roach R, et al. Severe case of pustular psoriasis during pregnancy. *BMJ Case Reports*. 2024;17(3):e258198. doi:10.1136/bcr-2023-258198
9. Zhang J, Xia P, Wan L, et al. Generalized pustular psoriasis of pregnancy successfully treated with secukinumab. *Indian J Dermatol Venereol Leprol*. 2023;89:886–888. doi:10.25259/IJDVL_1060_2022
10. Babuna Kobaner G, Polat Ekinci A. Infliximab for the treatment of recalcitrant generalized pustular psoriasis of pregnancy: report of a challenging case. *Dermatolog Therapy*. 2020;33(4). doi:10.1111/dth.13571
11. Wu H, Shen YN, Wu Z, et al. Ustekinumab in the treatment of generalized pustular psoriasis in a pregnant patient. *Clin Cosmetic Invest Dermatol*. 2024;Volume 17:1107–1110. doi:10.2147/CCID.S451738

International Medical Case Reports Journal

Publish your work in this journal

The International Medical Case Reports Journal is an international, peer-reviewed open-access journal publishing original case reports from all medical specialties. Previously unpublished medical posters are also accepted relating to any area of clinical or preclinical science. Submissions should not normally exceed 2,000 words or 4 published pages including figures, diagrams and references. The manuscript management system is completely online and includes a very quick and fair peer-review system, which is all easy to use. Visit <http://www.dovepress.com/testimonials.php> to read real quotes from published authors.

Submit your manuscript here: <https://www.dovepress.com/international-medical-case-reports-journal-journal>

Dovepress

Taylor & Francis Group