

# Cutaneous Granuloma Resulting from Mixed Infection with *Mycobacterium marinum* and *Candida metapsilosis*: A Case Report of Successful Treatment

Jing Li <sup>1,2,\*</sup>, Yinggai Song <sup>3,\*</sup>, Xiao Liu<sup>1,2</sup>, Jing Pan<sup>1,2</sup>

<sup>1</sup>Department of Dermatology, Beijing Jishuitan Hospital, Capital Medical University, Beijing, People's Republic of China; <sup>2</sup>Fourth Medical College of Peking University, Beijing, People's Republic of China; <sup>3</sup>Department of Dermatology and Venerology, Peking University First Hospital, Beijing, People's Republic of China

\*These authors contributed equally to this work

Correspondence: Jing Li, Department of Dermatology, Beijing Jishuitan Hospital, Capital Medical University, No. 31 Xijiekou East Street, Xicheng District, Beijing, 100035, People's Republic of China, Email [sophiali79@126.com](mailto:sophiali79@126.com)

**Background:** *Mycobacterium marinum* and *Candida metapsilosis* are rare pathogens that cause chronic cutaneous and soft tissue infections. Although molecular technologies have improved their diagnosis, both diseases are challenging to treat. Here, we describe the first case of cutaneous granuloma caused by concurrent *M. marinum* and *C. metapsilosis* infections.

**Case Presentation:** A 67-year-old male patient presented with a one-year history of painful erythematous nodules on his left ring finger after a fish stabbing. He was apparently immunocompetent and received no immunosuppressive treatment. Histopathological examination revealed infectious granuloma. Positive cultures for mycobacteria and fungi, along with molecular testing, confirmed the mixed infection with *M. marinum* and *C. metapsilosis*. Considering his old age and hepatitis B core antibody, we initiated treatment with oral clarithromycin, topical sulfadiazine silver cream (SSC), and topical nifuratel nystatin gel (NNG). Owing to adverse events, the course of clarithromycin was limited to ten days. Nonetheless, a three-month regimen of continuous topical SSC and NNG led to the complete recovery of his lesions without recurrence.

**Conclusion:** This is the first reported case of mixed infection with *M. marinum* and *C. metapsilosis*. The combination therapy with 10-day oral clarithromycin treatment and 3-month topical SSC and NNG successfully treated superficial infections caused by these two distinct pathogens. This case could offer a viable alternative for patients unable to endure prolonged systemic therapy. Further studies are required to verify its efficacy.

**Keywords:** *Mycobacterium marinum*, *Candida metapsilosis*, mixed infection, sulfadiazine silver, nystatin, clarithromycin

## Introduction

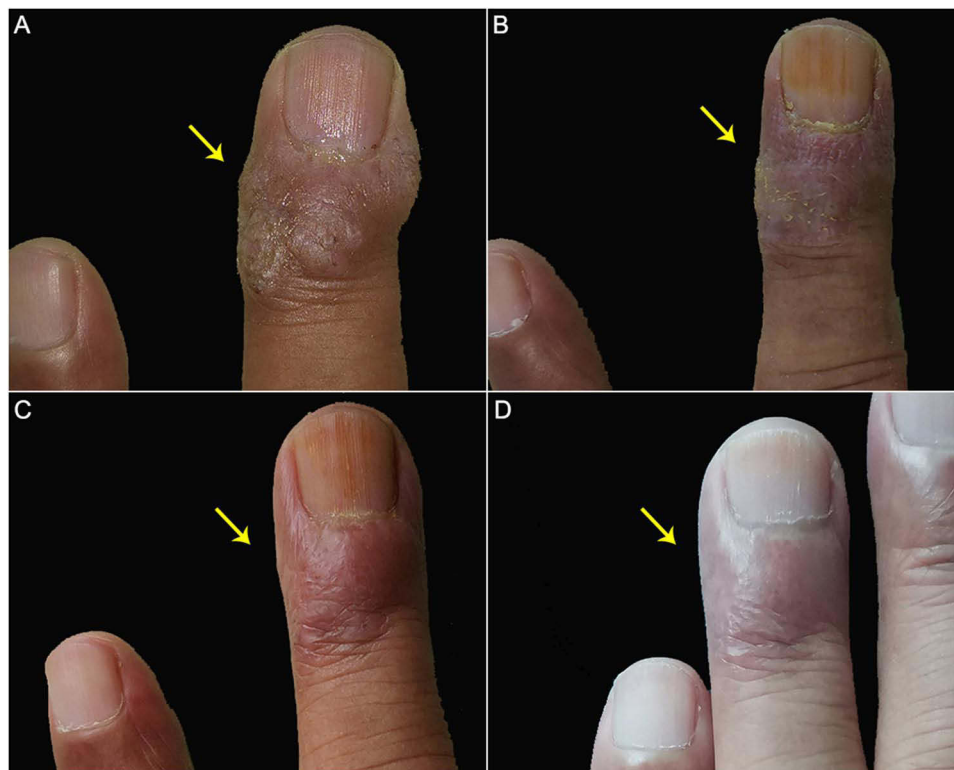
Cutaneous granulomas are characterized by skin inflammatory reactions caused by many stimuli and are categorized etiologically into infectious and non-infectious granulomas.<sup>1</sup> Infectious granulomas are triggered mainly by mycobacteria, parasites, or fungi.<sup>1</sup> *Mycobacterium marinum*, a slow-growing non-tuberculous mycobacterium (NTM), is an uncommon pathogen of chronic cutaneous and soft tissue infections.<sup>2</sup> Fish bites, skin injuries by shellfish or fishing tools, or contact with contaminated water are common causes of *M. marinum* infection.<sup>2,3</sup> *M. marinum* may usually cause superficial or sporotrichoid lesions and may involve deep tissues or even disseminated infections in immunocompromised individuals.<sup>2,4</sup> Although molecular techniques have improved its diagnosis, *M. marinum* remains challenging to treat due to its slow-growing nature and lack of a standard treatment regimen.<sup>3,4</sup> *M. marinum* infection usually requires combination therapies.<sup>2</sup> *Candida metapsilosis* is the least common and virulent within the *Candida parapsilosis* complex, but its prevalence and incidence have increased annually.<sup>5,6</sup> According to documented reports, *C. metapsilosis* was not only isolated from the blood samples of adults and older patients but also from those of neonates.<sup>5</sup> It may cause superficial candidiasis, deep infection,

candidemia, or even death.<sup>5,7-9</sup> The treatment is challenging because of increased resistance to some antifungal agents.<sup>5</sup> Here, we described the first case of cutaneous granuloma caused by concurrent infections with *M. marinum* and *C. metapsilosis*.

## Case Presentation

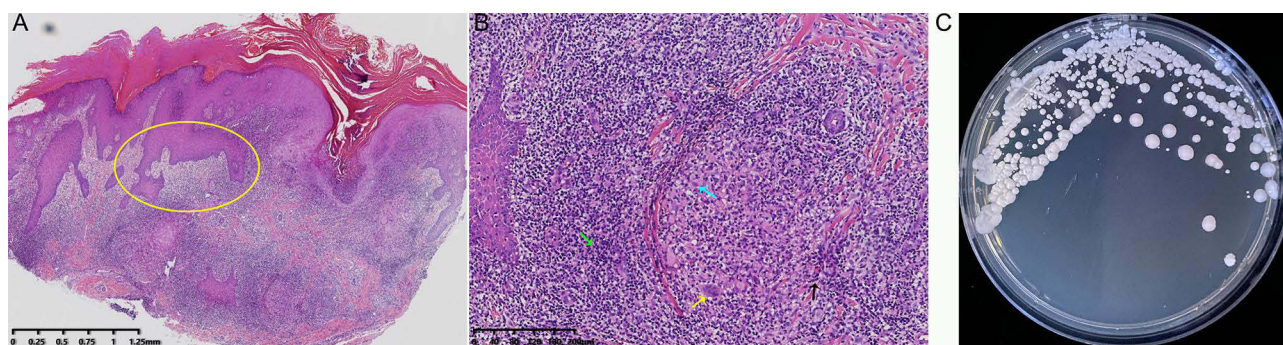
A 67-year-old immunocompetent male was presented with a one-year history of painful erythematous nodules on his left ring finger in April 2021. Initially, he was pricked while cleaning marine fish, leading to edema and erythema with tenderness at the distal end of his left ring finger. Considering normal routine blood test results and his refusal to undergo a biopsy for tissue culture, we administered cefixime to him as a tentative treatment. His lesions subsided marginally two weeks later, but apparent redness, swelling, nodules, and yellow crusts persisted. Topical administration of compound polymyxin B ointment alone showed minimal improvement after cessation of cefixime. His lesions expanded again two weeks after discontinuing the medication. The patient had no history of diabetes, liver illness, renal disease, or drug allergies except for hypertension. Physical examination revealed confluent erythematous plaques and nodules with crusts at the distal end of his left ring finger (Figure 1A). Lymph nodes in his left wrist and elbow were not palpable.

Histopathology of the biopsy specimens showed verrucous hyperplasia in the epidermis, non-caseating granulomatous inflammation, diffuse neutrophilic and lymphocyte aggregation, and abscess formation in the dermis (Figure 2A and B). Neither acid-fast staining nor periodic acid-Schiff staining yielded positive results. Using the mycobacterial culture system (Bactec MGIT 960, Becton, Dickinson and Company, USA), a mycobacterial culture was performed on the biopsy tissue in a liquid medium, which yielded positive results after four weeks.<sup>10,11</sup> The polymerase chain reaction (PCR) analysis did not detect *Mycobacterium tuberculosis*. *M. marinum* was identified using multiplex real-time PCR assays (Figure 3 and Appendix I).<sup>12,13</sup> Upon the fungal culture of biopsy tissue, smooth white yeast-like colonies were discovered on Sabouraud's Glucose Agar (SGA; BD™) (Figure 2C). The genomic DNA was extracted from the isolate

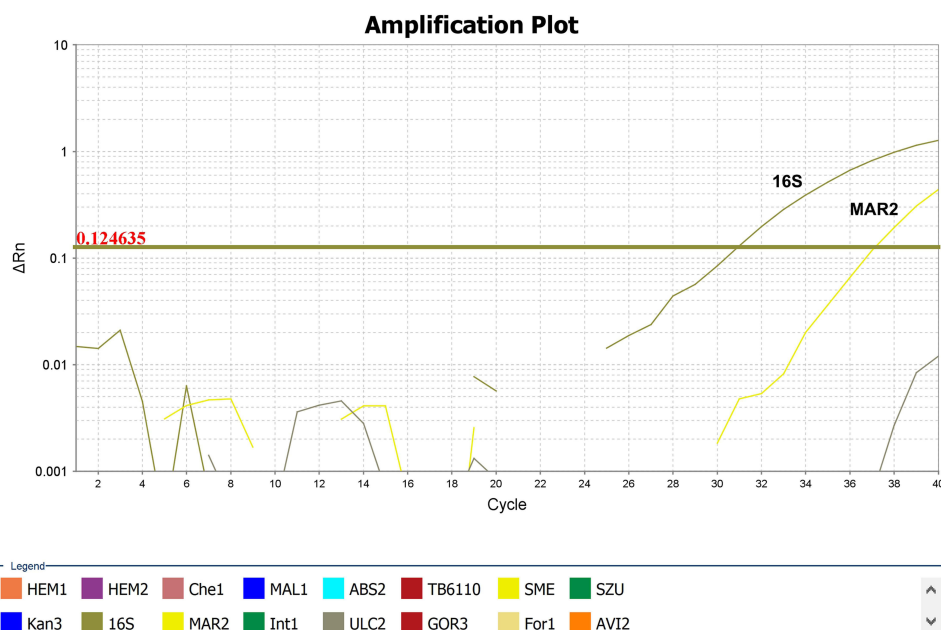


**Figure 1** Dermatological examination before and after treatment. (A) Before treatment, confluent erythematous plaques and nodules with crusts were found at the distal end of his left ring finger. (B) Ten days after receiving oral clarithromycin and topical SSC and NNG, there was still visible redness, swelling, and nodules on his finger. (C) One month after topical application of SSC and NNG, only one red nodule with a diameter of 2mm remained on his finger. (D) Three months after topical application of SSC and NNG, his lesion completely healed.

**Abbreviations:** SSC, sulfadiazine silver cream; NNG, nifuratel nystatin gel.



**Figure 2** Laboratory findings. (A) Pathologic findings of his lesion revealed verrucous hyperplasia in the epidermis (yellow circle shown), non-caseating granulomatous inflammation, and diffuse neutrophilic and lymphocyte aggregation in the dermis (hematoxylin-eosin staining, x20). (B) An enlarged view of his histopathology shows granulomatous inflammation with multinucleated giant cells (yellow arrow shown), histiocytes (blue arrow shown), lymphocytes (green arrow shown), and neutrophils (black arrow shown) (hematoxylin-eosin staining, x100). (C) The fungal culture of biopsy tissue showed smooth white yeast-like colonies.



**Figure 3** Analysis of biopsy samples using multiplex real-time PCR assays. *Mycobacterium marinum* was confirmed by 16S (16S) and *M. marinum* specific primer (Mar2). No cross-amplification was seen with other mycobacteria species including *M. haemophilum* (HEM1, HEM2), *M. chelonae* (Che1), *M. malmoense* (MAL1), *M. abscessus* (ABS2), *M. tuberculosis* (TB6110), *M. smegmatis* (SME), *M. szulgai* (SZU), *M. kansasii* (Kan3), *M. intercellulare* (Int1), *M. ulcerans* (ULC2), *M. goodii* (Gor3), *M. fortuitum* (For1) and *M. avium* (AVI2).

and used to amplify the region of internal transcribed spacer (ITS) by PCR. Sequence alignment of the PCR product in GenBank identified *C. metapsilosis* (GenBank accession no. PQ626156). Antifungal susceptibility tests revealed sensitivity to voriconazole, posaconazole, itraconazole, caspofungin, anifungin, micafungin, flucytosine, amphotericin B, fluconazole, and nystatin (Table 1). Screening for hepatitis B core (Hbc) antibody yielded a positive result, whereas HIV, HCV, and syphilis were not detected using the fully automated immunoassay analyzer (ARCHITECT i2000SR, Abbott Laboratories, USA). His liver and renal function tests, fasting glucose levels, and routine tests were normal.

The patient was diagnosed with cutaneous granuloma caused by *M. marinum* and *C. metapsilosis*. Given his old age and anti-Hbc antibody, the patient was administered oral clarithromycin 250 mg twice daily, topical sulfadiazine silver cream (SSC), and nifuratel nystatin gel (NNG). Clarithromycin was discontinued after ten days because the patient experienced facial edema, bilateral lower limb edema, and a drop in blood pressure. Although the lesions improved, the finger still showed visible redness, swelling, and nodules (Figure 1B). The patient continued to receive topical treatment

**Table 1** Antifungal Susceptibility Tests of *Candida Metapsilosis* Isolated in This Study.

Antifungal Agents	MIC <sub>100</sub> (ug/mL)
Voriconazole	0.03
Posaconazole	0.06
Itraconazole	0.12
Fluconazole	1
Nystatin	4
Caspofungin	0.12
Anifungin	0.12
Micafungin	0.5
Amphotericin B	0.5
Flucytosine	<=0.06

**Abbreviations:** MIC, Minimum Inhibitory Concentration.

with SSC once daily and NNG twice daily for an additional month. The lesion improved noticeably, and only one red nodule of 2 mm in diameter remained (Figure 1C). Upon completing 3-month topical treatments, his lesion completely healed without any scarring, prompting the cessation of treatment (Figure 1D). No recurrence was found at the follow-up of 3 months, 1 year, and 3 years at the clinic or by video telephone.

## Discussion

Clinically, combined infection of *Mycobacterium* and *Candida* is rare, and most cases are reported in immunocompromised individuals suffering from deep infections.<sup>14,15</sup> A recent report described that mixed infection of *M. marinum* and *C. dubliniensis* caused chronic polymorphic rashes in a lymphatic pattern in an immunocompromised patient with systemic lupus erythematosus.<sup>16</sup> Nevertheless, the coexistence of *M. chelonae* and *C. albicans* infections was reported to cause esophageal infection in an immunocompetent adult.<sup>17</sup> In our present case, *M. marinum* and *C. metapsilosis* were isolated from cutaneous granuloma in an elder. To the best of our knowledge, he did not have an immune deficiency underlying the acquired infections. *M. marinum*, belonging to non-tuberculous mycobacteria, is an important causative microorganism of infectious granulomas.<sup>2</sup> *C. albicans* is the most common causative pathogen for candidal granuloma.<sup>18</sup> To date, however, there have been no reports of cutaneous granulomas caused by *C. metapsilosis*. In our view, *M. marinum* might be the primary causal agent, and *C. metapsilosis* is most likely the secondary infection.

Our patient was initially suspected of *M. marinum* infection because of chronic nodules on his finger and a history of fish stabbing. Upper extremities, especially hands and fingers, are common sites of *M. marinum* infections due to the higher exposure and low temperatures favoring bacterial growth.<sup>2,19</sup> Histopathology of his biopsy specimens was suggestive of infectious granuloma caused by mycobacteria or fungi. However, periodic acid-Schiff staining and acid-fast staining in our case were negative because of the limited number of bacteria present in the specimen sections, as in most cases.<sup>2</sup>

Based on a positive culture in liquid media and molecular detection, *M. marinum* infection was identified. In the MGIT 960 culture system, specimens are incubated in liquid Mycobacteria Growth Indicator Tubes (MGIT), which enable automated detection of mycobacterial growth according to emissions of fluorescence.<sup>11</sup> Positive cultures of *M. marinum* in solid media require a certain temperature (30–32°C) and approximately 2 to 8 weeks to grow.<sup>2</sup> Compared with solid media, culture in liquid media is more rapid and sensitive, but it is not convenient to observe mycobacterial morphology.<sup>2</sup> Molecular methods, such as 16S ribosomal RNA sequencing, whole-genome sequencing, and multi-gene sequencing, have made the identification of NTM species more rapid and accurate, even without positive cultures.<sup>2,3</sup> *M. marinum* was identified using multiplex real-time PCR assays in our case.

Currently, there are no conclusions on the optimal treatment regimen for *M. mycobacteria* due to its rarity and absence of controlled trials.<sup>2</sup> Monotherapy is generally recommended for superficial infections, and the most commonly prescribed agents include clarithromycin, minocycline, doxycycline, and trimethoprim/sulfamethoxazole. Combination

therapy is recommended for deep tissue involvement or disseminated infection in immunosuppressed patients.<sup>2-4</sup> The duration varies from 2 weeks to 1.5 years, depending on the severity of the lesion, the patient's risk factors, and clinical response to the regimen.<sup>4</sup> However, it is promising that acquired antimicrobial resistance has not been described in treating *M. marinum* so far for any of the abovementioned antibiotics.<sup>2</sup> Considering his old age and anti-HBc antibody, we gave the patient oral clarithromycin and topical SSC to treat *M. marinum* infection. Susceptibility testing was not performed because it is not routinely recommended and only for patients who respond poorly to standard dual treatment.<sup>2</sup> Although oral clarithromycin lasted only ten days due to adverse events, 3-month continuous treatment with topical SSC and NNG resulted in complete recovery of the lesions without recurrence. Silver sulfadiazine is a broad-spectrum antibiotic mainly used to treat burn wounds.<sup>20</sup> Makoto et al applied oral clarithromycin (200mg/day), topical sulfadiazine silver, and hyperthermia to a leg ulcer with *M. shinshuense* infection.<sup>21</sup> Two months after treatment, the necrotic lesions had decreased in size, but sulfadiazine silver was replaced by U-pasta (sucrose and povidone-iodine) due to a large discharge of exudate from the lesions.<sup>21</sup> Unlike this case, we gave the patient oral clarithromycin 250 mg twice daily and did not find massive exudates on his lesion after topical application of SSC. These different reactions after applying sulfadiazine silver might be related to contact allergy. In addition, nifuratel, one component of NNG, also has broad antibacterial properties.<sup>22</sup> Until now, no studies have evaluated the susceptibility of *M. marinum* to sulfadiazine silver or nifuratel. To our knowledge, this is the first case of short-term oral clarithromycin and long-term continuous treatment with topical agents for *M. marinum* infection.

A positive fungal culture and sequence alignment of the ITS sequence amplification products confirmed *C. metapsilosis* infection. It is susceptible to azoles, echinocandins, flucytosine, amphotericin B, and nystatin, as reported previously.<sup>8,9</sup> However, there is no consensus on the treatment of *C. metapsilosis* infection.<sup>5</sup> Here, we applied topical nystatin to treat *C. metapsilosis* infections because of the possible adverse events of oral antifungals in the elderly. The superficial infection with *C. metapsilosis* was effectively treated with topical NNG. NNG is a commonly used topical agent containing nystatin for vulvovaginal infections. In addition to its broad antibacterial properties, nifuratel also exhibits antifungal activity.<sup>22</sup> To date, there is no evidence of the susceptibility of *C. metapsilosis* to nifuratel.

## Conclusion

To our knowledge, this is the first reported case of mixed infection with *M. marinum* and *C. metapsilosis*. Combination therapy with a 10-day oral clarithromycin treatment and a 3-month topical SSC and NNG therapy was effective in treating superficial infections of *M. marinum* and *C. metapsilosis*. This case provides a potentially viable alternative for patients who cannot tolerate prolonged systemic therapy. However, further studies are required to verify its efficacy.

## Ethics Statement

The Ethics Committee of Beijing Jishuitan Hospital approved this study and gave the agreement to report the case details (No. K2025-007-00).

## Consent Statement

Written informed consent was obtained from the patient to publish clinical information and any accompanying images.

## Acknowledgments

We thank Professor Lan Li for helping us resolve the disagreement regarding the pathological diagnosis and Dr Zhe Wan for providing technological support for antifungal sensitivity tests.

## Funding

This study was supported by Beijing Jishuitan Hospital Research Funding (3-1-992-926-18, LC202510).

## Disclosure

All authors report a patent “Primers and probes, implementation methods, and detection systems for pathogenic mycobacteria of cutaneous infectious granulomas (ZL202110452654. 8)” issued to Peking University First Hospital. The authors declare no other conflicts of interest in this work.

## References

1. Terziroli Beretta-Piccoli B, Mainetti C, Peeters MA, Laffitte E. Cutaneous granulomatosis: a comprehensive review. *Clin Rev Allergy Immunol.* 2018;54(1):131–146. doi:10.1007/s12016-017-8666-8
2. Tsiolakakis G, Lontos A, Filippas-Ntekouan S, et al. Mycobacterium marinum: a case-based narrative review of diagnosis and management. *Microorganisms.* 2023;11(7):1799. doi:10.3390/microorganisms11071799
3. Canetti D, Riccardi N, Antonello RM, Nozza S, Sotgiu G. Mycobacterium marinum: a brief update for clinical purposes. *Eur J Intern Med.* 2022;105:15–19. doi:10.1016/j.ejim.2022.07.013
4. Medel-Plaza M, Esteban J. Current treatment options for Mycobacterium marinum cutaneous infections. *Expert Opin Pharmacother.* 2023;24(10):1113–1123. doi:10.1080/14656566.2023.2211258
5. Gómez-Gaviria M, García-Carnero LC, Baruch-Martínez DA, Mora-Montes HM. The emerging pathogen candida metapsilosis: biological aspects, virulence factors, diagnosis, and treatment. *Infect Drug Resist.* 2024;17:171–185. doi:10.2147/IDR.S448213
6. Govrins M, Lass-Flörl C. Candida parapsilosis complex in the clinical setting. *Nat Rev Microbiol.* 2024;22(1):46–59. doi:10.1038/s41579-023-00961-8
7. Oliveira VK, Paula CR, Colombo AL, et al. Candidemia and death by Candida orthopsilosis and Candida metapsilosis in neonates and children. *Pediatr Neonatol.* 2014;55(1):75–76. doi:10.1016/j.pedneo.2013.07.006
8. Zhu Y, Shan Y, Fan S, Li J, Liu X. Candida parapsilosis sensu stricto and the closely related species Candida orthopsilosis and Candida metapsilosis in vulvovaginal candidiasis. *Mycopathologia.* 2015;179(1–2):111–118. doi:10.1007/s11046-014-9821-x
9. Ge YP, Boekhout T, Zhan P, et al. Characterization of the Candida parapsilosis complex in East China: species distribution differs among cities. *Med Mycol.* 2012;50(1):56–66. doi:10.3109/13693786.2011.591440
10. Sun X, Song J, Leng X, et al. A preliminary evaluation of targeted nanopore sequencing technology for the detection of mycobacterium tuberculosis in bronchoalveolar lavage fluid specimens. *Front Cell Infect Microbiol.* 2023;13:1107990. doi:10.3389/fcimb.2023.1107990
11. Pennington KM, Vu A, Challener D, et al. Approach to the diagnosis and treatment of non-tuberculous mycobacterial disease. *J Clin Tuberc Other Mycobact Dis.* 2021;24:100244. doi:10.1016/j.jctube.2021.100244
12. Wang CJ, Song Y, Li T, Hu J, Chen X, Li H. Mycobacterium smegmatis skin infection following cosmetic procedures: report of two cases. *Clin Cosmet Investig Dermatol.* 2022;15:535–540. doi:10.2147/CCID.S359010
13. Liu X, Xue R, Li R, et al. Establishment of a real-time fluorescence-based PCR method for identification of mycobacteria in skin biopsies. *Chin J Dermatol.* 2024;57(11):1016–1021.
14. Ding X, Ma X, Xu Y, Xu L. HIV-associated mycobacterium avium complex, oral Candida, and SARS-CoV-2 co-infection: a rare case report. *Infect Drug Resist.* 2022;15:7037–7042. doi:10.2147/IDR.S390333
15. Okada S, Markle JG, Deenick EK, et al. Impairment of immunity to Candida and mycobacterium in humans with bi-allelic RORC mutations. *Science.* 2015;349(6248):606–613. doi:10.1126/science.aaa4282
16. Long BQ, Long Q, Lai MY, Yang L, You FR, Guo HW. Mycobacterium marinum cutaneous infection misdiagnosed as sporotrichosis in a patient with systemic lupus erythematosus: a case report. *Heliyon.* 2024;10(14):e34444. doi:10.1016/j.heliyon.2024.e34444
17. Hsu HH, Chang YL, Chen JS, Hsueh PR, Lee YC. An esophageal mass with coexistent mycobacterium chelonae and Candida albicans infections in an immunocompetent adult. *J Infect.* 2006;52(3):e77–79. doi:10.1016/j.jinf.2005.06.008
18. Yang X, Jin X, Yang Z, Wang Y, Wei A, Yang X. Isolated cutaneous granuloma caused by candida parapsilosis: case report and literature review. *Mycopathologia.* 2024;189(2):20. doi:10.1007/s11046-023-00812-3
19. Chen W, Bao F, Pan Q, et al. A series of 35 cutaneous infections caused by Mycobacterium marinum in Han Chinese population. *J Trop Med.* 2023;2023:5514275. doi:10.1155/2023/5514275
20. Gascón E, Maisanaba S, Ota I, et al. (Amino)cyclophosphazenes as multisite ligands for the synthesis of antitumoral and antibacterial silver(I) complexes. *Inorg Chem.* 2020;59(4):2464–2483. doi:10.1021/acs.inorgchem.9b03334
21. Kondo M, Kurokawa I, Ito Y, Yamanaka K, Yamazaki T, Mizutani H. Leg ulcer caused by mycobacterium ulcerans ssp. shinshuense infection. *Int J Dermatol.* 2009;48(12):1330–1333. doi:10.1111/j.1365-4632.2008.04060.x
22. Mendling W, Mailland F. Microbiological and pharmaco-toxicological profile of nifuratel and its favourable risk/benefit ratio for the treatment of vulvo-vaginal infections. A review. *Arzneimittelforschung.* 2002;52(1):8–13. doi:10.1055/s-0031-1299849

Clinical, Cosmetic and Investigational Dermatology

Publish your work in this journal

Clinical, Cosmetic and Investigational Dermatology is an international, peer-reviewed, open access, online journal that focuses on the latest clinical and experimental research in all aspects of skin disease and cosmetic interventions. This journal is indexed on CAS. The manuscript management system is completely online and includes a very quick and fair peer-review system, which is all easy to use. Visit <http://www.dovepress.com/testimonials.php> to read real quotes from published authors.

Submit your manuscript here: <https://www.dovepress.com/clinical-cosmetic-and-investigational-dermatology-journal>

**Dovepress**  
Taylor & Francis Group