

Successful Treatment of HIV-Combined CNS *Nocardia Terpenica* Infection with Cotrimoxazole as a Single Agent During the Maintenance Phase: A Case Report and Review of the Literature

Jingjing He¹, Shengkui Tan², Jiannan Lv³

¹Department of Infection, Baise People's Hospital, Baise, 533000, People's Republic of China; ²Guangxi Clinical Medical Research Center for Hepatobiliary Diseases, Youjiang Medical University for Nationalities, Baise, 533000, People's Republic of China; ³Guangxi Clinical Medical Research Center for Hepatobiliary Diseases, Department of Infection, Affiliated Hospital of Youjiang Medical University for Nationalities, Baise, 533000, People's Republic of China

Correspondence: Shengkui Tan; Jiannan Lv, Email sktan2008@163.com; gxaidsc@163.com

Abstract: The *Nocardia* infection of the central nervous system (CNS) in HIV-positive individuals is difficult to diagnose and treat, often requiring a combination of at least two drugs during the maintenance phase. In this article, we report a case of CNS *Nocardia terpenica* infection in an AIDS patient diagnosed by cerebrospinal fluid targeted next-generation sequencing (tNGS), which was ultimately treated successfully with sulfamethoxazole monotherapy due to adverse drug reactions. Additionally, we reviewed the relevant literature to explore individualized treatment options for CNS *Nocardia* infections in patients with AIDS and to provide clinicians with evidence-based treatment recommendations.

Keywords: AIDS, *Nocardia terpenica*, central nervous system, tNGS, case report

Background

Nocardia terpenica (*N. terpenica*), first reported by Hoshino Y et al, is a Gram-stain-positive, aerobic actinomycete belonging to the genus *Nocardia*, which can be found in soil, fresh, brackish water, and decaying plants.¹ Like other *Nocardia* genera, it can cause localized and disseminated infections in immunocompromised patients, especially those with T-cell deficiencies.² To date, CNS infections caused by *Nocardia terpenica* have been reported only in a few cases and exclusively in HIV-negative populations.^{3–5} There have been no reports of such infections in HIV-positive patients. Significantly, the regimen and continuation of treatment for CNS *Nocardia* infections vary considerably in HIV-negative and HIV-positive populations. In HIV-infected patients, maintenance therapy requires a combination of at least two drugs and a duration of at least one year.⁶ However, in the case of HIV combined with CNS *N. terpenica* infection, severe adverse drug reactions, and poor patient adherence forced us to apply cotrimoxazole monotherapy for maintenance, which was also successful. This article aims to conduct a retrospective analysis of this case and review the relevant literature to discuss the individualized treatment of CNS *N. terpenica* infection in patients with AIDS.

Case Presentation

A 27-year-old male was admitted to the hospital on January 11, 2023, for “fever and headache for 6 days”.

History: The patient tested positive for HIV at the Baise City CDC in 2011 and started taking antiretroviral therapy (ART) with lamivudine, tenofovir, and efavirenz in 2018. However, he had poor adherence to the medication.

Main positive signs after admission: Temperature was 39.2°C. Pulse was 95 beats/min. Bilateral neck and inguinal areas had several enlarged lymph nodes, the most prominent being about 1×1 cm, with clear boundaries, medium texture,

and no pressure pain. The spleen was enlarged, extending about 5 cm below the left rib. The meningeal irritation sign was positive. Other pathological signs were not elicited.

Primary positive auxiliary data after admission: blood changes (see Table 1), T-lymphocyte subsets: CD3+CD4+ absolute count of 41/ μ L, CD4+/CD8+ ratio of 0.13; cerebrospinal fluid changes (see Table 2). Furthermore, tNGS of the cerebrospinal fluid was conducted: and *Nocardia terpenica* (sequence number: 4, a relative abundance of 2.81%, a genome coverage of less than 0.01%) and Microecological flora: EBV (sequence number: 2, and a relative abundance of 0.001%) were identified. Fungi, viruses, parasites and Resistance genes were not detected. The cerebrospinal fluid was tested using the metagenomic sequencing platform for pathogenic microorganisms of KingMed Diagnostics. This technology conducts comprehensive detection and analysis of the nucleic acid sequences of microbial populations in specific samples. By carefully comparing the measured sequences with the rich nucleic acid sequences of microorganisms in the database, it can accurately identify the suspected pathogenic microorganisms present in the samples. It has high sensitivity and accuracy and can effectively detect the gene sequences of the genus *Nocardia*. Abdominal ultrasound: splenomegaly (approximately 50 mm thick); cranial magnetic resonance enhancement: multiple foci of abnormal enhancement in the brain parenchyma, lateral ventricles, and cerebral pools, suggesting infectious lesions (Dynamic contrast-enhanced scan revealed linear enhancement in the suprasellar cistern and Sylvian fissure cistern. On diffusion-weighted imaging (DWI), nodular hyperintensity was observed in the left posterior horn of the lateral ventricle. The right frontal lobe demonstrated patchy slightly prolonged T1 and T2 signals, with slightly hyperintense signal on FLAIR images. DWI also showed patchy and nodular diffusion restriction in the left posterior horn of the lateral ventricle) (Figure 1A).

The patient had a pre-existing condition of acquired immunodeficiency syndrome (AIDS), with a very low level of functional CD4+ T cells, which made them prone to opportunistic infections such as tuberculosis and fungal infections. A cranial MRI showed multiple ring-enhancing lesions. Taking the imaging characteristics into account, possibilities like tuberculous and cryptococcal meningoenkephalitis could not be ruled out. However, CSF smear tests for pathogens, acid-fast bacilli, cryptococcal antigen, TB-DNA, G test, GM test, CMV - DNA, and EB-DNA all came back negative. Also,

Table 1 Changes in Routine Blood and Inflammatory Indicators During Hospitalization and Follow-Up of Patients

Dates	2023-1-11	2023-1-21	2023-4-7	2023-4-22	2023-8-13	2023-9-17	2023-11-17	2024-1-16
WBC $\times 10^9$ /L	3.4	2.1	4.3	5.0	1.1	4.8	5.4	4.3
LYM# $\times 10^9$ /L	1.92	1.23	2.43	0.65	0.66	0.68	0.77	0.90
HGB (g/L)	95	89	91	87	51	92	121	129
PLT $\times 10^9$ /L	148	224	222	147	120	266	217	190
CRP (mg/L)	53.83	22.33	9.29	1.1	–	–	–	–
PCT (ng/mL)	0.03	0.04	0.08	0.09	–	–	–	–
IL6 (pg/mL)	166.8	25.1	22.6	7.1	–	–	–	–
CD4 (/ul)	41	–	108	–	45	–	69	75
CD4/CD8	0.13	–	0.38	–	0.42	–	0.43	0.38
HIV-RNV (copies/mL)	<50	–	–	–	–	–	–	<50

Table 2 Changes in Cerebrospinal Fluid Routine and Biochemistry in Patients

Dates	2023-01-13	2023-04-08	2023-04-22	2023-08-13
Intracranial pressure (mmH2O)	240	250	180	185
Cell number (biology) ($\times 10^6$ /L)	838.90	685.00	21	6.60
Trace protein (mg/L)	1774.8	2590.0	2069.1	454.9
Glucose (mmol/L)	0.14	0.3	1.05	2.27
Chloride (mmol/L)	117	111.6	134.7	121.2
CMV-IgG (AU/mL)	–	344.85	–	213.70

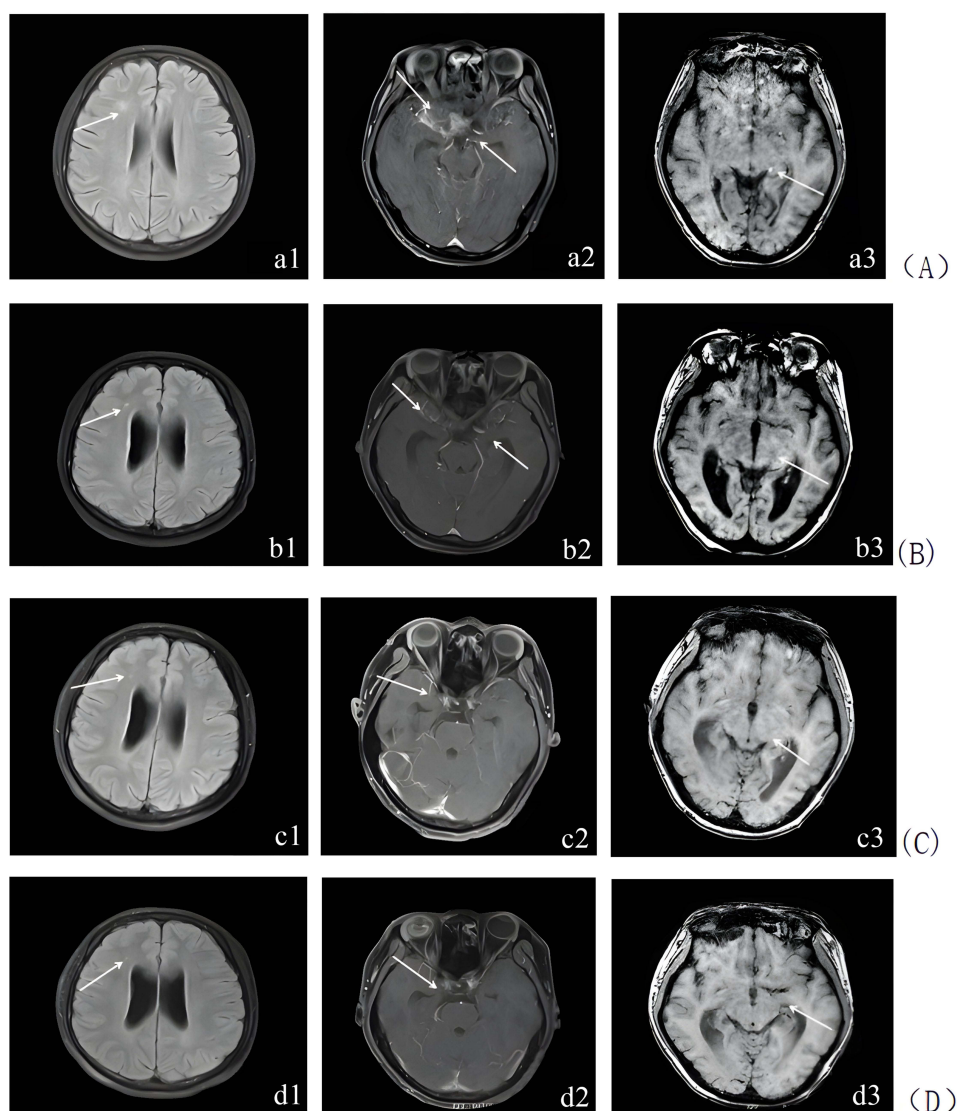


Figure 1 Comparison of cranial images before and after treatment in a patient with HIV combined with CNS *Nocardia Terpenica* infection. **(A)** January 17, 2023. Abnormal signal in the right frontal lobe, striated enhancement shadows in the suprasellar pool, and enhancement foci in the left parahippocampal gyrus, suggesting infectious lesions (indicated by arrows); **(B)** August 14, 2023. Intracranial infectious foci were better resorbed than previously imaged; **(C)** January 16, 2024. Intracranial infectious foci had disappeared; **(D)** April 13, 2024. The intracranial infected lesion had largely disappeared.

IGRA and PPD tests were negative, and bacterial and fungal cultures of both CSF and blood were negative. When all the supplementary examination data were put together, there was not enough evidence to diagnose tuberculosis or fungal infections. Therefore, a nervous system infection caused by *Nocardia terpenica* was considered more likely. According to the Sanford Guidelines, for neuro nocardiosis, it is best to choose a combination of 3–4 drugs. So far, TMP-SMZ, amikacin, linezolid, and imipenem-cilastatin remain the core drugs. TMP-SMZ and linezolid can easily penetrate the blood-brain barrier and have high drug concentrations in cerebrospinal fluid. Moreover, amikacin has a synergistic effect with other drugs, which can enhance the anti-*Nocardia* activity. Eventually, he was treated with cranial pressure lowering and symptomatic treatment, anti-bacterial ceftriaxone sodium (2g qd ivgg), and anti-nocardiosis (TMP-SMZ 1.44g tid po), amikacin (0.4g qd ivgg), and linezolid (0.6g q12h ivgg). The patient's condition gradually improved, and he was discharged on February 2, 2023. After discharge, anti-nocardiosis (TMP-SMZ 1.44g tid ivgtt) combined with linezolid (0.6g q12h po) was given, and antiretroviral therapy was continued with the original regimen (lamivudine, tenofovir, efavirenz).

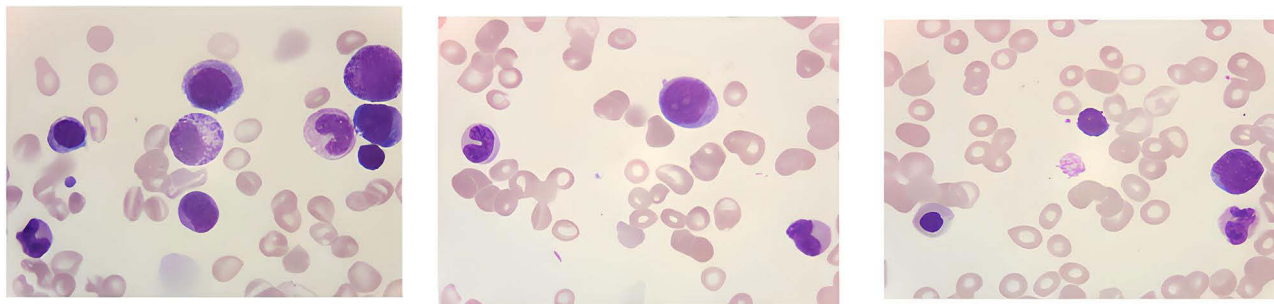


Figure 2 Bone marrow cytology: active proliferation of the granulopoietic lineage; markedly active proliferation of the erythroid lineage, with some megaloblastic changes visible; megakaryocytic lineage not classified, with platelets in small clusters; 1% monocytes visible.

On April 7, 2023, the patient was rehospitalised for worsening headache. Follow-up history revealed that the patient had not adhered to the prescribed regimen of linezolid and TMP-SMZ, leading to poor control of *Nocardia*. Treatment was given (meropenem 2g q8h ivgtt+ linezolid 0.6g q12h po+ TMP-SMZ 1.44g tid po) for anti-*Nocardia*. During two lumbar punctures, cerebrospinal fluid changes were monitored (see Table 2 for details). The patient's condition gradually improved, and he was discharged from the hospital on May 3, 2023, with instructions to continue the linezolid and TMP-SMZ regimen.

The patient was rehospitalized on August 13, 2023, with weakness and bilateral lower extremity pain. A review of cerebrospinal fluid (see Table 2 for details) and cranial imaging results (Figure 1B) showed effective control of the CNS infection. However, the patient had a hemoglobin of 51 g/L, a mean erythrocyte volume of 115.9 fL, and observed megaloblastic changes in bone marrow cytology (Figure 2). The patient presented with anemia and bilateral lower limb pain. These symptoms were considered to be related to bone marrow suppression and peripheral neuropathy caused by long-term use of linezolid.

Additionally, impaired folate metabolism due to TMP-SMZ, leading to megaloblastic anemia, could not be ruled out. Linezolid was discontinued. However, due to the patient's poor adherence and refusal to continue combination antibiotic therapy, monotherapy with TMP-SMZ was considered. This decision was based on TMP-SMZ achieving high CSF concentrations and demonstrating high susceptibility against *Nocardia*. Most importantly, follow-up CSF analysis and MRI indicated significant improvement in the patient's condition. Meanwhile, Vitamin B12 and folic acid were supplemented to correct anemia and bilateral lower limb pain, which improved. TMP-SMZ monotherapy was maintained after discharge from the hospital.

The patient was followed up during four outpatient visits on September 17, 2023, November 17, 2023, January 16, 2024, and April 13, 2024, respectively. During these visits, the patient experienced no significant discomfort. Blood routine reviews (see Table 1 for details) suggested that the anemia had gradually improved. Cranial imaging results indicated that the infectious lesions of the CNS had resolved mainly (see Figure 1C and 1D). Follow-up CSF results showed all parameters were essentially normal (see Table 2 for details). Considering all the above parameters, the patient's condition improved, and TMP-SMZ was discontinued.

Discussions

There are many species of *Nocardia*, but *Nocardia asteroides*, *Nocardia brasiliensis*, *Nocardia farcinica*, and *Nocardia otitidiscaviarum* are more common.² *Nocardia* infections occur more often in immunocompromised and immunosuppressed patients, such as those with AIDS, neoplastic diseases, lupus erythematosus, connective tissue diseases, diabetes mellitus, and other conditions.⁷ Some studies have shown that the mortality rate of *Nocardia* CNS infection is as high as 55% in immunocompromised patients, which is significantly higher than the 20% mortality rate in immunocompetent patients. However, there is no significant difference in the clinical manifestations of the two groups.^{8,9} Clinical manifestations of *Nocardia* CNS infection often include focal neurological abnormalities, headache, fever, and seizures, which are easily missed and misdiagnosed due to the lack of specificity in clinical manifestations, imaging, and biochemical tests.^{10,11} HIV is a high-risk factor for *Nocardia* infection; however, Nocardiosis is not a common opportunistic infection in HIV-positive

individuals.¹² *N. terpenica* is morphologically similar to *Actinobacillus* spp. and is a rare cause of CNS infection.³ *N. terpenica* has also been documented to infect immunocompetent individuals without underlying disease.^{13,14} To date, there have been few case reports of *N. terpenic* infections in HIV-negative individuals.^{4,5,15,16}

The definitive diagnosis of nocardiosis depends on bacterial culture, but *Nocardia* reproduces slowly, with colonies generally visible in 2–7 days, and some may take up to 4 weeks. The growth of *Nocardia* can be inhibited by other fast-growing bacteria, resulting in a low rate of culture positivity.¹⁵ With the widespread use of macro-genomic high-throughput sequencing (NGS), the detection rate of rare pathogens, including *N. terpenic*, has increased dramatically in recent years, and it has become an essential tool for confirming and typing *Nocardia*.¹⁷ So far, the treatment of *Nocardia terpenica* is still based on linezolid, TMP-SMZ, imipenem-cilastatin, and amikacin as the core drugs^{4,5,15,16,18} (See Table 3 for details). For non-severe cases, monotherapy demonstrates satisfactory efficacy. In patients with severe infections, neurological nocardiosis has become a serious problem. For patients with severe infections, neurologic nocardiosis, or poor treatment outcomes, a combination regimen of 3 to 4 drugs for at least 1 year may be considered.^{19,20} Continuation of treatment for CNS infections in HIV-positive patients typically requires a combination of 2 sensitive drugs for at least 1 year.^{6,21}

Immunocompetent patients with uncomplicated infections can be cured through a relatively short treatment course (8 weeks or longer). Studies demonstrate that the average treatment duration for patients with superficial skin infections is approximately 4 months. Those with pulmonary infections should receive 6–12 months of treatment, while patients with concurrent or disseminated diseases require 9–12 months of antimicrobial therapy. For patients with central nervous system involvement, intravenous antimicrobial treatment is recommended for 3–6 weeks (or longer), complemented by 1 year or more of oral antimicrobial therapy.^{8,22} However, linezolid is effective against all *Nocardia* isolates; the cost and toxicity of long-term treatment limit its widespread use.²² L et al²³ reported antimicrobial drug susceptibility in 8 cases of *N. terpenica*, showing that 2 cases (25%) were resistant to TMP-SMX, and 7 cases (87.5%) were resistant to amoxicillin clavulanic acid. Therefore, it is essential to be alert to the possibility of *Nocardia* resistance in cases with poor therapeutic outcomes.

In this case of AIDS first reported by our team, *N. terpenic* was detected by cerebrospinal fluid. The anti-infective regimen was strictly based on the Sanford Guidelines. However, the patient was hospitalized twice more during the treatment period due to poor medication adherence and adverse drug reactions. The administration of cotrimoxazole in combination with linezolid achieved good results during maintenance therapy. However, it was discontinued due to side effects such as myelosuppression and peripheral neuropathy of both lower extremities after prolonged use. The treatment was finally adjusted to cotrimoxazole monotherapy, which was successful. The successful maintenance with TMP-SMZ monotherapy depends on a triple mechanism: TMP-SMZ can easily cross the blood-brain barrier and has a high concentration in cerebrospinal fluid, exerting a bacteriostatic effect; ART (Highly Active Antiretroviral Therapy ART)-induced partial immune reconstitution leads to an increase in CD4+ T cells; and *Nocardia* has an inherent high sensitivity to TMP-SMZ. This case may provide ideas for individualized treatment of HIV combined with CNS *Nocardia* infection.

Table 3 Characteristics of Reported Cases of *Nocardia Terpenica* Infection

Reference, Year	Gender, Age (Years)	Diagnosis	Detection Section of <i>N. terpenica</i>	Medical Treatment	Duration of Treatment	Outcome
Lin, 2023 ⁵	Male/53	Purulent meningoencephalitis (<i>N. terpenica</i>)/Nephrotic syndrome	Cerebrospinal Fluid	Meropenem linezolid and switch to Oral clarithromycin	3 months (stop by himself)	Improved
Dong, 2023 ¹⁵	Male/53	Pulmonary infection (<i>N. terpenica</i>)	BALE	TMP-SMZ	6 months	Improved
T, 2021 ¹⁶	Male/75	Disseminated nocardiosis/Type 2 diabetes	BALE Skin lesions	Meropenem, linezolid and switch to oral clarithromycin	3 months	Improved
Hu, 2018 ⁴	Female/53	CNS infection (<i>N. terpenica</i>).	Cerebrospinal Fluid	Meropenem, TMP-SMZ, amikacin and switch to oral TMP-SMZ, Linezolid	6 months	Improved
Wu, 2025 ¹⁸	Male/45	Pulmonary infection (<i>N. terpenica</i>)	BALE	TMP-SMZ, imipenem-cilastatin and switch to Oral clarithromycin	NA	Improved

Conclusion

In summary, *N. terpenica* is a rare opportunistic pathogen. Cerebrospinal fluid mNGS may be an essential tool for rapidly diagnosing CNS *N. terpenic* infection and is vital to implementing early diagnosis and treatment. Although guidelines recommend that continuation therapy for CNS *N. terpenic* infection in HIV-positive patients requires a combination of 2 sensitive drugs, monotherapy with sulfamethoxazole can also be successful when administered. This may provide insights for individualized treatment of AIDS complicated with CNS *Nocardia* infection.

Data Sharing Statement

All data generated or analyzed during this study are included in this article.

Ethics Approval and Consent to Participate

This study has obtained ethical approval from the Ethics Review Committee of Baise People's Hospital, and all participants have signed the informed consent form, agreeing to participate in this study.

Clinical Trial Number

The therapeutic drug involved in the study has been marketed, and the chosen treatment regimen complies with the requirements of the drug's labeling, without involving clinical trial research.

Institutional Approval Statement

The approval from Baise People's Hospital has been obtained for publishing the details of this case.

Consent for Publication

I confirm that my participants/patients gave written informed Consent for their personal or clinical details along with any identifying images to be published in this study; see the response letter for details.

Author Contributions

All authors made a significant contribution to the work reported, whether that is in the conception, study design, execution, acquisition of data, analysis and interpretation, or in all these areas; took part in drafting, revising or critically reviewing the article; gave final approval of the version to be published; have agreed on the journal to which the article has been submitted; and agree to be accountable for all aspects of the work.

Funding

This research was supported by the National Key Research and Development Program of China, Grant No. 2023YFC2605400.

Disclosure

The authors declare that they have no competing interests for this work.

References

1. Hoshino Y, Watanabe K, Iida S, et al. *Nocardia terpenica* sp. nov. isolated from Japanese patients with nocardiosis. *Int J Syst Evol Microbiol*. 2007;57(Pt 7):1456–1460. doi:10.1099/ijs.0.64695-0
2. McNeil MM, Brown JM, Georghiou PR, Allworth AM, Blacklock ZM. Infections due to *Nocardia transvalensis*: clinical spectrum and antimicrobial therapy. *Clin Infect Dis*. 1992;15(3):453–463. doi:10.1093/clind/15.3.453
3. Sher M, Heard T, Munckhof W, et al. First case report of cerebral abscess from *Nocardia terpenica* and literature review. *Clin Neurol Neurosurg*. 2022;2022:220107341.
4. Hu N, Liu Y, Cai Q, et al. The First Report of Cerebral Nocardiosis Caused by *Nocardia terpenica* Together With *Exiguobacterium profundum* Bacteremia. *Jundishapur J Microbiol*. 2018. In Press. doi:10.5812/jjm.69604
5. Lin C, Lan H. One Case of Meningoencephalitis in a Patient with Nephrotic Syndrome Caused by *Nocardia terpenica*. *Chin Datab Clinl Cases*. 2023;05(01):E01509–E01509.

6. Fan H, Wang H, Zhou B, et al. *Gilbert's the Sanford Guide to Antimicrobial Therapy (48th Newly Translated Edition)*. Beijing: Peking Union Medical College Press. July 2019.
7. Barnaud G, Deschamps C, Manceron V. Brain Abscess Caused by *Nocardia cyriacigeorgica* in a Patient with Human Immunodeficiency Virus Infection. *J Clin Microbiol*. 2005;43(9):4895–4897. doi:10.1128/JCM.43.9.4895-4897.2005
8. Wilson JW. Nocardiosis: updates and Clinical Overview. *Mayo Clin Proc*. 2012;87(4):403–407. doi:10.1016/j.mayocp.2011.11.016
9. Zheng YC, Wang TL, Hsu JC, et al. Clinical Pathway in the Treatment of Nocardial Brain Abscesses Following Systemic Infections. *Neurological Med*. 2014;2014(1):584934.
10. Anagnostou T, Arvanitis M, Kourkoumpetis TK, et al. Nocardiosis of the central nervous system: experience from a general hospital and review of 84 cases from the literature. *Medicine*. 2014;93(1):19–32. doi:10.1097/MD.000000000000012
11. Xiaoran L, Xiaoju L. Clinical characterization of patients with *Nocardia* infection in southwest China. *Chin J Infect Chemother*. 2023;23(1):7.
12. Chi Y, Chuanjun X, Fang M, et al. A case of AIDS combined with disseminated nocardiosis. *Chin J Infect Dis*. 2020;38(9):3.
13. Beaman BL, Burnside J, Edwards B, et al. Nocardial infections in the United States, 1972-1974. *J Infect Dis*. 1976;134(3):286–289. doi:10.1093/infdis/134.3.286
14. Xiao X, Huang S. Fever with diffuse lung lesions and positive blood II gene sequencing. *Chin J Tuberculosis Respiratory Med*. 2020;43(8):3.
15. Dong J, Guan W. Mild Pulmonary Nocardiosis Caused by *Nocardia terpenica* in an Immunocompetent Patient: a Case Report. *Internal Medicine*. 2023;2023:9740.
16. Matsuo T, Nakaoka H, Mori N, et al. Disseminated nocardiosis due to *Nocardia terpenica*. *J Infect Chemother*. 2021;27(9):1365–1368. doi:10.1016/j.jiac.2021.04.014
17. Y Peng, X Dong, Y Zhu, et al. A rare case of pulmonary nocardiosis comorbid with Sjogren's syndrome. *J Clin Lab Anal*. 2021;2021(11):1.
18. Qingrong W, Zhang L, Zhang Y, et al. Pharmaceutical practice of clinical pharmacists in the treatment of a patient with pulmonary infection caused by *Nocardia terpenica*. *Chinese J Pharmacoepidemiol*. 2025;34(02):224–230.
19. A Restrepo, NM Clark. Nocardia infections in solid organ transplantation: guidelines from the Infectious Diseases Community of Practice of the American Society of Transplantation. *Clin Transplant*. 2019;2019:1.
20. W ZJ, Zhou H, Q JW, et al. A clinical case report of brain abscess caused by *Nocardia brasiliensis* in a non-immunocompromised patient and a relevant literature review. *BMC Infect Dis*. 2020;20(1). doi:10.1186/s12879-020-05052-0.
21. Hémar V, Imbert Y, Imbert Y, et al. Retrospective analysis of nocardiosis in a general hospital from 1998 to 2017. *Médecine Et Maladies Infectieuses*. 2018;48(8):516–525.
22. Fatahi-Bafghi M. Nocardiosis from 1888 to 2017. *Microb Pathog*. 2018;114:369–384. doi:10.1016/j.micpath.2017.11.012
23. Huang L, Chen X, Xu H, et al. Clinical features, identification, antimicrobial resistance patterns of *Nocardia* species in China: 2009-2017. *Diagnostic Microbiol Infect Dis*. 2019;94(2):165–172. doi:10.1016/j.diagmicrobio.2018.12.007

Infection and Drug Resistance

Publish your work in this journal

Infection and Drug Resistance is an international, peer-reviewed open-access journal that focuses on the optimal treatment of infection (bacterial, fungal and viral) and the development and institution of preventive strategies to minimize the development and spread of resistance. The journal is specifically concerned with the epidemiology of antibiotic resistance and the mechanisms of resistance development and diffusion in both hospitals and the community. The manuscript management system is completely online and includes a very quick and fair peer-review system, which is all easy to use. Visit <http://www.dovepress.com/testimonials.php> to read real quotes from published authors.

Submit your manuscript here: <https://www.dovepress.com/infection-and-drug-resistance-journal>

Dovepress
Taylor & Francis Group