

Exploration of Traditional Chinese Medicine Comprehensive Treatment of Triple Negative Breast Cancer Based on Molecular Pathological Mechanism

Mingya Zhu¹, Yongqin Liu¹, Zhu Wen¹, Hao Tan¹, Siman Li¹, Xinkang Yu¹, Hongping Luo¹, Delin Li¹, Jinyan Wang¹, Fangyan Qin²

¹Chengdu University of Traditional Chinese Medicine, Chengdu, Sichuan Province, People's Republic of China; ²The Second People's Hospital of Jiangjin Chongqing, Chongqing, People's Republic of China

Correspondence: Fangyan Qin, The Second People's Hospital of Jiangjin Chongqing, No. 62, Zhongxing Road, Baisha Town, Jiangjin District, Chongqing, People's Republic of China, Email qinfangyan2024@163.com

Abstract: Triple-negative breast cancer (TNBC) is recognized as the most aggressive subtype of breast cancer and is associated with poor prognosis. Clinically, TNBC is associated with significant invasiveness, high propensity for metastasis, frequent recurrence, and unfavorable outcomes. The absence of estrogen receptors, progesterone receptors, and human epidermal growth factor receptor 2 (HER2) in TNBC renders it unresponsive to endocrine therapies and treatments that target HER2. Consequently, the current therapeutic options are primarily confined to surgical intervention, adjuvant chemotherapy, and radiotherapy. Given the considerable heterogeneity of TNBC, targeted therapies have emerged as promising avenues for treatment. Furthermore, immunotherapy has demonstrated the potential to enhance overall survival and therapeutic response in patients with TNBC. Additionally, research indicates that traditional Chinese medicine (TCM) may yield beneficial effects in the management of this cancer subtype. This review aims to consolidate recent advancements in treatment strategies for TNBC, particularly those based on molecular subtypes.

Keywords: TNBC, HER2, targeted therapy, immunotherapy, TCM

Introduction

Triple-negative breast cancer (TNBC) is a subtype of breast cancer (BC) characterized by the absence of hormone receptor expression and amplification of the human epidermal growth factor receptor 2 (HER2) gene, representing approximately 24% of newly diagnosed cases of BC.¹ The absence of targetable hormone receptors and HER2 expression contributes to the generally poor prognosis associated with TNBC as well as the limited availability of effective therapeutic options.^{2,3} TNBC is a functional classification that encompasses a diverse array of entities exhibiting distinct biological and clinical characteristics, which are marked by considerable genetic, transcriptional, histological, and clinical variability.⁴ Compared to other BC subtypes, TNBC is associated with a poorer prognosis, as patients typically experience a more aggressive clinical trajectory characterized by advanced stage at initial diagnosis, early relapse with metastatic progression, and diminished overall survival (OS) rates.^{5,6}

A novel classification system for BC, based on gene expression patterns,⁷ categorizes the disease into four “intrinsic subtypes”: luminal, HER2, basal-like, and “normal breast-like”. Notably, both basal-like and normal breast-like subtypes have been identified as TNBC,⁸ which is characterized by the absence of estrogen receptor (ER), progesterone receptor (PR), and HER2 expression. Gene expression profiling typically identifies TNBC as a subtype of basal-like breast cancer (BLBC), with approximately 56% of the gene expression profiles of TNBC and BLBC exhibiting overlap.^{9,10}

TNBC exhibits a unique molecular phenotype that renders it unresponsive to endocrine and molecular targeted therapies. Consequently, chemotherapy remains the primary systemic treatment modality. However, the effectiveness of standard postoperative adjuvant radiotherapy and chemotherapy is limited. The presence of residual metastatic lesions ultimately contributes to tumor recurrence.¹¹ This finding underscores the pressing need for the development of novel therapeutic strategies and targets.

TNBC presents significant diagnostic and therapeutic challenges owing to its aggressive characteristics and absence of targeted treatment options. Recent advancements in technologies such as artificial intelligence (AI) and liquid biopsy have paved the way for innovative approaches for the diagnosis and management of TNBC.¹² By processing extensive datasets, AI can discern intricate patterns that can enhance the diagnostic accuracy and inform treatment decisions for TNBC. Specifically, AI algorithms, particularly those utilizing deep learning techniques, are adept at identifying subtle features of TNBC in imaging modalities, such as mammography, ultrasound, and MRI, thereby facilitating earlier and more precise diagnoses. Furthermore, AI can analyze pathological specimens to detect specific biomarkers associated with TNBC, aiding pathologists in achieving more accurate classification and diagnosis. By integrating clinical, genomic, and imaging data, AI can also predict treatment responses and prognoses for patients with TNBC, thereby contributing to the personalization of therapeutic strategies.¹³

Liquid biopsy offers a non-invasive approach for diagnosis and monitoring through the analysis of circulating tumor DNA (ctDNA), circulating tumor cells (CTC), and exosomes present in the bloodstream.¹⁴ This technique can identify mutations and biomarkers associated with TNBC in blood samples, thereby facilitating early detection. Furthermore, by continuously monitoring fluctuations in ctDNA and CTC levels, liquid biopsy enables the real-time assessment of treatment responses, allowing for timely adjustments to therapeutic strategies. In addition, liquid biopsy can detect genetic mutations that contribute to drug resistance, thereby assisting in the selection of alternative treatment options.

The integration of AI with liquid biopsy has the potential to enhance the diagnostic and therapeutic outcomes of TNBC. AI is capable of analyzing intricate data derived from liquid biopsies, facilitating the identification of potential biomarkers and predicting treatment responses.¹⁴

Given the significant heterogeneity of TNBC and the intricacies associated with its treatment, this study aimed to investigate the holistic management of TNBC using traditional Chinese medicine (TCM), informed by the molecular pathological mechanisms underlying the disease.

Epidemiology

BC is the most prevalent malignancy diagnosed among women globally, with over two million cases documented in the Global Cancer Observatory in 2018.¹⁵ The incidence of TNBC was notably higher in younger patients. A population-based study conducted in Atlanta revealed that TNBC was more frequently observed in individuals aged 20–39 years, as determined using multivariate analysis.¹⁶ After adjusting for factors such as body mass index (BMI), cancer stage, and grade, a case review from the Henry Ford Health System indicated a 16% decrease in the risk of developing triple-negative breast cancer for each decade of life.¹⁷ Additionally, younger age was linked to BLBC in the Carolina Breast Cancer Study.¹⁸ Other studies have shown that a greater proportion of TNBC cases in younger patients exhibit a basal-like phenotype, whereas nearly half of TNBC cases in patients aged > 65 years are classified as non-basal-like subtypes.¹⁹ This disparity may explain why certain epidemiological associations of age-related risk factors in younger patients could provide insights into the morbidity mechanisms of basal-like cancers, whereas risk factors in older patients may be indicative of HER2 enrichment and a higher prevalence of luminal triple-negative cancers.²⁰

The aggressive nature of TNBC is evident from its characteristics. According to the SEER analysis conducted from 2010 to 2013, TNBC constituted only 8.2% of stage I cancers, in contrast to over 15% of cancers diagnosed at more advanced stages.²¹ Furthermore, TNBC represented only 8.5% of tumors measuring less than 2 cm, and only 2.3% of low-grade cancers were classified as triple-negative. While the long-term survival rates for stage I TNBC are comparable to those of other receptor subtypes, the prognosis significantly worsens with advancing stage; nearly 50% of women diagnosed with stage III disease succumb within four years. Variations in the frequency, target demographics, and imaging techniques employed in breast cancer screening programs may elucidate some disparities in staging among different breast cancer subtypes. Interval cancers, which are diagnosed between screening intervals, were found to be

over six times more likely to be estrogen receptor-negative and three times more likely to be TNBC, correlating with markedly higher breast cancer-specific mortality rates.^{22,23} TNBCs frequently lack calcifications and other mammographic features characteristic of breast cancer and may be present in younger women with dense breast tissue. In contrast, magnetic resonance imaging (MRI) has demonstrated superior sensitivity for the early detection and diagnosis of these cancers.²⁴

A multitude of studies have highlighted racial disparities in the diagnosis of TNBC, with odds ratios (ORs) typically indicating a two- to three-fold increased risk among Black Americans.^{25–28} The influence of ethnicity on invasive breast cancer subtypes was further corroborated by global epidemiological data. According to the Global Cancer Observatory's 2018 report, Africa exhibited a mortality rate ranging from 15.4 to 18.4 per 100,000 individuals, whereas Europe and North America reported lower mortality rates, despite having incidence rates that were two to three times higher than those in Africa. This observation suggests a potentially more aggressive disease phenotype in African patients.¹⁵ Although the report did not specify receptor subtypes, this disparity may be partially attributed to the elevated incidence of triple-negative disease, which may reach as high as 59% within the Nigerian population.²⁹

Lifestyle and social disparities may contribute to an elevated risk in this demographic group. As previously noted, various reproductive and metabolic risk factors were found to be more prevalent among young African-American women in the Carolina Breast Cancer Study, and these factors correlated with basal-like immunohistochemical expression patterns. These factors include lack of breastfeeding, early onset of menarche, early childbirth, waist-to-hip ratio, and weight gain since childhood.¹⁸ Although odds ratios for the majority of reproductive risk factors were adjusted for age and race, parity was generally found to be protective against breast cancer.³⁰ Additionally, several case-control studies have reported comparable rates of triple-negative breast cancer among Hispanic and non-Hispanic white populations.^{25,26} Given the considerable heterogeneity within the Hispanic population, further research is warranted to identify specific high-risk groups for triple-negative breast cancer.³¹

Subtypes of TNBC

In 2011, Lehmann et al¹⁰ conducted a gene expression profiling study on tumor samples from 587 patients diagnosed with TNBC, classifying TNBC into six distinct subtypes: basal-like 1 (BL1), basal-like 2 (BL2), mesenchymal (M), mesenchymal stem cell-like (MSL), immunomodulatory (IM), and luminal androgen receptor (LAR). Additionally, they performed genetic profiling and categorized existing TNBC breast cancer cell lines into six subtypes, thereby establishing a reliable cellular model for the clinical management of TNBC. A noteworthy finding of this study was the relationship between TNBC subtypes and cytokeratin expression patterns. Specifically, the LAR subtype exhibits elevated levels of luminal keratin expression but lacks basal-type keratin, which is predominantly expressed in the BL1, BL2, and M subtypes. Moreover, the correlation between the genetic profiles of TNBCs and the intrinsic gene set centroids of the five molecular subtypes derived from the intrinsic/UNC 306-gene set³² further substantiated the predominance of basal-like molecular subtypes within the TNBC cohort. Conversely, a significant proportion of triple-negative cancers have demonstrated associations with other intrinsic subtypes.

Burstein et al³³ recently proposed that the gene expression profiles associated with cancer are influenced by varying compositions of stromal and immune cells. Their research led to an enhancement in the classification of these profiles, reducing the six previously identified molecular subtypes to four distinct categories: BL1, BL2, M, and LAR. Tumors categorized as IM subtypes exhibit elevated levels of tumor-infiltrating lymphocytes (TILs), and the study elucidates the differing degrees of “IM components” present in TNBC types, which correlate with the percentage of TILs and the respective IM subtypes. Conversely, tumors classified under subtype M demonstrated a low correlation with the IM subtype.

Through the application of cluster analysis of diverse gene expression levels within a substantial cohort of patients diagnosed with TNBC, the researchers achieved precise molecular classification of this highly heterogeneous disease. Currently, the majority of investigations into the molecular typing of TNBC rely on the mRNA expression levels of various genes. However, it is important to note that mRNA expression levels do not necessarily provide an accurate representation of protein expression levels because numerous modifications and regulatory mechanisms during protein translation can influence the efficacy of targeted therapies and prognostic predictions for certain patients. Furthermore,

there remains ambiguity regarding the accurate determination of TNBC molecular subtypes based on immunohistochemical staining results and the quantity of clinical specimens available, with existing data proving to be insufficient. Consequently, there is a pressing need for further research on the various biomarkers associated with TNBC molecular subtypes and their clinical implications. It is conceivable that in future clinical settings, gene chip technology may facilitate rapid identification of breast cancer molecular subtypes in patients. Additionally, the analysis of protein expression in clinical specimens from TNBC patients using molecular techniques could provide a more accurate reflection of TNBC phenotypes, thereby informing the selection of targeted therapeutic agents (See Figure 1).

Genetics

TNBC and basaloid-like breast cancer (BLBC) are frequently misinterpreted as synonymous due to their common pathological characteristics, the absence of standardized terminology in molecular research, and the resultant ambiguity in classification.^{34,35} With advancements in genetic mapping have been made, numerous researchers have acknowledged the similarities between basaloid tumors and TNBC; however, they have also delineated distinct differences.^{33,36} It has been noted that while basaloid tumors constitute a significant proportion of TNBC cases, not all basaloid tumors exhibit a triple-negative phenotype.

BLBC is characterized by the expression of genes typically associated with basal and myoepithelial cells in normal breast tissue.³⁷ These tumors are predominantly triple-negative³⁸ and may express the epidermal growth factor receptor (EGFR);³⁹ mutations in the TP53 gene are also frequently observed.^{38–40} Immunohistochemistry serves as a valuable clinical tool for the identification of BLBC in routine practice, as the basal-like phenotype is associated with a specific immunohistochemical profile.⁴¹ This profile includes the expression of basal cell keratins (CK5/6, CK14, and CK17) and absence of ER, PR, and HER2. Based on this framework, all basaloid tumors can be classified as triple-negative. However, as noted by Lehmann^{10,42} et al, the implementation of genomic characterization has revealed significant distinctions, leading to the identification of two distinct subtypes of TNBC: basal-like and normal breast carcinoma-like.⁷

The differentiation between these two entities is significant owing to their differing prognostic implications, with TNBC characterized by a basal phenotype being linked to poorer survival outcomes in comparison to non-basal-like TNBC.^{39,43} Specifically, the clinicopathological and immunohistochemical characteristics that distinguish TNBCs from basal-like subtypes have been correlated with elevated mitotic indices, increased proliferative activity, and unfavorable prognoses.³⁹ Furthermore, basaloid carcinomas are noted for their considerable genetic instability, which includes various gene aberrations,⁷ and they frequently present with mutations in the BRCA1 gene.^{38,44}

Furthermore, Prat et al⁴⁵ analyzed all intrinsic subtypes of BC and evaluated their significance in relation to prognosis and treatment outcomes. Their findings corroborated the predominance of basaloid hapten low subtypes within the “triple-negative group”, highlighting their correlation with unfavorable prognoses and the absence of therapeutic targets. The study also explored the potential epithelial-mesenchymal origin of these tumors.

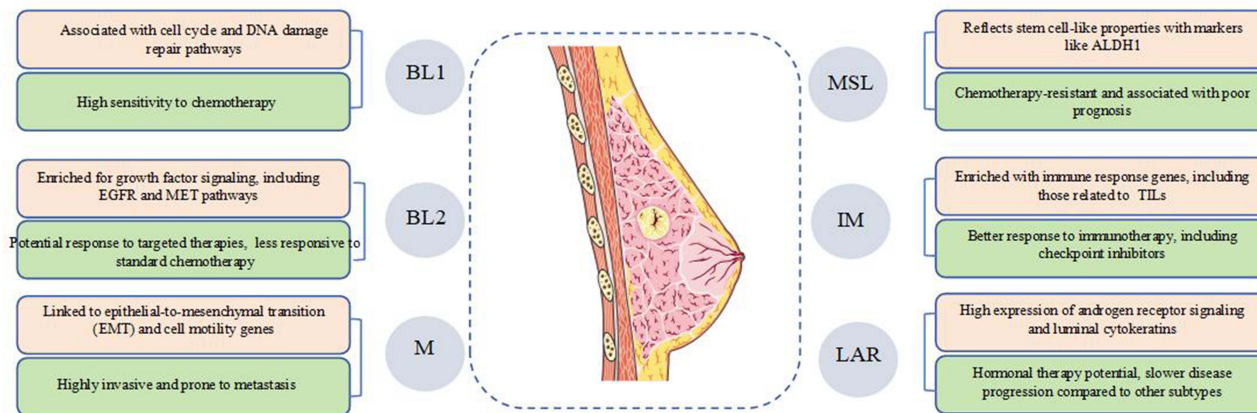


Figure 1 TNBC molecular subtypes and characteristics.

From a histological perspective, BLBC exhibits distinctive characteristics that provide valuable insights into clinical practice. Typically, these tumors are classified as high-grade invasive ductal carcinomas that do not conform to the specific subtypes. They are characterized by progressive noninvasive margins, extensive geographic necrosis, lack of differentiation accompanied by nuclear pleomorphism, elevated mitotic activity, and pronounced inflammatory infiltrates.^{36,46}

For the convenience of the reader, the similarities and differences between TNBC and BLBC are summarized in Table 1.

Research conducted by Alexandrov et al^{47–49} has elucidated that the spectrum of somatic genetic alterations in cancer, encompassing both passenger and driver mutations, can yield significant insights into the biological processes that influence cancer genomes. Specifically, mutational profiling has revealed that in BC, the predominant mutational process is characterized by senescence or a clock-like mechanism, along with mutagenesis associated with the apolipoprotein B mRNA editing enzyme, catalyzing polypeptide-like enzyme (APOBEC), which is likely a consequence of the activity of APOBEC cytidine deaminase, which serves both as a viral defense mechanism and in RNA editing. Additionally, defects in homologous recombination (HR) DNA repair have been identified.⁵⁰ Mutational processes identified through mutational signatures appear to differ based on ER and HER2 status.^{51,52} The most prevalent mutational signatures in ER-positive breast cancer are senescence, and APOBEC-related triple-negative breast cancer exhibits a notable enrichment of homologous recombination deficiency (HRD) signatures. Nevertheless, these mutational characteristics do not seem to be exclusive to any specific subtype classified using the PAM50 gene expression assay.^{53,54}

Within the realm of structural rearrangement characteristics, the tandem replicon phenotype (TDP) warrants further examination, particularly in TNBC. TDP, identified as a genome-wide configuration that promotes cancer, exhibited a notable prevalence in these tumors, with as many as 52.8% of high-grade TNBC cases demonstrating this genomic pattern. This phenomenon may arise from the interplay between genomic instability and the replication drive inherent in TNBC.⁵⁵

Molecular Pathology

Not all basaloid carcinomas and TNBC exhibit uniform histopathological and prognostic characteristics. It may be misleading to categorize all TNBC as aggressive, as the triple-negative classification encompasses a spectrum of lesions that range from low-grade to high-grade.⁵⁶ Various distinct and infrequent histological types demonstrate triple-negative features, with carcinomas exhibiting apocrine differentiation, metaplastic carcinomas, and medullary carcinomas classified as high-grade triple-negative lesions. Conversely, rare subtypes, such as salivary adenoid cystic carcinoma and secretory carcinoma, are classified as low-grade lesions.⁵⁶

TNBC exhibiting apocrine differentiation is distinguished by the expression of androgen receptors (AR) and mutations in the PIK3CA signaling pathway.⁵⁶ The prognostic significance of AR positivity in TNBC remains a subject of debate. Some researchers have posited that AR positivity correlates with improved survival outcomes.⁵⁷ Conversely, Dieci et al⁵⁸ analyzed AR expression in TNBC and revealed an association between AR positivity and reduced distant disease-free survival (DDFS) in a substantial patient cohort undergoing surgical intervention and chemotherapy. Furthermore, histopathological characteristics such as predominance of non-ductal histology, lower subtissue grade, reduced Ki67 levels, and diminished TILs are frequently linked to AR-positive TNBC, corroborating earlier findings in the literature.⁵⁸ Kensler et al⁵⁹ assessed the prognostic and predictive implications of AR expression in

Table 1 Similarities and Differences Between TNBC and BLBC

Name	TNBC	BLBC
Definitions and characteristics	Lack of ER, PR, and HER2 expression.	Basal epithelial cell gene signature, as defined by gene expression profiling.
Overlap	Most TNBCs are BLBCs, but not all BLBCs are TNBCs.	TNBC and BLBC are similar in molecular characteristics, clinical behavior and prognosis, such as high proliferation rate, strong invasiveness and poor prognosis.
Molecular characteristics	Both showed a high frequency of TP53 mutations and DNA repair pathway abnormalities.	Common gene expression features include high expression of basal markers such as cytokeratin 5/6 and EGFR.
Clinical behavior	TNBC and BLBC are common in young women, are more aggressive, and are prone to early recurrence and metastasis.	It is sensitive to standard chemotherapy, but lacks targeted therapy options.

a large cohort of postmenopausal women with estrogen receptor-positive (ER⁺) early breast cancer and found no significant correlation with prognosis. This led to the conclusion that AR signaling may exhibit differential effects in ER⁺ and ER⁻ breast tumors.

Additional significant subtypes of TNBC exhibiting basaloid characteristics include metaplastic, medullary, and adenoid cystic carcinomas.^{36,56,60} Medullary carcinomas are distinguished by their well-defined margins, notable inflammatory infiltrates, absence of tubule formation, and marked cellular polymorphism.⁶¹ This subtype is linked to the intrinsic subtype of IM and is associated with a favorable prognosis despite its high histological grade.¹⁰

Metaplastic BC is a distinct subtype of breast cancer characterized by squamous or mesenchymal differentiation and typically presents with a high histological grade.⁵⁶ This subtype is associated with poor survival outcomes and resistance to chemotherapy.⁶² Molecularly, metaplastic BC shares intrinsic genetic expression similarities with both metaplastic BC³⁵ and claudin-low tumors. Furthermore, a specific subtype of TNBC is often classified as a variant of BLBC, characterized by a low proliferative index, absence of luminal marker expression, and elevated levels of markers indicative of epithelial-to-mesenchymal transition.⁶³ Metaplastic carcinomas are associated with a high incidence of TP53 mutations and frequent activation of the PI3K and WNT signaling pathways.⁶⁴ Low-grade variants of metaplastic BC include adenosquamous carcinomas and fibromatosis-like carcinomas. Notably, adenosquamous carcinoma of the breast is a rare entity that comprises a combination of tubular glands and metaplastic components.⁶⁵ Genetic analyses of this variant have demonstrated a high prevalence of PIK3CA mutations and a notable absence of TP53 mutations.⁶⁶

Adenoid cystic carcinoma (ACC) is classified as a subset of breast tumors referred to as “salivary glandular” tumors. This classification is characterized by the presence of a dual cellular population comprising basal/myoepithelial and luminal cells, as well as genetic translocation 1 that results in the activation of the MYB1 oncogene.⁶⁷ ACC is considered a rare malignancy, and despite its classification as triple-negative, it is associated with a relatively favorable prognosis and tendency for indolent progression.⁶⁸ Classical variants of ACC typically exhibit low-grade histological features including tubular or cribriform structures, minimal cytological atypia without necrosis, and a high mitotic index. Conversely, high-grade variants, such as basal-like solid forms, may present with necrosis, significant atypia, and lymph node metastasis.^{69,70} Notably, high-grade transformations maintain MYB1 oncogene expression and are associated with the development of genetic intratumoral heterogeneity.⁷¹ It is noteworthy that ACC does not share a genetic profile with other TNBC and instead exhibits a mutation pattern similar to that observed in head and neck ACC. Specifically, mutations in TP53, PIK3CA, RB1, BRCA1, and BRCA2, which are frequently identified in TNBC, are not typically found in ACC.⁷²

In conclusion, solid papillary BC, which bears resemblance to a hypercellular variant of papillary thyroid carcinoma, is classified as a primary triple-negative breast cancer that is associated with a favorable prognosis and distinct histological characteristics similar to those of high-cell carcinoma of the thyroid.^{73,74} This tumor type is noted for its indolent nature, exhibiting a low incidence of local recurrence and lymph node metastasis⁷³ as well as the presence of IDH2 R172 and PIK3CA hotspot mutations.⁷⁵ Recently, this subtype of breast cancer has been reclassified as “high cell carcinoma of opposite polarity” because of its genetic and prognostic similarities with solid papillary carcinoma of opposite polarity.^{75,76}

Consequently, the various BC subtypes affirm the notion that the TNBC category may exhibit significant heterogeneity and complexity. A substantial proportion of TNBC cases are characterized by a high pathological grade and elevated proliferation rate, which correlates with a favorable response to chemotherapy based on cytotoxic agents.⁷⁷ However, advancements in genomic profiling technologies have facilitated a deeper understanding of the biological mechanisms underlying TNBC and yielded novel prognostic and predictive insights regarding BC treatment. Moreover, although the intrinsic subtype may not be entirely captured through histological assessment, identification of the lesser subtype of TNBC in clinical practice is crucial to prevent unnecessary overtreatment.

Treatment

Chemotherapy

Cytotoxic chemotherapy continues to be the primary systemic treatment for both early and advanced TNBC.⁷⁸ However, the optimal incorporation of platinum-based agents remains a subject of debate. In the context of neoadjuvant therapy, a meta-analysis encompassing nine randomized controlled trials indicated that the inclusion of platinum-based drugs increased the rate of pathological complete response (pCR) by 10% to 15%. However, this benefit is accompanied by an increase in hematological toxicity and a higher incidence of treatment discontinuation.⁷⁹ Notably, this meta-analysis did not establish a definitive correlation between elevated pCR rates and extended event-free survival.⁷⁹

Platinum-based chemotherapy has demonstrated reduced efficacy as an adjuvant therapy. Findings from the PATTERN trial indicated that anthracycline-free treatment regimens were associated with improved 5-year disease-free survival (DFS) rates compared to conventional anthracycline-taxane-based chemotherapy.⁸⁰ Nonetheless, this trial did not investigate the potential impact of incorporating platinum-based agents into standard treatment regimens.

In the context of metastatic disease, a meta-analysis of three randomized controlled trials (RCTs) indicated that patients receiving platinum-based therapies did not experience a significant improvement in progression-free survival (PFS) compared to those treated with alternative regimens.⁸¹ Conversely, a Phase III TNT trial demonstrated that patients harboring germline BRCA1/2 mutations exhibited a statistically significant PFS advantage when treated with carboplatin as opposed to docetaxel.⁸² Furthermore, it is noteworthy that the combination of paclitaxel and carboplatin resulted in a markedly extended median PFS duration within this specific patient cohort.⁸³

A meta-analysis encompassing 26 RCTs involving patients with early stage TNBC who received dose-dense adjuvant chemotherapy indicated a moderate yet statistically significant enhancement in the long-term outcomes associated with this dosing strategy.⁸⁴ It is noteworthy that the majority of trials examined variations in agents and dosages, with only a limited number directly comparing identical chemotherapy regimens administered via standard and dose-dense protocols.^{85–88}

Targeted Therapy

Owing to the significant heterogeneity observed in TNBC, identifying novel therapeutic targets and developing targeted therapies presents considerable challenges. Currently, numerous clinical trials are underway that focus on targeted therapies for TNBC, which aim to address specific receptors or are informed by immunohistochemical staining outcomes (See Figure 2).

Nielsen et al⁴¹ conducted a comprehensive DNA microarray analysis of a substantial cohort of BLBC samples, revealing that approximately 60% exhibited high expression levels of EGFR. Supporting this finding, Livasy et al⁸⁹ reported that between 70% and 78% of basal-like TNBC samples demonstrated elevated EGFR expression.

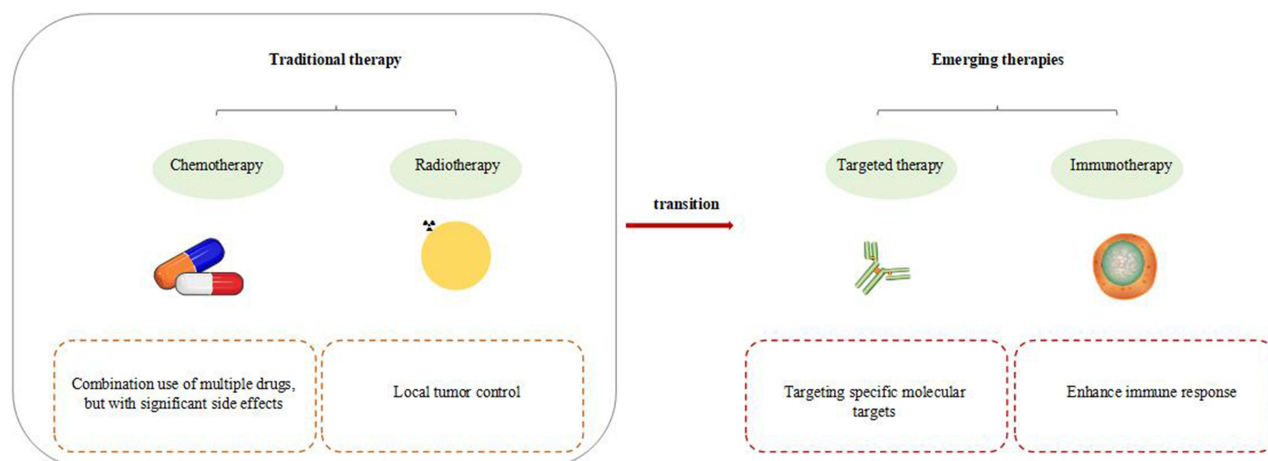


Figure 2 TNBC treatment strategy and research progress.

Consequently, it has been hypothesized that EGFR may serve as a viable therapeutic target in TNBC. However, a randomized Phase II clinical trial involving 120 TNBC patients indicated that the response rates (RRs) to cetuximab monotherapy was below 6% and only 17% when cetuximab was combined with carboplatin.⁹⁰ Thus, despite robust preclinical evidence advocating EGFR as a potential target for TNBC therapy, clinical trial outcomes have not met the anticipated expectations. Cho et al⁹¹ recently identified a subset of triple-negative cells that are activated via the ERBB signaling pathway. While bulk RNA sequencing data revealed no significant changes in the expression of three subtype marker genes (ERBB2, ESRI, and PGR), single-cell transcriptomic analysis revealed intratumoral heterogeneity. This finding implies that ERBB signaling may be activated through an indirect mechanism, and that molecular subtypes can be modified at the single-cell level.

Poly ADP-ribose polymerase (PARP) belongs to a class of enzymes involved in DNA repair mechanisms. The primary roles of PARP include maintenance of genomic stability, DNA repair, cell cycle progression, and apoptosis.⁹² Among the PARP family members, PARP-1 is particularly important because of its essential function in DNA repair processes. The inhibition of PARP activity results in the impairment of DNA repair capabilities, which subsequently triggers apoptotic pathways. Furthermore, PARP inhibitors have been shown to markedly enhance the efficacy of radiotherapy and chemotherapy.⁹³ Notably, these inhibitors exhibit a pronounced antitumor effect in tumors deficient in BRCA1/2, demonstrating a therapeutic advantage that is 100–1000 times greater in BRCA1-mutated tumors than in those lacking this mutation.⁹⁴ Consequently, PARP inhibitors represent a promising avenue for targeted therapy in TNBC patients harboring BRCA1 mutations.

Immunotherapy

Recent advancements in immunotherapy for TNBC have led to diversification of treatment strategies. The development of immune checkpoint inhibitors (ICIs) has facilitated the identification of various molecular subtypes, thereby enabling the development of tailored immunotherapy protocols. ICIs function by disrupting the inhibitory mechanisms of the immune system that prevent it from attacking cancer cells. The most notable ICIs target CTLA-4, PD-1, and protein 1 (PD-L1). Comprehensive multiomics analyses have revealed distinct microenvironmental characteristics and immune evasion strategies associated with TNBC. These microenvironments can be categorized into three types: the immune desert type, which fails to recruit immune cells; the immunosuppressive type, characterized by the presence of chemotaxis, but with inactivated innate immunity and low levels of tumor antigens, potentially facilitating immune evasion; and the immune inflammatory type, which exhibits elevated expression of immune checkpoint molecules. The findings from this study provide valuable insights for personalized immunotherapy of patients with TNBC.

Programmed cell death protein 1 (PD-1) is a significant immunosuppressive molecule predominantly located on immune cells,⁹⁵ including T, B, natural killer (NK), and myeloid cells. Its ligand, programmed cell death ligand 1 (PD-L1), is expressed by tumor cells and activated T cells, macrophages, and cancer-associated fibroblasts (CAFs).⁹⁶ The interaction between PD-1 and PD-L1 activates SH2 domain-containing protein tyrosine phosphatase 2 (SHP2), which subsequently downregulates phosphoinositide 3-kinase/protein kinase B (PI3K/AKT) signaling. This process inhibits the proliferation of T and B cells in the peripheral tissues, induces programmed cell death in T cells, and mitigates autoimmune diseases, thereby contributing to the maintenance of immune homeostasis. However, this mechanism also facilitates immune evasion by tumor cells.⁹⁷ The US Food and Drug Administration (FDA) has approved several PD-1/PD-L1 inhibitors, including opdivo, pimumab, atezolizumab, semimumab, aviumumab, and Duvarumumab.⁹⁸ Research indicates that PD-L1 expression is observed in approximately 20–30% of TNBC cases, correlating with lymphocytic infiltration and histological grade. Furthermore, the combination of PD-1/PD-L1 inhibitors with extracellular signal-regulated kinase 1/2 inhibitors has demonstrated enhanced efficacy in TNBC cell lines compared with non-TNBC cells.⁹⁹ In a Phase I clinical trial, the PD-L1 inhibitor, atezolizumab, administered as monotherapy, yielded a sustained clinical benefit in patients with metastatic TNBC (mTNBC).¹⁰⁰ Nevertheless, the therapeutic efficacy of PD-1/PD-L1 inhibitors as monotherapy in TNBC is constrained by various factors, and the resistance of breast cancer cells to ICIs poses challenges to their clinical application.

Treatment of TNBC with TCM

Recent clinical practice studies have demonstrated that TCM exhibits pronounced and significant efficacy in the treatment. This form of medicine possesses inherent properties that not only target and eliminate cancer cells, but also enhance the effectiveness of chemotherapy agents, thereby contributing to cancer resistance and extending patient survival.

TCM demonstrates anti-tumor effects against TNBC through modulation of the Wnt/ β -catenin signaling pathway. Recent research has highlighted tumor-associated macrophage (TAM) as a critical factor in tumor progression. Tumor-associated macrophages (TAMs) are significant contributors to immune evasion and tumor promotion. These macrophages can differentiate into the M1 and M2 subtypes, with TAMs predominantly exhibiting the M2 phenotype. Consequently, macrophage repolarization presents a promising therapeutic strategy for cancer treatment.

Andrographolide (ADE), an active compound derived from *Andrographis paniculata* Nees, has been shown to markedly enhance the M1-like polarization of macrophages while concurrently inhibiting M2-like polarization, the formation of blood vessels in human umbilical vein endothelial cells (HUVECs), and the secretion of M2-associated cytokines such as PDGF-AA and CCL2. Further investigations have indicated that ADE can inhibit TNBC¹⁰¹ by modulating macrophage polarization and its associated functions via the Wnt5a/ β -catenin pathway.

Additionally, research conducted by Xie et al¹⁰² demonstrated that oxymatrine can counteract epithelial-mesenchymal transition (EMT) and cancer stem cell (CSC) subsets induced by bevacizumab through the inhibition of the Wnt pathway. When administered in combination, oxymatrine not only enhances the anti-tumor efficacy of bevacizumab but also mitigates the risk of recurrence and metastasis associated with targeted therapies. Furthermore, compounds such as saikosaponin,¹⁰³ hawthorn extract,¹⁰⁴ and schisandrin¹⁰⁵ have been reported to inhibit apoptosis induced by Wnt pathway-related proteins in TNBC cells.

The PI3K/protein kinase B (AKT)/mTOR signaling pathway is recognized as a critical pathway for cancer development, progression, and chemoresistance.¹⁰⁶ Within this pathway, AKT and mTOR serve as pivotal nodes downstream of PI3K. Activation of the PI3K pathway is frequently linked to activation of oncogenes or inactivation of tumor suppressor genes.^{107,108} Numerous studies have indicated that patients with TNBC often exhibit mutations in genes such as TP53, PIK3CA, PREN, and RB1.¹⁰⁹ SOLZAK et al¹¹⁰ conducted a comparative analysis of RNA sequencing data from normal breast tissues and TNBC tissues, revealing that even in TNBC tissues devoid of the aforementioned gene mutations, there was significant overexpression of components associated with the PI3K/AKT/mTOR pathway, including AKT, p21, 4E-BP1, and S6 kinase. Additionally, WU et al¹¹¹ demonstrated that luteolin could inhibit the proliferation and metastasis of androgen receptor-positive TNBC cells by disrupting the PI3K/AKT/mTOR signaling pathway. Furthermore, luteolin exhibits potential synergistic effects when used in conjunction with mTOR and AKT inhibitors in cancer treatment. Subsequent investigations into its mechanism of action revealed that luteolin exerts its anti-tumor effects by modulating histone acetylation through epigenetic modifications.

Aberrant activation of the Hh signaling pathway has been associated with the pathogenesis of various tumors, including TNBC, basal cell carcinoma, and medulloblastoma. The primary effector molecules within the Hh signaling pathway include Hh ligands, Patched (Ptch), and Gli proteins, which are integral to the transcriptional regulation of downstream target genes such as Cyclin D, Cyclin E, and Wnt. Research conducted by Lee et al¹¹² demonstrated that the expression of GLI-1 was significantly elevated in TNBC tissues compared to normal and hyperplastic breast tissues. Among the Gli family members, GLI-1 predominantly functions as a transcriptional activator, thereby facilitating pathway activation, in contrast to Gli-2 and Gli-3.¹¹³ Furthermore, Wang et al¹¹⁴ reported that gambogic acid, derived from gamboge, markedly enhanced the expression of cleaved caspase-3 and BAX while concurrently diminishing Bcl-2 expression in cells through downregulation of the Sonic Hedgehog (SHH) signaling pathway. This compound also exhibits the capacity to inhibit the activity of paclitaxel-resistant TNBC cells, increase the rate of apoptosis, and improve sensitivity to paclitaxel, thereby effectively reversing drug resistance. In addition to traditional Chinese medicinal extracts, sulforaphane,¹¹⁵ which is obtained from vegetables, has demonstrated significant anti-TNBC properties.

The Notch signaling cascade is critically involved in the progression, metastasis, drug resistance, and prognosis of TNBC. Research conducted by Zhang et al¹¹⁶ demonstrated through in vitro studies that targeted deletion of the Lfng

gene, a downstream target of the Notch pathway, in a TNBC cell line can effectively inhibit Notch pathway activation, subsequently leading to reduced cell proliferation and tumor formation. Furthermore, Kushwaha et al¹¹⁷ reported that extracts from *Phalaris arundinacea* significantly diminished the viability of TNBC cell lines, induced cell cycle arrest in the G1 phase, generated elevated levels of reactive oxygen species (ROS) induced cancer cell death, and promoted apoptosis. Additionally, these extracts exhibit the capacity to decrease secretase enzyme activity, thereby reducing the production of Hes1 and Hey1, which results in downregulation of the Notch pathway. Twist1, a transcription factor with a molecular weight of 21 kDa, can be activated by various signaling pathways to enhance its transcriptional activity. Its overexpression is frequently observed in cancer tissues and its expression varies across cancer types. Twist1 has been implicated in facilitating tumor invasion and metastasis,¹¹⁸ and contributes to drug resistance¹¹⁹ (See Figures 3 and 4).

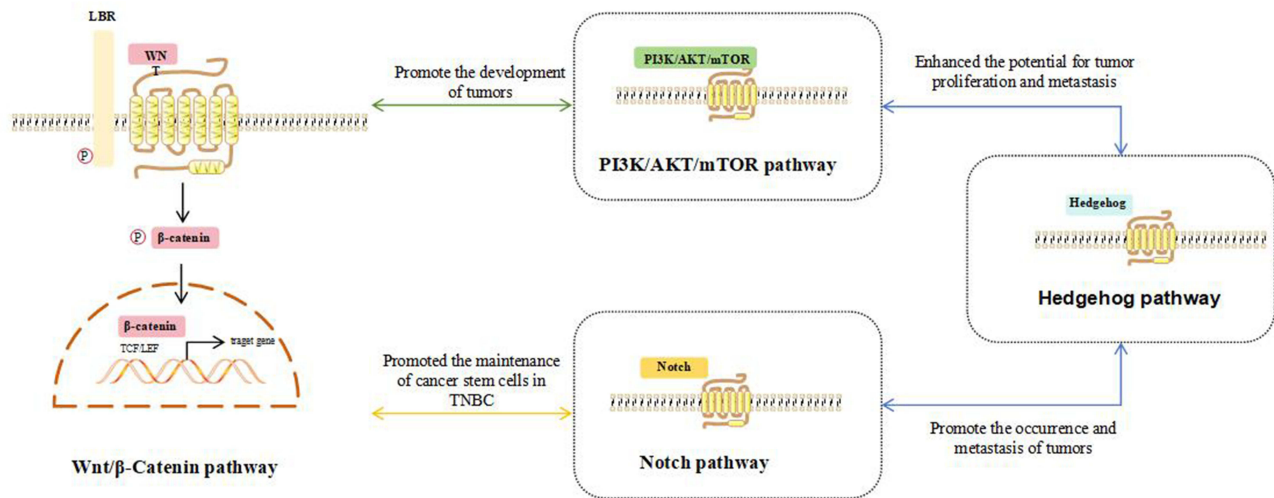


Figure 3 The key signaling pathway of TNBC.

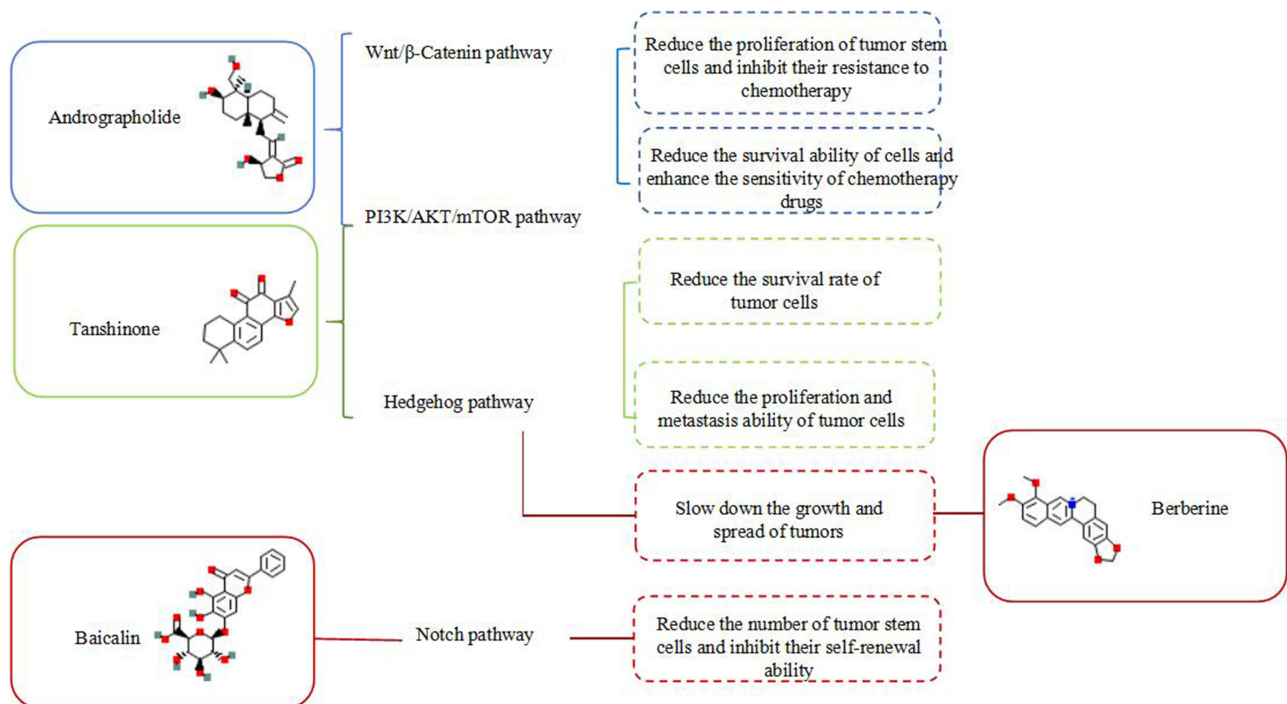


Figure 4 The mechanism of traditional Chinese medicine in treating TNBC.

Conclusion

TNBC is an operational classification that encompasses a diverse array of diseases characterized by the absence of ER, PR, and HER2. Despite this shared deficiency, these diseases exhibit considerable variations in their histological features, genomic profiles, clinical behaviors, and therapeutic responses. TNBC continues to pose significant challenges as a subtype of breast cancer, often associated with poor prognosis, and existing treatment options remain insufficient for managing unresectable or recurrent TNBC tumors. In recent decades, advances in sequencing technology have greatly enhanced our understanding of TNBC. Consequently, new pharmacological agents are being continually developed and evaluated in clinical trials.

Given the distinct characteristics of TNBC, integration of immunotherapy into its treatment regimen is becoming increasingly essential. Immune checkpoint inhibitors, such as atezolizumab and pembrolizumab, have demonstrated partial efficacy in improving patient outcomes. Bispecific antibodies (BsAbs) and bispecific T-cell engagers (BiTEs) have been developed to address the limitations associated with the immune response rates of single-target monoclonal antibodies. Furthermore, novel antibody-drug conjugates (ADCs), including sacituzumab govitecan, have recently received FDA approval. Although adoptive cell therapy (ACT) for solid tumors has advanced significantly, it is yet to yield optimal results. While immunotherapy is making substantial strides in the management of TNBC, it appears to be insufficient as a standalone treatment. Therefore, a combination therapeutic approach that incorporates immunotherapy may be a more effective strategy for enhancing treatment outcomes in TNBC.

TCM has demonstrated a notable effect on TNBC, exhibiting the ability to inhibit the proliferation, invasion, and migration of TNBC cells. Additionally, TCM can suppress EMT, reverse resistance to chemotherapeutic agents such as paclitaxel and platinum, enhance the sensitivity of tumor cells to these drugs, and promote apoptosis in cancer cells by modulating pathways such as Wnt/ β -catenin and Notch. Furthermore, the various signaling pathways involved in TCM's therapeutic effects of TCM in TNBC do not operate in isolation; rather, they engage in complex interactions characterized by "crosstalk".

Despite these promising findings, several limitations persist in the application of TCM for TNBC treatment. First, the predominant reliance on animal models in research presents certain constraints and highlights a deficiency in high-quality clinical validation both *in vivo* and *in vitro*. Second, current investigations have primarily focused on the individual components of natural medicinal plants or single agents, with insufficient exploration of TCM formulations. Third, there is a notable lack of research addressing the pharmacokinetics and potential adverse reactions associated with TCM in TNBC treatment. Finally, the intricate and dynamic nature of TNBC pathophysiology, which arises from the dysregulation of multiple pathways rather than a singular abnormality, complicates the understanding of TCM mechanisms. Given that TCM is characterized by its multi-target and multi-pathway synergistic effects, exploration of its mechanisms in TNBC treatment presents both significant challenges and critical importance.

To enhance the efficacy of TNBC treatments, several areas warrant further investigation. First, there is a need for additional research aimed at improving the effectiveness of current pharmacological agents and at addressing issues related to drug resistance. Second, although some clinical trials have indicated that combination therapies may yield superior outcomes compared to monotherapies, the optimal sequencing and timing of these combinations require further exploration. Third, it is essential to conduct further studies to identify novel therapeutic targets, biomarkers, and pharmacological agents.

In this review, we delineate the subtypes and characteristics of TNBC, along with its underlying pathology. We also summarize recent advancements in targeted therapies, immunotherapies, and TCM while discussing prospective avenues for enhancing clinical outcomes in TNBC treatment. Nevertheless, the current state of TNBC research remains inadequate, indicating that significant progress is necessary in the future.

Abbreviation

TNBC, Triple-negative breast cancer; BC, breast cancer; HER2, human epidermal growth factor receptor 2; OS, overall survival; ER, estrogen receptor; PR, progesterone receptor; BLBC, basal-like breast cancer; BMI, body mass index; MRI, magnetic resonance imaging; BL1, basal-like 1; BL2, basal-like 2; M, mesenchymal; MSL, mesenchymal stem cell-like; IM, immunomodulatory; LAR, luminal androgen receptor; TILs, tumor-infiltrating lymphocytes; EGFR, epidermal growth factor receptor; APOBEC, apolipoprotein B mRNA editing enzyme, catalyzing polypeptide-like; HRD, HR

deficiency; TDP, tandem replicon phenotype; AR, androgen receptors; DDFS, distant disease-free survival; ER+, estrogen receptor-positive; ACC, adenoid cystic carcinoma; RCTs, randomized controlled trials; pCR, pathological complete response; DFS, disease-free survival; PFS, progression-free survival; RRs, response rates; PARP, Poly(ADP-ribose) polymerase; ICIs, immune checkpoint inhibitors; PD-1, protein 1; NK, natural killer; PD-L1, programmed cell death ligand 1; CAFs, cancer-associated fibroblasts; SHP2, SH2 protein tyrosine phosphatase 2; PI3K, phosphoinositide 3-kinase; AKT, protein kinase B; FDA, Food and Drug Administration; TCM, traditional Chinese medicine; TAM, tumor-associated microenvironment; TAMs, Tumor-associated macrophages; ADE, Andrographolide; HUVECs, human umbilical vein endothelial cells; EMT, epithelial-mesenchymal transition; CSCs, cancer stem cells; Ptc, Patched; ROS, reactive oxygen species; BsAb, bispecific antibodies; BiTE, bispecific T-cell engagers; ADCs, antibody-drug conjugates; ACT, adoptive cell therapy.

Disclosure

The authors declare that they have no affiliation with or involvement in any organization or entity with any financial interest in the subject matter or materials discussed in this manuscript.

References

1. Rakha EA. Triple-negative/basal-like breast cancer: review. *Pathology*. 2010;42(6):40–47.
2. Prat A, Lluch A, Albanell J. Predicting response and survival in chemotherapy-treated triple-negative breast cancer. *Br J Cancer*. 2014;111(8):1532–1541. doi:10.1038/bjc.2014.444
3. Luo S-P, Wu Q-S, Chen H, et al. Validation of the prognostic significance of the prognostic stage group according to the eighth edition of American cancer joint committee on cancer staging system in triple-negative breast cancer: an analysis from surveillance, epidemiology, and end results 18 database. *J Surg Res*. 2020;247:211–219. doi:10.1016/j.jss.2019.09.072
4. Pareja F, Geyer FC, Marchiò C, et al. Triple-negative breast cancer: the importance of molecular and histologic subtyping, and recognition of low-grade variants. *NPJ Breast Cancer*. 2016;2(1):1–11.
5. Dent R, Trudeau M, Pritchard KI, et al. Triple-negative breast cancer: clinical features and patterns of recurrence. *Clin Cancer Res*. 2007;13(15):4429–4434. doi:10.1158/1078-0432.CCR-06-3045
6. Boyle P. Triple-negative breast cancer: epidemiological considerations and recommendations. *Ann Oncol*. 2012;23:vi7–vi12. doi:10.1093/annonc/mds187
7. Perou CM, Sørlie T, Eisen MB, et al. Molecular portraits of human breast tumours. *nature*. 2000;406(6797):747–752. doi:10.1038/35021093
8. Hallett RM, Dvorkin-Gheva A, Bane A, et al. A gene signature for predicting outcome in patients with basal-like breast cancer. *Sci Rep*. 2012;2(1):227. doi:10.1038/srep00227
9. Bonotto M, Gerrata L, Poletto E, et al. Measures of outcome in metastatic breast cancer: insights from a real-world scenario. *oncologist*. 2014;19(6):608–615. doi:10.1634/theoncologist.2014-0002
10. Lehmann BD, Bauer JA, Chen X, et al. Identification of human triple-negative breast cancer subtypes and preclinical models for selection of targeted therapies. *J Clin Invest*. 2011;121(7):2750–2767. doi:10.1172/JCI45014
11. Denkert C, Liedtke C, Tutt A, et al. Molecular alterations in triple-negative breast cancer—the road to new treatment strategies. *Lancet*. 2017;389(10087):2430–2442.
12. Esteva A, Kuprel B, Novoa RA, et al. Dermatologist-level classification of skin cancer with deep neural networks. *nature*. 2017;542(7639):115–118. doi:10.1038/nature21056
13. Lecun Y, Bengio Y, Hinton G. Deep learning. *Nature*. 2015;521(7553):436–444.
14. Dawson S-J, Tsui DW, Murtaza M, et al. Analysis of circulating tumor DNA to monitor metastatic breast cancer. *N Engl J Med*. 2013;368(13):1199–1209. doi:10.1056/NEJMoa1213261
15. Bray F, Ferlay J, Soerjomataram I, et al. Global cancer statistics 2018: GLOBOCAN estimates of incidence and mortality worldwide for 36 cancers in 185 countries. *Ca a Cancer J Clinicians*. 2018;68(6):394–424. doi:10.3322/caac.21492
16. Trivers KF, Lund MJ, Porter PL, et al. The epidemiology of triple-negative breast cancer, including race. *Cancer Causes Control*. 2009;20:1071–1082. doi:10.1007/s10552-009-9331-1
17. Stark A, Schultz D, Kapke A, et al. Obesity and risk of the less commonly diagnosed subtypes of breast cancer. *Eur J Surg Oncol*. 2009;35(9):928–935. doi:10.1016/j.ejso.2008.11.009
18. Millikan RC, Newman B, Tse C-K. Epidemiology of basal-like breast cancer. *Breast Cancer Res Treat*. 2008;109:123–139. doi:10.1007/s10549-007-9632-6
19. Gulbağcı HE, Bernard PS, Weltzien EK. Differences in molecular features of triple-negative breast cancers based on the age at diagnosis. *Cancer*. 2018;124(24):4676–4684. doi:10.1002/encr.31776
20. Howard FM, Olopade OI. Epidemiology of triple-negative breast cancer: a review. *Cancer J*. 2021;27(1):8–16. doi:10.1097/PPO.0000000000000500
21. Howlader N, Cronin KA, Kurian AW, et al. Differences in breast cancer survival by molecular subtypes in the United States. *Cancer Epidemiol Biomarkers Prev*. 2018;27(6):619–626.
22. Niraula S, Biswanger N, Hu P, et al. Incidence, characteristics, and outcomes of interval breast cancers compared with screening-detected breast cancers. *JAMA Network Open*. 2020;3(9):e2018179–e. doi:10.1001/jamanetworkopen.2020.18179

23. Bellio G, Marion R, Giudici F, et al. Interval breast cancer versus screen-detected cancer: comparison of clinicopathologic characteristics in a single-center analysis. *Clin Breast Cancer*. 2017;17(7):564–571. doi:10.1016/j.clbc.2017.04.001
24. Dogan B, Turnbull L. Imaging of triple-negative breast cancer. *Ann Oncol*. 2012;23:vi23–vi9. doi:10.1093/annonc/mds191
25. Kwan ML, Kushi LH, Weltzien E, et al. Epidemiology of breast cancer subtypes in two prospective cohort studies of breast cancer survivors. *Breast Cancer Res*. 2009;11:1–13.
26. Shinde SS, Forman MR, Kuerer HM, et al. Higher parity and shorter breastfeeding duration: association with triple-negative phenotype of breast cancer. *Cancer*. 2010;116(21):4933–4943. doi:10.1002/cncr.25443
27. Kohler BA, Sherman RL, Howlader N, et al. Annual report to the nation on the status of cancer, 1975–2011, featuring incidence of breast cancer subtypes by race/ethnicity, poverty, and state. *J National Cancer Inst*. 2015;107(6):djv048. doi:10.1093/jnci/djv048
28. Shoemaker ML, White MC, Wu M, et al. Differences in breast cancer incidence among young women aged 20–49 years by stage and tumor characteristics, age, race, and ethnicity, 2004–2013. *Breast Cancer Res Treat*. 2018;169:595–606. doi:10.1007/s10549-018-4699-9
29. Huo D, Ikpatt F, Khrantsov A, et al. Population differences in breast cancer: survey in indigenous African women reveals over-representation of triple-negative breast cancer. *J Clin Oncol*. 2009;27(27):4515–4521. doi:10.1200/JCO.2008.19.6873
30. Huo D, Adebamowo C, Ogundiran T, et al. Parity and breastfeeding are protective against breast cancer in Nigerian women. *Br J Cancer*. 2008;98(5):992–996. doi:10.1038/sj.bjc.6604275
31. Pinheiro PS, Sherman RL, Trapido EJ, et al. Cancer incidence in first generation US Hispanics: Cubans, Mexicans, Puerto Ricans, and new Latinos. *Cancer Epidemiol Biomarkers Prev*. 2009;18(8):2162–2169.
32. Hu Z, Fan C, Oh DS, et al. The molecular portraits of breast tumors are conserved across microarray platforms. *BMC Genomics*. 2006;7:1–12. doi:10.1186/1471-2164-7-1
33. Lehmann BD, Jovanović B, Chen X, et al. Refinement of triple-negative breast cancer molecular subtypes: implications for neoadjuvant chemotherapy selection. *PLoS One*. 2016;11(6):e0157368. doi:10.1371/journal.pone.0157368
34. Kreike B, Van Kouwenhove M, Horlings H, et al. Gene expression profiling and histopathological characterization of triple-negative/basal-like breast carcinomas. *Breast Cancer Res*. 2007;9:1–14. doi:10.1186/bcr1771
35. Turner NC, Reis-Filho JS. Tackling the diversity of triple-negative breast cancer. *Clin Cancer Res*. 2013;19(23):6380–6388. doi:10.1158/1078-0432.CCR-13-0915
36. Rakha E, Reis-Filho JS. Basal-like breast carcinoma: from expression profiling to routine practice. *Arch Pathol Lab Med*. 2009;133(6):860–868.
37. Reis-Filho J, Tutt A. Triple negative tumours: a critical review. *Histopathology*. 2008;52(1):108–118. doi:10.1111/j.1365-2559.2007.02889.x
38. Leidy J, Khan A, Kandil D. Basal-like breast cancer: update on clinicopathologic, immunohistochemical, and molecular features. *Arch Pathol Lab Med*. 2014;138(1):37–43. doi:10.5858/arpa.2012-0439-RA
39. Rakha EA, Elsheikh SE, Aleskandarany MA, et al. Triple-negative breast cancer: distinguishing between basal and nonbasal subtypes. *Clin Cancer Res*. 2009;15(7):2302–2310. doi:10.1158/1078-0432.CCR-08-2132
40. Borresen-Dale AL. TP53 and breast cancer. *Human Mutation*. 2003;21(3):292–300. doi:10.1002/humu.10174
41. Nielsen TO, Hsu FD, Jensen K, et al. Immunohistochemical and clinical characterization of the basal-like subtype of invasive breast carcinoma. *Clin Cancer Res*. 2004;10(16):5367–5374. doi:10.1158/1078-0432.CCR-04-0220
42. Bertucci F, Finetti P, Cervera N, et al. How basal are triple-negative breast cancers? *Int J Cancer*. 2008;123(1):236–240. doi:10.1002/ijc.23518
43. Toft DJ, Cryns VL. Minireview: basal-like breast cancer: from molecular profiles to targeted therapies. *Mol Endocrinol*. 2011;25(2):199–211. doi:10.1210/me.2010-0164
44. Tutt A, Tovey H, Cheang MCU, et al. Carboplatin in BRCA1/2-mutated and triple-negative breast cancer BRCAness subgroups: the TNT trial. *Nature Med*. 2018;24(5):628–637. doi:10.1038/s41591-018-0009-7
45. Prat A, Perou CM. Deconstructing the molecular portraits of breast cancer. *Mol Oncol*. 2011;5(1):5–23. doi:10.1016/j.molonc.2010.11.003
46. Lavasani MA, Moifar F. Molecular classification of breast carcinomas with particular emphasis on “basal-like” carcinoma: a critical review. *J Biophotonics*. 2012;5(4):345–366. doi:10.1002/jbio.201100097
47. Alexandrov LB, Jones PH, Wedge DC. Clock-like mutational processes in human somatic cells. *Nature Genet*. 2015;47(12):1402–1407. doi:10.1038/ng.3441
48. Alexandrov LB, Kim J, Haradhvala NJ. The repertoire of mutational signatures in human cancer. *Nature*. 2020;578(7793):94–101. doi:10.1038/s41586-020-1943-3
49. Alexandrov LB, Nik-Zainal S, Wedge DC, et al. Signatures of mutational processes in human cancer. *nature*. 2013;500(7463):415–421. doi:10.1038/nature12477
50. Nik-Zainal S, Davies H, Staaf J, et al. Landscape of somatic mutations in 560 breast cancer whole-genome sequences. *Nature*. 2016;534(7605):47–54. doi:10.1038/nature17676
51. Degasperi A, Amarante TD, Czarnecki J, et al. A practical framework and online tool for mutational signature analyses show intertissue variation and driver dependencies. *Nat Cancer*. 2020;1(2):249–263. doi:10.1038/s43018-020-0027-5
52. Nik-Zainal S, Alexandrov LB, Wedge DC, et al. Mutational processes molding the genomes of 21 breast cancers. *Cell*. 2012;149(5):979–993. doi:10.1016/j.cell.2012.04.024
53. Jiang Y-Z, Ma D, Suo C, et al. Genomic and transcriptomic landscape of triple-negative breast cancers: subtypes and treatment strategies. *Cancer Cell*. 2019;35(3):428–40.e5. doi:10.1016/j.ccell.2019.02.001
54. Nik-Zainal S, Morganella S. Mutational signatures in breast cancer: the problem at the DNA level. *Clin Cancer Res*. 2017;23(11):2617–2629. doi:10.1158/1078-0432.CCR-16-2810
55. Menghi F, Inaki K, Woo X, et al. The tandem duplicator phenotype as a distinct genomic configuration in cancer. *Proc Natl Acad Sci*. 2016;113(17):E2373–E82.
56. Geyer FC, Pareja F, Weigelt B, et al. The spectrum of triple-negative breast disease: high- and low-grade lesions. *Am J Pathol*. 2017;187(10):2139–2151. doi:10.1016/j.ajpath.2017.03.016
57. Bozovic-Spasojevic I, Zardavas D, Brohée S, et al. The prognostic role of androgen receptor in patients with early-stage breast cancer: a meta-analysis of clinical and gene expression data. *Clin Cancer Res*. 2017;23(11):2702–2712. doi:10.1158/1078-0432.CCR-16-0979

58. Dieci MV, Tsvetkova V, Griguolo G, et al. Androgen receptor expression and association with distant disease-free survival in triple negative breast cancer: analysis of 263 patients treated with standard therapy for stage I-III disease. *Front Oncol.* 2019;9:452. doi:10.3389/fonc.2019.00452
59. Kensler KH, Regan MM, Heng YJ, et al. Prognostic and predictive value of androgen receptor expression in postmenopausal women with estrogen receptor-positive breast cancer: results from the Breast International Group Trial 1–98. *Breast Cancer Res.* 2019;21:1–11. doi:10.1186/s13058-018-1086-8
60. Elsayaf Z, Sinn H-P. Triple-negative breast cancer: clinical and histological correlations. *Breast Care.* 2011;6(4):273–278. doi:10.1159/000331643
61. Ridolfi RL, Rosen PP, Port A, et al. Medullary carcinoma of the breast. A clinicopathologic study with 10 year follow-up. *Cancer.* 1977;40(4):1365–1385. doi:10.1002/1097-0142(197710)40:4<1365::AID-CNCR2820400402>3.0.CO;2-N
62. Jung S-Y, Kim HY, Nam B-H, et al. Worse prognosis of metaplastic breast cancer patients than other patients with triple-negative breast cancer. *Breast Cancer Res Treat.* 2010;120:627–637. doi:10.1007/s10549-010-0780-8
63. Prat A, Parker JS, Karginova O, et al. Phenotypic and molecular characterization of the claudin-low intrinsic subtype of breast cancer. *Breast Cancer Res.* 2010;12:1–18.
64. Krings G, Chen -Y-Y. Genomic profiling of metaplastic breast carcinomas reveals genetic heterogeneity and relationship to ductal carcinoma. *Mod Pathol.* 2018;31(11):1661–1674. doi:10.1038/s41379-018-0081-z
65. Van Hoesen K, Drudis T, Cranor ML, et al. Low-grade adenosquamous carcinoma of the breast: a clinicopathologic study of 32 cases with ultrastructural analysis. *Am J Surg Pathol.* 1993;17(3):248–258. doi:10.1097/0000478-199303000-00005
66. Bataillon G, Fuhrmann L, Girard E, et al. High rate of PIK 3 CA mutations but no TP 53 mutations in low-grade adenosquamous carcinoma of the breast. *Histopathology.* 2018;73(2):273–283. doi:10.1111/his.13514
67. Agafonoff S, Sobolewski A, Braverman TS. Adenoid cystic carcinoma of the breast-Discordant size on imaging and pathology: a case report and review of literature. *Ann Med Surg.* 2019;43:1–4. doi:10.1016/j.amsu.2019.04.007
68. Marchio C, Weigelt B, Reis-Filho JS. Adenoid cystic carcinomas of the breast and salivary glands (or ‘The strange case of Dr Jekyll and Mr Hyde’ of exocrine gland carcinomas). *J Clin Pathol.* 2010;63(3):220–228. doi:10.1136/jcp.2009.073908
69. Shin SJ, Rosen PP. Solid variant of mammary adenoid cystic carcinoma with basaloid features: a study of nine cases. *Am J Surg Pathol.* 2002;26(4):413–420. doi:10.1097/0000478-200204000-00002
70. Foschini MP, Rizzo A, De Leo A, et al. Solid variant of adenoid cystic carcinoma of the breast: a case series with proposal of a new grading system. *Int J Surg Pathol.* 2016;24(2):97–102. doi:10.1177/1066896915606973
71. Fusco N, Geyer FC, De Filippo MR, et al. Genetic events in the progression of adenoid cystic carcinoma of the breast to high-grade triple-negative breast cancer. *Mod Pathol.* 2016;29(11):1292–1305. doi:10.1038/modpathol.2016.134
72. Martelotto LG, De Filippo MR, Ng CK, et al. Genomic landscape of adenoid cystic carcinoma of the breast. *J Pathol.* 2015;237(2):179–189. doi:10.1002/path.4573
73. Foschini MP, Asioli S, Foreid S, et al. Solid papillary breast carcinomas resembling the tall cell variant of papillary thyroid neoplasms: a unique invasive tumor with indolent behavior. *Am J Surg Pathol.* 2017;41(7):887–895. doi:10.1097/PAS.0000000000000853
74. Colella R, Guerriero A, Giansanti M, et al. An additional case of breast tumor resembling the tall cell variant of papillary thyroid carcinoma. *Int J Surg Pathol.* 2015;23(3):217–220. doi:10.1177/1066896914536222
75. Lozada JR, Basili T, Pareja F, et al. Solid papillary breast carcinomas resembling the tall cell variant of papillary thyroid neoplasms (solid papillary carcinomas with reverse polarity) harbour recurrent mutations affecting IDH 2 and PIK 3 CA: a validation cohort. *Histopathology.* 2018;73(2):339–344. doi:10.1111/his.13522
76. Zhong E, Hoda S, Scognamiglio T, et al. Tall cell (With Reverse Polarity) carcinoma of breast: molecular characterization of six cases by next-generation sequencing. *Am J Clin Pathol.* 2018;150(suppl_1):S48–S. doi:10.1093/ajcp/aly090.117
77. Prat A, Fan C, Fernández A, et al. Response and survival of breast cancer intrinsic subtypes following multi-agent neoadjuvant chemotherapy. *BMC Med.* 2015;13:1–11. doi:10.1186/s12916-015-0540-z
78. Bianchini G, Balko JM, Mayer IA, et al. Triple-negative breast cancer: challenges and opportunities of a heterogeneous disease. *Nat Rev Clin Oncol.* 2016;13(11):674–690. doi:10.1038/nrclinonc.2016.66
79. Poggio F, Bruzzone M, Ceppi M, et al. Platinum-based neoadjuvant chemotherapy in triple-negative breast cancer: a systematic review and meta-analysis. *Ann Oncol.* 2018;29(7):1497–1508. doi:10.1093/annonc/mdy127
80. Yu K-D, Ye F-G, He M, et al. Effect of adjuvant paclitaxel and carboplatin on survival in women with triple-negative breast cancer: a Phase 3 randomized clinical trial. *JAMA Oncol.* 2020;6(9):1390–1396. doi:10.1001/jamaoncol.2020.2965
81. Monferrer E, Burgos-Panadero R, Blanquer-Maceiras M, Cañete A, Navarro S, Noguera R. Triple negative breast cancer and platinum-based systemic treatment: a meta-analysis and systematic review. *BMC Cancer.* 2019;19:1–9. doi:10.1186/s12885-018-5219-3
82. Tutt A, Tovey H, Cheang MCU, et al. A randomised phase III trial of carboplatin compared with docetaxel in BRCA1/2 mutated and pre-specified triple negative breast cancer “BRCAness” subgroups: the TNT Trial. *Nature Med.* 2018;24(5):628.
83. Diéras V, Han HS, Kaufman B, et al. Veliparib with carboplatin and paclitaxel in BRCA-mutated advanced breast cancer (BROCADE3): a randomised, double-blind, placebo-controlled, phase 3 trial. *Lancet Oncol.* 2020;21(10):1269–1282. doi:10.1016/S1470-2045(20)30447-2
84. Gray R, Bradley R, Braybrooke J, et al. Increasing the dose intensity of chemotherapy by more frequent administration or sequential scheduling: a patient-level meta-analysis of 37 298 women with early breast cancer in 26 randomised trials. *Lancet.* 2019;393(10179):1440–1452.
85. Cameron D, Morden JP, Canney P, et al. Accelerated versus standard epirubicin followed by cyclophosphamide, methotrexate, and fluorouracil or capecitabine as adjuvant therapy for breast cancer in the randomised UK TACT2 trial (CRUK/05/19): a multicentre, phase 3, open-label, randomised, controlled trial. *Lancet Oncol.* 2017;18(7):929–945. doi:10.1016/S1470-2045(17)30404-7
86. Citron ML, Berry DA, Cirincione C, et al. Randomized trial of dose-dense versus conventionally scheduled and sequential versus concurrent combination chemotherapy as postoperative adjuvant treatment of node-positive primary breast cancer: first report of Intergroup Trial C9741/ Cancer and Leukemia Group B Trial 9741. *J Clin Oncol.* 2003;21(8):1431–1439. doi:10.1200/JCO.2003.09.081
87. Del Mastro L, De Placido S, Bruzzi P, et al. Fluorouracil and dose-dense chemotherapy in adjuvant treatment of patients with early-stage breast cancer: an open-label, 2 × 2 factorial, randomised phase 3 trial. *Lancet.* 2015;385(9980):1863–1872.

88. Venturini M, Del Mastro L, Aitini E, et al. Dose-dense adjuvant chemotherapy in early breast cancer patients: results from a randomized trial. *J National Cancer Inst.* 2005;97(23):1724–1733. doi:10.1093/jnci/dji398
89. Livasy CA, Karaca G, Nanda R, et al. Phenotypic evaluation of the basal-like subtype of invasive breast carcinoma. *Mod Pathol.* 2006;19(2):264–271. doi:10.1038/modpathol.3800528
90. Carey LA, Rugo HS, Marcom PK, et al. TBCRC 001: randomized phase II study of cetuximab in combination with carboplatin in stage IV triple-negative breast cancer. *J Clin Oncol.* 2012;30(21):2615–2623. doi:10.1200/JCO.2010.34.5579
91. Cho SY. Identification of ERBB pathway-activated cells in triple-negative breast cancer. *Genom & informat.* 2019;17(1). doi:10.5808/GI.2019.17.1.e3
92. Tentori L, Graziani G. Chemopotentiality by PARP inhibitors in cancer therapy. *Pharmacol Res.* 2005;52(1):25–33. doi:10.1016/j.phrs.2005.02.010
93. De Vos M, Schreiber V, Dantzer F. The diverse roles and clinical relevance of PARPs in DNA damage repair: current state of the art. *Biochem Pharmacol.* 2012;84(2):137–146. doi:10.1016/j.bcp.2012.03.018
94. Farmer H, McCabe N, Lord CJ, et al. Targeting the DNA repair defect in BRCA mutant cells as a therapeutic strategy. *Nature.* 2005;434(7035):917–921. doi:10.1038/nature03445
95. Qin W, Hu L, Zhang X, et al. The diverse function of PD-1/PD-L pathway beyond cancer. *Front Immunol.* 2019;10:2298. doi:10.3389/fimmu.2019.02298
96. Ahmed FS, Gaule P, Mcguire J, et al. PD-L1 protein expression on both tumor cells and macrophages are associated with response to neoadjuvant durvalumab with chemotherapy in triple-negative breast cancer. *Clin Cancer Res.* 2020;26(20):5456–5461. doi:10.1158/1078-0432.CCR-20-1303
97. Twomey JD, Zhang B. Cancer immunotherapy update: FDA-approved checkpoint inhibitors and companion diagnostics. *AAPS J.* 2021;23:1–11. doi:10.1208/s12248-021-00574-0
98. Hargadon KM, Johnson CE, Williams CJ. Immune checkpoint blockade therapy for cancer: an overview of FDA-approved immune checkpoint inhibitors. *Int Immunopharmacol.* 2018;62:29–39. doi:10.1016/j.intimp.2018.06.001
99. Bräutigam K, Kabore-Wolff E, Hussain AF, et al. Inhibitors of PD-1/PD-L1 and ERK1/2 impede the proliferation of receptor positive and triple-negative breast cancer cell lines. *J Cancer Res Clin Oncol.* 2021;147(10):2923–2933. doi:10.1007/s00432-021-03694-4
100. Emens LA, Cruz C, Eder JP, et al. Long-term clinical outcomes and biomarker analyses of atezolizumab therapy for patients with metastatic triple-negative breast cancer: a Phase 1 study. *JAMA Oncol.* 2019;5(1):74–82. doi:10.1001/jamaoncol.2018.4224
101. Li L, Yang LL, Yang SL, et al. Andrographolide suppresses breast cancer progression by modulating tumor-associated macrophage polarization through the Wnt/ β -catenin pathway. *Phytother Res.* 2022;36(12):4587–4603. doi:10.1002/ptr.7578
102. Xie W, Zhang Y, Zhang S, et al. Oxymatrine enhanced anti-tumor effects of Bevacizumab against triple-negative breast cancer via abating Wnt/ β -Catenin signaling pathway. *Am J Cancer Res.* 2019;9(8):1796.
103. Wang J, Qi H, Zhang X, et al. Saikosaponin D from Radix Bupleuri suppresses triple-negative breast cancer cell growth by targeting β -catenin signaling. *Biomed Pharmacother.* 2018;108:724–733. doi:10.1016/j.biopha.2018.09.038
104. Kombiyil S, Sivasithamparam ND. In vitro anti-cancer effect of Crataegus oxyacantha berry extract on hormone receptor positive and triple negative breast cancers via regulation of canonical Wnt signaling pathway. *Appl Biochem Biotechnol.* 2023;195(4):2687–2708. doi:10.1007/s12010-021-03724-4
105. Xu X, Rajamanicham V, Xu S, et al. Schisandrin A inhibits triple negative breast cancer cells by regulating Wnt/ER stress signaling pathway. *Biomed Pharmacother.* 2019;115:108922.
106. Lorusso PM. Inhibition of the PI3K/AKT/mTOR pathway in solid tumors. *J Clin Oncol.* 2016;34(31):3803–3815. doi:10.1200/JCO.2014.59.0018
107. Kofuji S, Kimura H, Nakanishi H, et al. INPP4B is a PtdIns (3, 4, 5) P3 phosphatase that can act as a tumor suppressor. *Cancer Discover.* 2015;5(7):730–739. doi:10.1158/2159-8290.CD-14-1329
108. Reed DE, Shokat KM. INPP4B and PTEN loss leads to PI-3, 4-P2 accumulation and inhibition of PI3K in TNBC. *Molecul Cancer Res.* 2017;15(6):765–775.
109. Guerini-Rocco E, Piscuoglio S, Ng CK, et al. Microglandular adenosis associated with triple-negative breast cancer is a neoplastic lesion of triple-negative phenotype harbouring TP53 somatic mutations. *J Pathol.* 2016;238(5):677–688.
110. Solzak JP, Atale RV, Hancock BA, et al. Dual PI3K and Wnt pathway inhibition is a synergistic combination against triple negative breast cancer. *NPJ Breast Cancer.* 2017;3(1):17. doi:10.1038/s41523-017-0016-8
111. Wu H-T, Lin J, Liu Y-E, et al. Luteolin suppresses androgen receptor-positive triple-negative breast cancer cell proliferation and metastasis by epigenetic regulation of MMP9 expression via the AKT/mTOR signaling pathway. *Phytomedicine.* 2021;81:153437. doi:10.1016/j.phymed.2020.153437
112. Lee SH, Lee JS, Park JH, et al. Glycolytic metabolic remodeling by the truncate of glioma-associated oncogene homolog 1 in triple-negative breast cancer cells. *J Cancer.* 2022;13(10):3031. doi:10.7150/jca.72793
113. Pietrobono S, Gagliardi S, Stecca B. Non-canonical hedgehog signaling pathway in cancer: activation of GLI transcription factors beyond smoothed. *Front Genetics.* 2019;10:556. doi:10.3389/fgene.2019.00556
114. Wang Y, Sui Y, Tao Y. Gambogic acid increases the sensitivity to paclitaxel in drug-resistant triple-negative breast cancer via the SHH signaling pathway. *Molecul Med Rep.* 2019;20(5):4515–4522.
115. Bao C, Kim MC, Chen J, et al. Sulforaphene interferes with human breast cancer cell migration and invasion through inhibition of hedgehog signaling. *J Agricult Food Chemist.* 2016;64(27):5515–5524. doi:10.1021/acs.jafc.6b02195
116. Zhang S, Chung W-C, Miele L, et al. Targeting met and notch in the Lfng-deficient, Met-amplified triple-negative breast cancer. *Cancer Biol Ther.* 2014;15(5):633–642.
117. Kushwaha PP, Vardhan PS, Kapewangolo P, et al. Bulbine frutescens phytochemical inhibits notch signaling pathway and induces apoptosis in triple negative and luminal breast cancer cells. *Life Sci.* 2019;234:116783. doi:10.1016/j.lfs.2019.116783
118. Yang J, Mani SA, Donaher JL, et al. Twist, a master regulator of morphogenesis, plays an essential role in tumor metastasis. *cell.* 2004;117(7):927–939.
119. Chen Y, Li L, Zeng J, et al. Twist confers chemoresistance to anthracyclines in bladder cancer through upregulating P-glycoprotein. *Chemotherapy.* 2012;58(4):264–272. doi:10.1159/000341860

Breast Cancer: Targets and Therapy

Publish your work in this journal

Breast Cancer - Targets and Therapy is an international, peer-reviewed open access journal focusing on breast cancer research, identification of therapeutic targets and the optimal use of preventative and integrated treatment interventions to achieve improved outcomes, enhanced survival and quality of life for the cancer patient. The manuscript management system is completely online and includes a very quick and fair peer-review system, which is all easy to use. Visit <http://www.dovepress.com/testimonials.php> to read real quotes from published authors.

Submit your manuscript here: <https://www.dovepress.com/breast-cancer—targets-and-therapy-journal>

Dovepress
Taylor & Francis Group