

# Management of Regorafenib-Induced Hand-Foot Skin Reaction with Topical Chinese Medicine and Urea Ointment: A Case Report and Literature Review

Zhe-Ning Liu<sup>1,2</sup>, Yu-Lei Shen<sup>1,2</sup>, Hui-Jing Dong<sup>1,2</sup>, Ke-Xin Tan<sup>1,2</sup>, Jia Li<sup>1,2</sup>, Yan-Mei Peng<sup>3</sup>, Hui-Juan Cui<sup>2</sup>

<sup>1</sup>Graduate School, Beijing University of Chinese Medicine, Beijing, 100029, People's Republic of China; <sup>2</sup>Oncology Department of Integrative Medicine, China-Japan Friendship Hospital, Beijing, 100029, People's Republic of China; <sup>3</sup>Oncology Department, Beijing Fangshan District Traditional Chinese Medicine Hospital, Beijing, 102401, People's Republic of China

Correspondence: Yan-Mei Peng, Beijing Fangshan District Traditional Chinese Medicine Hospital, No. 4, Chengguan Baojian Road, Fangshan District, Beijing, 102400, People's Republic of China, Email kaixin52184@163.com; Hui-Juan Cui, China-Japan Friendship Hospital, No. 2 Yinghua East Road, Chaoyang District, Beijing, 100029, People's Republic of China, Email cuihj1963@sina.com

**Abstract:** Regorafenib, a multikinase inhibitor, frequently induces severe hand-foot skin reactions (HFSR), often requiring dose reduction or discontinuation. This case report demonstrates the successful management of HFSR in a patient with fibromyxoid sarcoma using topical Chinese medicine “Shouzuping” soaking combined with urea ointment. It suggests the unique advantages of integrated traditional Chinese and Western medicine in managing HFSR. This article further reviews the clinical characteristics, pathogenesis, prevention and treatment strategies of HFSR caused by targeted therapies, with a view to providing valuable clinical insights.

**Keywords:** HFSR, topical Chinese medicine, Regorafenib, fibromyxoid sarcoma, case report

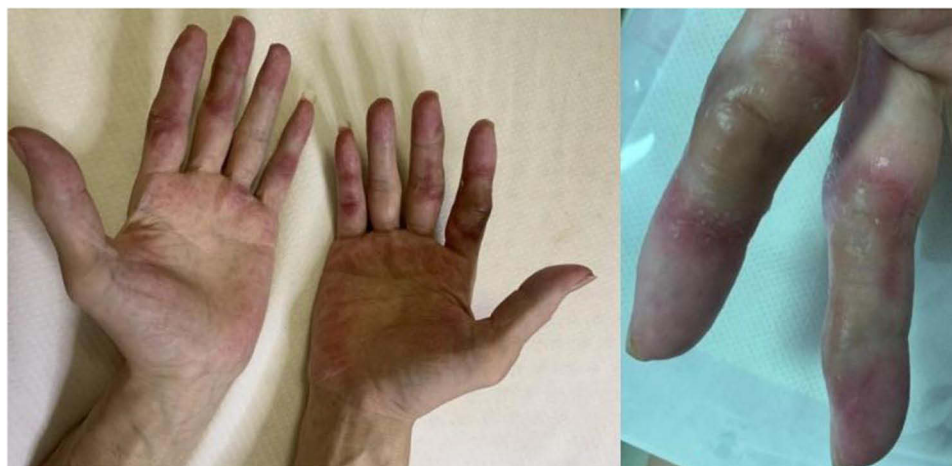## Introduction

Regorafenib is an oral, broad-spectrum multikinase inhibitor (MKI) that has an anti-angiogenic and tumor cell proliferation mechanism.<sup>1</sup> It has been approved for use in advanced colorectal cancer,<sup>2</sup> advanced gastrointestinal stromal tumors<sup>3</sup> and hepatocellular carcinoma,<sup>4</sup> and has shown clinical anticancer activity against soft tissue sarcomas and osteosarcomas in multiple clinical trials.<sup>5</sup> Hand-foot skin reaction (HFSR) is a common adverse reaction of MKI drugs. HFSR is characterized by erythematous and bullous lesions due to necrosis of epidermal keratinocytes,<sup>6</sup> which often occur 2–4 weeks after the use of regorafenib.<sup>7</sup> Severe HFSR seriously affects the patient's life and activity, leading to treatment reduction or One of the main reasons for discontinuation of medication. Controlling HFSR is crucial to improving patients' medication compliance and quality of life.

This article reports a case of severe HFSR associated with regorafenib treated with external Chinese medicine soaking and urea ointment. The efficacy is significant and can provide clinical reference. It also reviews relevant literature to explore the mechanism of severe HFSR and the advantage of external Chinese medicine.

## Clinical Information

The patient, a 55-year-old middle-aged male, was diagnosed with low-grade fibromyxoid sarcoma on September 15, 2020. He had undergone surgery, apatinib, and furiquntinib treatment and progressed. He started combined immunotherapy with sintilimab on July 7, 2023, and started oral regorafenib 120 mg qd on July 29, 2023. After taking regorafenib for 10 days, erythema appeared on the joints of the index and middle fingers of both hands, accompanied by pain when the fingers were flexed and extended. In the following days, the edges of the erythema continued to expand, and at the same time, bullae formed in the center, the fingers swelled, and the pain worsened. And new red spots continued to appear on the little fingers, palms and other parts of the body.



**Figure 1** Palm and fingers before treatment.

He visited the outpatient clinic on August 10, 2023. The patient reported that the pain was unbearable when moving his hands, which was slightly relieved when resting, accompanied by numbness and abnormal needle-like sensations. Sensitive to temperature and cannot tolerate cold or hot water. A physical examination of his hands revealed swelling of the interphalangeal joints of the index finger, middle finger, little finger, and metacarpophalangeal joint of the ring finger, multiple bullae and erythema, and difficulty in flexing and extending the fingers (Figure 1). NRS score 4–5 points. Physical examination by traditional Chinese medicine shows a red tongue, less fur, and a thin and weak pulse.

The patient had no history of skin diseases on the hands and feet or systemic diseases causing skin lesions, and was considered to be diagnosed with regorafenib-related HFSR. According to the treatment based on syndrome differentiation of traditional Chinese medicine, systemic dialectics and local dialectics are combined, and the syndrome is blood stasis combined with dampness and heat. Treatment includes nourishing and activating blood, resolving stasis and pain, and clearing heat and drying dampness. The patient was treated with 21 doses of prescription “Shouzuping” (Table 1) soaked and washed combined with urea ointment. Method of use: Add Chinese medicine to 3000 mL of boiling water. When the water temperature drops to 38 to 42°C, soak the hands and feet for 30 minutes each time, once in the morning and evening. After soaking, apply urea ointment topically.

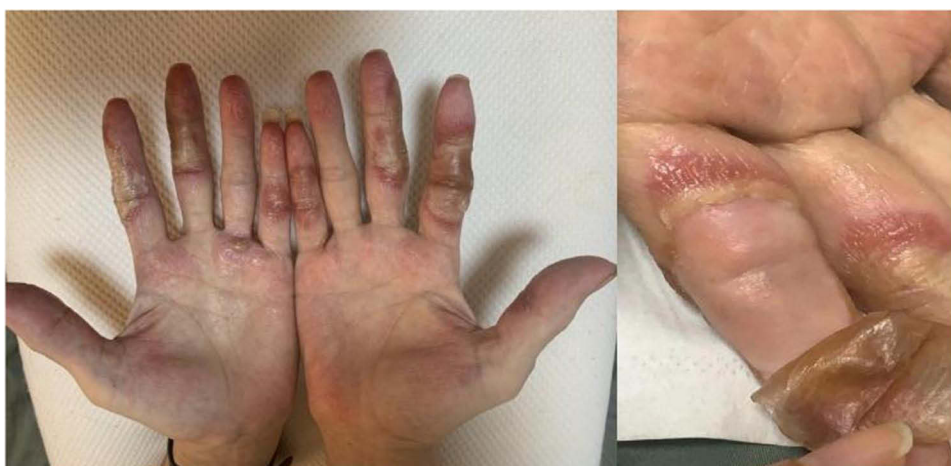7 days after taking the medication (August 18, 2023, Figure 2), the area of erythema did not continue to expand, the bullae formed calluses, and there were fissures at the edges. New tissue was visible after falling off. The pain was relieved than before, and the NRS score was 3–4 points.

15 days after treatment (2023-8-27, Figure 3), the erythema area did not continue to expand, the bullae and calluses disappeared, light red new tissue and surface scales were visible in the original lesion area, the pain was relieved, and the NRS score was 1–2 points.

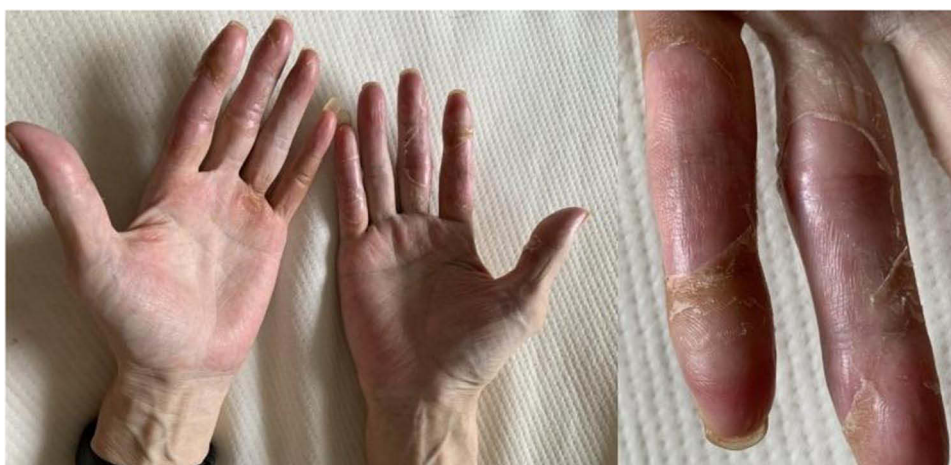Follow-up after 21 days of medication (2023-9-8, Figure 4), the original lesion area was basically healed, with only a small amount of scales, and the NRS score was 0 points. The patient did not experience any dose reduction or

**Table 1** Composition of the “Shouzuping”

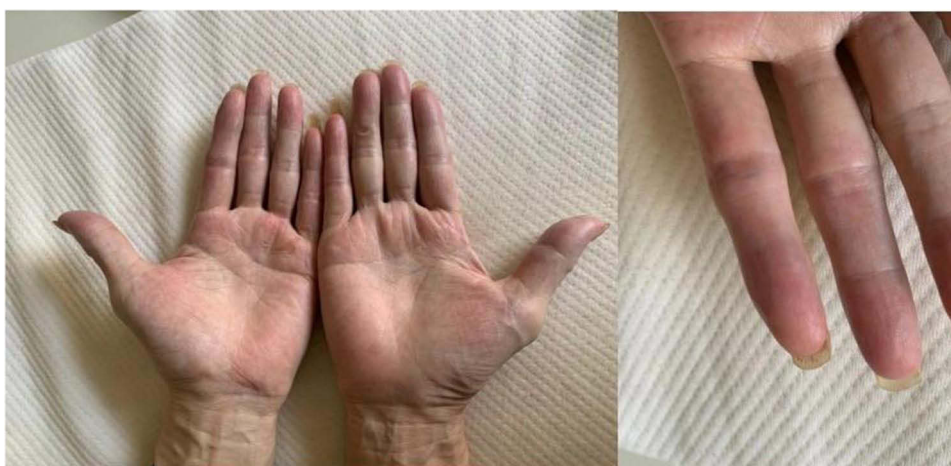Name of Herb	Dosages
Rhizoma Chuanxiong	20g
Jinyinhua	20g
Moutan Cortex	15g
Carthamus tinctorius L.	10g
Cortex Phellodendri	10g
Scutellaria baicalensis	10g
Salvia miltiorrhiza	15g
Suberect Spatholobus Stem	10g



**Figure 2** Palms and fingers after 7 days of treatment.



**Figure 3** Palms and fingers after 14 days of treatment.



**Figure 4** Palms and fingers after 21 days of treatment.

discontinuation of regorafenib during the course of HFSR. After resolution, he stopped Chinese medicine soaking, and we recommended continued use of urea ointment to prevent symptom recurrence.

## Literature Review

### The Mechanism of HFSR

The molecular mechanism of regorafenib-induced HFSR has not yet been determined. The use of multiple MKIs may produce similar clinical symptoms, which indicates that there may be some common mechanisms that may lead to the occurrence of HFSR, and the influencing factors are as follows.

### Physiological Characteristics of Hands and Feet

The occurrence of HFSR is related to the physiological characteristics of the hands and feet. The hands and feet are important structures that support the daily life and activities of the human body. Therefore, they are often subject to friction and mechanical pressure. Physical damage to the skin causes capillary and blood vessel damage. The epidermis of normal people has a certain self-repair function. The process of skin repair and restoration of homeostasis involves three main participating parts: keratinocytes, angiogenesis, and inflammatory response.<sup>8,9</sup> In patients who use MKIs such as regorafenib, the normal functions of local keratinocytes and capillaries are destroyed, resulting in vulnerability to trauma and relatively insufficient post-traumatic repair, resulting in local inflammatory reactions. After capillary damage, harmful substances are more likely to leak into surrounding tissues, leading to increased drug levels in the tissues. On the other hand, there are many exocrine glands in the palms and soles of the feet. Some researchers believe that MKI drugs cause damage to epidermal keratinocytes and endocrine sweat glands during their excretion through sweat. And it was determined that the levels of drugs and metabolites in patients' sweat were positively correlated with the severity of HFSR.<sup>10</sup> Since PDGFR and c-KIT are expressed in endocrine sweat gland tissue,<sup>11,12</sup> inhibition of PDGFR and c-KIT by MKIs may cause sweat gland abnormalities.

### Regulation of Vascular Endothelial Targets

The occurrence of HFSR is regulated by relevant targets on capillary endothelium. VEGFR is a key target causing HFSR. The VEGF pathway regulates the proliferation, migration, and survival of vascular endothelial cells.<sup>13</sup> VEGF antibodies cause damage to the vascular endothelium of the hands and feet, destabilizing blood vessels, causing local ischemia, hypoxia, and microcirculation disorders. In a meta-analysis,<sup>14</sup> the incidence of all-grade and high-grade HFSR was significantly higher in patients treated with MKIs combined with the VEGF antibody bevacizumab than with any MKI monotherapy. Further subgroup analysis showed that increasing the dose of bevacizumab (77.8% vs 51.1%,  $P=0.04$ ) and MKI (64.3% vs 52.6%,  $P=0.02$ ) could significantly increase the incidence of HFSR. In addition, VEGF is the most effective pro-angiogenic mediator in the skin. Angiogenesis is also involved in the repair of skin damage. VEGF is of great significance in tissue repair.<sup>15</sup> It has been observed in clinical applications of bevacizumab treatment It can lead to poor wound healing,<sup>16</sup> which indicates that inhibition of VEGFR plays a key role in the occurrence and development of HFSR.

PDGFR may be an auxiliary target. PDGF is an important mediator of wound healing and is released by platelets, macrophages, endothelial cells and fibroblasts.<sup>17</sup> May improve dermal regeneration, promote local protein and collagen synthesis, and induce endothelial migration or angiogenesis. Inhibition of PDGFR can lead to insufficient post-traumatic repair. Multi-target inhibitors of VEGFR and PDGFR, such as regorafenib, sorafenib, and sunitinib, have a higher incidence of HFSR than single-target VEGFR-TKIs. Dual inhibition of VEGFR and PDGFR causes tumor vessel regression and interferes with pericyte-mediated endothelial cell survival.<sup>18</sup> This inhibition results in coordinated disruption of endothelial and vascular repair of normal tissue. Local tissue damage is exacerbated in areas susceptible to friction and mechanical stress. When PDGFR is inhibited alone, HFSR is less common, such as the PDGFR inhibitor imatinib, whose side effects usually manifest as rash, dryness, etc.

c-Kit ligands exist on keratinocytes and vascular endothelial cells to promote proliferation, migration, and angiogenesis. Inhibiting c-Kit may have direct toxic effects on keratinocytes and vascular endothelial cells.<sup>19</sup>

In addition, regorafenib uniquely blocks TIE-2 receptors in normal vascular endothelium, thereby interfering with the angiopoietin (ANG)/TIE-2 signaling pathway. The interaction between tyrosine kinase receptor proteins (TIE-1, TIE-2) and their ligands (angiopoietin: ANG-1, ANG-2, and ANG-4) in this pathway jointly regulates vascular remodeling.

During this process, vascular pericytes are damaged, and the instability and permeability of blood vessels are increased, accompanied by the release of pro-inflammatory factors.<sup>20</sup>

### Keratinocyte Toxicity

Keratinocyte cytotoxicity results in a high incidence of HFSR. A study<sup>21</sup> observed the direct cytotoxic effects of 21 tyrosine kinase inhibitors (TKIs) on primary cultured human keratinocytes, and 18 of them reduced cell viability in a dose-dependent manner. The ratio of the patient's trough concentration ( $C_{\text{trough}}$ ) to the  $LC_{50}$  value of reduced cell viability was higher than the unity value of the four HFSR-inducing TKIs, indicating that these TKIs can cause keratinocyte toxicity at clinically relevant concentrations. In addition, 8 TKIs that induce HFSR have inhibitory effects on VEGFR-2, and their  $C_{\text{trough}}/IC_{50, \text{VEGFR-2}}$  values are greater than 1. This study proposes that HFSR induced by TKIs may be related to direct keratinocyte toxicity, VEGFR-2 inhibition, and inflammatory response to physically damaged skin.

### Drug Accumulation

Drug accumulation is one of the triggering factors of HFSR. Extended medication time, increased medication dosage, and combined use of similar drugs may intensify the occurrence of side effects. The severity of HFSR is related to the time of drug use. The results of skin biopsy of seven HFSE patients by some researchers<sup>6</sup> showed necrosis of the keratinocyte horizontal layer, which is related to the time of drug exposure: early stage (<30 years from the beginning of drug use) leads to changes in the granular layer and stratum spinosum, and late stages ( $\geq 30$  days) lead to stratum corneum lesions. The incidence of HFSR is affected by the dosage and combination of medications. It has been reported that the incidence of HFSR increases in a dose-dependent manner after treatment with regorafenib.<sup>22</sup> Another study showed that the frequency and severity of HFSR were increased in patients receiving anti-VEGF therapy with sorafenib plus bevacizumab.<sup>23</sup> In clinical practice, dose reduction and treatment interruption remain the only definitive treatments for HFSR, which generally resolve within 2–4 weeks after discontinuation of treatment.

In summary, current research shows that MKIs-induced HFSR involves multiple mechanisms: capillary and sweat gland damage in the hands and feet, regulation of vascular endothelial targets, direct keratinocyte toxicity, and drug accumulation (Figure 5). This skin toxicity is related to multiple pharmacological targets of MKIs. In addition, this patient had previously received apatinib and fruquintinib, MKI drugs that can cause HFSR, and no adverse skin reactions occurred during use. However, whether these drug histories promoted the activation of relevant target receptors and ultimately caused skin Sensitization, thereby making severe HFSR more likely to occur after regorafenib use, is currently unknown.

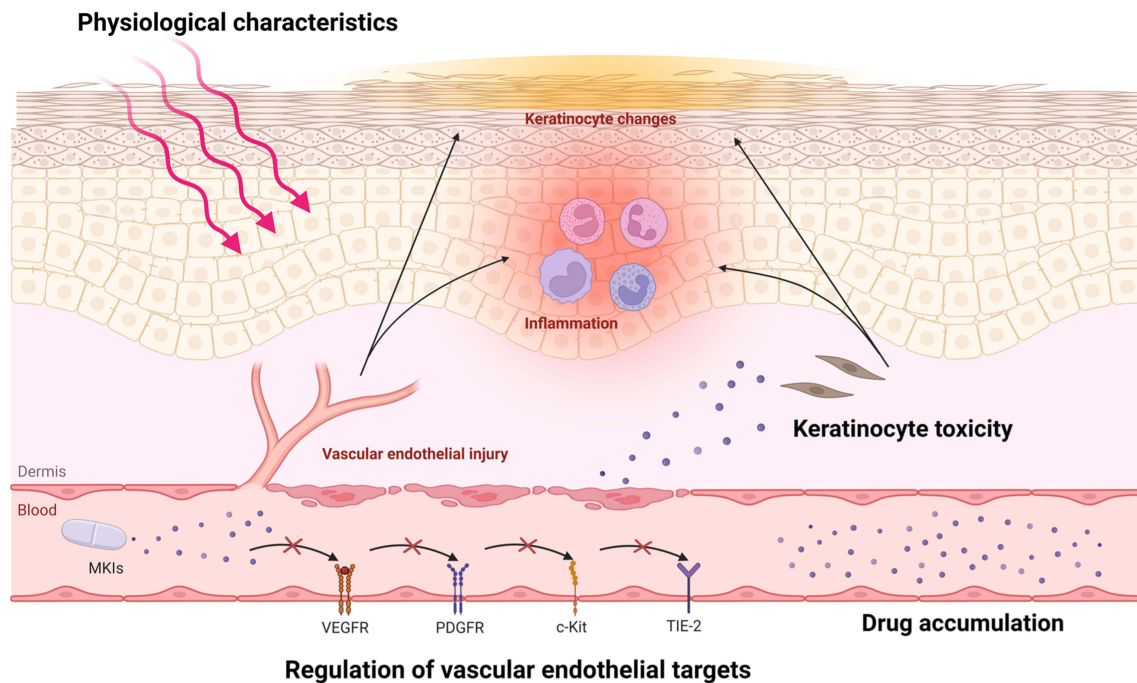
## Treatment of HFSR

### Modern Medical Treatment

HFSR has keratinocyte changes, including parakeratosis and apoptosis, as well as histological manifestations such as telangiectasia and inflammatory infiltration.<sup>22</sup> Topical drug treatments with keratolytic, antiproliferative and anti-inflammatory properties therefore show benefit. The current ESMO anticancer drug-related skin toxicity guidelines recommend focusing on preventing physical damage.<sup>24</sup> In terms of treatment, urea cream or salicylic acid preparations can be applied topically to promote exfoliation of cuticles, 5% lidocaine cream or patch can be applied for symptomatic analgesia, glucocorticoids are anti-inflammatory, and antibacterial solutions can be used to treat erosion and ulcers. However, western medicine treatment options are difficult to solve the problems of severe local pain, abnormal sensation, difficulty in wound healing, and local blood vessel damage repair in patients with high-grade HFSR.

### Traditional Chinese Medicine Treatment

External treatment of traditional Chinese medicine is a common intervention measure for skin diseases. Topical application allows the effect of the medicine to reach the hospital directly. Multiple studies have shown that topical Chinese medicine, as a complementary treatment option, has unique advantages in dealing with adverse skin reactions related to tumor treatment. Topical Chinese medicine can prevent and treat radiation dermatitis caused by local radiotherapy of malignant tumors. Meta-analysis results show that various combinations of Chinese medicine can reduce the severity of radiation dermatitis, delay its occurrence, and accelerate the healing of skin lesions.<sup>25</sup> Topical Chinese medicine can alleviate chemotherapy-induced peripheral neurotoxicity (CIPN) and hand-foot syndrome (HFS) in



**Figure 5** The mechanism of HFSR. The figure shows localized skin and blood vessels on hand or feet with HFSR. Red cells representing endothelial cells, yellow spindle-shaped cells as keratinocytes, and purple particles as MKI drug components. After entering the bloodstream, MKIs regulate vascular endothelial targets, including VEGFR, PDGFR, c-Kit, TIE-2, leading to endothelial cell damage. This injury triggers inflammation in the affected blood vessels and surrounding skin tissue, followed by changes in epidermal keratinocytes, which form the basis of HFSR. The hands and feet, with their physiological characteristics of frequent exposing to pressure and friction, and the blood vessels on the hands and feet are particularly susceptible to injury, which act as triggers for HFSR. Prolonged drug use, increased dosage, or drug accumulation due to combination therapies exacerbates the damage and inflammation. Additionally, MKIs directly cause keratinocyte toxicity, further contributing to the development of HFSR.

Colorectal cancer. Five randomized controlled trials evaluated the use of traditional Chinese medicine hand and foot soaks plus chemotherapy versus chemotherapy alone to prevent and treat oxaliplatin-induced CIPN symptoms. Compared with the control group, the incidence of all grades of CIPN in the comprehensive treatment group was reduced, and the alleviation effect on low-grade CIPN was better.<sup>26</sup> In an evaluation of the efficacy and safety of Shouzu Ning Decoction compared with halometasone plus celecoxib in patients with grade 2 HFSR,<sup>27</sup> the topical Chinese medicine group had a higher clinical remission rate and improved life. The quality effect is better. In another observation of the efficacy of traditional Chinese medicine oil in alleviating HFSR caused by regorafenib,<sup>28</sup> the overall quality of life, physical function, social function, and emotional function of the patients in the intervention group were significantly improved, while pain symptoms improved significantly. In the above studies of topical Chinese medicines, only a few patients experienced allergic reactions. Therefore, traditional Chinese medicine can reduce the incidence of adverse skin reactions related to tumor treatment, promote the healing of skin lesions, reduce the grade of adverse reactions, improve the quality of life of patients, and has good safety, has been widely used in China. In the 2020 Chinese consensus on drug safety management of anti-angiogenic tyrosine kinase inhibitors for the treatment of bone and soft tissue sarcoma, “topical Chinese medicine preparations” are recommended as type 3 evidence for the treatment of HFSR.<sup>29</sup>

## Discussion

Low-grade fibromyxoid sarcoma (LGFMS) is a rare type of soft tissue sarcomas (STS),<sup>30</sup> which usually presents as a slowly growing, painless mass in the deep soft tissues of the lower limbs or trunk. Due to its low incidence and numerous subtypes, it is clinically extremely complex and difficult to treat. The prognosis of locally advanced or metastatic STS is poor, and the options for chemotherapy drugs and treatment options are limited. In recent years, the exploration of anti-angiogenic treatment options in the field of STS has been ongoing. Various MKIs have completed Phase II or Phase III clinical trials in advanced STS such as pazopanib,<sup>31</sup> sunitinib,<sup>32</sup> sorafenib,<sup>33</sup> regorafenib,<sup>34</sup> cediranib,<sup>35</sup> apatinib,<sup>36</sup> etc. According to the REGOSARC<sup>34</sup> trial (ClinicalTrials.gov, NCT01900743), mPFS in the Regorafenib group compared with the placebo group was 4 months

(95% CI 2.6–5.5) vs 1 month (95% CI 0.9–1.8) (HR =0.36, P <0.001), mOS was 13.4 months (95% CI 8.6–17.3) vs 9 months (95% CI 6.8–12.5) (HR=0.67). Therefore, it was recommended by the 2018 NCCN Clinical Practice Guidelines for Soft Tissue Sarcomas. Anti-angiogenic drugs can promote the accumulation and activation of immune cells by normalizing tumor blood vessels and improving the tumor microenvironment. From a mechanism perspective, there is a synergistic effect between anti-angiogenic therapy and immunotherapy, and novel treatments using MKIs combined with immune checkpoint inhibitors may improve the prognosis of sarcoma.<sup>37</sup> This patient with fibromyxoid sarcoma was treated with regorafenib combined with sintilimab after failure of multiple lines of treatment. As writing this article, the PFS has reached 6.4 months.

Despite achieving certain therapeutic effects, patients using regorafenib are often plagued by side effects. Due to the broad range of effects of regorafenib on multiple targets (VEGF-R1/-R2/-R3, FGFR-1, PDGFR- $\alpha/\beta$ , KIT, RET, RAF and p38 MAPK), its adverse effects are The incidence rate is significantly higher than other MKIs. In a meta-analysis,<sup>20</sup> the overall incidence of all-grade HFSR in the regorafenib group was 60.5%, which was higher than previously reported sorafenib (33.8%)<sup>38</sup> and axitinib<sup>37</sup> (29.2%), sunitinib<sup>39</sup> (18.9%) and pazopanib<sup>40</sup> (4.5%). In patients with soft tissue sarcoma, the incidence of severe HFSR caused by regorafenib is higher, which may be related to the high therapeutic dose of MKIs commonly used in patients with sarcoma. In published trials of sarcoma patients, regorafenib resulted in grade  $\geq 3$  hFSR in 5–17%.<sup>5</sup>

Patients with HFSR initially present with local erythema and hypoesthesia, and then the pain in the erythema area continues to increase, and the central part exhibits callus-like thickening. Severe patients develop bullae, fissures, exfoliation, and ulcers,<sup>41</sup> accompanied by severe pain and unable to take care of themselves. The patient in this case had a clear history of medication. He began to develop hand and foot skin reactions 10 days after taking the medication, which continued to worsen. The time of treatment was the 14th day after taking the medication. The changes were consistent with this process. The patient had no history of allergies and denied other exposures. He was considered to be diagnosed with HFSR caused by regorafenib. According to the National Cancer Institute (NCI) CTCAE 4.0 grading standard, it was evaluated as a grade III severe adverse reaction. The patient's disease site was localized and he had no special systemic symptoms. Therefore, local treatment was mainly used, including topical urea cream combined with traditional Chinese medicine soaking and washing. The treatment effect was satisfactory.

According to TCM theory, HFSR caused by Regorafenib belongs to the category of “blood arthralgia”, which is a type of limb and joint disease caused by blockage of channels and disturbance of Ying, Wei, Qi and blood. This patient's syndrome is deficiency in origin and excess in superficiality. Cancer toxins easily damage healthy qi, then the body is deficient, and drug eruption invades the skin and enter the meridians to damage the blood. The local syndrome differentiation is mainly stasis, dampness, and heat-toxin syndrome. Treatment is based on nourishing and activating blood, resolving stasis and pain, and clearing heat and drying dampness. “Shouzuping” consists of 8 kinds of herbs. Suberect Spatholobus Stem is the basis of this prescription to nourish and activate blood, replenishing the source for the production and transformation of Qi and blood. Rhizoma Chuanxiong can promote blood and Qi circulation, relieving pain. Salvia miltiorrhiza, Carthamus tinctorius L., and Moutan Cortex remove the blood stasis and unblock meridians, making the blood run smoothly, and nourishing the ends of the limbs. Jinyinhua, Scutellaria baicalensis and Cortex Phellodendri clear away heat and remove dampness, causing the heat to come out and resolve it. They have the functions of nourishing blood, removing the blood stasis, unblocking meridians, detoxifying, clearing away heat and promoting dampness. The above Chinese herbs play a synergistic effect and directly act on the affected area through local soaking and external application without affecting the treatment of the primary tumor.

Modern pharmacological research shows that this prescription has pharmacological effects such as improving the blood supply, promoting wound healing, anti-inflammation and analgesia. Traditional Chinese medicine can upregulate the HIF-1 $\alpha$ -VEGF pathway and regulate endothelial nitric oxide synthase (eNOS)/NO downstream of VEGF, promote ischemic remodeling and angiogenesis, and improve blood supply to the hands and feet. For local tissue damage and inflammatory infiltration, traditional Chinese medicine can inhibit inflammation and oxidative stress-related pathways, reduce the levels of multiple inflammatory factors, relieve pain, and promote wound healing.

Hypoxia-inducible factor-1 $\alpha$  is an important upstream transcriptional regulator of VEGF. Ferulic acid, the main component of Chuanxiong, can upregulate HIF-1 $\alpha$ ,<sup>42</sup> enhance the expression of locally inhibited VEGF and PDGF to promote angiogenesis. Hydroxysafflor yellow A from safflower can upregulate HIF-1 $\alpha$ -VEGF and regulate Bcl-2/Bax, thereby

increasing the survival rate of vascular endothelial cells.<sup>43</sup> eNOS plays a major role in VEGF-induced angiogenesis and vascular permeability. VEGF induces the production of NO through eNOS.<sup>44</sup> NO can promote relaxation of vascular smooth muscle cells and vasodilation, stimulate angiogenesis and the proliferation of fibroblasts and keratinocytes.<sup>45</sup> Various phenolic acid components in *Salvia miltiorrhiza*, such as tanshinone, salvianolic acid, and rosmarinic acid, can upregulate the expression of the endothelial nitric oxide synthase (eNOS) promoter.<sup>46,47</sup> Ferulic acid can increase NO levels, inhibit oxidative stress, and promote wound healing.<sup>48</sup> Topical application of ferulic acid can effectively relieve chronic inflammation and tissue edema.<sup>49</sup> Paeoniflorin from peony bark can reduce postoperative pain in mice and accelerate the proliferation of skin fibroblasts,<sup>50</sup> and activate the Nrf2 pathway to increase endothelial cell proliferation and migration, reduce cell apoptosis, and promote wound healing.<sup>51</sup> *Scutellaria baicalensis* contains active ingredients such as baicalin and baicalein, can reduce the expression of inflammatory cytokines such as NF- $\kappa$ B and COX-2, inhibit the activation and infiltration of macrophages and the proliferation of keratinocytes, have significant anti-inflammatory activity.<sup>52–54</sup> Salvianolic acid B from *Salvia miltiorrhiza*, has immunomodulatory, anti-inflammatory and skin protection,<sup>55</sup> can inhibit the PI3K/Akt signaling pathway, thereby inhibiting inflammation (downregulating IL-22, IL-23, IL-17A, IL-1 $\beta$  and IL-6) and the expression of keratin markers (downregulating K16 and K17).<sup>56</sup> It can also eliminate and inhibit the production of ROS by regulating the Nrf2/Keap1 pathway, exerting a pharmacological effect of anti-oxidative damage.<sup>57</sup> Tanshinone IIA blocks the activation of the ERK-NF- $\kappa$ B pathway, downregulates TRPV1, and improves pain and heat sensitivity induced by inflammation.<sup>58</sup> The flavonoid components in honeysuckle have pharmacological effects such as anti-inflammatory, analgesic, immune-enhancing, and cell pyroptosis inhibition.<sup>59</sup> The main component, chlorogenic acid, participates in the regulation of inflammatory signaling pathways such as NF- $\kappa$ B and Nrf2, regulates inflammatory factors such as TNF- $\alpha$ , IL-1 $\beta$ , IL-6, and IL-8, and reduces oxidative stress and inflammatory response.<sup>60</sup> *Phellodendron amurense* contains a variety of natural alkaloid components such as phellodendronine, berberine, and magnolia alkaloids, which can inhibit NF- $\kappa$ B and MAPK activation, and have potential benefits in various inflammatory and oxidative stress aspects.<sup>61</sup>

Based on the observation of this patient, soaking has been found effective in softening calluses. It is important to maintain the water temperature at a suitable level to avoid local irritation from excessively cold or hot water. Following each soak, urea ointment is applied to promote cuticle exfoliation and accelerate the shedding of hyperkeratosis on the skin lesions' surface. Concurrently, traditional Chinese medicine ingredients exhibit anti-inflammatory, analgesic, and wound-healing effects on the expanding inflammatory areas under and around the callus. As a result, after initiating the soaking and washing treatment, the patient's NRS score continued to decrease. The abnormal temperature sensation and transient tingling were alleviated compared to before, and the erythema's edge did not progress further. Once the cuticle is shed, the new subcutaneous tissue appears light red and feels soft, allowing normal flexion and extension of the joints. The patient's overall HFSR grade improved from grade 3 to grade 1. Regarding quality of life, HFSR had previously reduced the patient's ability to perform self-care tasks such as cleaning, dressing, using tableware, and lifting items, which improved after treatment. Cancer patients often take multiple medications and have serious comorbidities, so interventions for anticancer drug toxicity should not cause additional adverse effects. This patient reported no relevant adverse reactions during the entire course of external Chinese medicine treatment. Due to the continuous use of MKIs, the area of HFSR in the patient continued to expand. Timely treatment prevented further worsening of HFSR, enabling the patient to tolerate the antitumor drugs without reduction or discontinuation of regorafenib. Which will help provide more evidence-based medical evidence for this treatment option. Indeed, the availability of Chinese medicine may be limited in certain parts of the world, which poses a challenge to its widespread use. In the future, it could be developed as a proprietary Chinese medicine for further testing and promotion.

## Conclusion

This case demonstrates the therapeutic value of topical Chinese medicine for the skin toxicity associated with MKIs. In the future, we can further explore the combined treatment approach of Chinese medicine with topical preparations recommended by guidelines to develop a more effective integrated management model. Cutaneous toxicity from MKIs is complex, involving multiple factors and pharmacological targets. For HFSR, it is essential to investigate the synergistic effects of these factors, elucidate its underlying mechanisms, and enhance diagnosis and treatment guidelines to ensure optimal treatment doses, improved clinical outcomes, and enhanced quality of life for patients.

## Ethics Approval and Consent to Participate

The study, including the publication of case details and any accompanying images, received approval from the ethics committee of China-Japan Friendship Hospital and obtained written informed consent from the participant.

## Funding

This work was supported by National Natural Science Foundation of China (82104879), Beijing Municipal Science and Technology Plan (Z221100007422103).

## Disclosure

The authors declare that there are no competing interests in this work.

## References

1. Wilhelm SM, Dumas J, Adnane L, et al. Regorafenib (BAY 73-4506): a new oral multikinase inhibitor of angiogenic, stromal and oncogenic receptor tyrosine kinases with potent preclinical antitumor activity. *Int J Cancer*. 2011;129(1):245–255. doi:10.1002/ijc.25864
2. Grothey A, Van Cutsem E, Sobrero A, et al. Regorafenib monotherapy for previously treated metastatic colorectal cancer (CORRECT): an international, multicentre, randomised, placebo-controlled, Phase 3 trial. *Lancet*. 2013;381(9863):303–312. doi:10.1016/S0140-6736(12)61900-X
3. Demetri GD, Reichardt P, Kang YK, et al. Efficacy and safety of regorafenib for advanced gastrointestinal stromal tumours after failure of imatinib and sunitinib (GRID): an international, multicentre, randomised, placebo-controlled, phase 3 trial. *Lancet*. 2013;381(9863):295–302. doi:10.1016/S0140-6736(12)61857-1
4. Bruix J, Qin S, Merle P, et al. Regorafenib for patients with hepatocellular carcinoma who progressed on sorafenib treatment (RESORCE): a randomised, double-blind, placebo-controlled, phase 3 trial [published correction appears in *Lancet*. *Lancet*. 2017;389(10064):56–66. doi:10.1016/S0140-6736(16)32453-9
5. Blay JY, Duffaud F, George S, et al. Regorafenib for the treatment of sarcoma. *Curr Treat Options Oncol*. 2022;23(11):1477–1502. doi:10.1007/s11864-022-00990-0
6. Lacouture ME, Reilly LM, Gerami P, et al. Hand foot skin reaction in cancer patients treated with the multikinase inhibitors sorafenib and sunitinib. *Ann Oncol*. 2008;19(11):1955–1961. doi:10.1093/annonc/mdn389
7. Sastre J, Argilés G, Benavides M, et al. Clinical management of regorafenib in the treatment of patients with advanced colorectal cancer. *Clin Transl Oncol*. 2014;16(11):942–953. doi:10.1007/s12094-014-1212-8
8. Rittié L. Cellular mechanisms of skin repair in humans and other mammals. *J Cell Commun Signal*. 2016;10(2):103–120. doi:10.1007/s12079-016-0330-1
9. Li J, Zhang YP, Kirsner RS. Angiogenesis in wound repair: angiogenic growth factors and the extracellular matrix. *Microsc Res Tech*. 2003;60(1):107–114. doi:10.1002/jemt.10249
10. Lankheet NA, Huitema AD, Mallo H, et al. The effect of seasonal variation and secretion of sunitinib in sweat on the development of hand-foot syndrome. *Eur J Clin Pharmacol*. 2013;69(12):2065–2072. doi:10.1007/s00228-013-1579-4
11. Lammie A, Drobnjak M, Gerald W, et al. Expression of c-kit and kit ligand proteins in normal human tissues. *J Histochem Cytochem*. 1994;42(11):1417–1425. doi:10.1177/42.11.7523489
12. Pontén F, Ren Z, Nistér M, et al. Epithelial-stromal interactions in basal cell cancer: the PDGF system. *J Invest Dermatol*. 1994;102(3):304–309. doi:10.1111/1523-1747.ep12371787
13. Khodabakhsh F, Merikhan P, Eisavand MR, et al. Crosstalk between MUC1 and VEGF in angiogenesis and metastasis: a review highlighting roles of the MUC1 with an emphasis on metastatic and angiogenic signaling. *Cancer Cell Int*. 2021;21(1):200. doi:10.1186/s12935-021-01899-8
14. Zhu Y, Zhang X, Lou X, et al. Vascular endothelial growth factor (VEGF) antibody significantly increases the risk of hand-foot skin reaction to multikinase inhibitors (MKIs): a systematic literature review and meta-analysis. *Clin Exp Pharmacol Physiol*. 2018;45(7):659–667. doi:10.1111/1440-1681.12935
15. Eming SA, Krieg T. Molecular mechanisms of VEGF-A action during tissue repair. *J Invest Dermatol Symp Proc*. 2006;11(1):79–86. doi:10.1038/sj.jidsymp.5650016
16. Scappaticci FA, Fehrenbacher L, Cartwright T, et al. Surgical wound healing complications in metastatic colorectal cancer patients treated with bevacizumab. *J Surg Oncol*. 2005;91(3):173–180. doi:10.1002/jso.20301
17. Judith R, Nithya M, Rose C, et al. Application of a PDGF-containing novel gel for cutaneous wound healing. *Life Sci*. 2010;87(1–2):1–8. doi:10.1016/j.lfs.2010.05.003
18. McLellan B, Ciardiello F, Lacouture ME, et al. Regorafenib-associated hand-foot skin reaction: practical advice on diagnosis, prevention, and management. *Ann Oncol*. 2015;26(10):2017–2026. doi:10.1093/annonc/mdv244
19. Pathania S, Pentikäinen OT, Singh PK. A holistic view on c-Kit in cancer: structure, signaling, pathophysiology and its inhibitors. *Biochim Biophys Acta Rev Cancer*. 2021;1876(2):188631. doi:10.1016/j.bbcan.2021.188631
20. Cascone T, Heymach JV. Targeting the angiopoietin/Tie2 pathway: cutting tumor vessels with a double-edged sword? *J Clin Oncol*. 2012;30(4):441–444. doi:10.1200/JCO.2011.38.7621
21. Hasan Alshammari A, Masuo Y, Fujita KI, et al. Discrimination of hand-foot skin reaction caused by tyrosine kinase inhibitors based on direct keratinocyte toxicity and vascular endothelial growth factor receptor-2 inhibition. *Biochem Pharmacol*. 2022;197:114914. doi:10.1016/j.bcp.2022.114914
22. Mross K, Frost A, Steinbild S, et al. A Phase I dose-escalation study of regorafenib (BAY 73-4506), an inhibitor of oncogenic, angiogenic, and stromal kinases, in patients with advanced solid tumors. *Clin Cancer Res*. 2012;18(9):2658–2667. doi:10.1158/1078-0432.CCR-11-1900

23. Azad NS, Aragon-Ching JB, Dahut WL, et al. Hand-foot skin reaction increases with cumulative sorafenib dose and with combination anti-vascular endothelial growth factor therapy. *Clin Cancer Res*. 2009;15(4):1411–1416. doi:10.1158/1078-0432.CCR-08-1141
24. Yu HB, Han BJ, Cao HJ. Prevention of radiodermatitis with topical Chinese herbal medicine: a systematic review and meta-analysis. *Front Pharmacol*. 2022;13:819733. doi:10.3389/fphar.2022.819733
25. Liu Y, May BH, Zhang AL, et al. Integrative herbal medicine for chemotherapy-induced peripheral neuropathy and hand-foot syndrome in colorectal cancer: a systematic review and meta-analysis. *Integr Cancer Ther*. 2019;18:1534735418817833. doi:10.1177/1534735418817833
26. Shou L, Shao T, Chen J, et al. The efficacy and safety of the Shouzu Ning decoction treatment versus halometasone plus celecoxib treatment in patients with grade 2 hFSR: a randomized clinical trial. *Integr Cancer Ther*. 2023;22:15347354231168796. doi:10.1177/15347354231168796
27. Zhang L, Cai J, Sun H, et al. Efficacy of compound traditional Chinese medicine oil in alleviating regorafenib-induced hand-foot skin reaction. *Asia Pac J Oncol Nurs*. 2021;9(2):125–129. doi:10.1016/j.apjon.2021.10.002
28. Chinese Medical Doctor Association Bone Tumor Professional Committee, China Bone Tumor Research Collaboration Group. Consensus on the safe management of anti-angiogenic tyrosine kinase inhibitors in the treatment of bone and soft tissue sarcomas. *Chinese Journal of Clinical Oncology*. 2020;47(4):163–171.
29. Nishio J, Iwasaki H, Nabeshima K, et al. Cytogenetics and molecular genetics of myxoid soft-tissue sarcomas. *Genet Res Int*. 2011;2011:497148. doi:10.4061/2011/497148
30. van der Graaf WT, Blay JY, Chawla SP, et al. Pazopanib for metastatic soft-tissue sarcoma (PALETTE): a randomised, double-blind, placebo-controlled phase 3 trial. *Lancet*. 2012;379(9829):1879–1886. doi:10.1016/S0140-6736(12)60651-5
31. Mahmood ST, Agresta S, Vigil CE, et al. Phase II study of sunitinib malate, a multitargeted tyrosine kinase inhibitor in patients with relapsed or refractory soft tissue sarcomas. Focus on three prevalent histologies: leiomyosarcoma, liposarcoma and malignant fibrous histiocytoma. *Int J Cancer*. 2011;129(8):1963–1969. doi:10.1002/ijc.25843
32. Maki RG, D'Adamo DR, Keohan ML, et al. Phase II study of sorafenib in patients with metastatic or recurrent sarcomas. *J Clin Oncol*. 2009;27(19):3133–3140. doi:10.1200/JCO.2008.20.4495
33. Mir O, Brodowicz T, Italiano A, et al. Safety and efficacy of regorafenib in patients with advanced soft tissue sarcoma (REGOSARC): a randomised, double-blind, placebo-controlled, Phase 2 trial. *Lancet Oncol*. 2016;17(12):1732–1742. doi:10.1016/S1470-2045(16)30507-1
34. Judson I, Scurr M, Gardner K, et al. Phase II study of cediranib in patients with advanced gastrointestinal stromal tumors or soft-tissue sarcoma. *Clin Cancer Res*. 2014;20(13):3603–3612. doi:10.1158/1078-0432.CCR-13-1881
35. Liao Z, Li F, Zhang C, et al. Phase II trial of VEGFR2 inhibitor apatinib for metastatic sarcoma: focus on efficacy and safety. *Exp mol Med*. 2019;51(3):1–11.
36. Nishio J, Nakayama S. Biology and management of high-grade myxofibrosarcoma: state of the art and future perspectives. *Diagnostics*. 2023;13(19):3022. doi:10.3390/diagnostics13193022
37. Chu D, Lacouture ME, Fillos T, Wu S. Risk of hand-foot skin reaction with sorafenib: a systematic review and meta-analysis. *Acta Oncol*. 2008;47(2):176–186. doi:10.1080/02841860701765675
38. Fischer A, Wu S, Ho AL, et al. The risk of hand-foot skin reaction to axitinib, a novel VEGF inhibitor: a systematic review of literature and meta-analysis. *Invest New Drugs*. 2013;31(3):787–797. doi:10.1007/s10637-013-9927-x
39. Balagula Y, Wu S, Su X, et al. The risk of hand foot skin reaction to pazopanib, a novel multikinase inhibitor: a systematic review of literature and meta-analysis. *Invest New Drugs*. 2012;30(4):1773–1781. doi:10.1007/s10637-011-9652-2
40. Belum VR, Wu S, Lacouture ME. Risk of hand-foot skin reaction with the novel multikinase inhibitor regorafenib: a meta-analysis. *Invest New Drugs*. 2013;31(4):1078–1086. doi:10.1007/s10637-013-9977-0
41. Luo Y, Wang CZ, Sawadogo R, et al. Effects of herbal medicines on pain management. *Am J Chin Med*. 2020;48(1):1–16. doi:10.1142/S0192415X20500019
42. Lin CM, Chiu JH, Wu IH, et al. Ferulic acid augments angiogenesis via VEGF, PDGF and HIF-1 alpha. *J Nutr Biochem*. 2010;21(7):627–633. doi:10.1016/j.jnutbio.2009.04.001
43. Ji DB, Zhu MC, Zhu B, et al. Hydroxysafflor yellow A enhances survival of vascular endothelial cells under hypoxia via upregulation of the HIF-1 alpha-VEGF pathway and regulation of Bcl-2/Bax. *J Cardiovasc Pharmacol*. 2008;52(2):191–202. doi:10.1097/FJC.0b013e318181fb02
44. Fukumura D, Gohongi T, Kadambi A, et al. Predominant role of endothelial nitric oxide synthase in vascular endothelial growth factor-induced angiogenesis and vascular permeability. *Proc Natl Acad Sci U S A*. 2001;98(5):2604–2609. doi:10.1073/pnas.041359198
45. Stallmeyer B, Kämpfer H, Kolb N, et al. The function of nitric oxide in wound repair: inhibition of inducible nitric oxide-synthase severely impairs wound reepithelialization. *J Invest Dermatol*. 1999;113(6):1090–1098. doi:10.1046/j.1523-1747.1999.00784.x
46. De G, Yang M, Cai W, et al. Salvia miltiorrhiza augments endothelial cell function for ischemic hindlimb recovery. *Biol Chem*. 2023;405(2):119–128. doi:10.1515/hsz-2022-0316
47. Jia Q, Zhu R, Tian Y, et al. Salvia miltiorrhiza in diabetes: a review of its pharmacology, phytochemistry, and safety. *Phytomedicine*. 2019;58:152871. doi:10.1016/j.phymed.2019.152871
48. Ghaisas MM, Kshirsagar SB, Sahane RS. Evaluation of wound healing activity of ferulic acid in diabetic rats. *Int Wound J*. 2014;11(5):523–532. doi:10.1111/j.1742-481X.2012.01119.x
49. Fernández MA, Sáenz MT, García MD. Anti-inflammatory activity in rats and mice of phenolic acids isolated from *Scrophularia frutescens*. *J Pharm Pharmacol*. 1998;50(10):1183–1186. doi:10.1111/j.2042-7158.1998.tb03332.x
50. Andoh T, Goto M. Repeated topical paeoniflorin attenuates postoperative pain and accelerates cutaneous fibroblast proliferation in mice. *J Pharmacol Sci*. 2023;151(2):84–87. doi:10.1016/j.jphs.2022.12.004
51. Sun X, Wang X, Zhao Z, et al. Paeoniflorin accelerates foot wound healing in diabetic rats through activating the Nrf2 pathway. *Acta Histochem*. 2020;122(8):151649. doi:10.1016/j.acthis.2020.151649
52. Hong GE, Kim JA, Nagappan A, et al. Flavonoids identified from Korean *Scutellaria baicalensis* Georgi inhibit inflammatory signaling by suppressing activation of NF- $\kappa$ B and MAPK in RAW 264.7 cells. *Evid Based Complement Alternat Med*. 2013;2013:912031. doi:10.1155/2013/912031
53. Wang PW, Lin TY, Yang PM, et al. Therapeutic efficacy of *Scutellaria baicalensis* Georgi against psoriasis-like lesions via regulating the responses of keratinocyte and macrophage. *Biomed Pharmacother*. 2022;155:113798. doi:10.1016/j.biopha.2022.113798

54. Wu X, Deng X, Wang J, et al. Baicalin inhibits cell proliferation and inflammatory cytokines induced by Tumor Necrosis Factor  $\alpha$  (TNF- $\alpha$ ) in Human Immortalized Keratinocytes (HaCaT) Human Keratinocytes by Inhibiting the STAT3/Nuclear Factor kappa B (NF- $\kappa$ B) signaling pathway. *Med Sci Monit.* 2020;26:e919392. doi:10.12659/MSM.919392
55. He G, Chen G, Liu W, et al. Salvianolic acid B: a review of pharmacological effects, safety, combination therapy, new dosage forms, and novel drug delivery routes. *Pharmaceutics.* 2023;15(9):2235. doi:10.3390/pharmaceutics15092235
56. Wang S, Zhu L, Xu Y, et al. Salvianolic acid B ameliorates psoriatic changes in imiquimod-induced psoriasis on BALB/c mice by inhibiting inflammatory and keratin markers via altering phosphatidylinositol-3-kinase/protein kinase B signaling pathway. *Korean J Physiol Pharmacol.* 2020;24(3):213–221. doi:10.4196/kjpp.2020.24.3.213
57. Xiao Z, Liu W, Mu YP, et al. Pharmacological effects of Salvianolic Acid B against oxidative damage. *Front Pharmacol.* 2020;11:572373. doi:10.3389/fphar.2020.572373
58. Sun S, Yin Y, Yin X, et al. Anti-nociceptive effects of Tanshinone IIA (THIA) in a rat model of complete Freund's adjuvant (CFA)-induced inflammatory pain. *Brain Res Bull.* 2012;88(6):581–588. doi:10.1016/j.brainresbull.2012.06.002
59. Li CC, Wang L, Guan KK, et al. Optimization of extraction of flavonoids from *Lonicera rupicola* and analysis of its effects in resisting inflammation, relieving pain, enhancing immunity, and inhibiting pyroptosis. *Zhongguo Zhong Yao Za Zhi.* 2021;46(22):5877–5886. doi:10.19540/j.cnki.cjcmm.20210722.701
60. Huang J, Xie M, He L, et al. Chlorogenic acid: a review on its mechanisms of anti-inflammation, disease treatment, and related delivery systems. *Front Pharmacol.* 2023;14:1218015. doi:10.3389/fphar.2023.1218015
61. Choi YY, Kim MH, Han JM, et al. The anti-inflammatory potential of Cortex Phellodendron in vivo and in vitro: down-regulation of NO and iNOS through suppression of NF- $\kappa$ B and MAPK activation. *Int Immunopharmacol.* 2014;19(2):214–220. doi:10.1016/j.intimp.2014.01.020

## OncoTargets and Therapy

### Publish your work in this journal

OncoTargets and Therapy is an international, peer-reviewed, open access journal focusing on the pathological basis of all cancers, potential targets for therapy and treatment protocols employed to improve the management of cancer patients. The journal also focuses on the impact of management programs and new therapeutic agents and protocols on patient perspectives such as quality of life, adherence and satisfaction. The manuscript management system is completely online and includes a very quick and fair peer-review system, which is all easy to use. Visit <http://www.dovepress.com/testimonials.php> to read real quotes from published authors.

Submit your manuscript here: <https://www.dovepress.com/oncotargets-and-therapy-journal>

**Dovepress**  
Taylor & Francis Group