

# Successful Treatment of Facial Multiple Melanocytic Nevus-Like Dark Macules Caused by Severe Acne Vulgaris by a Single Session of Intense Pulsed Light Treatment

Jinxiang Yang<sup>1,2,\*</sup>, Jinwen Shen<sup>1,2,\*</sup>, Yuwei Kong<sup>1,2,\*</sup>, Lei Wang<sup>1,2</sup>, Zhirong Yao<sup>1,2</sup>, Jianying Liang<sup>1,2</sup>, Xia Yu<sup>1,2</sup>

<sup>1</sup>Department of Dermatology, Xinhua Hospital, Shanghai Jiaotong University School of Medicine, Shanghai, People's Republic of China; <sup>2</sup>Institute of Dermatology, Shanghai Jiaotong University School of Medicine, Shanghai, People's Republic of China

\*These authors contributed equally to this work

Correspondence: Xia Yu, Department of Dermatology, Xinhua Hospital, Shanghai Jiaotong University School of Medicine; Institute of Dermatology, Shanghai Jiaotong University School of Medicine, Shanghai, 200092, People's Republic of China, Tel +86-25076927, Email 10517832@qq.com; jianyingliang@163.com

**Background and Objective:** The case report aims to demonstrate the therapeutic effects of a single session of intense pulsed light (IPL) treatment on facial multiple melanocytic nevus-like dark macules induced by severe acne vulgaris.

**Materials and Methods:** A 17-year-old male with acne was assessed as Pillsbury IV according to the Pillsbury classification. After three sessions of photodynamic therapy (PDT), he experienced an increase in number and darkening of facial melanocytic nevus-like dark macules. We attempted to use broadband light (BBL) (SCITON Company, USA) (420nm, 8J, 180ms; 515nm, 13J, 20ms; 560nm, 16J, 24ms; 590nm, 16J, 24ms) therapy to improve post-inflammatory erythema (PIE) and post-inflammatory hyperpigmentation (PIH). Following a baseline assessment, we performed a single session of IPL treatment on the patient and evaluated the changes in melanocytic nevus-like dark macules, PIE, PIH, and sebum secretion through standardized photography.

**Results:** Compared to the baseline, we observed a significant reduction of the patient's melanocytic nevus-like dark macules and a significant improvement in PIE, PIH, and sebum secretion after a single IPL treatment.

**Conclusions:** This study provides preliminary evidence of the effects of IPL treatment on melanocytic nevi associated with severe acne vulgaris. Further research is warranted to elucidate the underlying mechanisms and promote the wider application of this treatment modality in managing acne sequelae.

**Keywords:** acne vulgaris, intense pulsed light, melanocytic nevus, photodynamic therapy

## Introduction

Acne vulgaris is a common dermatological condition that can lead to significant psychological distress due to its impact on physical appearance.<sup>1</sup> In addition to active lesions, post-inflammatory changes such as erythema, hyperpigmentation, and the development of melanocytic nevus-like dark macules are common sequelae that can persist and exacerbate the patient's condition.<sup>2</sup> The application of confocal microscopy and dermatoscopy aids in the non-invasive determination of the benign or malignant nature of pigmentary disorders.<sup>3</sup> Long-term follow-up helps assess the efficacy and safety of laser technologies such as IPL for treating of pigmentary disorders.

The introduction of light-based therapies, particularly intense pulsed light (IPL), has provided a promising non-invasive treatment modality for various dermatological conditions, including pigmentary disorders.<sup>4</sup> IPL exerts selective photothermolysis to target and disrupt specific melanin, playing a role in the treatment of diseases with abnormal pigmentation and selectively destroying melanin-rich hair follicles for hair removal purposes.<sup>5</sup> This case report presents

a unique case of a patient with severe acne vulgaris who developed multiple melanocytic nevus-like dark macules and experienced a significant improvement following a single session of IPL treatment. The findings highlight the potential of IPL for treating post-acne pigmentary changes, which is crucial for managing such conditions.

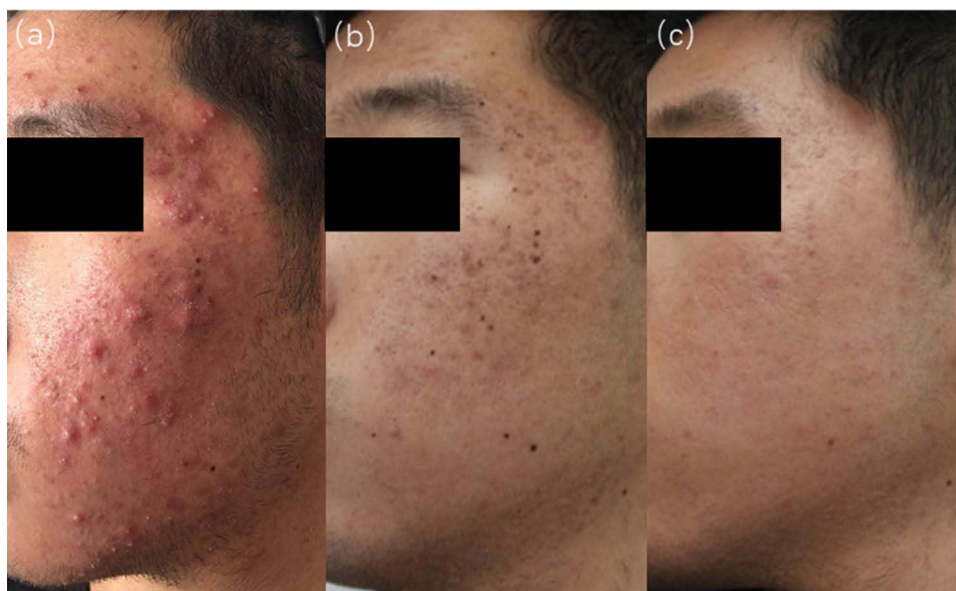
## Case Report

A 17-year-old male presented to our department with a 4-year history of recurrent severe inflammatory acne vulgaris manifesting as red papules, nodules, and cystic lesions on his face. The lesions were classified as Pillsbury IV. The patient complained of persistent recurrence of rash and an increase in the number of multiple black spots of 1mm to 2mm diameter on his face. Considering potential photosensitivity and side effects of tetracycline and retinoid medications, which could exacerbate the hyperpigmentation, the patient refused oral medications. Therefore, 5-aminolevulinic acid-photodynamic therapy (ALA-PDT) was administered. After three treatments of ALA-PDT, there was noticeable improvement in inflammatory skin lesions. However, the melanocytic nevus-like dark macules showed a slight increase in number and pigmentation (Figure 1a and b).

Six weeks after completing three sessions of PDT, the patient returned for follow-up, showing further improvement in inflammatory skin lesions. However, post-inflammatory erythema (PIE), post-inflammatory hyperpigmentation (PIH) and melanocytic nevus-like dark macules were still evident. Consequently, the patient received one session of broadband light (BBL) therapy (SCITON Company, USA) (420nm, 8J, 180ms; 515nm, 13J, 20ms; 560nm, 16J, 24ms; 590nm, 16J, 24ms). When the patient returned one month later, we were surprised to find significant subsidence of the melanocytic nevus-like dark macules and significant improvement of PIE, PIH and sebum secretion after a single session compared to the baseline (Figure 1c).

## Discussion

The patient developed significant facial multiple melanocytic nevus-like dark macules during severe inflammatory acne vulgaris, which deepened and increased in number after three sessions of ALA-PDT treatment. But the melanocytic nevus-like dark macules significantly subsided after a single session treatment of IPL. Further studies are needed to explore the underlying mechanisms of this uncommon response. It has been reported that inflammation can lead to increased melanocyte activity, closely related to the severity of inflammation and the degree of epidermal



**Figure 1** Severe acne patient developed multiple melanocytic nevus-like dark macules on the face after three sessions of ALA-PDT treatment and subsided after one session of BBL treatment. (a) PDT baseline. The patient presented with red papules, nodules, and cystic lesions, as well as multiple black spots measuring 1mm to 2mm in diameter. (b) BBL baseline, which is 6 weeks after last PDT treatment. The increased and deepened of melanocytic nevus-like dark macules after three ALA-PDT treatments, while the acne lesions subsided. (c) One month after one session of BBL. The melanocytic nevus-like dark macules subsided after one session of BBL treatment, and PIH and PIE improved.

destruction,<sup>6</sup> which is considered a potential cause for the increase in the number of multiple facial melanocytic nevus-like dark macules. Meanwhile, it has been shown that ALA-PDT can activate melanocytes,<sup>7</sup> which may lead to further aggravation of melanocytic nevus-like dark macules in this case. Furthermore, we report here, for the first time, that IPL is effective in improving melanocytic nevus-like dark macules caused by this kind of cause. Several cases and observational trials have been reported regarding the regression of melanocytic nevus under IPL during hair removal treatment.<sup>5,8–10</sup> Therefore, IPL can be considered for post-inflammatory hyperpigmentation in melanocytic nevi-like dark macules, especially in cosmetically sensitive areas like the face, reduce unnecessary surgical treatment, minimize postoperative scarring, and lower overall treatment costs.

The effect of IPL on epidermal pigment is evident attributed to the characteristics of wavelength depth. Most of the regression of melanocytic nevus-like dark macules after IPL hair removal reported in previous studies occurred after multiple treatments.<sup>5,9,10</sup> However, in our patient, his melanocytic nevus-like dark macules were significantly improved after only one session of IPL treatment. We speculate that these dark spots may not be true melanocytic nevi, but rather epidermal spots with melanocyte proliferation and without nevus cell nests, such as sunspots or freckles. Unfortunately, as this was an incidental finding during the IPL treatment process, we did not have pre-treatment skin pathological examinations or dermatoscopic assessments to substantiate our hypothesis. Additional case accumulation and histopathological studies are needed to further validate our findings. Although there are currently no clear reports of IPL-induced melanoma, and due to the lack of long-term follow-up data, we still recommend a comprehensive physical examination of the laser treatment area prior to IPL, and dermatoscopic examination for melanocytic nevi with a potential for malignancy.

The diagnostic methods for distinguishing melanocytic nevi from melanoma under dermatoscopy are well-established, including the ABCD rule and the 7-point checklist, which assist in non-invasive diagnosis and in determining the benign or malignant nature of nevus-like skin lesions.<sup>11,12</sup> Regarding post-inflammatory hyperpigmentation (PIH), the diagnosis generally relies on the clinical history of skin inflammation, with patchy epidermal or dermal pigmentation.<sup>13</sup> Under dermatoscopy, PIH often presents as diffuse or reticular pigmentation patterns, appearing in shades of brown, blue, or black.<sup>14</sup> Wood's lamp is helpful in clarifying whether the pigmentation is in the epidermis (with increased contrast) or the dermis (without increased contrast), especially in the case of melasma.<sup>15,16</sup>

In conclusion, the incidence of acne vulgaris is high and severe sequelae symptoms can lead to severe disfigurement phobia. Our study is the first study to suggest an increase in facial melanocytic nevus-like dark macules after severe acne vulgaris and significant regression after a single session of IPL treatment. It is of great importance for the treatment of acne sequelae and the improvement of appearance-related anxiety in patients.

## Data Sharing Statement

Data sharing not applicable to this article as no datasets were generated or analyzed during the current study.

## Ethics Approval and Informed Consent

The patient and his parents in this manuscript have provided written informed consent for the publication of their case details. No institutional approval was required.

## Acknowledgment

We appreciate the patient and their relatives for providing us the consent for investigation.

## Author Contributions

All authors made a significant contribution to the work reported, whether that is in the conception, study design, execution, acquisition of data, analysis and interpretation, or in all these areas; took part in drafting, revising or critically reviewing the article; gave final approval of the version to be published; have agreed on the journal to which the article has been submitted; and agree to be accountable for all aspects of the work.

## Funding

This work was supported by grants from the National Natural Science Foundation of China (82203962), the Clinical Research Plan of Shanghai Hospital Development Center (no. SHDC22022302), and the Medical-Engineering Cross Fund of Shanghai Jiao Tong University (YG2021QN57).

## Disclosure

The authors declare no competing interests in this work.

## References

- Samuels DV, Rosenthal R, Lin R, Chaudhari S, Natsuaki MN. Acne vulgaris and risk of depression and anxiety: a meta-analytic review. *J Am Acad Dermatol.* 2020;83(2):532–541. doi:10.1016/j.jaad.2020.02.040
- Eimpunth S, Wanitphadeedecha R, Manuskiatti W. A focused review on acne-induced and aesthetic procedure-related postinflammatory hyperpigmentation in Asians. *J Eur Acad Dermatol Venereol.* 2013;27(1):7–18. doi:10.1111/jdv.12050
- Steiner A, Pehamberger H, Wolff K. In vivo epiluminescence microscopy of pigmented skin lesions. II. Diagnosis of small pigmented skin lesions and early detection of malignant melanoma. *J Am Acad Dermatol.* 1987;17(4):584–591. doi:10.1016/S0190-9622(87)70240-0
- Passeron T, Genedy R, Salah L, et al. Laser treatment of hyperpigmented lesions: position statement of the European Society of Laser in Dermatology. *J Eur Acad Dermatol Venereol.* 2019;33(6):987–1005. doi:10.1111/jdv.15497
- Cices A, Dover JS, Labadie JG. Changes in melanocytic nevi treated with laser hair removal: a systematic review. *Lasers Surg Med.* 2023;55(7):617–624. doi:10.1002/lsm.23712
- Ho SG, Chan HH. The Asian dermatologic patient: review of common pigmentary disorders and cutaneous diseases. *Am J Clin Dermatol.* 2009;10(3):153–168. doi:10.2165/00128071-200910030-00002
- Monfrecola G, Procaccini EM, D'Onofrio D, et al. Hyperpigmentation induced by topical 5-aminolaevulinic acid plus visible light. *J Photochem Photobiol B.* 2002;68(2–3):147–155. doi:10.1016/S1011-1344(02)00384-6
- Pampín Franco A, Gamó Villegas R, Floristán Muruzábal U, Ascanio Armada L, Pinedo F, López-Estebarez JL. Changes in melanocytic nevi after laser treatment evaluated by dermoscopy and reflectance confocal microscopy. *Int J Dermatol.* 2016;55(5):e307–309. doi:10.1111/ijd.13083
- Dessinioti C, Tsiakou A, Christodoulou A, Stratigos AJ. Clinical and Dermoscopic Findings of Nevi after Photoepilation: a Review. *Life.* 2023;13(9). doi:10.3390/life13091832
- Guicciardi F, Ferrelli C, Rongioletti F, Atzori L. Dermoscopic evaluation of melanocytic nevi changes after photo-epilation techniques: a prospective study. *J Eur Acad Dermatol Venereol.* 2019;33(5):954–958. doi:10.1111/jdv.15388
- Nachbar F, Stolz W, Merkle T, et al. The ABCD rule of dermoscopy. High prospective value in the diagnosis of doubtful melanocytic skin lesions. *J Am Acad Dermatol.* 1994;30(4):551–559. doi:10.1016/S0190-9622(94)70061-3
- Argenziano G, Fabbrocini G, Carli P, De Giorgi V, Sammarco E, Delfino M. Epiluminescence microscopy for the diagnosis of doubtful melanocytic skin lesions. Comparison of the ABCD rule of dermoscopy and a new 7-point checklist based on pattern analysis. *Arch Dermatol.* 1998;134(12):1563–1570. doi:10.1001/archderm.134.12.1563
- Farabi B, Khan S, Jamgochian M, Atak MF, Jain M, Rao BK. The role of reflectance confocal microscopy in the diagnosis and management of pigmentary disorders: a review. *J Cosmet Dermatol.* 2023;22(12):3213–3222. doi:10.1111/jocd.15827
- El-Samanoudy SI, Gawdat HI, Fouda KM, Abdelkader HA. Dermoscopy aids in differentiating primary cutaneous amyloidosis and post-inflammatory hyperpigmentation: a clinico-dermoscopic-histopathological study. *J Cosmet Dermatol.* 2022;21(11):6434–6440. doi:10.1111/jocd.15332
- Wirya SA, de Castro Maymone MB, Widjajahakim R, Vashi NA. Subclinical melasma: determining disease extent. *J Am Acad Dermatol.* 2017;77(2):e41–e42. doi:10.1016/j.jaad.2017.03.009
- Gomez-Martinez S, Ibaceta Ayala J, Morgado-Carrasco D. Wood's light in inflammatory and autoimmune dermatoses, infections and skin cancer. *Actas Dermosifiliogr.* 2024. doi:10.1016/j.ad.2024.12.006

Clinical, Cosmetic and Investigational Dermatology

Publish your work in this journal

Clinical, Cosmetic and Investigational Dermatology is an international, peer-reviewed, open access, online journal that focuses on the latest clinical and experimental research in all aspects of skin disease and cosmetic interventions. This journal is indexed on CAS. The manuscript management system is completely online and includes a very quick and fair peer-review system, which is all easy to use. Visit <http://www.dovepress.com/testimonials.php> to read real quotes from published authors.

Submit your manuscript here: <https://www.dovepress.com/clinical-cosmetic-and-investigational-dermatology-journal>

**Dovepress**  
Taylor & Francis Group