


Single-Use Flexible Bronchoscope in Facilitating Endobronchial Valve Treatment in Severe Emphysema

Tadashi Sakaguchi^{1,2}, Dirk-Jan Slebos^{2,3} 

¹Department of Respiratory Medicine, Matsusaka Municipal Hospital, Matsusaka, Mie, Japan; ²Department of Pulmonary Diseases, University of Groningen, University Medical Center Groningen, Groningen, the Netherlands; ³Groningen Research Institute for Asthma and COPD, University of Groningen, University Medical Center Groningen, Groningen, the Netherlands

Correspondence: Tadashi Sakaguchi, Department of Respiratory Medicine, Matsusaka Municipal Hospital, 1550, Tonomachi, Matsusaka, Mie, 515-0073, Japan, Tel +81 598 23 1515, Email iwbd0524@yahoo.co.jp

Abstract: Ensuring proper placement of one-way endobronchial valves is a vital step in achieving successful bronchoscopic lung volume reduction. The ability to navigate into sharply angled airways may be limited by the maximal flexion capability of bronchoscopes. We sometimes encounter difficult anatomical situations, causing a challenging, or sometimes even impossible placement of the EBV in the appropriate position due to steep bronchial bifurcation angles, particularly in the apical segments. A 56-year-old woman with severe emphysema was referred to our hospital after an incomplete EBV treatment due to a very sharp bronchial bifurcation angle in the right upper lobe apical segment (RB1). We were able to easily solve the problem by placing the final RB1 valve using a single-use therapeutic bronchoscope with a greater angulation range than conventional reusable bronchoscopes. The use of single-use therapeutic bronchoscopes with greater flexibility than conventional reusable therapeutic bronchoscopes may be a valuable approach for achieving successful EBV placement in anatomically challenging cases with sharp bronchial branching angles.

Keywords: bronchoscopic lung volume reduction, emphysema, endobronchial valves, single-use bronchoscopy, Zephyr

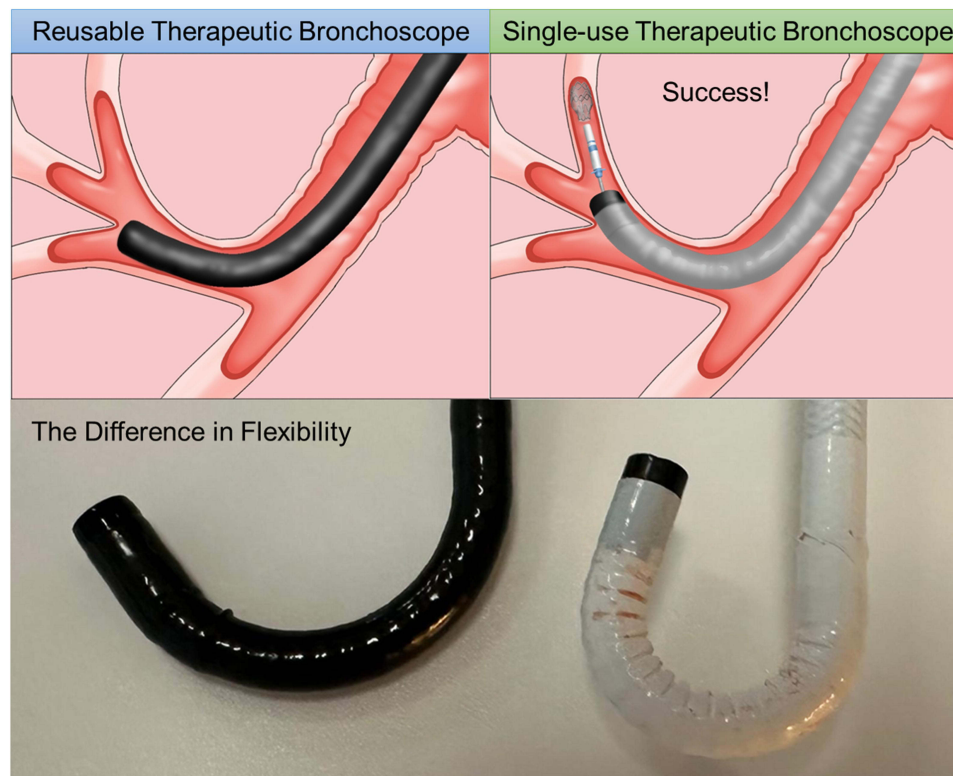
Introduction

The Zephyr endobronchial valve (EBV; Pulmonx Corp., Redwood City, CA, USA) is an implantable device designed to occlude the segmental and lobar bronchi in the most destroyed lobe of the lung in emphysema patients in order to achieve complete lobar collapse. When placed correctly, EBV induces a full lobar collapse, thereby reducing hyperinflation, which manifests in clinical improvement.¹ However, we sometimes encounter anatomical challenges in placing the valves in the appropriate position due to acute angled bronchial bifurcation, particularly in the apical segments. Here, we present a successful bronchoscopic lung volume reduction (BLVR) case with EBVs performed using a single-use flexible bronchoscope, which offers much greater flexion and extension than traditional reusable therapeutic bronchoscopes.

Case Report/Case Presentation

A 56-year-old woman with severe emphysema was referred to our hospital after an incomplete EBV treatment due to a very sharp bronchial bifurcation angle of the right upper lobe apical segment (RB1). The initial right upper lobe EBV procedure was also complicated by an intraprocedural small right-sided pneumothorax, which did not require further interventions but was presumed to reflect the difficulties encountered during the initial procedure. The initial pre-procedure chest CT quantification showed a heterogenous emphysema distribution, with a right upper lobe treatment target with 46% of the voxel density less than -950 hU, and a total right upper lobe fissure completeness score of 98%. The absence of collateral ventilation was confirmed during the initial procedure by

Graphical Abstract



Chartis (PulmonX, Pulmonx Corp., Redwood City, CA, USA), which is an assessment tool for collateral ventilation with a pressure-flow transducer balloon catheter. The chest CT on arrival of the patient in our hospital showed a full recovery of the pneumothorax as well as the insertion of three Zephyr valves in the right upper lobe segments (RB1a1, RB2, and RB3), with the valve in the RB1a1 being placed too distal leaving the RB1a2 and RB1b open. We performed bronchoscopy using 1TH190 (Olympus) under general anesthesia. On inspection, the EBV inserted in RB3 was appropriately placed, the valve in RB2 was misaligned, solved by gentle removal and re-insertion of a new 4.0 valve in the same segment. After this, the too distally placed valve in RB1a1 was removed. At that time, it already became apparent that RB1b would be difficult to reach, with a too short and much too wide landing zone for just a single RB1 valve placement. We first attempted to approach RB1b for sizing with a 5.5 endobronchial delivery catheter (EDC, Pulmonx Corp., Redwood City, CA, USA), but advancing the catheter to the subsegment was difficult due to the steep bronchial bifurcation angles. We then re-attempted to reach the target subsegment by bending the catheter and carefully maneuvering the bronchoscope; however, it remained inaccessible. Therefore, we switched to a single-use bronchoscope (Ambu[®] aScope[™] 5 Broncho HD 5.6/2.8, Ambu A/S, Ballerup, Denmark) with a more flexible tip, as shown in [Figure 1A](#) and [B](#). This change finally enabled us to reach the location and successfully place a 5.5 LP valve in RB1b. After that, we inserted a new 4.0 LP valve in RB1a, completing the placement of valves in all target lobe segments. The post-procedural chest X-ray already showed partial lung volume reduction of the right upper lobe, with no recurrence of the pneumothorax. The patient was discharged uneventfully after three days.

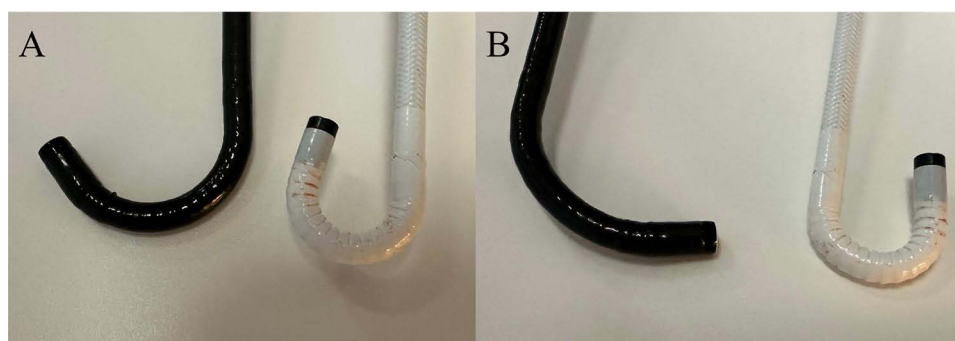


Figure 1 Comparison of the bending range between a reusable therapeutic bronchoscope and a disposable therapeutic bronchoscope. (A) upward bending, (B) downward bending.

Discussion

Achieving significant lung volume reduction is crucial for obtaining clinical benefits from BLVR with EBVs. To achieve this, it is necessary to confirm the absence of collateral ventilation and to properly place valves in all segments or subsegments of the target lung for complete lobar occlusion.²

However, we sometimes encounter challenging anatomical situations in cases where placing the valves in the appropriate position is difficult. Although the important procedural considerations and techniques related to EBV placement have been previously reported, placing the valve in the ideal position can sometimes be challenging due to patient anatomy.² In our experience, the apical segments of the lobe can sometimes be difficult for catheter delivery and valve placement due to steep bronchial bifurcation angles. When a 4.0 EBV is of the appropriate size, delivery is facilitated by the use of a J-type 4.0 EDC. However, if a 5.5 EBV is required, alternative strategies are required. The Zephyr EDC requires therapeutic bronchoscopes with a working channel of 2.8 mm or larger. Although currently available reusable therapeutic bronchoscopes have a bending range of up to 180° for upward angulation and up to 130° for downward angulation, some of the recently introduced single-use therapeutic bronchoscopes offer a bending range of up to 195° to 210° for both upward and downward angulation,³ as summarized in Table 1.

Table 1 List of Therapeutic Bronchoscopes

Reuse/Single-Use Bronchoscope	Traditional Reusable Therapeutic Bronchoscopes						Single-Use Flexible Therapeutic Bronchoscopes					
	Olympus				Fujifilm	PENTAX	Vathin		Ambu	Boston Scientific	PENTAX	The Surgical Company
Company												
Product	XT190	ITH1100/ ITH1200	ITQ290	ITH190	530T	EB19	H-SteriScopes™		aScope™ 5 Broncho	EXALT™ Model B	Medical ONE Pulmo™	Bronchoflex™
							Extra	Large	HD 5.6/ 2.8	Large	EB15- S01	VORTEX
Outer diameter (Insertion tube diameter)	6.1 mm (6.3 mm)	5.8 mm (6.1 mm)	5.9 mm (6.0 mm)	6.2 mm (6.0 mm)	5.8 mm (5.9mm)	6.1 mm (6.4 mm)	6.5 mm (6.2 mm)	5.7 mm (5.8mm)	6.0 mm (5.6mm)	5.8mm	5.8 mm (5.3mm)	5.6mm
Channel size	3.2mm	3.0mm	3.0mm	2.8mm	2.8mm	2.8mm	3.2mm	2.8mm	2.8mm	2.8mm	3.0mm	2.8mm
Upward bending	180°	180°	180°	180°	180°	180°	210°	210°	195°	180°	210°	200°
Downward bending	130°	130°	130°	130°	130°	130°	210°	210°	195°	180°	180°	200°
Rotation	120°	120°	120°	120°	-	-	90°	90°	120°	-	-	-
Field of view	110°	120°	120°	120°	120°	120°	110°	110°	120°	90°	120°	87.5°

In this case, we used a single-use therapeutic bronchoscope capable of bending up to 195° in both upward and downward angles. This flexibility allowed us to successfully place a valve in a bronchus with a steep branching angle, which was in this case impossible with traditional reusable therapeutic bronchoscopes. The fact that the working channel of the reusable bronchoscope is on the right side and in our single-use on the left side might have also facilitated a somewhat easier airway access. To our knowledge, this is the first report showing the utility of single-use therapeutic bronchoscopes in BLVR with EBVs, although almost none of the major reports associated with BLVR with EBVs disclosed whether single-use or reusable bronchoscopes were used. The use of single-use therapeutic bronchoscopes with greater flexibility than conventional reusable therapeutic bronchoscopes may be a valuable approach to achieving successful EBV placement in cases with steep bronchial branching angles that are challenging to approach and is a creative addition to the interventional pulmonologists' toolbox.⁴

Data Sharing Statement

All data in this case report are included in this article. Further enquiries can be directed to the corresponding author.

Ethics Approval and Informed Consent

Ethics approval was not required. Written informed consent was obtained from the patient for publication of this case report and any accompanying images.

Author Contributions

All authors made a significant contribution to the work reported, whether that is in the conception, design of the report, execution, acquisition of data and interpretation, or in all these areas; took part in drafting, revising or critically reviewing the article; gave final approval of the version to be published; have agreed on the journal to which the article has been submitted; and agree to be accountable for all aspects of the work.

Funding

This case report did not receive any specific grants from funding agencies in the public, commercial, or not-for-profit sectors.

Disclosure

Tadashi Sakaguchi reports no conflicts of interest in this work. Dirk-Jan Slebos reports grants and research support from Pulmonx USA; PneumRx/BTG/BSc USA; Broncus USA; FreeFlowMedical USA; Apreo USA; MoreAir USA; PulmAir USA; CSA Medical USA, NuVaira USA; GALA USA, Ryme Medical USA, Thirona NL; 4DM USA/AUS, and consultancy for PulmonX USA; Apreo USA; MoreAir USA; NuVaira USA.

References

1. Klooster K, ten Hacken NH, Hartman JE, et al. Endobronchial valves for emphysema without interlobar collateral ventilation. *N Engl J Med*. 2015;373(24):2325–2335.
2. Klooster K, Slebos DJ. Endobronchial valves for the treatment of advanced emphysema. *Chest*. 2021;159(5):1833–1842. doi:10.1016/j.chest.2020.12.007
3. Deasy KF, Sweeney AM, Danish H, et al. Single use or disposable flexible bronchoscopes: bench top and preclinical comparison of currently available devices. *J Intensive Care Med*. 2023;38(6):519–528. doi:10.1177/08850666221148645
4. Garner JL, Shah PL, Herth F, et al. ERJ advances: interventional bronchoscopy. *Eur Respir J*. 2024;64(1):2301946. doi:10.1183/13993003.01946-2023

International Journal of Chronic Obstructive Pulmonary Disease

Publish your work in this journal

The International Journal of COPD is an international, peer-reviewed journal of therapeutics and pharmacology focusing on concise rapid reporting of clinical studies and reviews in COPD. Special focus is given to the pathophysiological processes underlying the disease, intervention programs, patient focused education, and self management protocols. This journal is indexed on PubMed Central, MedLine and CAS. The manuscript management system is completely online and includes a very quick and fair peer-review system, which is all easy to use. Visit <http://www.dovepress.com/testimonials.php> to read real quotes from published authors.

Submit your manuscript here: <https://www.dovepress.com/international-journal-of-chronic-obstructive-pulmonary-disease-journal>

Dovepress
Taylor & Francis Group